CT-Morphological Characterization of Respiratory Syncytial Virus (RSV) Pneumonia in Immune-Compromised Adults

Morphologische Charakterisierung und Verlaufsbeurteilung von Respiratory Syncytial Virus (RSV) Pneumonien bei immunkompromittierten Erwachsenen in der Thorax-CT

Authors J. L. Mayer[1], N. Lehners[2], G. Egerer[2], H. U. Kauczor[1], C. P. Heußel[3]

Affiliations
[1] Diagnostic and Interventional Radiology, University Hospital Heidelberg
[2] Internal Medicine V of Hematology, Oncology and Rheumatology, University Hospital Heidelberg
[3] Diagnostic and Interventional Radiology with Nuclear Medicine, Thoracic Hospital at Univerity Hospital Heidelberg

Key words
- thorax
- CT
- infection
- sinusitis
- pneumonia
- respiratory syncytial virus (RSV)

received 16.5.2013
accepted 13.11.2013

Bibliography
DOI http://dx.doi.org/10.1055/s-0033-1356353
Published online: 20.2.2014
Fortschr Röntgenstr 2014; 186: 686–692 © Georg Thieme Verlag KG Stuttgart · New York · ISSN 1438-9029

Correspondence
Dr. Johanna Laura Mayer
Diagnostic and Interventional Radiology, University Hospital Heidelberg
Im Neuenheimer Feld 110
69210 Heidelberg
Tel.: ++ 49/62 21/5 63 83 64
Fax: ++ 49/62 21/56 57 30
johanna.mayer@med.uni-heidelberg.de

Abstract

Purpose: Characterization and follow-up evaluation of chest CT of RSV pneumonia in immune-compromised adults during a seasonal epidemic.

Materials and Methods: Retrospective analysis of 132 chest CT examinations of 51 adult immune-compromised patients (29 m/22f, Ø58 years) with clinical signs of pneumonia and positive RSV test in winter 2011/2012. Two experienced chest radiologists evaluated the morphology (bronchial wall thickening, tree-in-bud, nodules, halo, ground-glass opacities, consolidations, pleural fluid) of the CT scans by consensus.

Results: Pathological findings were in 86 % of the chest CT scans: Areas of ground-glass attenuation in 64 %, consolidations in 56 %, nodules in 55 % (Ø 8 mm in maximal diameter, with halo in 71 %), pleural fluid in 44 % (Ø 2 cm), tree-in-bud in 36 %, bronchial wall thickening in 27 % and more than one morphological finding in 72 %. There were no pathological CT findings in 14 % of patients with clinical symptoms of pneumonia because these patients did not undergo follow-up. Radiological progression was found in 45 % of patients and regression in 33 % in follow-up examinations. In 37 % an additional examination of the paranasal sinuses was performed and showed sinusitis in 63 % of cases. 90 % of the patients had sinusitis as well as pneumonia. In addition to RSV, a further pathogenic agent was found in bronchoalveolar lavage of five patients (Aspergillus spec., herpes simplex virus, Pseudomonas aeruginosa). Conclusion: The most characteristic signs in chest CT scans were at the beginning of pneumonia with nodules and tree-in-bud often combined with bronchial wall thickening. The following CT scans showed characteristic but not pathognomonic chest CT findings of RSV pneumonia. These morphological findings should be recognized seasonally (winter) especially at the beginning of the case of pneumonia. RSV-associated additional sinusitis is probably common and should be noticed.

Key Points:
- The most characteristic signs in chest CT scans were at the beginning of RSV pneumonia with nodules and tree-in-bud; we suppose that the pneumonia is run through different CT morphological phases.
- The following CT scans showed less characteristic and multiple CT variations most frequently ground glass and nodules.
- Negative thoracic CT were seen only in a little part of RSV positive patients with symptoms of pneumonia.
- An additional RSV-associated sinusitis should be in mind.

Citation Format:
- Mayer JL, Lehners N, Egerer G et al. CT-Morphological Characterization of Respiratory Syncytial Virus (RSV) Pneumonia in Immune-Compromised Adults. Fortschr Röntgenstr 2014; 186: 686–692

Zusammenfassung

Ziel: Radiomorphologische Charakterisierung und Verlaufsbeurteilung der Thorax-CT-Befunde bei Ausbruch einer saisonalen Epidemie von RSV-Infektionen in einem immunsupprimierten Patientenkollektiv.

Material und Methoden: Retrospektive Analyse von 132 Thorax-CT-Untersuchungen bei 51 erwachsenen immunsupprimierten Patienten (29 m/22 w, Ø 58 Jahre) mit klinisch nachgewiesenem Infekt der Atemwege und positivem RSV-Nachweis im Winter 2011/2012. Musterbasierte Auswertung

(Bronchialwandverdickungen, tree-in-bud, Noduli, Halo, Milchglas, Konsolidierungen, Pleuraerguss) der radiologischen Bilder durch zwei erfahrene Thoraxradiologen im Konsens.

Ergebnisse: 86 % der CT-Untersuchungen wiesen einen relevanten Befund auf: 64 % milchglasartige Dichteanhebungen, 56 % Konsolidierungen, 55 % Noduli (Ø 8 mm, davon 71 % mit Halo), 44 % Pleuraerguss (Ø 2 cm), 36 % tree-in-bud, 27 % Bronchialwandverdickungen, 72 % mit mehreren morphologischen Veränderungen. Bei 14 % der Patienten mit klinischen Symptomen einer Pneumonie wurden keine relevanten morphologischen Veränderungen in der CT festgestellt. Im Verlauf kam es bei 45 % der Patienten zur radiologischen Progression (33 % Regression) in den Folgeuntersuchungen. Zusätzliche Untersuchungen der Nasennebenhöhlen (NNH) bei 37 % der Patienten erbrachten in 63 % eine Sinusitis, davon 90 % bei gleichzeitigem Vorliegen radiologischer Zeichen einer Pneumonie. Im Verlauf konnte bei fünf Patienten ein weiterer Keim in der BAL (Aspergillus spec., HSV [Herpes simplex virus], Pseudomonas aeruginosa) nachgewiesen werden.

Schlussfolgerung: Am charakteristischsten waren die Thorax-CTs zum mutmaßlichen Beginn der Erkrankung mit Noduli bzw. tree-in-bud häufig in Kombination mit Bronchialwandverdickungen. In den CTs bei zeitlich weiter fortgeschrittener Erkrankung finden sich auch noch, jedoch weniger charakteristische Lungenparenchymveränderungen. Diese RSV-Charakteristika, v. a. zum mutmaßlichen Beginn der Erkrankung, sollten gerade im Winter als verdächtig bewertet und ein Keimnachweis angestrebt werden. Bei positivem RSV Nachweis sollte zusätzlich an eine begleitende Sinusitis gedacht werden.

Introduction

An unusually high number of nosocomial as well as community-acquired respiratory syncytial virus (RSV) infections of the respiratory tract in adult patients particularly with a hematological or autoimmune primary disease was seen in the winter of 2011/2012 at a hematology and transplant center [1, 2]. RSV infection is known primarily as an inflammatory change of the lung in children. This pathogenic agent has been less frequently described as a community-acquired infection in adults. RSV pneumonia is more frequently seen in patients who have undergone stem cell transplantation and have a malignant hematological primary disease or in the case of immunosuppression [3 – 5]. Mild to moderate inflammation of the upper respiratory tract is typical in immunocompetent adults. However, in immunosuppressed or older patients with preexisting conditions, an RSV infection can result in severe pneumonia with a fatal outcome in some cases. Therefore, it is important for the radiologist to know the immune status of the patient being examined [6].

The RS virus is a pneumovirus and is part of the paramyxoviridae family. The mumps virus and parainfluenza virus also belong to the paramyxoviridae family. RSV is an enveloped virus with negative single-strand RNA. It can be differentiated into subtypes A and B. RSV is transmitted primarily via smear infection. It can live on surfaces for several hours and be incorporated by large drops or droplet infection. Therefore, hands should be disinfected and masks should be worn for primary prevention. Initial infection with RSV usually occurs in children. Due to incomplete immunity, reinfection often occurs but has a milder clinical course. The following clinical symptoms are seen in decreasing order of frequency: rhinorrhea, whistling respiratory sound, dyspnea, productive coughing, fever, and myalgia. RSV replicates in the ciliated epithelial cells of the mucous membranes of the respiratory tract. The infection can last from 6 days to 8 weeks. There are four established diagnostic procedures for detecting RSV including virus culture, antigen determination via immunofluorescence assay (IFA) or enzyme immunoassay (EIA), RNA determination via RT-PCR (real-time polymerase chain reaction) and serology. With 60 – 90 % PCR has the highest sensitivity. Adult patients are typically treated based on symptoms. A bacterial superinfection that complicates the course of the RSV infection occurs in 10 – 30 % of cases. It was shown in vitro that a superinfection in the case of an existing RSV infection is most frequently associated with Haemophilus influenzae and Streptococcus pneumoniae [7]. Ribavirin is a broad-spectrum antiviral medication with a controversial therapeutic effect. It is used in children and older patients. There is currently no approved RSV vaccine [6].

The CT-morphological signs of RSV pneumonia are not frequently described in the current literature and are often underdiagnosed or misinterpreted in the clinical routine, e. g. due to similar morphologies confused with fungal infections [8]. Fungal infections, primarily Aspergillus infections, are a complication with a potentially fatal outcome in patients with malignant hematological diseases or immunosuppression. Therefore, diagnosis (microbiology and primarily computed tomography) plays a major role in differentiation and treatment planning [9].

The goal of this analysis is to identify characteristic morphologies in chest CT in patients with RSV pneumonia in order to make CT-morphological diagnosis of RSV pneumonia more probable.

Materials and Methods

All patients of medical clinic V between November 2011 and July 2012 who tested RSV-positive and underwent a chest CT (median 1 day after [30 days before, 19 days after] a positive test) were included in the retrospective analysis approved by the ethics commission. The significant variability was the result of the fact that the epidemic (November 2011) was initially not recognized as such and thus serial RSV testing was not performed until December 2011. The first chest CT in each case was performed within the first 24 hours after the start of clinical symptoms. Samples were acquired via throat swab (n = 447), sputum (n = 7), tracheal secretion (n-14), or bronchoalveolar lavage (BAL) (n = 62) and examined via PCR [10]. The tests were thus performed in all patients several times with different sample materials and analysis techniques over the course of the disease. Bronchoalveolar lavage was performed in patients (n = 20) who had already undergone chest CT showing pronounced radiological changes.

The patients included in the study primarily had hematological and autoimmune primary diseases, e. g. multiple myeloma or acute myelocytic leukemia (**Table 1**).

The CT examinations of the thorax (n = 132) and in some cases also of the paranasal sinuses (n-19) were primarily performed using a 128-row iCT (Philips, Hamburg). In addi-

tion, individual chest examinations were performed using other devices (Somatom Definition Flash, Sensation 16, Volume Zoom and Definition AS40, Siemens Medizintechnik, Forchheim). The technique was usually native (n = 106/132, with a slice thickness of 3 – 5 mm (n = 124 with 3 mm, n = 5 with 4 mm, n = 3 with 5 mm) always in spiral technique during an inspiratory breath hold with dose modulation. The images were interpreted in consensus by two experienced chest radiologists on a PACS workstation (Synapse 3.2.1, Fujifilm, Düsseldorf) in accordance with DIN 6868 – 57 with two category A monitors using all of the usual image viewing techniques.

In the case of follow-up examinations, each examination was evaluated individually as well as in comparison to determine whether worsening or improvement could be detected. A visually noticeable increase in pathologies or the occurrence of new pathologies was evaluated as worsening of the findings. An improvement was defined as a visually detectable relevant decrease in pathologies.

To evaluate characteristic early signs of RSV pneumonia, the particular CT was evaluated at the presumable start of the disease. Even patients without a follow-up examination were included. A further inclusion criterion was a low number of pathologies (fewer than two at the same time). Exclusion criteria were more than two simultaneously present pathologies or large-area changes (> 25 % of the lung parenchyma).

A tabular schema based on the current literature was used for the qualitative and quantitative evaluation of the lung parenchyma [3]. Bronchial wall thickening, tree-in-bud, nodules, halo, ground-glass opacity, consolidations, and pleural effusions were evaluated with respect to their anatomical distribution (bi-/unilateral, basal/apical, central/peripheral, peribronchovascular/lobar/(non-)segmental/random) and if possible were quantified (longitudinal diameter and number (< 5, 5 – 10, > 10) of nodules, percentage estimation of the proportion of ground-glass opacity or consolidations in relation to the total lung parenchyma, ventrodorsal diameter of the pleural effusions).

Table 1 Primary diseases of the patients included in the evaluation (n = 51).

malignant primary disease	frequency
multiple myeloma	14
acute myelocytic leukemia (AML)	13
acute lymphatic leukemia (ALL)	3
diffuse large B-cell lymphoma (DLCBL)	3
B-non-Hodgkin lymphoma	2
chronic lymphatic leukemia (CLL)	2
myelodysplastic syndrome (MDS)	2
T-lymphoblastic leukemia (T-LBL)	2
chronic myelocytic leukemia (CML)	1
mantel cell lymphoma (MCL)	1
Hodgkin's disease	1
small lymphocytic leukemia (SLL)	1
T-non-Hodgkin lymphoma	1
autoimmune primary disease	
amyloidosis	2
scleroderma	1
vasculitis	1
other primary disease	
kidney transplant in diabetic nephropathy	1
total	51

The individual lung parenchymal changes were preferentially defined according to the criteria of the "Fleischner Society's glossary of terms" [11]: Nodules of up to 3 cm were included and classified as consolidations. An increase in the density of the lung parenchyma with still recognizable vascular structures was defined as a ground-glass change. Consolidations were then documented when increases in the lung parenchyma density did not have recognizable vascular structures. These were then additionally differentiated as respiratory tract consolidations and parenchyma consolidations.

In individual patients (19/51), the skull was examined via CT or MRI for neuroradiological purposes. These images were only used in the present analysis to evaluate the paranasal sinuses. Air-fluid levels in the individual paranasal sinuses were evaluated as acute sinusitis. If this was found in all sinuses, pansinusitis was diagnosed. Any osseous arrosion was noted.

Results

The main scan period of the patients in this evaluation was from December 2011 to March 2012. 51 patients with a positive RSV test were examined in a total of 132 chest CT examinations. 6 additional patients had a positive RSV test but only had minor clinical symptoms so that no radiological imaging was performed. Therefore, these 6 patients were not included in the present study. The average age was 58 years. 75 % of the patients were examined multiple times. A pathological lung finding in terms of the study evaluation was found in 86 % of the examined patients. As a result, 14 % of the patients had a normal finding in this regard despite clinical symptoms of pneumonia. 55 % of the patients required oxygen and 29 % required intensive care and ventilation. 27 % of the patients suffered an infection-associated death (**Table 2**).

14 % of the patients did not show any pathology on the chest CT scans despite clinical symptoms of pneumonia. 28 of the 132 CT scans were performed in these patients. All of these CT scans were reconstructed with a slice thickness of 3 mm. 4 of these patients underwent a single examination. Two patients underwent one follow-up examination and one patient underwent three follow-up examinations. The average age of these patients was also 58 years (from 24 to 76 years)

Table 2 Overview of basic data of all included patients.

basic data	patients: n = 51	chest CT scans: n = 132
female	43 % (22/51)	
male	57 % (29/51)	
age	Ø 58 [22 – 78]	
multiple examinations	75 % (38/51) [2 – 9 times]	
pathological finding	86 % (44/51)	79 % (104/132)
no pathological finding	14 % (7/51)	21 % (28/132)
multiple pathologies at the same time	80 % (41/51)	72 % (95/132)
requiring oxygen	55 % (28/51)	
intensive care and ventilation	29 % (15/51)	
infection-associated death	27 % (14/51)	
germ detected in addition to RSV	10 % (5/51)	

and the primary diseases also varied. All of these CT scans did not show any pathological change, also not over the course of the disease, i. e., these patients were RSV-positive and had clinical symptoms of pneumonia but lung parenchymal changes were not seen over the entire period.

In general, the following pathological CT changes were seen in descending order of frequency: ground-glass opacity (95 % bilateral, average 18 % of the lung parenchyma), consolidations (average 11 % of the lung parenchyma, 23 % with positive bronchoaerogram), nodules, tree-in-bud, bronchial wall thickening (▶ **Table 3**). These pathologies were associated with pleural effusions (average 2 cm) in 63 % of the patients. Nodules with an average maximum diameter of 8 mm (from 3 to 25 mm) typically occurred in high numbers (14 %, < 5, 13 % 5 – 10, 74 % > 10 nodules) and in a centrilobular position (58 %) (often also random (29 %)) and had a halo in 81 % of the patients (▶ **Table 3**, ▶ **Fig. 1**).

Table 3 Pathological CT changes.

pathological CT change	patients: n = 51	chest CT scans: n = 132
bronchial wall thickening	37 % (19/51)	27 % (35/132)
tree-in-bud	51 % (26/51)	36 % (47/132)
nodules	61 % (31/51)	55 % (72/132)
halo around nodules	81 % (25/31)	71 % (51/72)
ground-glass opacity	76 % (39/51)	64 % (85/132)
consolidations	71 % (36/51)	56 % (74/132)
pleural effusion	63 % (32/51)	44 % (58/132)

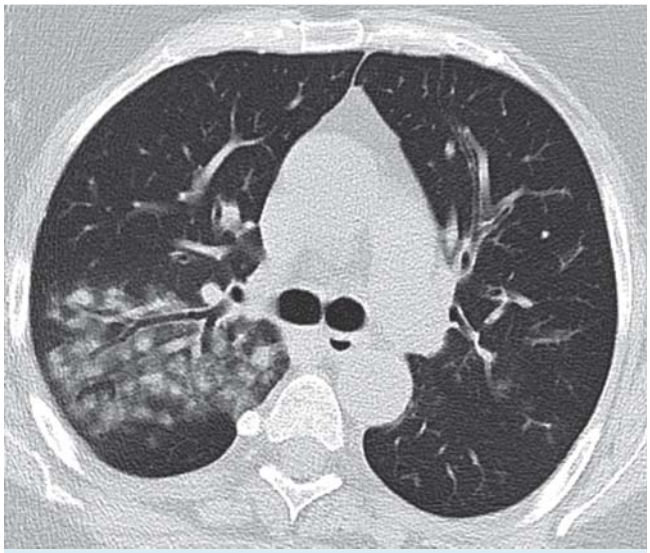

Fig. 1 This CT image of a 45-year-old female patient with ALL was acquired on the same day as the positive RSV test. A few centrilobular nodules in segment 2 of the right upper lobe of the lung surrounded by ground glass. This pattern was often seen. 6 days before and 14 days after this CT scan, there was no pathological result in the CT examinations.

Multiple radiomorphological lung parenchymal changes with the following distribution in the lung parenchyma in descending order were detected in 72 % of all CT examinations: 30 % random, 22 % segmental, 22 % basal, 12 % apical, and 12 % lobar. In addition to the positive RSV test, HSV (herpes simplex virus) was found in BAL in two cases and HSV as well as Aspergillus spec. in an additional two cases. Pseudomonas aeruginosa was found in BAL immediately prior to death in one case. Thus, a second pathogenic agent was found in 5/51 (10 %) patients.

Two or more CT examinations were performed in the course of the disease in 38/51 (75 %) patients, thus making it possible to evaluate the radiomorphological development of the RSV pneumonia in a relevant patient collective. The median time between the first and second follow-up examination was 11 days. With 79 % (30/38) ground-glass opacity was the most common pathological sign on the first CT scan of patients with later follow-up examinations (▶ **Fig. 2**). With 61 %, nodules were the second most common pathological sign (▶ **Fig. 3**). With 87 % nodules were the most frequent pathological sign in the first follow-up examination and with 65 % ground-glass opacity was the second.

To evaluate the characteristic early changes of RSV pneumonia, the relevant CT scan was assessed at the presumed start of the disease. However, as already described above, the positive RSV test varied with respect to time since the epidemic was not initially recognized as such.

34/51 (67 %) patients were evaluated in this regard. Nodules were found in 53 % (18/34) of patients, bronchial wall thickness in 41 % (14/34), tree-in-bud pattern in 32 % (11/34), pleural effusions in 21 % (7/34), ground-glass opacity only in 3 % (1/34) and consolidations in no patients. It is noteworthy that bronchial wall thickening occurred in combination with nodules or the tree-in-bud pattern in 79 % (11/14) of the cases. An exemplary but very typical image is shown in ▶ **Fig. 1**.

The median time between CT examinations with progression of the findings was 7 days and 22 days in the case of regression of the findings. A radiological increase in findings was diagnosed in 45 % of patients (▶ **Fig. 3b-d**), regression in 33 % (▶ **Fig. 3e**) and no significant change in the findings in the remaining 22 % in the follow-up examinations. The ground-glass opacity increased by 21 % and the consolidations by

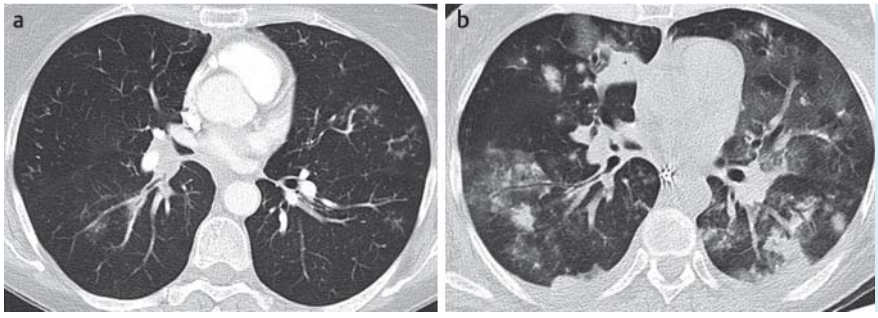

Fig. 2 There are discrete centrilobular nodular changes with ground glass in the lower lobes and the lingular segment of the lung in a 58-year-old woman with a positive RSV test and B cell lymphoma (a). The proportion of ground glass and nodules with halo increased and new consolidations were seen 14 days later (b). Exitus letalis on day 17.

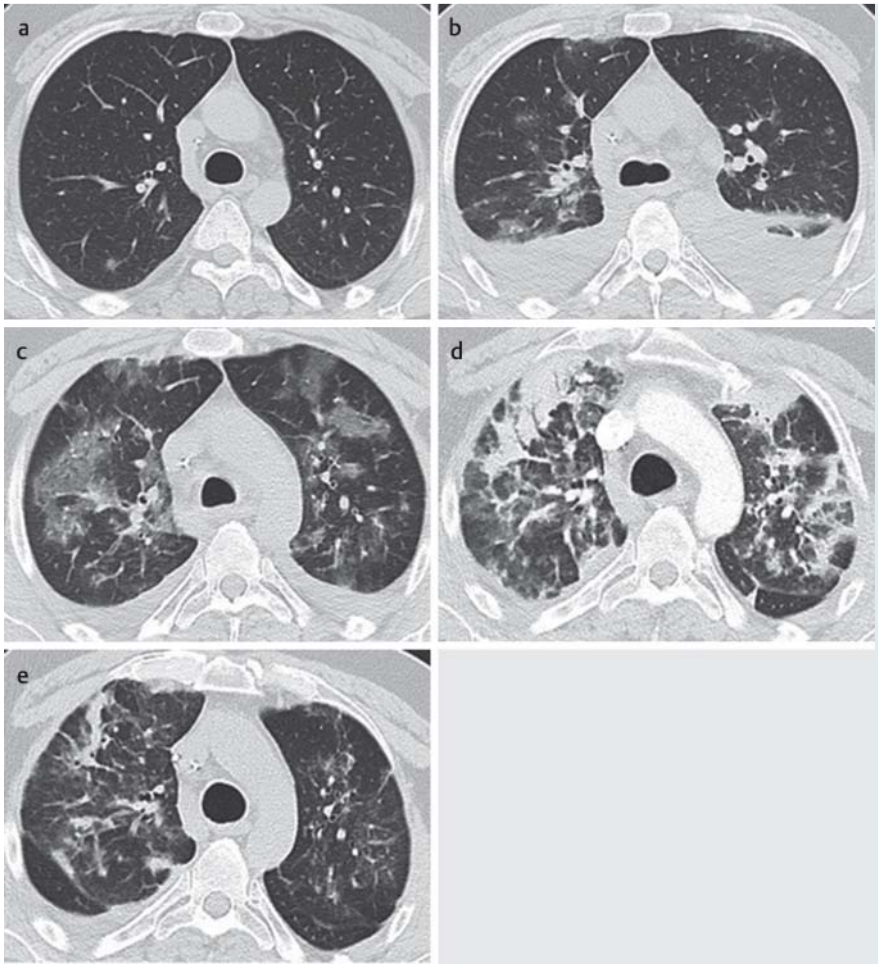

Fig. 3 CT examinations of a 42-year-old male aplastic patient with ALL. Only one small nodule in segment 2 of the right upper lobe was seen in CT on the day of the positive RSV test **a**. There were new pleural fluids and bipulmonary ground glass nine days after the previous CT **b**. The pleural fluids decreased but the ground glass increased on day 15 after a positive RSV test **c**. The next CT scan on day 25 showed new bipulmonary consolidations with a positive air bronchogram as a sign of organizing pneumonia **d**. At the same time the ground glass and pleural fluids decreased **d**. The last examination on day 38 showed recurrent consolidations **e**. Hematologic reconstitution began on day 15 and advanced until the last day of CT examination.

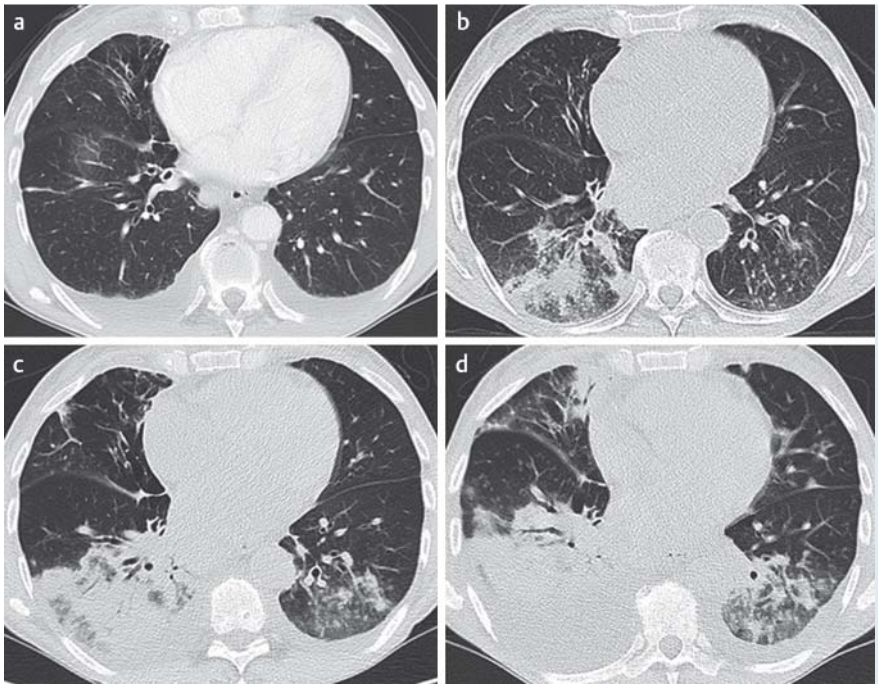

Fig. 4 67-year-old female patient with CLL and a positive RSV test. There were pleural fluids and only a few bronchial wall thickenings in the bronchi of the middle and the right lower lobe **a**. Bronchial wall thickening increased and was seen bipulmonary 10 days later **b**. Furthermore, there were new centrilobular nodules in both lower lobes and consolidations in the right lower lobe **b**. Consolidations in the right lower lobe increased and showed a positive air bronchogram 14 days later as a sign of organizing pneumonia. There was also progress of the ground glass and centrilobular nodules in the left lower lobe **c**. These findings increased on day 20 again. Exitus letalis on day 28.

12 % in the examinations with progression of the findings. New nodules and the tree-in-bud pattern occurred in 22 % of the cases (▶ **Fig. 4**).

The paranasal sinuses were evaluated via CT or MRI in 37 % (19/51) of the patients. In 63 % (12/19) of these examinations, air-fluid levels and thus sinusitis were able to be diagnosed.

All paranasal sinuses were affected in 26% (5/19) of the cases, i.e. pansinusitis was diagnosed. In addition to these findings, further intracranial pathologies (otitis media (2 cases), mastoiditis (4 cases), subdural hematoma (3 cases), subdural hygroma (1 case)) were found in 42% (8/19) of the patients but no osseous arrosions were found. 90% (11/12) of the patients with sinusitis or pansinusitis also had pneumonic lung infiltrates and 50% (6/12) required ventilation.

Discussion

The seasonal occurrence of RSV infections is known and is also reflected in the main scan period of the patients in this analysis [3, 5]. Compared to other studies, this study is the first to address the CT-morphological changes of RSV pneumonias over the course of the disease and to additionally analyze its association with sinusitis. 51 patients and 132 chest CT examinations were included.

In these CT examinations ground-glass opacity was found most frequently with a rate of 64%, followed by consolidations with 56%, and nodules with 50% (in 74% >10). The most common pathological morphologies in patients with a follow-up examination were ground-glass opacity and nodules (primarily centrilobular) in this order of frequency. This was reversed in the first follow-up examination and nodules were seen more frequently than ground-glass opacity. The other detected pathologies were rarer. The clinical spectrum ranged from mild clinical infection constellation to intensive care with organ failure [12].

The above range of pulmonary changes as seen for example in H3N2 influenza infections generally supports the diagnosis of viral pneumonia. However, the occurrence of multiple pulmonary changes is only suggestive but not specific for viral pneumonia as in H3N2, for example [13]. Other studies that have addressed CT changes in immunosuppressed patients with RSV pneumonia obtained similar results:

The three most common pathological signs in descending order of frequency according to Franquet et al. were ground-glass opacity, nodules, and bronchial wall thickening. Of 130 patients who underwent hematopoietic stem cell transplantation, BAL, and chest CT, 26 patients with proven RSV pneumonia were included in this retrospective evaluation [3].

In a study by Gasparetto et al., 20 bone marrow transplant patients with nosocomial RSV pneumonia underwent CT examination within 24 hours of the start of symptoms. RSV was diagnosed via BAL, nasopharyngeal swab, or nasal lavage. Nodules, consolidations, and ground-glass opacity were found in this order of frequency [4].

Escuissato et al. included 111 bone marrow transplant recipients from a cohort of 774 patients who underwent chest CT within 24 hours of the start of symptoms. All of these patients had symptoms of pneumonia. However, RSV pneumonia was verified in only 30 patients. Primarily nodules, consolidations, and ground-glass opacity were found in patients with RSV pneumonia in this study [14].

Miller et. al [15] who retrospectively examined the CT-morphological characteristics of 115 community-acquired bacterial and viral (19 RSV) infections of the lower respiratory tract found the tree-in-bud pattern and bronchial wall thickening most frequently in association with RSV.

It should be mentioned that there were only a limited number of RSV-positive patients with no pathological changes in the CT examinations despite symptoms of pneumonia. In contrast, the percentage of such cases was 14% in the study by Ko et al. [16] and in the present study and 20% in the studies by Escuissato et al. [14] and Gasparetto et al. [4]. All negative CT scans in the present study were reconstructed with a slice thickness of 3 mm. It is therefore not assumed that significant findings were overlooked but rather that these CT scans in fact did not show any pathologies.

In light of the fact that nodules were the second most frequent finding with a rate of 50% in this analysis and 70% of these had a halo, it is useful to point out that this halo is a non-specific morphological change that can be caused by a hemorrhage or local infiltration. However, the halo sign is often found in association with a pulmonary fungal infection [11, 17].

Fungal infections, primarily Aspergillus infections, are a complication with a potentially fatal outcome in patients with malignant hematological diseases or immunosuppression. Therefore, diagnosis (microbiology, computed tomography) plays a major role in differentiation and treatment planning [9].

The current evaluation analyzes both the morphological criteria in each CT scan and the course of the disease with respect to progression or regression. The following parameters were taken into consideration: which change could be detected from the beginning, which new parenchymal patterns occurred, what was the extent of any new parenchymal patterns. The current literature includes a study by Ko et al. [16] who also used CT to examine the course of RSV pneumonias. The collective of 7 patients in this study included lung transplant recipients. However, the follow-up evaluation only relates to progression, regression, and stabilization. Concrete morphological changes are not described.

It can be assumed that the course of RSV pneumonia includes different visible morphological stages. The most characteristic is the initial stage since many different parenchymal changes occur at the same time in the advanced stages. Nodules which are often seen in combination with bronchial wall thickening occur in the greatest numbers and have the most characteristic morphological appearance. The paranasal sinuses were also evaluated in 19 of the 51 analyzed patients (37%) with a positive RSV test. Acute sinusitis or pansinusitis was diagnosed in 63% of the patients and 90% of these had clinical and radiological pneumonia.

In viral rhinosinusitis, there is increased production of viscous material in the sinus that accumulates there since the regular removal process is impaired by disrupted and reduced cilia functionality [18]. This can facilitate a bacterial superinfection [18]. In addition, RSV plays different roles in the pathogenesis of the infection from colonization and incidental co-infection, which acts as the precursor to other pathogens, to possible major pathogens [19–21]. RSV-associated sinusitis or pansinusitis is rarely described in the current literature [22, 23]. New literature addressing both the CT-morphological changes of RSV pneumonia and the presence of sinusitis also cannot be found. RSV sinusitis presumably arises from RSV pneumonia. Therefore, it would be useful to test the upper respiratory tract separately from the lower tract during pathogen diagnosis in order to be able to prove this in possible further studies.

This study has the following limitations:
Firstly, it is a retrospective, descriptive analysis whose observed incidence was presumably increased during RSV screening and mild clinical processes that would not have been tested for RSV in a targeted manner under different circumstances were monitored. This allowed a broader radiological characterization of RSV pneumonia.
Secondly, only chest CT scans with a slice thickness of 3–5 mm were available for the evaluation. 1-mm slices were not available. It is possible that minor pathologies, such as ground-glass opacities, may not have been correctly evaluated or detected on the few CT scans with a slice thickness of 4 mm or 5 mm (n = 9).
Thirdly, a superinfection was detected via BAL in 5/51 patients. However, not every patient underwent BAL and not every pathogenic agent detected via BAL causes pneumonia but in some cases only colonization without a pathogenic effect [20, 24, 25]. For example, an RSV infection of the respiratory tract was detected in a prospective study including 165 children on ventilation (median age 1.6 months old), 22 % of whom had a verified bacterial co-infection and another 21 % had a possible bacterial co-infection [19].
Fourthly, no special or systematic examination of the paranasal sinuses (e. g. nasopharyngeal lavage, nasal swab) was performed in patients with sinusitis since this issue was not the focus of the head examinations [23].

Conclusion

This analysis of chest CT scans shows that ground-glass opacity, consolidations, and nodules with a halo were seen in cases of RSV pneumonia. Ground-glass opacity was primarily seen in the initial stage, while centrilobular nodules were seen in the advanced stages. In most cases, multiple pathological changes that developed primarily due to worsening of the symptoms were present at the same time. However, the chest CT scans acquired at the presumed start of the disease with nodules or tree-in-bud often in combination with bronchial wall thickening were most characteristic.
Although these are not pathognomic lung parenchymal changes, they are characteristic so that RSV-associated pneumonia should be considered with greater frequency on a seasonal basis (winter months) and associated sinusitis should also be taken into consideration.

Relevance of the study

1. Characterization of pneumonia to identify indicators of possible triggers
2. Targeted use of suitable screening tests for pathogen identification
3. Early detection of RSV pneumonia for early treatment planning primarily in immunosuppressed patients
4. Prevention of unnecessarily broad and long-lasting empiric antibiotic regimens to lower costs, toxicity, and resistance development

References

1 *Lehners N, Schnitzler P, Geis S et al.* Risk factors and containment of respiratory syncytial virus outbreak in a hematology and transplant unit. Bone Marrow Transplant 2013; DOI: 10.1038/bmt.2013.94 [Epub ahead of print]
2 *Geis S, Prifert C, Weissbrich B et al.* Molecular characterization of a respiratory syncytial virus outbreak in a hematology unit in Heidelberg, Germany. J Clin Microbiol 2013; 51: 155–162
3 *Franquet T, Rodriguez S, Martino R et al.* Thin-section CT findings in hematopoietic stem cell transplantation recipients with respiratory virus pneumonia. Am J Roentgenol 2006; 187: 1085–1090
4 *Gasparetto EL, Escuissato DL, Marchiori E et al.* High-resolution CT findings of 3 respiratory syncytial virus pneumonie after bone marrow transplantation. Am J Roentgenol 2004; 182: 1133–1137
5 *Anaissie EJ, Mahfouz TH, Aslan T.* The natural history of respiratory syncytial virus infection in cancer and transplant patients: implications for management. Blood 2004; 103: 1611–1617
6 *Falsey AR.* Respiratory syncytial virus infection in adults. Semin Respir Crit Care Med 2007; 28: 171–181
7 *Avadhanula V, Wang Y, Portner A et al.* Nontypeable Haemophilus influenzae and Streptococcus pneumoniae bind respiratory syncytial virus glycoprotein. J Med Microbiol 2007; 56: 1133–1137
8 *Shiley KT, Van Deerlin VM, Miller WT.* Chest CT features of community-acquired respiratory viral infections in adult inpatients with lower respiratory tract infections. J Thorac Imaging 2010; 25: 68–75
9 *Scheer F, Kuithan F, Wiggermann P.* Fatal outcome of invasive tracheal aspergillosis. Fortschr Röntgenstr 2011; 183: 480–482 [Article in German]
10 *Hettwer S, Wilhelm J, Schürmann M et al.* Microbial diagnostics in patients with presumed severe infection in the emergency department. Med Klin Intensivmed Notfmed 2012; 107: 53–62
11 *Hansell DM, Bankier AA, MacMahon H.* Fleischner Society: glossary of terms for thoracic imaging. Radiology 2008; 246: 697–722
12 *Fox H, Seeger FH, Schmitt J et al.* Veno-arterial ECMO as bridge to recovery. Cardiogenic shock and suspected myocarditis in a 37-year-old patient. Med Klin Intensivmed Notfmed 2012; 107: 206–212 [Article in German]
13 *Betz M, Beck R, Hetzel J et al.* Imaging findings in H3N2-related pulmonary infection. Fortschr Röntgenschr 2012; 184: 863–864 [Article in German]
14 *Escuissato DL, Gasparetto EL, Marchiori E.* Pulmonary infections after bone marrow transplantation: high-resolution CT findings in 111 patients. Am J Roentgenol 2005; 185: 608–615
15 *Miller WT, Mickus TJ, Barbosa E.* CT of viral lower respiratory tract infections in adults: comparison among viral organisms and between viral and bacterial infections. Am J Roentgenol 2011; 197: 1088–1095
16 *Ko JP, Shepard JA, Sproule MW.* CT manifestations of respiratory syncytial virus infection in lung transplant recipients. J Comput Assist Tomogr 2000; 24: 235–241
17 *Tanaka N, Kunihiro Y, Yujiri T et al.* High-resolution computed tomography of chest complications in patients treated with hematopoietic stem cell transplantation. Jpn J Radiol 2011; 29: 229–235
18 *Osur SL.* Viral respiratory infections in association with asthma and sinusitis: a review. Ann Allergy Asthma Immunol 2002; 89: 553–560
19 *Thorburn K, Harigopal S, Reddy V et al.* High incidence of pulmonary bacterial co-infection in children with severe respiratory syncytial virus (RSV) bronchiolitis. Thorax 2006; 61: 611–615
20 *Hament JM, Aerts PC, Fleer A et al.* Enhanced adherence of Streptococcus pneumoniae to human epithelial cells infected with respiratory syncytial virus. Pediatr Res 2004; 55: 972–978
21 *Randolph AG, Reder L, Englund JA.* Risk of bacterial infection in previously healthy respiratory syncytial virus-infected young children admitted to the intensive care unit. Pediatr Infect Dis J 2004; 23: 990–994
22 *Louie JK, Hacker JK, Gonzales R.* Characterization of viral agents causing acute respiratory infection in a San Francisco University Medical Center Clinic during the influenza season. Clin Infect Dis 2005; 41: 822–828
23 *Silva AR, Park M, Vilas BoasLS.* Respiratory syncytial virus rhinosinusitis in intensive care unit patients. Braz J Infect Dis 2007; 11: 163–165
24 *Mühlethaler K, Bögli-Stuber K, Wasmer S.* Quantitative PCR to diagnose Pneumocystis pneumonia in immunocompromised non-HIV patients. Eur Respir J 2012; 39: 971–978
25 *Angrill J, Agustí C, de Celis R.* Bacterial colonisation in patients with bronchiectasis: microbiological pattern and risk factors. Thorax 2002; 57: 15–19