

Hemospray for arterial hemorrhage following endoscopic ultrasound-guided pseudocyst drainage

An 80-year-old man with alcoholic liver cirrhosis and obstructed jaundice due to a large pancreatic pseudocyst was referred for endoscopic ultrasound (EUS)-guided cystogastrostomy. A computed tomography scan of the abdomen confirmed a 20-cm pancreatic pseudocyst, which was compressing the stomach and biliary tree, as well as a moderate amount of ascites and portal thrombosis with signs of portal hypertension [1]. The platelet count was 70 000/mm³. EUS confirmed the large pseudocyst adhering to the stomach wall. Cystogastrostomy was performed, and a double pigtail catheter (10Fr, 10 cm) was placed across the gastrocystic fistula.

After 10 hours, the patient complained of severe hematemesis with a significant drop in hemoglobin. Emergency endoscopy revealed a large amount of blood and clots in the gastric fundus, with active bleeding from a vessel in the margin of the gastric fistula (● Fig. 1). The catheter was not visualized and the fistula appeared to be closed. Adrenalin and fibrin glue were injected with an apparent cessation of bleeding; however, 4 hours later, the patient experienced two episodes of hematemesis of large amount of fresh blood. A second endoscopy was performed and confirmed the active bleeding. A decision was made to apply Hemospray (Cook Medical, Winston Salem, North Carolina, USA), which resulted in immediate hemostasis (● Fig. 2 and ● Fig. 3, ● Video 1). The patient recovered well and no further episodes of bleeding occurred.

Hemospray acts by forming a barrier over the bleeding site and increasing local concentration of clotting factors [1]. Its efficacy has been shown in peptic ulcer bleeding [2], in cancer-related gastrointestinal bleeding, and in patients undergoing antithrombotic therapy [3,4]. These initial reports are very promising in terms of in-

itial hemostasis and rates of rebleeding, but are limited by the small number of published cases.

In the present case, Hemospray was used for very severe bleeding after cystogastrostomy in a patient with liver cirrhosis and portal hypertension, and the need for additional endoscopic or radiologic treatments was obviated simply by spraying the material onto the bleeding vessel.

Endoscopy_UCTN_Code_TTT_1AO_2AN

Competing interests: None

Ilaria Tarantino, Luca Barresi, Antonino Granata, Gabriele Curcio, Mario Traina

Department of Gastroenterology,
IsMeTT/UPMC, Palermo, Italy

References

- 1 Holster IL, De Maat MP, Ducharme R et al. In vitro examination of the effects of the hemostatic powder (hemospray) on coagulation and thrombus formation in humans. *Gastrointest Endosc* 2012; 75: AB240
- 2 Ung JJY, Luo D. Early clinical experience of the safety and effectiveness of Hemospray in achieving hemostasis in patients with acute peptic ulcer bleeding. *Endoscopy* 2011; 43: 291–295
- 3 Weusten B, Bergman JJ. A hemostatic spray: the easy way out for upper gastrointestinal bleeding? *Endoscopy* 2011; 43: 343–344
- 4 Holster IL, Kuipers EJ. Hemospray in the treatment of upper gastrointestinal hemorrhage in patients on antithrombotic therapy. *Endoscopy* 2013; 45: 63–66

Bibliography

DOI <http://dx.doi.org/10.1055/s-0033-1359164>
Endoscopy 2014; 46: E71
© Georg Thieme Verlag KG
Stuttgart · New York
ISSN 0013-726X

Corresponding author

Ilaria Tarantino
Department of Gastroenterology
IsMeTT/UPMC
via trcomi Palermo 90100
Italy
Fax: +39-091-6665340
itarantino@ismett.edu

Video 1

Active bleeding from a vessel in the margin of the gastric fistula was treated by application of Hemospray, which resulted in immediate hemostasis.

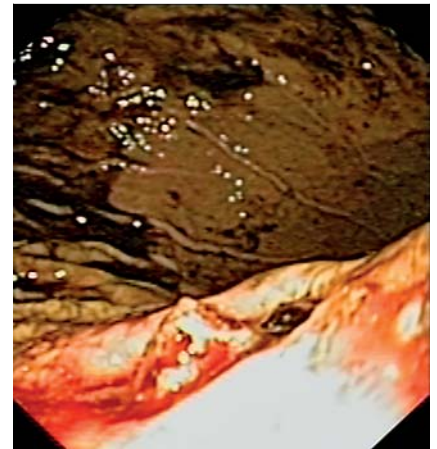


Fig. 1 Active bleeding from a vessel in the margin of the gastric fistula.

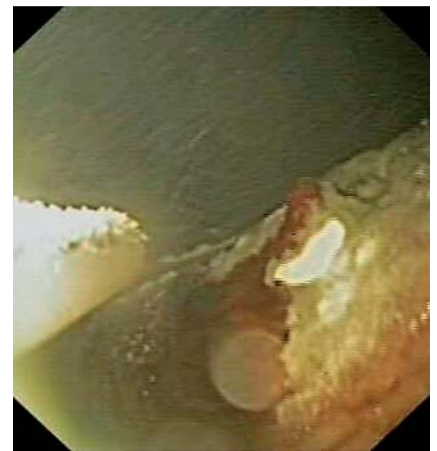

Fig. 2 Endoscopic treatment with Hemospray.

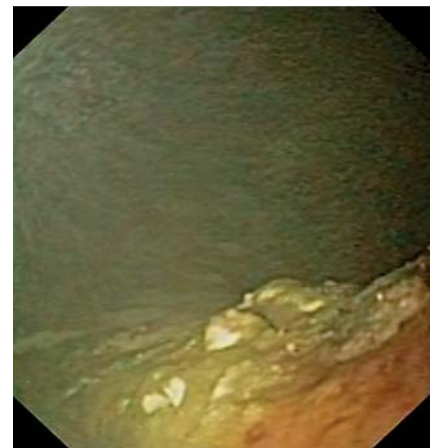


Fig. 3 Immediate hemostasis after Hemospray treatment.