

Untying the knot: technique of unraveling a guidewire knot created during EUS-guided biliary drainage

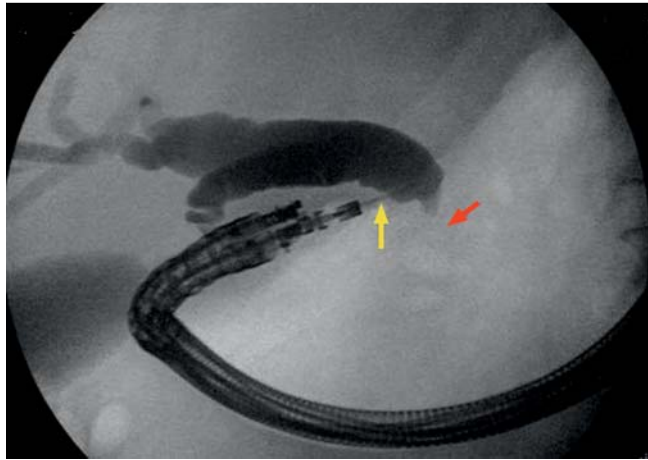


Fig. 1 A 19-gauge needle (yellow arrow) is used to puncture the bile duct and inject contrast. Cholangiogram reveals a dilated proximal bile duct and tight distal common bile duct stricture (red arrow).

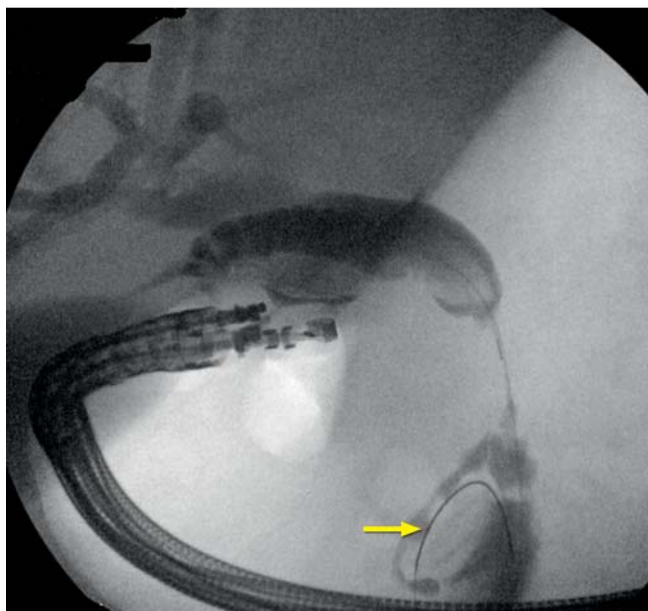


Fig. 2 The wire is passed through the stricture in an antegrade fashion and coiled in the duodenum (arrow).

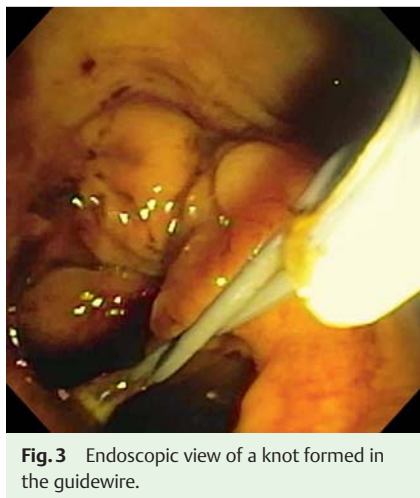

Fig. 3 Endoscopic view of a knot formed in the guidewire.

Inadvertent knotting of guidewires and catheters has been reported in several procedures, including cardiac catheterization [1], central venous access [2], and urologic procedures [3]. However, there are no reports of guidewire knotting during endoscopic procedures. We describe successful untangling of a knot created in a guidewire during endoscopic ultrasound (EUS)-guided rendezvous biliary drainage.

A 70-year-old man with biliary obstruction due to a 4-cm head of pancreas adenocarcinoma presented for endoscopic retrograde cholangiopancreatography (ERCP)

and biliary stent placement. Two attempts at ERCP were performed; however, biliary access could not be obtained due to a tight distal biliary stricture. As previously described [4], the patient underwent EUS-guided biliary drainage. The tip of the linear echoendoscope (UC140P-AL5; Olympus America, Center Valley, PA, USA) was positioned in the duodenal bulb. A segment of dilated bile duct proximal to the site of obstruction was punctured with a 19-gauge fine-needle aspiration needle (Expect 19 Flex; Boston Scientific, Natick, MA, USA). Contrast injection and fluoroscopic imaging confirmed a dilated proximal common biliary tree with a tight distal common bile duct stricture (● Fig. 1). A 0.025-inch guidewire (VisiGlide; Olympus) was passed through the needle. Antegrade guidewire passage through the site of obstruction and across the papilla was achieved (● Fig. 2). The wire was coiled within the duodenum. The echoendoscope was withdrawn and the transduodenal portion of the wire was held by an assistant. A side-viewing duodenoscope was passed to the papilla and a forceps was used to grasp the papillary portion of the guidewire. As the wire was withdrawn through the endoscope, it slipped and could not be fully withdrawn into the endoscope channel. The elevator was used to hold the wire while the endoscope (and wire) were withdrawn from the patient. Both ends of the wire were now held by an assistant. The papillary portion of the wire was back-loaded through a sphincterotome that was already advanced through the working channel of the duodenoscope. As the endoscope was advanced, tension was applied to the wire. However, resistance was met as the sphincterotome was advanced. The endoscope was advanced into the duodenum. A knot had formed within the wire (● Fig. 3, ● Fig. 4). The sphincterotome was withdrawn and a ratcheted forceps was used to grip one portion of the wire. The forceps and endoscope were withdrawn out of the patient while the wire was allowed to slip through the teeth of the forceps and the knot was untangled (● Videos 1, 2). The procedure was completed by cannulating the bile duct with a sphincterotome over the wire and placing a 10 mm × 60 mm fully covered self-expandable metallic biliary stent. Guidewire knotting can occur during rendezvous procedures if the wire forms a loop during endoscope or catheter exchanges, as occurred in this case. To prevent looping, it is important to main-

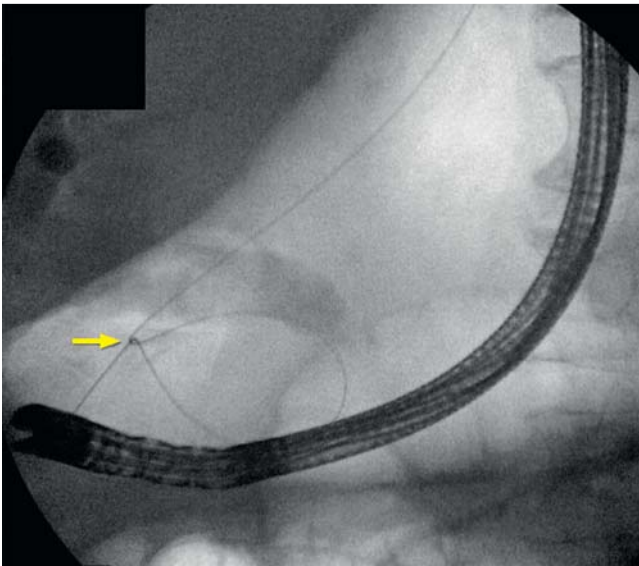


Fig. 4 Fluoroscopic image of knot formed in the guidewire (yellow arrow).

Payal Saxena, Gerard Aguila, Vivek Kumbhari, Mouen A. Khashab

Department of Medicine and Division of Gastroenterology and Hepatology, The Johns Hopkins Medical Institutions, Baltimore, Maryland, USA

References

- 1 Gupta PN, Praveen GK, Ahmed SZ et al. Knots in the cath lab, an embarrassing complication of radial angiography. *Heart Asia* 2013; 5: 36–38
- 2 Lee JJ, Kim JS, Jeong WS et al. A complication of subclavian venous catheterization: extravascular kinking, knotting, and entrapment of the guidewire: a case report. *Korean J Anesthesiol* 2010; 58: 296–298
- 3 Sambrook AJ, Todd A. Untangling of knotted urethral catheters. *Pediatr Radiol* 2007; 37: 380–383
- 4 Khashab MA, Valeshabad AK, Modayil R et al. EUS-guided biliary drainage by using a standardized approach for malignant biliary obstruction: rendezvous versus direct transluminal techniques (with videos). *Gastrointest Endosc* 2013; 78: 734–741

Bibliography

DOI <http://dx.doi.org/10.1055/s-0033-1359240>
Endoscopy 2014; 46: E140–E141
 © Georg Thieme Verlag KG
 Stuttgart · New York
 ISSN 0013-726X

Corresponding author

Mouen A. Khashab, MD
 Johns Hopkins Hospital
 1800 Orleans St, Suite 7125B
 Baltimore
 MD 21205
 USA
 Phone: +1-443-287-1960
 mkhasha1@jhmi.edu

Video 1

A segment of dilated common bile duct (CBD) was identified on endoscopic ultrasonography and was punctured with a 19-gauge needle to obtain a cholangiogram. A distal CBD stricture was identified and a wire advanced across the stricture and into the distal duodenum in an antegrade fashion. The echoendoscope was withdrawn and a side-viewing duodenoscope passed to grasp the wire at the papilla. The duodenoscope and wire were then withdrawn out of the patient.

Video 2

The wire was back-loaded into the side-viewing duodenoscope, which was preloaded with a sphincterotome. Resistance was encountered as the sphincterotome was advanced over the wire. A knot was apparent within the wire. The duodenoscope was withdrawn and a gastro-scope used to pass a rat-toothed forceps, which was used to loosely grasp the wire at the level of the papilla. The wire was allowed to slip through the forceps as the gastroscope was withdrawn, allowing untangling of the knot. The endoscopic retrograde cholangiopancreatography was completed with placement of a self-expandable metallic biliary stent.

tain constant tension on the wire during all exchanges. Knots and tangling of the guidewire become apparent when a catheter meets resistance as it is advanced over the wire. Fluoroscopy can confirm the problem, which can be solved using the technique described.

Endoscopy_UCTN_Code_TTT_1AS_2AG

Competing interests: Payal Saxena has received consulting fees from Boston Scientific and research support from Cook Medical.

Mouen A. Khashab is a consultant for Boston Scientific and Olympus and has received research support from Cook Medical.