

Spreader Graft in Closed Rhinoplasty: The “Rail Spreader”

Alberto Scattolin, MD¹ Niana Orlando, MD¹ Luca D’Ascanio, MD²

¹Department of Otolaryngology, Villa Donatello Clinic, Piazzale Donatello, Florence, Italy

²Department of Otolaryngology-Head and Neck Surgery, “Carlo Poma” Civil Hospital, Mantova, Italy

Address for correspondence Luca D’Ascanio, MD, Department of Otolaryngology-Head and Neck Surgery, “Carlo Poma” Civil Hospital, Mantova, Italy (e-mail: l.dascanio@gmail.com).

Facial Plast Surg 2013;29:515–519.

Abstract

Spreader grafts (SGs) have been widely used for both aesthetic and functional reasons to prevent middle vault collapse and treat internal nasal valve insufficiency. Although SG precise fixation can be easily achieved in open rhinoplasty, the difficulties of SG placement in closed rhinoplasties can be discouraging. In the present report, we describe a new custom-made SG (called “rail spreader”) and the personal easy method of application of such graft in “endonasal” rhinoplasty. The technical details and results are reported along with the advantages of our technique over previously described approaches.

Keywords

- ▶ spreader graft
- ▶ closed rhinoplasty
- ▶ rail spreader
- ▶ surgical technique

Spreader grafts (SGs) have been widely used for both aesthetic and functional reasons to prevent middle vault collapse and treat internal nasal valve insufficiency. The rationale of their use is represented by SG ability to push the upper lateral cartilages in the lateral direction, thus increasing the cross-sectional area of the internal nasal valve and support the nasal dorsum. As originally described by Sheen,¹ SGs are placed into submucous tunnels on either side of the dorsal septal cartilage. The main problem with the use of SG is their precise fixation to the dorsal septal border. This can be easily achieved in open rhinoplasty, while in endonasal rhinoplasties, the difficulties in their fixation can be discouraging.^{2–4}

In the present report, we describe a new custom-made SG (the “rail spreader” [RS]) and the personal easy method of application of such graft in “endonasal” rhinoplasty. The technical details and results are reported along with the advantages of our technique over previously described approaches. This study was approved by the institutional review board of “Villa Donatello” Clinic.

Materials and Methods

Sample

Between 2007 and 2011, we submitted 49 Caucasian patients (29 male, 20 female; mean age, 27.8 years; age range, 18–57

years) to “closed” approach rhinoplasty with endonasal placement of our custom-made SG (named “RS”) for the correction of functionally incompetent internal nasal valve or aesthetic deformities of the nasal pyramid, such as “inverted-V,” saddle, or crooked nose.

All patients complained of nasal breathing obstruction due, in part at least, to an incompetent internal nasal valve. This was demonstrated by improvement in nasal patency with the use of a modified Cottle test in which an instrument with a diameter of 2 mm, such as a cotton gauze holder, was placed in the internal nasal valve, mimicking the desired postoperative situation.⁵

From an aesthetic viewpoint, 7 subjects presented a saddle nose, 13 an “inverted-V” deformity, and 21 a crooked nose. Patients’ selection was performed with careful history and complete otorhinolaryngological examination, rigid endoscopy, and computed tomographic scanning of the nasal passages. Thirty-four patients had previously undergone nasal surgery. Among those patients, 7 had had previous septoplasty, 4 inferior turbinate reduction, 2 ethmoid surgery, and 12 rhinoplasty; 9 had undergone more than one previous operation.

Of the 49 patients we submitted to rhinoplasty, 45 underwent concomitant septum correction. In cases in which the only septal work consisted of cartilage harvesting, this was

classified as septum correction. In the seven patients where no cartilage could be obtained from the nasal septum because of previous surgery, conchal cartilage was harvested. In each patient, antibiotic prophylaxis was performed with cephalozolin at 1.0 g i.v. at anesthetic induction and amoxicillin orally for 7 days postoperatively (1 g every 12 hours).

All subjects answered the Nasal Obstruction Septoplasty Effectiveness (NOSE) standardized questionnaire before the surgical treatment and 6 months postoperatively to assess the improvement of nasal symptoms after surgery.⁶ Anterior active rhinomanometry (AAR) was performed in all patients to determine nasal flow resistance⁷ preoperatively and 6 months after surgery. Mean follow-up was 12.2 months (range, 6–48 months). Informed consent was obtained from all patients as appropriate.

Surgical Technique

The surgical procedure is performed under general or local anesthesia with local infiltration of mepivacaine 2% with epinephrine (1:200,000). The endonasal approach rhinoplasty is performed as usual through a bilateral intercartilaginous incision and raising of nasal dorsal skin. The upper lateral cartilages are divided extramucosally from the septum either directly with Stevens scissors or as a consequence of cartilaginous hump removal (when required). We usually perform all the other surgical steps (septoplasty, turbinoplasty, osteotomies, etc.) before SG insertion, which is fixed at the end of the procedure.

The SG system is prepared with a cartilage base (obtained from the nasal septum or the auricular concha) shaped as a trapezoid (its length and width are decided in relation to the defect to be corrected) and beveled in its superior surface (►Fig. 1). Two strips of cartilage graft are molded and sutured symmetrically along the lateral edges of the base inferior surface, thus giving the graft the shape of two rails connected to a cartilaginous base (“RS” graft) and separated by a groove. Each strip graft is fixed to the cartilage base using two stitches (one for each strip extremity) in Vicryl Rapide 4/0 (Johnson & Johnson Intl., Brussels, Belgium), thus creating a sled-like shape (►Fig. 2). The skin of the nasal dorsum is raised by

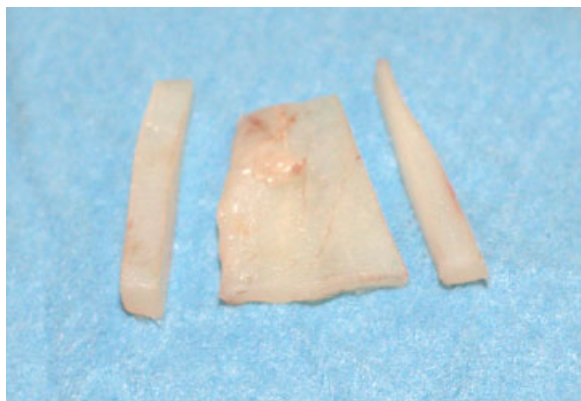

Fig. 1 The “rail spreader” composed of a trapezoid cartilage base and two cartilage strips.




Fig. 2 The “rail spreader” components are joint together with Vicryl Rapide 4/0 suture. Notice the three-dimension sled-like shape of the “bilateral spreader graft system.”

Aufricht elevator to expose the cartilaginous dorsum. A Cottle elevator is used to create two tunnel pockets (one on each side of the nasal septum) by preserving the integrity on the nasal mucosa between the septum and the upper lateral cartilages. The “RS” is inserted with its base upward by making the two rails slide cranially between the nasal septum and the upper lateral cartilages (►Figs. 3 and 4). Once in place, the graft does not need to be sutured, as the “railroad system,” together with the mucosal (below) and skin (above) “sandwich” coverage, will keep it still. In case of a severe saddling of the nasal dorsum, it will be possible to increase the graft thickness by adding several cartilage layers to increase dorsal height. Among our cases, we experienced a complete interruption of the internal mucosal layer (noticed in five patients after the removal of a prominent dorsal hump), which did not prevent the use of the RS because the nasal mucosa spontaneously covers the graft inferior surface. Nasal packing and external taping plaster are applied (to stabilize the RS in place) and removed 7 days after surgery.




Fig. 3 Frontal view illustration of “rail spreader” correct position.

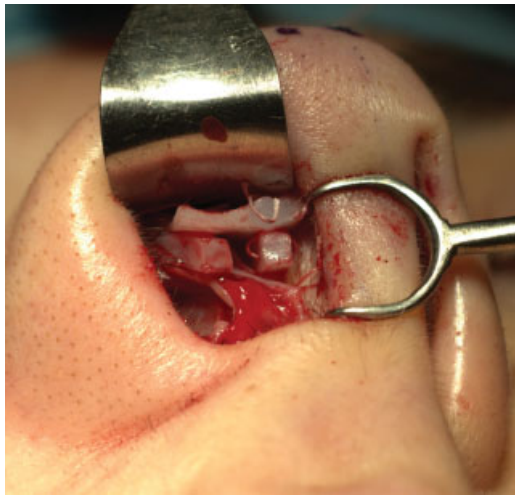


Fig. 4 Extramucosal approach and insertion of the “rail spreader” in the proper position: the upper edge of the septum and upper lateral cartilages are separated to create two tunnel pockets for graft placement.

Results

In all our patients, the surgical procedure was completed successfully. Only autogenous materials were used for grafting. Among the 49 SGs used, 42 were harvested from the nasal septum and 7 from ear cartilage.

All subjects included in this study had a follow-up of at least 6 months and were re-examined several times within this period. At postoperative follow-up, 47 (98%) patients displayed an improvement of their nose breathing function, as confirmed by a significant ($p < 0.001$) reduction of nasal breathing resistances at postoperative AAR (0.22 ± 0.11 Pa/cm³/s at 150 Pa) compared with preoperative conditions (0.92 ± 0.55 Pa/cm³/s). When comparing patients' answers to the NOSE questionnaire before and 6 month after surgery, a significant ($p < 0.001$) improvement in NOSE scores was found: preoperative 76.79 (± 18.57) versus 14.38 (± 10.92) postoperative.

No complication in terms of nasal infection or bleeding was recorded. No case of turbinoseptal synechiae was found. During the follow-up period, we did not notice any RS-related complication, such as graft displacement, soft-tissue deformation, or visible skin irregularities.⁸ From an aesthetic viewpoint, among the 21 patients with crooked nose we operated, no recurrence of nasal pyramid deviation was noticed during the follow-up period.

Discussion

The technique of “endonasal” SG placement we propose is a conservative procedure to treat functional nasal obstruction caused by an incompetent internal nasal valve and/or aesthetic deformities eventually associated with internal valve collapse (i.e., “inverted-V” deformity, saddle, or crooked nose). In such cases of functional and/or aesthetic impairment, placement of SG between the septum and the



Fig. 5 Frontal view showing the results of previous rhinoplasty: notice the “inverted-V” deformity and internal nasal valve collapse secondary to over-resection of the lower lateral cartilages.

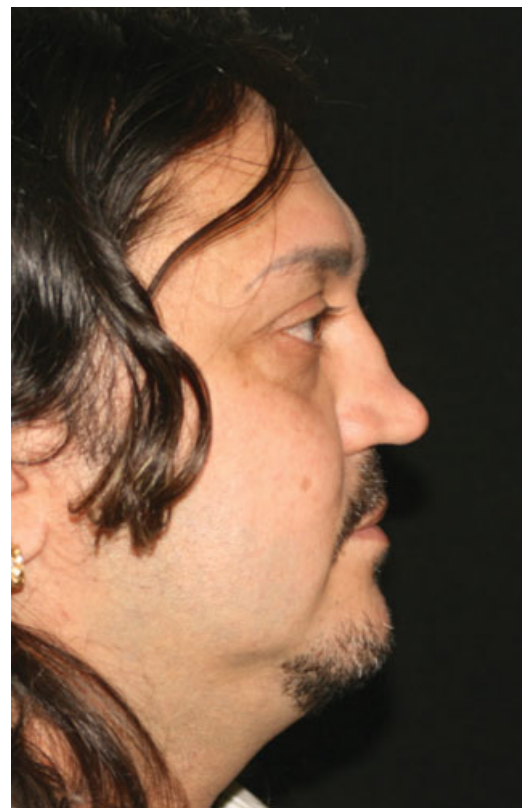

Fig. 6 Right lateral view of the previous case: notice the saddle nose deformity.

upper lateral cartilages after division in the apex, using an external-approach rhinoplasty, gives good results but may be more invasive than necessary. In particular, modern surgery is continuously searching for minimally invasive techniques without visible scars, quicker postoperative healing, preservation of the natural anatomy and aesthetic appearance, and restoration of the physiologic elasticity of the operated structures.^{4,9} On the basis of these principles, “endonasal” placement of SG seems extremely modern and desirable.

In 1984, Sheen described the SG for the first time in his article “a method of reconstructing the roof of the middle nasal vault following rhinoplasty” as a way to correct the “narrow nose syndrome” in “closed” rhinoplasty.¹ The major limitation to the use of SG in “endonasal” rhinoplasty is represented by the higher complexity of graft positioning and suturing in “closed” rhinoplasty with respect to the “transcolumellar” approach.^{1,8} To avoid such difficulties, we have developed and used an easily custom-made SG, we call “RS” because of its shape similar to the railroad tracks. “RS” construction is easy and rapid. Although no significant differences in outcomes was noticed in relation to graft source, we would advise the use of nasal cartilage, when available, for reasons of cartilage stiffness and straightness (useful for RS design), a part from avoidance of unnecessary ear trauma. “RS” stability does not require graft suture fixation because it is laid between the nasal septum and the upper lateral cartilages (stability on the horizontal plane) and the mucosal and skin lining (fixation on the vertical plane). The presence of two cartilage strips in



Fig. 7 Postoperative frontal view: notice the correction of the “inverted-V” deformity after rail spreader insertion.

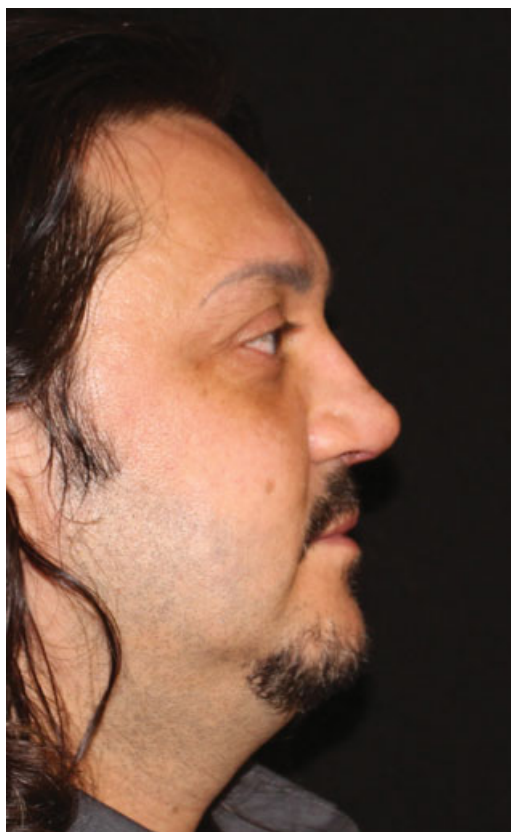

Fig. 8 Postoperative right lateral view: notice the resolution of the saddle nose deformity.

the RS structure enables the “RS” to work as a bilateral SG while increasing its stability. Avoiding the need of time-consuming and potentially troublesome graft suture fixation makes the use of RS extremely comfortable and straightforward. Moreover, the absence of unreabsorbable suture for graft fixation reduces the stiffness and the loss of natural elasticity of the cartilaginous pyramid, which are common “side effects” of SG placement with unreabsorbable suture in “open” rhinoplasty.⁹ Thanks to its base (whose thickness can be adapted in relation to the surgeon’s need), the RS is also extremely useful to increase nasal dorsum height in saddle nose and “inverted-V” deformity (► **Figs. 5–8**). Finally, its sled-like shape enables a rigid connection between the two “spreader strips,” which helps maintain a straight dorsum in patients treated for crooked nose.

In conclusion, our experience confirms a high reliability of the RS thanks to a very low complication rate and its applicability both in primary and secondary rhinoplasties.

Conclusion

The “RS” described is an effective, simple, and safe graft for the correction of both functional (i.e., internal nasal valve collapse) and aesthetic defects (i.e., saddle nose, “inverted-V” deformity, and crooked nose). Such graft is a valuable device in most secondary rhinoplasties and selected primary cases.

References

- 1 Sheen JH. Spreader graft: a method of reconstructing the roof of the middle nasal vault following rhinoplasty. *Plast Reconstr Surg* 1984;73(2):230–239
- 2 Rohrich RJ, Hollier LH. Use of spreader grafts in the external approach to rhinoplasty. *Clin Plast Surg* 1996;23(2):255–262
- 3 Bocchieri A, Macro C, Pascali M. The use of spreader grafts in primary rhinoplasty. *Ann Plast Surg* 2005;55(2):127–131
- 4 Micheli-Pellegrini V. Rhinoplasty. *Atlas of Practical Surgery*. Florence: SEE; 2005
- 5 André RF, Paun SH, Vuyk HD. Endonasal spreader graft placement as treatment for internal nasal valve insufficiency: no need to divide the upper lateral cartilages from the septum. *Arch Facial Plast Surg* 2004;6(1):36–40
- 6 Stewart MG, Smith TL, Weaver EM, et al. Outcomes after nasal septoplasty: results from the Nasal Obstruction Septoplasty Effectiveness (NOSE) study. *Otolaryngol Head Neck Surg* 2004;130(3):283–290
- 7 Huizing EH, De Groot JAM. *Functional Reconstructive Nasal Surgery*. Stuttgart, New York: Thieme; 2003
- 8 Tebbetts JB. Rethinking the logic and techniques of primary tip rhinoplasty: a perspective of the evolution of surgery of the nasal Tip. *Otolaryngol Clin North Am* 1999;32(4):741–754
- 9 Daniel RK. *Mastering Rhinoplasty. A Comprehensive Atlas of Surgical Techniques with Integrated Video Clips*. 2nd ed. Berlin, Heidelberg:: Springer-Verlag; 2010