

Colon sarcoidosis presenting with abdominal pain

Sarcoidosis is a multisystemic disease of unknown cause that is diagnosed on the basis of the history and demonstration of granulomas in involved organs in patients before the age of 50 years; peak incidence occurs between the ages of 20 and 39 years [1]. The gastrointestinal tract is involved in less than 1% of all cases of sarcoidosis [1,2]. The stomach is the most commonly involved part of the gastrointestinal tract, but reported locations range from the esophagus to the rectum. Sarcoidosis is usually diagnosed incidentally [1–3].

The patient is a 36-year-old black woman born in the United States who presented with abdominal pain. She was well until approximately 3 weeks prior to admission when she had postumbilical hernia repair.

Three days before admission she experienced abdominal bloating, diarrhea, and severe abdominal pain. Her past medical history was positive for a diagnosis at another institution of inconsequential polyp disease. Her family history showed multiple family members with malignancy, but also family members with sarcoidosis, mostly cousins. On examination, the patient had marked tenderness on the periumbilical region and hyperactive bowel sounds but no peritoneal signs. Results of routine hematology and biochemistry investigations, including liver enzymes, were all within normal limits except for mild hyperkalemia. Abdominal computed tomography (CT) showed extensive retroperitoneal and mesenteric lymphadenopathy. Colonoscopy showed small sessile polyps throughout the colon (Fig. 1). Colon random biopsy showed colonic mucosa with multifocal giant-cell and epithelioid confluent granulomata (Fig. 2).

Chest CT showed numerous nodules in both lungs with mild mediastinal and hilar adenopathy (Fig. 3). Right supraclavicular lymph node biopsy showed diffuse non-caseating granulomatous inflammation. Soft tissue CT of the neck showed scattered bilateral cervical lymphadenopathy with homogeneous enhancement suggesting reactive lymphadenopathy. Lymph nodes varied in size from 15 to 18 mm.

Endoscopy_UCTN_Code_CCL_1AD_2AJ

Competing interests: None

Taha Bat¹, Charles M. Morgan², Robert Marx³, Rebecca S. Bailey¹

¹ Department of Internal Medicine, Northeastern Ohio University College of Medicine (NEOUCOM), Youngstown, Ohio, USA

² Department of General Surgery, Northeastern Ohio University College of Medicine (NEOUCOM), Youngstown, Ohio, USA

³ General Surgery, Northside Medical Center, Youngstown, Ohio, USA

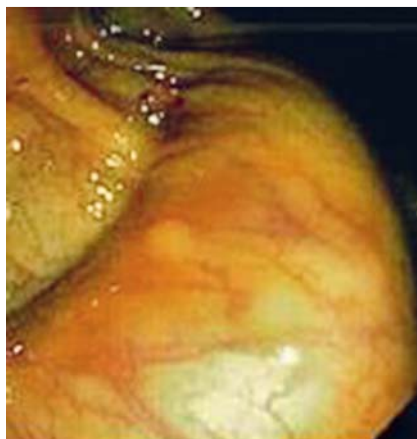

Fig. 1 Colonoscopic view of small sessile polyps throughout the colon.

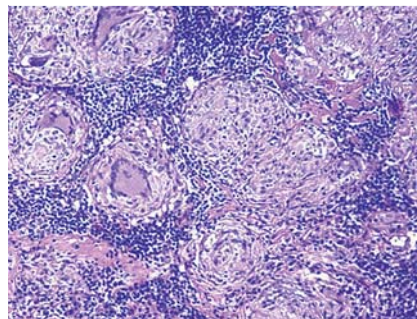


Fig. 2 Colon random biopsy showed colonic mucosa with multifocal giant-cell and epithelioid confluent granulomata.

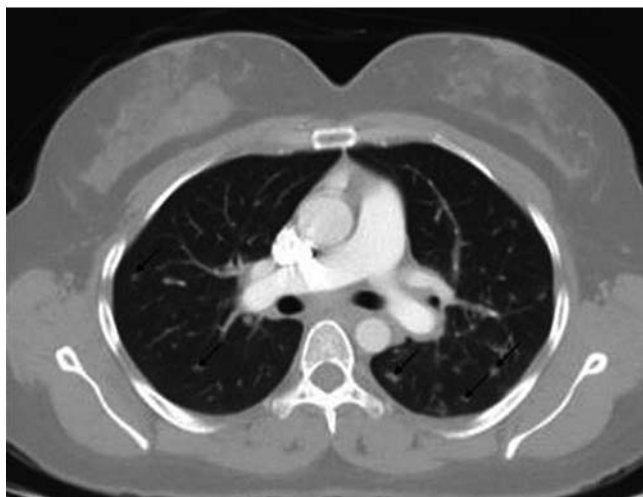

Fig. 3 Chest CT showed numerous nodules in both lungs with mild mediastinal and hilar adenopathy.

References

- 1 Shigemitsu H, Saleh S, Sharma OP et al. Colon sarcoidosis responds to methotrexate: a case report with review of literature. *J Pulm Respir Med* 2013; 3: 148
- 2 Nunes H, Bouvry D, Soler P et al. Sarcoidosis. *Orphanet J Rare Dis* 2007; 2: 46
- 3 Warshauer DM, Lee JKT. Imaging manifestations of abdominal sarcoidosis. *AJR Am J Roentgenol* 2004; 182: 15–28

Bibliography

DOI <http://dx.doi.org/10.1055/s-0034-1364890>
Endoscopy 2014; 46: E121
© Georg Thieme Verlag KG
Stuttgart · New York
ISSN 0013-726X

Corresponding author

Taha Bat, MD
500 Gypsy Lane, Youngstown
OH 44505, USA
TAHA_BAT@vchs.net