Cardiac incidentaloma during endoscopic ultrasound: cardiac myxoma with Gamna–Gandy bodies

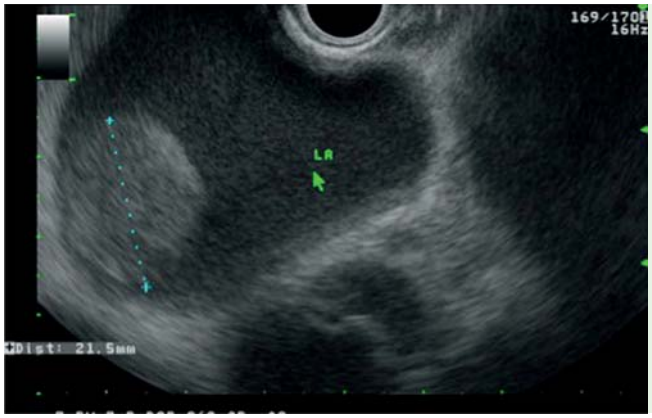

Fig. 1 Endoscopic ultrasonography at the level of the left atrium demonstrated the presence of an intra-atrial mass. LA, left atrium.

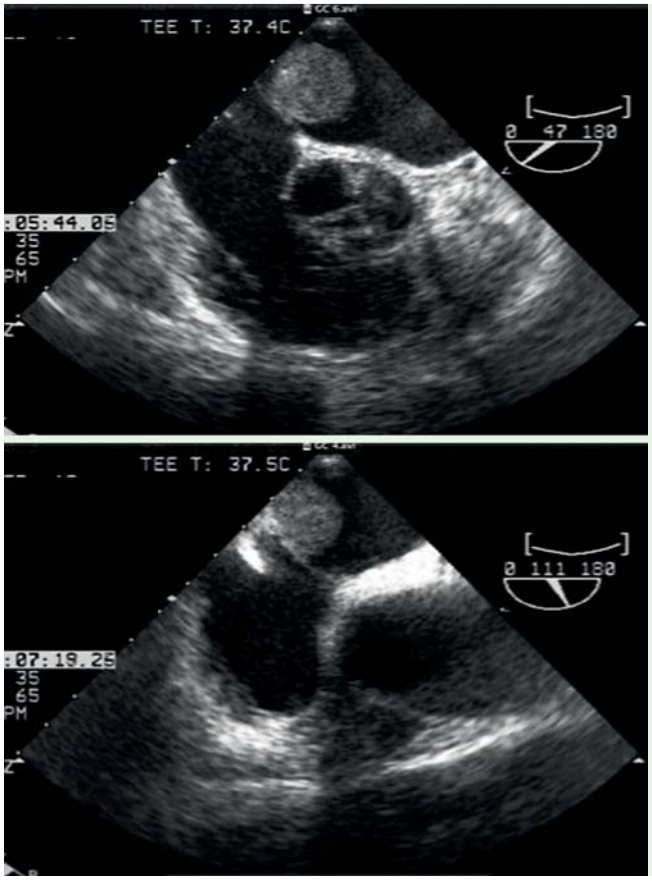

Fig. 2 Transesophageal echocardiogram revealed a mass adherent to the interatrial septum.

A 63-year-old female patient underwent endoscopic ultrasonography (EUS) for a gastric subepithelial lesion previously identified during upper endoscopy. A linear echoendoscope (Olympus UCT140AL5; Olympus, Tokyo, Japan) was used and no subepithelial lesion was found. However, a systematic evaluation revealed a 2-cm mass in the left atrium (**Fig. 1**). A transesophageal echocardiogram (TEE) confirmed the presence of a sessile mass, which was adherent to the upper third of the interatrial septum in the left atrium, with a heterogeneous appearance and a slight multilobulated contour (area 3.9 cm^2, dimensions 2.4 × 1.94 cm) (**Fig. 2**).

The patient underwent complete surgical resection of the tumor and the histopathological analysis revealed a cardiac myxoma (**Fig. 3**). Fibrotic nodules containing iron and calcium (Gamna–Gandy bodies) were identified within the tumor. Gamna–Gandy bodies have been described in atrial myxomas, but are considered a rare finding [1–4]. These nodules are more commonly seen in the spleen in conditions such as hemochromatosis, sickle cell anemia, and portal hypertension. As Gamna–Gandy bodies have been described in myxomas, but not in other cardiac tumors, their identification by ultrasound would be a noninvasive method of confirming the diagnosis of myxoma. Gamna–Gandy bodies can be identified on an ultrasound as bright echoes, sometimes with an acoustic shadow [5].

In the current case, on TEE some nodular bright echoes that might correspond to Gamna–Gandy bodies were observed. However, myxomas on TEE are usually heterogeneous and speckled in appearance, even when Gamna–Gandy bodies are not identified by histopathology. On EUS, no images consistent with Gamna–Gandy bodies could be identified. We believe this was probably due to the small size of the nodules in this case.

Left atrium myxomas are the most common primary tumor of the heart. They have an embolic potential and therefore resection is usually recommended even in asymptomatic patients. To the best of our knowledge, there are no previous reports of this entity being diagnosed during EUS. This is probably because primary tumors of the heart are a rare entity but also because sometimes a gastrointestinal-focussed approach is adopted. Nevertheless, a thorough evaluation of all surrounding systems may reveal additional unpredicted diagnoses. The proximity of the esophagus to the heart, in particular the atria, allowed the diagnosis of the mass in our patient. This emphasizes the importance of scanning the structures surrounding the gastrointestinal system during EUS. This proximity of the two systems should prompt greater collaboration between cardiologists and gastroenterologists.

Endoscopy_UCTN_Code_CCL_1AF_2AC

Competing interests: None

This document was downloaded for personal use only. Unauthorized distribution is strictly prohibited.

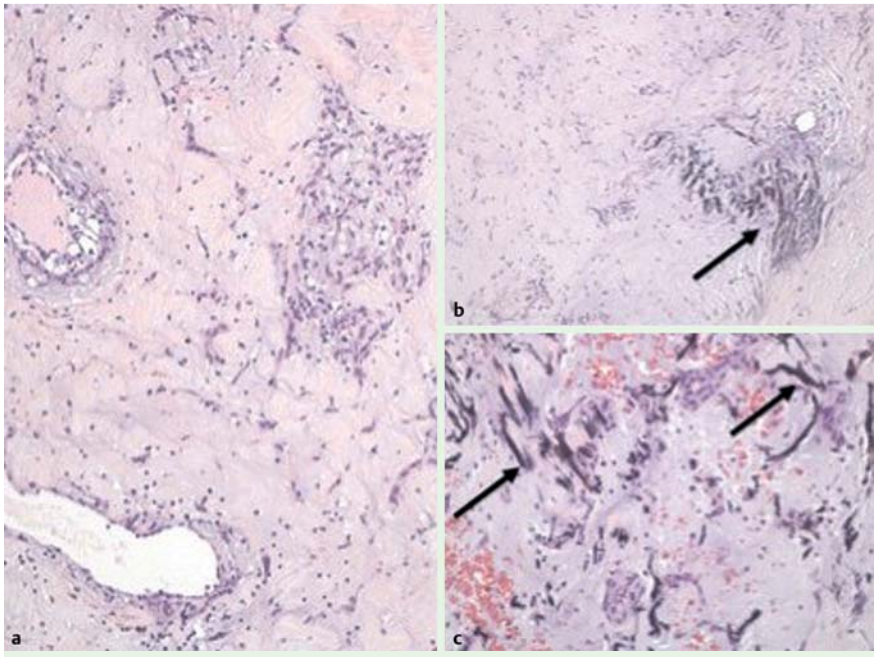

Fig. 3 Histological analysis of cardiac myxoma (hematoxylin and eosin). **a** Round, fusiform, and stellate cells in a myxoid matrix. **b, c** Gamna–Gandy bodies (arrows): multiple small nodules and elongated structures of fibrous tissue impregnated with hemosiderin (iron pigment) and calcium salts, surrounding perivascular spaces.

Paula Fazendas[1], Pedro Pinto Marques[2], Francisco Tortosa[3], Ricardo Rio Tinto[4], Cláudia Reis[2], Carlos Cotrim[1], Helder Pereira[1]

[1] Department of Cardiology, Hospital Garcia de Orta, Almada, Portugal
[2] Department of Gastroenterology, Garcia de Orta, Almada, Portugal
[3] Department of Pathology, Centro Hospitalar Lisboa Norte, Lisbon, Portugal
[4] Department of Gastroenterology, Centro Hospitalar Lisboa Central, Lisbon, Portugal

References

1 *Bhatnagar G, George E, Al Lawati F.* Cardiac myxomas with Gamna Gandy bodies – a case report and review of literature. Gulf J Oncolog 2009; 5: 64 – 67
2 *Jiménez Heffernan JA, Salas C, Tejerina E* et al. Gamna-Gandy bodies from cardiac myxoma on intraoperative cytology. Cytopathology 2010; 21: 203 – 205
3 *Watanabe M, Takazawa K, Wada A* et al. Cardiac myxoma with Gamna-Gandy bodies: case report with MR imaging. J Thorac Imaging 1994; 9: 185 – 187
4 *Trotter SE, Shore DF, Olsen EG.* Gamna-Gandy nodules in a cardiac myxoma. Histopathology 1990; 17: 270 – 272
5 *Bhatt S, Simon R, Vikram S.* Gamna-Gandy bodies – sonographic features with histopathologic correlation. J Ultrasound Med 2006; 25: 1625 – 1629

Bibliography

DOI http://dx.doi.org/10.1055/s-0034-1364945
Endoscopy 2014; 46: E122–E123
© Georg Thieme Verlag KG Stuttgart · New York
ISSN 0013-726X

Corresponding author
Paula Fazendas, MD
Cardiology Department
Hospital Garcia de Orta
Av. Professor Torrado da Silva
2800 Almada
Portugal
Fax: +351-21-2727162
pfazendas@hotmail.com

This document was downloaded for personal use only. Unauthorized distribution is strictly prohibited.