

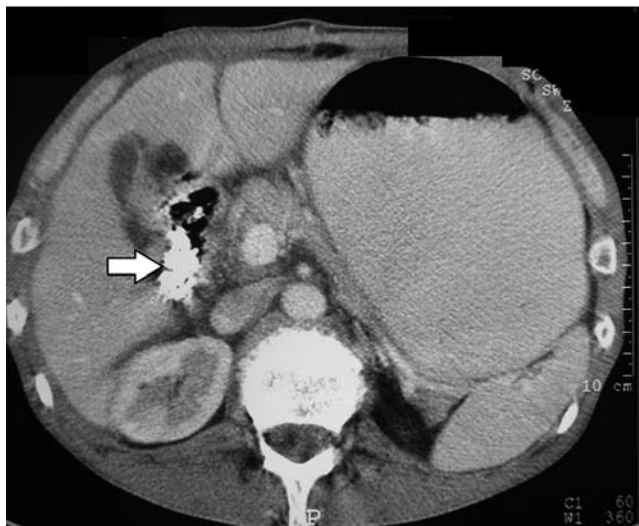
## Large nylon bag causing gastric outlet obstruction in a patient with schizophrenia

A 62-year-old man was admitted to our clinic complaining of nausea, vomiting, and abdominal pain for 5 days. He had a history of schizophrenia and had been on antipsychotic treatment for 10 years. His vital signs were within normal limits, but on physical examination, he was found to have a distended abdomen with no palpable mass. The results of laboratory tests were within normal limits, except for a slight leukocytosis of  $12 \times 10^9/L$  (normal  $4-10 \times 10^9/L$ ). Because, from his clinical presentation and an abdominal radiograph, we suspected he had intestinal obstruction, he underwent an abdominal computed tomography (CT) scan before having an endoscopic examination. Contrast-enhanced images showed a hyperdense area with irregular margins in the region of duodenum (▶ Fig. 1).


We performed upper gastrointestinal endoscopy while the patient was sedated with propofol but not intubated. This revealed food residues in the stomach. The distal part of the stomach was covered by an indefinable material, like a bag, which was obstructing the pylorus; the remnant stomach mucosa was normal. After washing the area with water, we were able to see the material that was stuck at the pylorus more clearly. Its color was brownish, with some black patchiness, but it seemed to reflect the light from the endoscope in some areas.

Grabbing the material was a quite difficult. After several attempts, the center of the material, which was close to pylorus, was successfully grabbed using a standard, oval, large-sized snare (Micro-Tech Co. Ltd., Düsseldorf, Germany). The foreign body was held close to the scope, which was then slowly withdrawn. In this way we were able at the first attempt to carefully remove the material from the stomach, without it breaking into pieces. Surprisingly, the material was a nylon bag, which was approximately  $15 \times 10$  cm in size (▶ Fig. 2). After endoscopic removal of the nylon bag, the patient's complaints improved dramatically.

Foreign body ingestion is extremely rare and generally occurs in patients with psychiatric disorders and intellectual disability [1]. According to the literature, around 90% of these foreign bodies pass through the gastrointestinal tract without any serious complications, 10%–20% require endoscopic removal, and only 1% of them will finally need surgical intervention [2]. In patients with psychiatric disorders and intellectual disability, failure to obtain an adequate medical history may lead to delays in diagnosis. Moreover, it is likely such patients will repeat this behavior, if they do not get adequate treatment for their psychiatric disorder. Therefore, these patients should be evaluated at the earliest opportunity with endoscopy if



**Fig. 1** Abdominal computed tomography (CT) scan showing a hyperdense area of contrast enhancement with irregular margins in the region of duodenum.



**Fig. 2** The foreign body was a nylon bag, which was approximately  $15 \times 10$  cm in size.

they present with a sudden onset of abdominal pain, nausea, and vomiting, so that emergency surgery can be avoided.

Endoscopy\_UCTN\_Code\_CCL\_1AB\_2AF

**Competing interests:** None

**Hakan Akinci, Fatih Karaahmet, Mevlut Hamamci, Sahin Coban**

Department of Gastroenterology, Diskapı Yıldırım Beyazıt Education and Research Hospital, Ankara, Turkey

**References**

- 1 *Hitosugi M, Kitamura O, Takatsu A et al.* Autopsy case of duodenal obstruction from impacted mushroom. *J Gastroenterol* 1998; 33: 562–565
- 2 *Pavlidis TE, Marakis GN, Triantafyllou A et al.* Management of ingested foreign bodies. How justifiable is a waiting policy? *Surg Laparosc Endosc Percutan Tech* 2008; 18: 286–287

**Bibliography**

**DOI** <http://dx.doi.org/10.1055/s-0034-1365377>  
*Endoscopy* 2014; 46: E210–E211  
© Georg Thieme Verlag KG  
Stuttgart · New York  
ISSN 0013-726X

**Corresponding author**

**Fatih Karaahmet, MD**  
Department of Gastroenterology  
Dışkapı Yıldırım Beyazıt Educational and Research  
Hospital  
Altındag  
Ankara, 06080  
Turkey  
Fax: +90-312-3186690  
[fatih\\_ares@yahoo.com.tr](mailto:fatih_ares@yahoo.com.tr)