Redeployment of proximally misplaced self-expandable metallic stent in an inoperable esophageal carcinoma, using an overtube technique

Fig. 1 Endoscopic view of a self-expanding metal stent (SEMS) that had been misplaced proximally from an esophageal tumor.

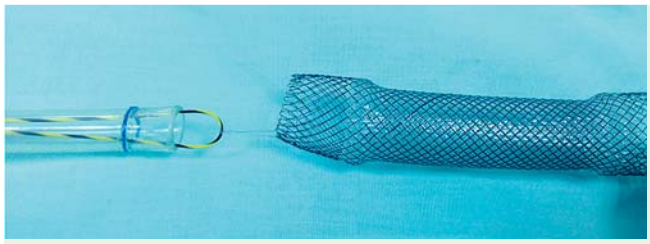

Fig. 2 Demonstration of the technique for retracting the self-expanding metal stent (SEMS): a guidewire has been looped through the lasso (see text), and will be used to pull the stent into the self-made transparent overtube as the overtube is pushed in the opposite direction. A blue radiopaque marker is attached at the distal end of the overtube.

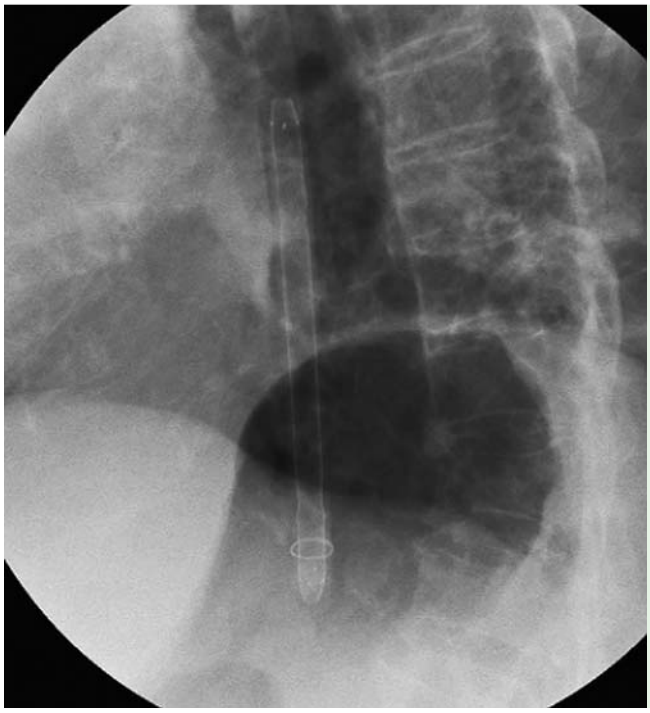

Fig. 3 Fluoroscopic view showing the self-expanding metal stent (SEMS) retracted into the self-made overtube. The radiopaque marker indicates the distal end of the overtube.

Fig. 4 How the retracted self-expanding metal stent (SEMS) can be redeployed by pushing the modified inner shaft of the stent delivery device.

Placement of self-expandable metallic stents (SEMSs) has been demonstrated to be a safe palliative procedure for patients with inoperable esophageal cancer and dysphagia [1,2]. When deployed distally from the stricture, most SEMSs can be repositioned endoscopically by pulling the lasso attached to the proximal end of the SEMS. However, if the deployment of the SEMS is completely proximal from the stricture, endoscopic repositioning of the SEMS is challenging. We report here a novel method for redeploying a proximally misplaced SEMS using an overtube.

A 70-year-old man attended our institution because of progressive dysphagia and weight loss. Upper endoscopy showed an esophageal tumor near the esophagogastric junction. Abdominal ultrasonography showed multiple liver tumors. Histopathological investigation confirmed the diagnosis of esophageal carcinoma with liver metastasis.

A SEMS (Evolution, 12 cm; Cook Endoscopy, Winston-Salem, North Carolina, USA) was placed for the palliative treatment of dysphagia. However, the SEMS was misplaced in a position proximal to the esophageal carcinoma (**Fig. 1**). Because the SEMS could not be repositioned distally after full deployment, a self-made transparent overtube with an internal diameter of 6 mm was used to retract the SEMS. A guidewire (Jagwire; Boston

This document was downloaded for personal use only. Unauthorized distribution is strictly prohibited.

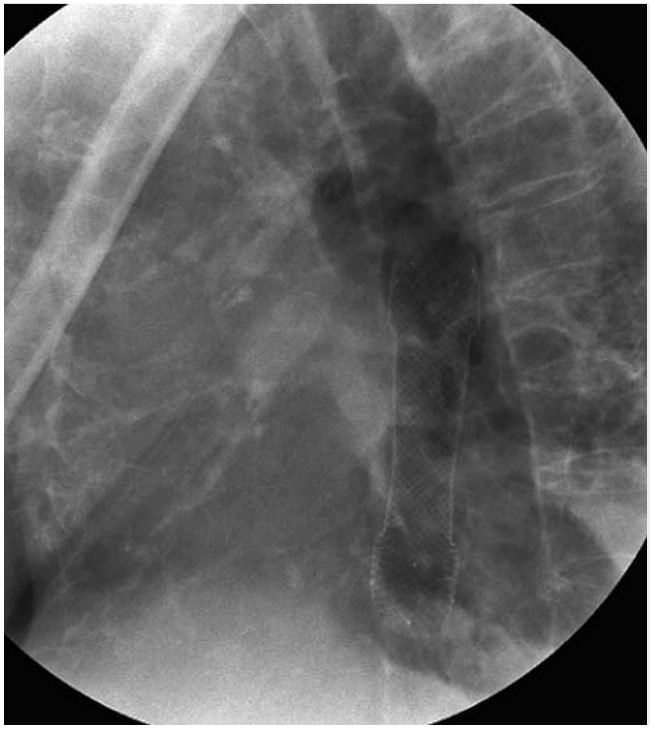

Fig. 5 Fluoroscopic view showing the stent now redeployed in the correct position.

Scientific Corporation, Natick, Massachusetts, USA) was inserted from the outer side of the lasso loop as far as the lumen of the SEMS. A retrieval basket was then used to grasp the distal end of the guidewire. The guidewire was then retrieved by the basket from the other side of the lasso so that it formed a U-shaped link through the lasso loop. Both ends of the guidewire were grasped and pulled into the overtube (▶ **Fig. 2**). The SEMS was then successfully retracted into the overtube as we pushed down on the overtube while simultaneously pulling out the guidewire (▶ **Fig. 3**).

The retracted SEMS was now inside the overtube. The modified inner shaft of the delivery device (outer diameter 5 mm; ▶ **Fig. 4**) was then used to push the SEMS in order to successfully redeploy the SEMS, under fluoroscopic control, at the correct position (▶ **Fig. 5**).

Endoscopy_UCTN_Code_TTT_1AO_2AZ

Competing interests: None

Tsung-Hsun Yang[1], Sheng-Lei Yan[1], Chien-Hua Chen[2], Yung-Hsiang Yeh[1], Shing-Kao Yueh[2]

[1] Division of Gastroenterology, Department of Internal Medicine, Chang Bing Show-Chwan Memorial Hospital, Taiwan

[2] Division of Gastroenterology, Department of Internal Medicine, Show-Chwan Memorial Hospital, Changhua City, Taiwan

References

1 *Knyrim K, Wanger HJ, Bethge N* et al. A controlled trial of an expansile metal stent for palliation of esophageal obstruction due to inoperable cancer. N Engl J Med 1993; 329: 1302 – 1307

2 *Ell C, Hochberger J, May A* et al. Coated and uncoated self-expanding metal stents for malignant stenosis in the upper GI tract: preliminary clinical experience with Wallstents. Am J Gastroenterol 1994; 89: 1496 – 1500

Bibliography

DOI http://dx.doi.org/10.1055/s-0034-1365432
Endoscopy 2014; 46: E260–E261
© Georg Thieme Verlag KG
Stuttgart · New York
ISSN 0013-726X

Corresponding author
Sheng-Lei Yan, MD, PhD
Division of Gastroenterology,
Department of Internal Medicine
Chang Bing Show-Chwan Memorial Hospital
No 6, Lugong Rd, Lugang Township
Changhua County 505
Taiwan
Fax: +886-4-7812401
yslcsmc@yahoo.com

This document was downloaded for personal use only. Unauthorized distribution is strictly prohibited.