

Asymptomatic colonic spirochetosis with severe inflammation on endoscopy

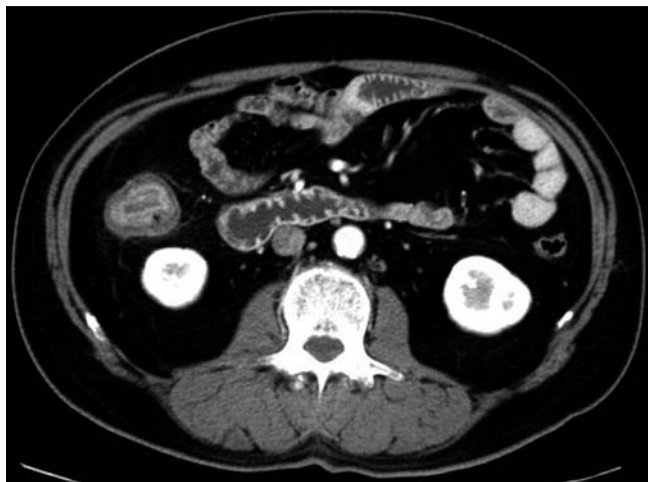

Fig. 1 Contrast-enhanced computed tomography shows thickening of the wall of the ascending colon in a 52-year-old man admitted for treatment of diabetes mellitus.

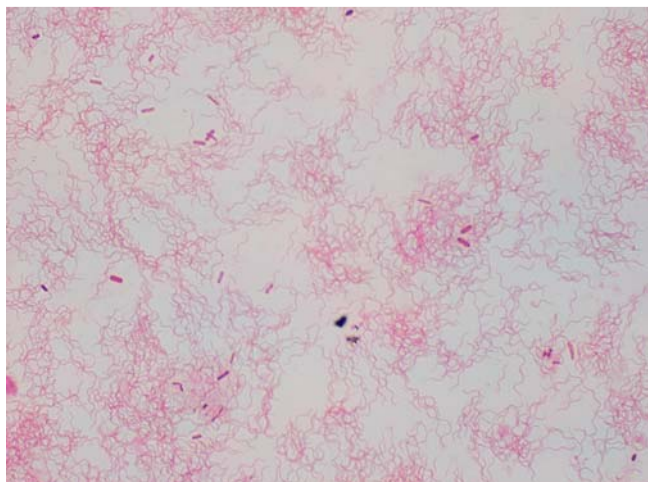


Fig. 3 Photomicrograph shows abundant Gram-positive bacilli in colonic lavage fluid.

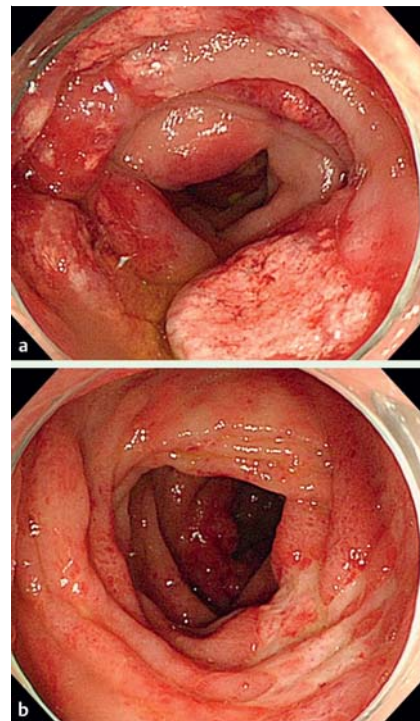


Fig. 2 a, b Endoscopy of the ascending colon shows a erythema b localized ulcers.

Intestinal spirochetosis is a condition defined by the presence of spirochetal microorganisms that have attached to the luminal surface of the intestinal epithelium [1]. The disease is relatively rare in developed countries, but the prevalence tends to be much higher in developing countries, as well as among homosexual individuals and those who are human immunodeficiency virus (HIV)-positive [2]. Spirochetes are difficult to cultivate in culture media; therefore, the diagnosis is made based on characteristic histopathological findings such as a basophilic fringe that produces a brush border on the epithelium of the intestinal surface. Despite the presence of digestive symptoms, endoscopic examination often shows a normal-appearing mucosa [3]. Metronidazole is frequently prescribed for treatment in immunosuppressed patients and those with invasive disease, while some reports

have suggested that treatment may not be necessary for noninvasive and asymptomatic cases [4,5].

A 52-year-old heterosexual Japanese man was hospitalized for treatment of diabetes mellitus. Although he was asymptomatic, peripheral blood examination revealed moderate elevation of C-reactive protein (7.82 mg/dL). Serological tests for syphilis, HIV, and *Entamoeba histolytica* yielded negative results. Computed tomography showed thickening of the wall of the ascending colon (Fig. 1). Colonoscopy revealed diffuse mucosal edema with erythema and localized ulcers in the ascending colon (Fig. 2). Gram staining of colonic lavage fluid showed abundant Gram-negative bacilli under microscopy (Fig. 3). No other specific bacteria, fungi, or acid-fast bacteria were detected in the lavage culture. Histopathological examination of biopsy specimens revealed the

presence of a blue fringe attached to the colonic surface epithelium and confirmed a diagnosis of colonic spirochetosis (Fig. 4). Immunohistochemical staining for cytomegalovirus was negative. Genetic investigation of spirochetes was not performed, therefore the microbiological detail was unclear. We were unable to follow-up the colonic lesion because the patient declined to undergo further radiological or endoscopic examinations.

Endoscopy_UCTN_Code_CPL_1AJ_2AB

Competing interests: None

Koichiro Abe¹, Mai Okubo¹, Yamato Mashimo¹, Akari Isono¹, Tadahisa Ebato¹, Takatsugu Yamamoto¹, Taro Ishii¹, Kazufusa Hoshimoto², Hiroto Kita¹, Yasushi Kuyama¹

¹ Department of Internal Medicine, Teikyo University School of Medicine, Tokyo, Japan

² Department of Pathology, Teikyo University School of Medicine, Tokyo, Japan

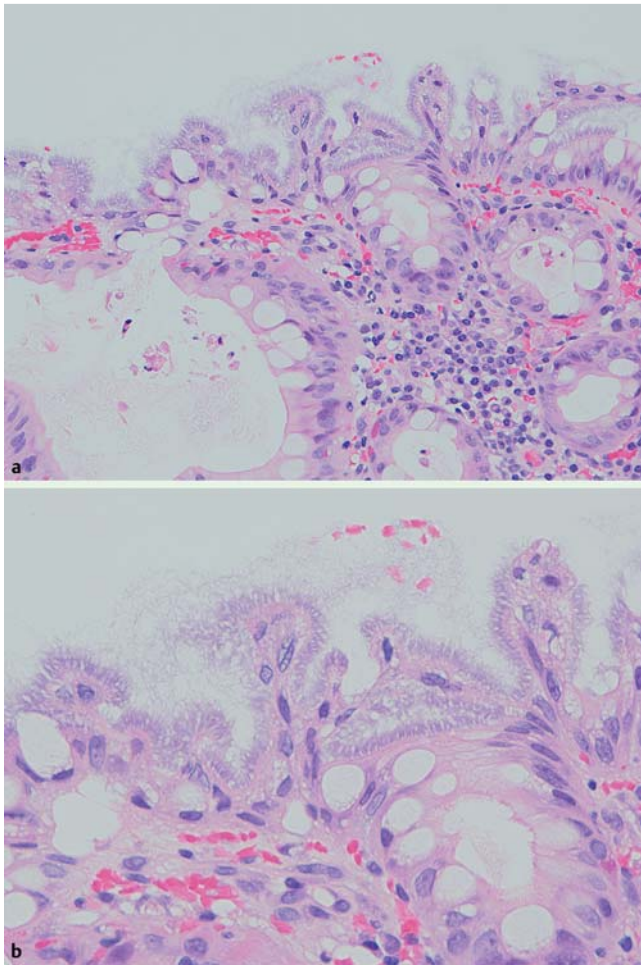


Fig. 4 Histopathological section of biopsy specimen from the ascending colon lesion shows the presence of a blue fringe attached to the colonic surface epithelium, confirming a diagnosis of colonic spirochetosis. Hematoxylin and eosin. **a** Low-power field; **b** High-power field.

References

- 1 Harland WA, Lee FD. Intestinal spirochaetosis. *BMJ* 1967; 3: 718–719
- 2 Korner M, Gebbers JO. Clinical significance of human intestinal spirochetosis – a morphologic approach. *Infection* 2003; 31: 341–349
- 3 Anthony NE, Blackwell J, Ahrens W et al. Intestinal spirochetosis: an enigmatic disease. *Dig Dis Sci* 2013; 58: 202–208
- 4 Koteish A, Kannangai R, Abraham SC et al. Colonic spirochetosis in children and adults. *Am J Clin Pathol* 2003; 120: 828–832
- 5 Nielsen RH, Orholm M, Pedersen JO et al. Colorectal spirochetosis: clinical significance of the infestation. *Gastroenterology* 1983; 85: 62–67

Bibliography

DOI <http://dx.doi.org/10.1055/s-0034-1365444>
Endoscopy 2014; 46: E264–E265
 © Georg Thieme Verlag KG
 Stuttgart · New York
 ISSN 0013-726X

Corresponding author

Koichiro Abe, MD
 Department of Internal Medicine
 Teikyo University School of Medicine
 2-11-1, Kaga, Itabashi-ku
 173-8606 Tokyo
 Japan
 Fax: +81-3-53751308
 abe@med.teikyo-u.ac.jp