

Gastrointestinal bleeding from jejunal heterotopic pancreas diagnosed by deep small-bowel enteroscopy

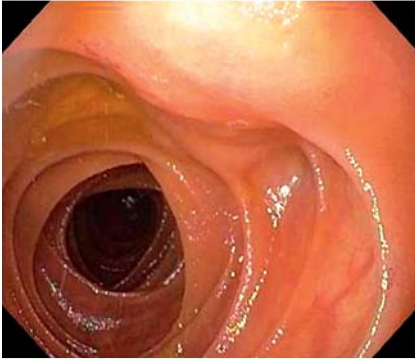


Fig. 1 View during spiral enteroscopy showing a medium-sized subepithelial mass with mucosal nodularity in the distal jejunum.

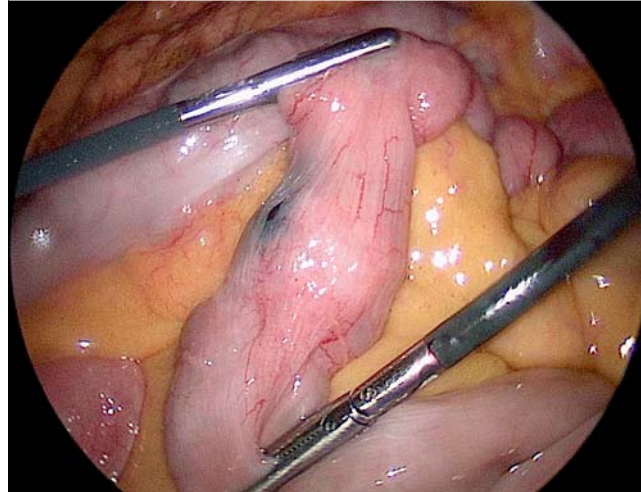


Fig. 2 Laparoscopic view of the jejunal mass with the adjacent tattoo mark clearly visible.

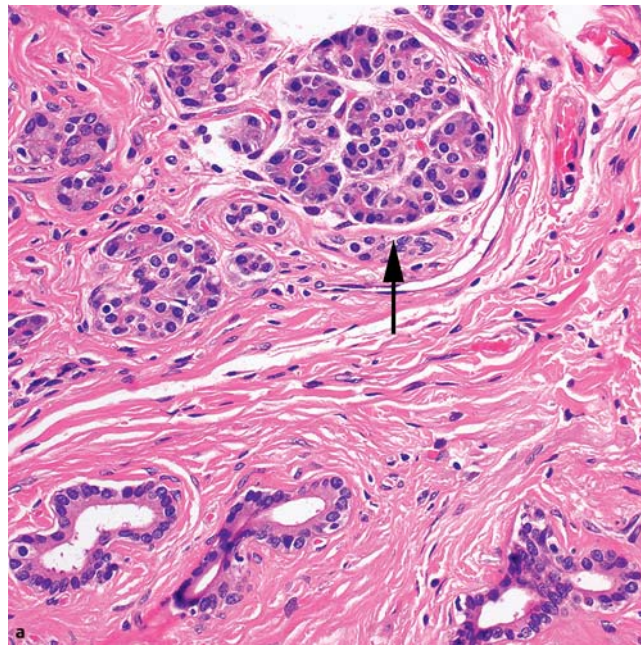
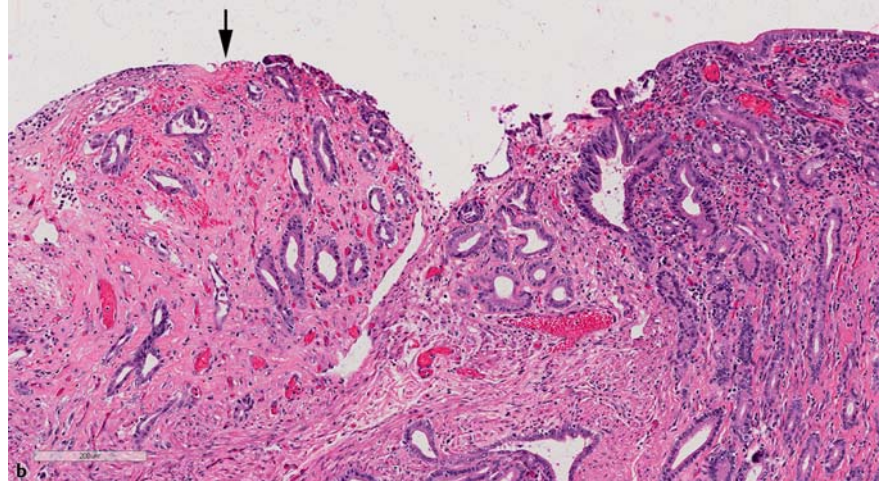


Fig. 3 Histopathologic appearance of the resected jejunal mass following hematoxylin and eosin (H&E) staining showing: **a** pancreatic acini (arrow) within the mass (magnification $\times 200$); **b** ectopic pancreas and evidence of ulceration at the mucosal surface (arrow), with otherwise intact mucosa to the upper right of the image (magnification $\times 100$).



A 70-year-old man presented with a 2-week history of overt (melena) and obscure gastrointestinal bleeding requiring an 8-unit blood transfusion. He underwent upper gastrointestinal endoscopy, colonoscopy, and push enteroscopy, all of which were nondiagnostic. A video capsule endoscopy, which reached the cecum at 6 hours and 21 minutes, showed active bleeding at 2 hours and 18 minutes without an obvious underlying lesion.

The patient was transferred to our facility and underwent antegrade deep (spiral) enteroscopy. A medium-sized subepithelial mass with mucosal nodularity was found 90 cm distal to the ligament of Treitz (Fig. 1). Standard forceps biopsies were diagnostic of heterotopic pancreas. At laparoscopy, the tumor was easily identified at the site of the endoscopically placed tattoo (Fig. 2) and jejunal resection was subsequently performed. Pathologic evaluation of the surgical specimen confirmed heterotopic pancreas (Fig. 3a) with focal areas of mucosal ulceration (Fig. 3b). Postoperatively, the patient did well and he had no recurrent bleeding at his 1-month follow-up visit.

Heterotopic (ectopic) pancreas is a relatively rare submucosal tumor that occurs most commonly in the stomach and duodenum [1]. Most tumors are discovered incidentally during radiographic or endoscopic examination, but a small proportion of patients with heterotopic pancreas can present with symptoms such as abdominal pain or bleeding [2]. A few recent

case reports have described the diagnosis of small-bowel heterotopic pancreas by capsule or balloon enteroscopy [3–5], but to our knowledge, this is the first reported case of heterotopic pancreas diagnosed by spiral enteroscopy.

Newer tools for evaluating the small intestine have expanded the diagnostic capabilities, but laparoscopic resection remains the definitive treatment for symptomatic heterotopic pancreas. Small-bowel heterotopic pancreas should be considered in the differential diagnosis of obscure gastrointestinal bleeding. Deep small-bowel enteroscopy can identify the lesion, provide tissue diagnosis, and allow placement of a tattoo mark for easy localization at the time of laparoscopy.

Endoscopy_UCTN_Code_CCL_1AC_2AH

Competing interests: None

J. Blair Williamson¹, David H. Gonzalo², Juan F. Alvarez³, Georgios Rossidis³, Peter V. Draganov¹

¹ Department of Medicine, University of Florida, Gainesville, Florida, USA

² Department of Pathology, University of Florida, Gainesville, Florida, USA

³ Department of Surgery, University of Florida, Gainesville, Florida, USA

References

- 1 *Dolan RV, ReMine WH, Dockerty MB.* The fate of heterotopic pancreatic tissue. A study of 212 cases. *Arch Surg* 1974; 109: 762–765
- 2 *Hsia CY, Wu CW, Lui WY.* Heterotopic pancreas: a difficult diagnosis. *J Clin Gastroenterol* 1999; 28: 144–147
- 3 *Lee MJ, Chang JH, Maeng IH et al.* Ectopic pancreas bleeding in the jejunum revealed by capsule endoscopy. *Clin Endosc* 2012; 45: 194–1974
- 4 *Tsurumaru D, Utsunomiya T, Kayashima K et al.* Heterotopic pancreas of the jejunum diagnosed by double-balloon enteroscopy. *Gastrointest Endosc* 2007; 66: 1026–1027
- 5 *Takeda Y, Nakase H, Chiba T.* Ectopic pancreas at the jejunum. *Dig Liver Dis* 2011; 43: e6

Bibliography

DOI <http://dx.doi.org/10.1055/s-0034-1365747>
 Endoscopy 2014; 46: E297–E298
 © Georg Thieme Verlag KG
 Stuttgart · New York
 ISSN 0013-726X

Corresponding author

J. Blair Williamson, MD

University of Florida
 Division of Gastroenterology, Hepatology,
 and Nutrition
 1329 SW 16th
 Ave, Suite 5251
 PO Box 100214
 Gainesville, FL 32608
 USA
 Fax: +1-352-392-3618
 blair.williamson@medicine.ufl.edu