Extensive dabigatran-induced exfoliative esophagitis harboring squamous cell carcinoma

A 90-year-old woman presented to the emergency ward with chest pain and odynophagia. Her medical history included chronic atrial fibrillation, for which she had been started a treatment with the novel oral anticoagulant dabigatran 6 months previously. The patient had not complied with the strict instructions relevant to the intake of dabigatran, namely that it needs to be taken while in an upright position with food or with an 8-ounce glass of water.

After exclusion of myocardial infarction, an esophagogastroduodenoscopy (EGD, GIF H180, Olympus, Hamburg, Germany) was performed, and revealed extensive exfoliative esophagitis with spontaneously sloughed esophageal casts, findings that were most prominent in the distal part of the esophagus (**Fig. 1**). In addition, we observed an irregular nodular segment in the mid-esophagus. The patient was treated with proton pump inhibitors and was kept nil by mouth; dabigatran was discontinued.

A repeat EGD 3 days later showed marked improvement in the esophagitis with scarring and patchy residual erosions and erythema (**Fig. 2 a**). However, 29 – 31 cm from the incisors, there was a semicircumferential polypoid mass that was highly suspicious of esophageal carcinoma (**Fig. 2 b**), a diagnosis that was supported by the findings on narrow band imaging (**Fig. 2 c**).

Histopathology of biopsies taken from this lesion confirmed the presence of a poorly differentiated squamous cell carcinoma, while mucosal biopsies displayed parakeratosis and acanthosis. Serology and direct immunofluorescence to exclude medication-induced pemphigoid were negative. The patient underwent an endoscopic ultrasound (EUS), which revealed a T2N$^+$ lesion, and computed tomography (CT) excluded metastatic disease. Given her advanced age, the patient was referred for palliative radiotherapy. Dabigatran was permanently withdrawn.

Dabigatran is a novel oral anticoagulant which poses new challenges in terms of the management of any complicating gastrointestinal hemorrhage and because of its propensity to cause potentially severe esophagitis [1, 2]. Although the important question as to mere coincidence or causal relationship must remain open, this is the first reported case of malignancy in the setting of severe dabigatran-related esophageal injury, illustrating that re-endoscopy after drug withdrawal appears to be a reasonable approach to ensure that other esophageal lesions do not go unnoticed [3].

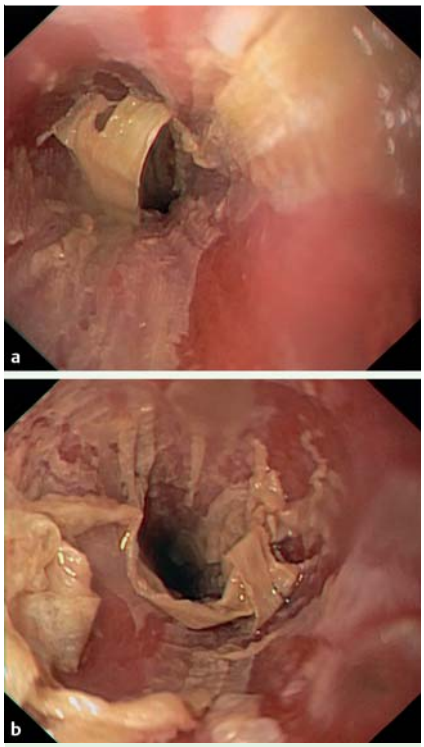

Fig. 1 Views during esophagogastroduodenoscopy (EGD) showing: **a** widespread spontaneous sloughing of the esophageal mucosa, compatible with extensive exfoliative esophagitis; **b** changes that were most marked in the distal segment of the esophagus.

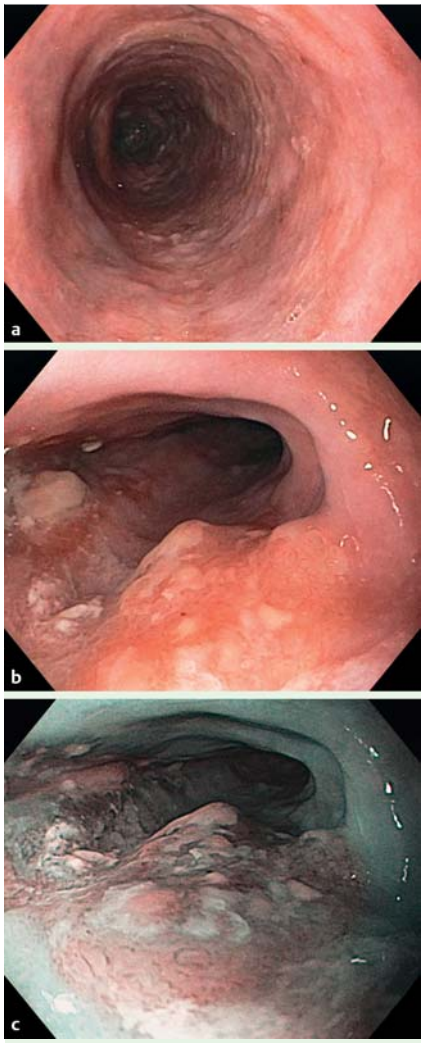

Fig. 2 Views from a repeat esophagogastroduodenoscopy (EGD) 3 days later showing: **a** marked improvement in the esophagitis with scarring and patchy residual erosions and erythema; **b** a suspicious semicircumferential polypoid lesion at 29 – 31 cm from the incisors; **c** the findings on narrow band imaging, which supported the likely diagnosis of an esophageal carcinoma.

Endoscopy_UCTN_Code_CCL_1AB_2AC_3AH

Competing interests: None

Vincent Zimmer, Markus Casper, Frank Lammert

Department of Medicine II, Saarland University Hospital, Homburg, Germany

This document was downloaded for personal use only. Unauthorized distribution is strictly prohibited.

References

1 *Desai J*, *Granger CB*, *Weitz JI* et al. Novel oral anticoagulants in gastroenterology practice. Gastrointest Endosc 2013; 78: 227 – 239

2 *Okada M*, *Okada K*. Exfoliative esophagitis and esophageal ulcer induced by dabigatran. Endoscopy 2012; 44 : E23 – E24

3 *Ootani A*, *Hayashi Y*, *Miyagi Y*. Dabigatran-induced esophagitis. Clin Gastroenterol Hepatol. Epub ahead of print 2013, doi: 10.1016/j.cgh.2013.09.010

Bibliography

DOI http://dx.doi.org/10.1055/s-0034-1365782

Endoscopy 2014; 46: E273–E274

© Georg Thieme Verlag KG

Stuttgart · New York

ISSN 0013-726X

Corresponding author

Vincent Zimmer, MD

Department of Medicine II

Saarland University Hospital

Kirrberger Str.

66421 Homburg

Germany

Fax: +49-6841-1621305

vincent.zimmer@uks.eu

This document was downloaded for personal use only. Unauthorized distribution is strictly prohibited.