

Endoscopic removal of a proximally migrated pancreatic stent using a gooseneck snare

The effectiveness of pancreatic stents for prevention of post-endoscopic retrograde cholangiopancreatography (ERCP) pancreatitis is widely recognized [1]. However, proximal migration of a pancreatic stent is occasionally encountered, potentially necessitating surgical intervention [2,3]. A gooseneck snare (Amplatz Gooseneck Microsnare Kit; Covidien, Irvine, California, USA), which was originally developed for removing intravascular foreign bodies [4], is a microsnare that forms a 90° angle just after exiting the outer sheath (● Fig. 1). We herein describe a useful technique for endoscopic removal of a proximally migrated pancreatic stent using this snare.

A 72-year-old man required endoscopic removal of common bile duct stones. Whilst he was undergoing the procedure, a one-sided pigtail pancreatic stent (Daimon T stent, 5 Fr, 5 cm; Silux, Saitama, Japan) was incorrectly placed in the main pancreatic duct (MPD). Impaction of its pigtail end into a branch of the pancreatic duct and the non-dilated MPD (● Fig. 2) inhibited the removal of the stent with a small-diameter snare, basket, balloon catheter, and biopsy forceps.

The patient was referred to our institution and ERCP was carried out. Access to the MPD was obtained with a conventional cannula (ERCP catheter; MTW-Endoskopie, Wesel, Germany) and 0.035-inch hydrophilic guidewire (Radifocus; Terumo, Tokyo, Japan). The catheter was passed alongside the stent to the tail of the pancreas. A gooseneck snare (4-mm-wide loop, 175-cm long) was then detached from its accessory sheath and inserted through the prepositioned catheter. As the snare was withdrawn, its loop passed over the pancreatic stent until it reached the bend in the pigtail portion of the stent (● Fig. 3a). With the pigtail portion therefore grasped by the loop of the snare, further withdrawal of the snare allowed the stent to be easily pulled back into the duodenum (● Fig. 3b and ● Fig. 4; ● Video 1).




Fig. 1 The gooseneck microsnare kit has a snare loop that forms a 90° angle just after exiting the sheath. Various sizes of snare loops are available, and the optimal size can be chosen according to the diameter of the pancreatic duct.

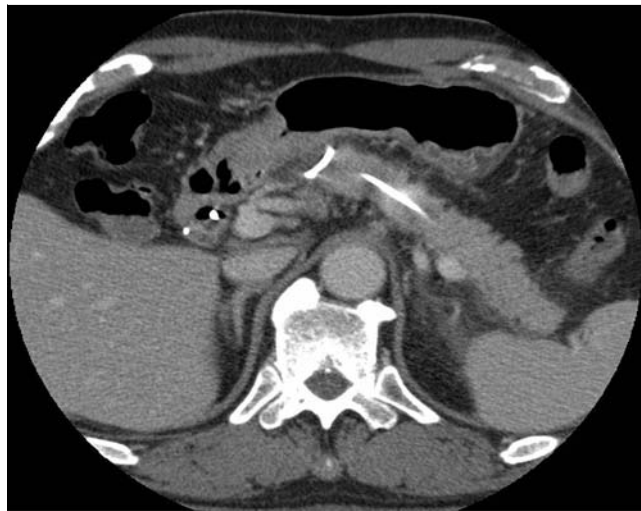

Fig. 2 Computed tomography (CT) image showing the proximally migrated pancreatic stent with its pigtail end impacted in a branch of the pancreatic duct.

Video 1

Endoscopic removal of a proximally migrated pancreatic stent using a gooseneck snare.

Endoscopic removal of a pancreatic stent located in the MPD is technically demanding [5]. A gooseneck snare can easily expand with a snare loop perpendicular to the MPD, making the stent easier to grasp.

Endoscopy_UCTN_Code_CPL_1AK_2AC

Competing interests: None

Kazunaga Ishigaki¹, Tsuyoshi Hamada¹, Hiroyuki Isayama¹, Hirofumi Kogure¹, Yousuke Nakai¹, Tomonori Wada², Kazuhiko Koike¹

¹ Department of Gastroenterology, Graduate School of Medicine, The University of Tokyo, Tokyo, Japan

² Department of Gastroenterology, Sanraku Hospital, Tokyo, Japan

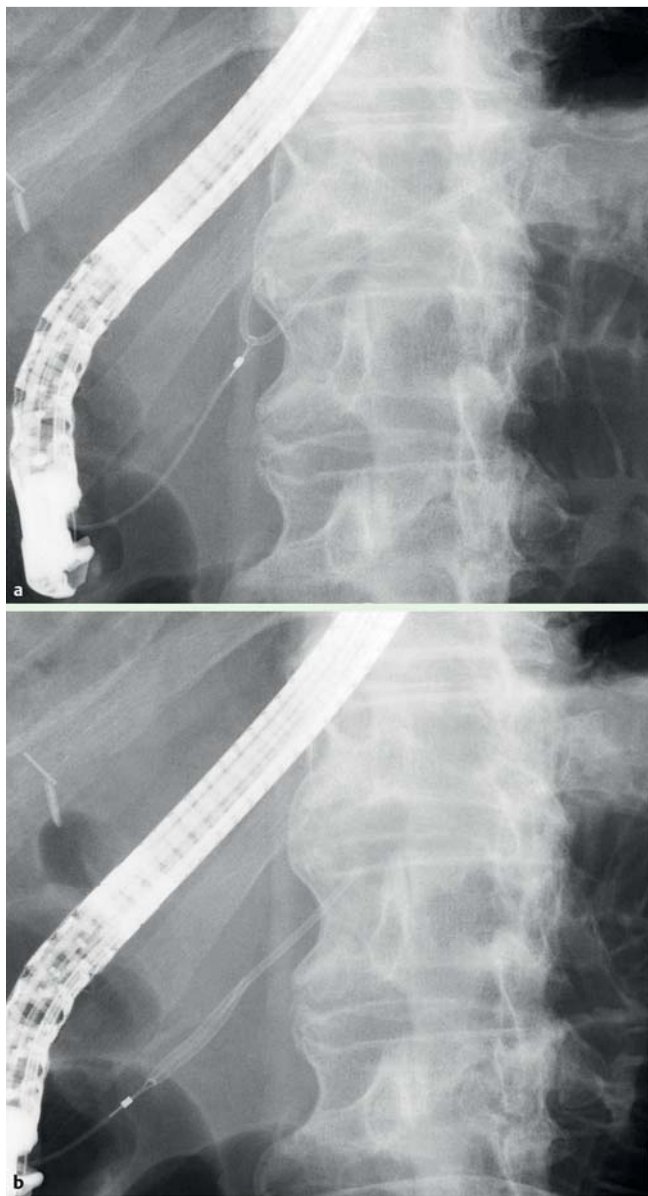


Fig. 3 Fluoroscopic images of: **a** the gooseneck snare grasping the pigtail portion of the migrated pancreatic stent; **b** the pancreatic stent being pulled out of the pancreatic duct.

References

- 1 Choudhary A, Bechtold ML, Arif M et al. Pancreatic stents for prophylaxis against post-ERCP pancreatitis: a meta-analysis and systematic review. *Gastrointest Endosc* 2011; 73: 275–282
- 2 Matsubayashi H, Ooka S, Kimura H et al. Proximally migrated pancreatic stent successfully removed using needle-knife and forceps: complication after precut papillotomy assisted by pancreatic stenting. *Clin Res Hepatol Gastroenterol* 2011; 35: 321–324
- 3 Gonzalez F, Mesleh MG, Lukens FJ et al. Laparoscopic central pancreatectomy and pancreaticogastrostomy for the management of a proximally migrated pancreatic stent. *JOP* 2013; 14: 273–276
- 4 Jang JH, Woo SI, Yang DH et al. Successful coronary stent retrieval from the ascending aorta using a gooseneck snare kit. *Korean J Intern Med* 2013; 28: 481–485
- 5 Takahara N, Isayama H, Sasahira N et al. Endoscopic removal of a piece of retained pancreatic stent with a novel new technique: turned guide-wire looping method. *Endoscopy* 2012; 44: E401

Bibliography

DOI <http://dx.doi.org/10.1055/s-0034-1365792>
Endoscopy 2014; 46: E283–E284
 © Georg Thieme Verlag KG
 Stuttgart · New York
 ISSN 0013-726X

Corresponding author

Hiroyuki Isayama, MD
 Department of Gastroenterology,
 Graduate School of Medicine
 The University of Tokyo
 7-3-1 Hongo Bunkyo-ku
 Tokyo 113-8655
 Japan
 Fax: +81-3-38140021
isayama-tky@umin.ac.jp



Fig. 4 The 5-Fr, 5-cm plastic pancreatic stent following its successful removal.