Delayed successful treatment of iatrogenic colon perforation using an over-the-scope clip

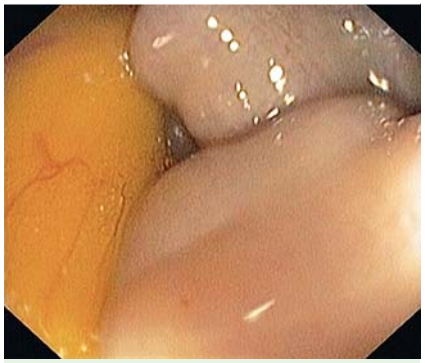

Fig. 1 Colon perforation with visualization of the epiploon.

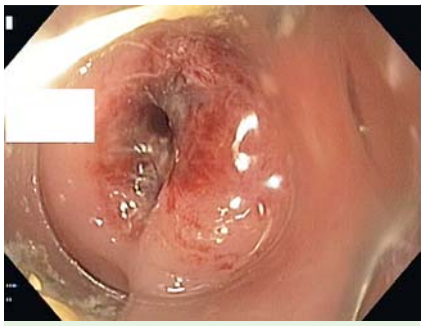

Fig. 2 Perforation orifice and 11/6 t over-the-scope clip.

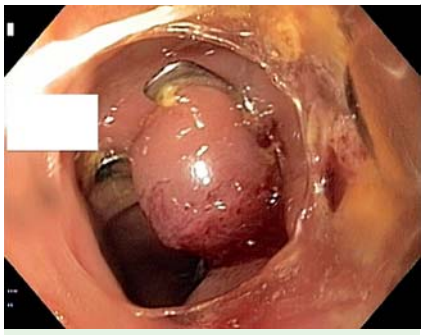

Fig. 3 Over-the-scope in place.

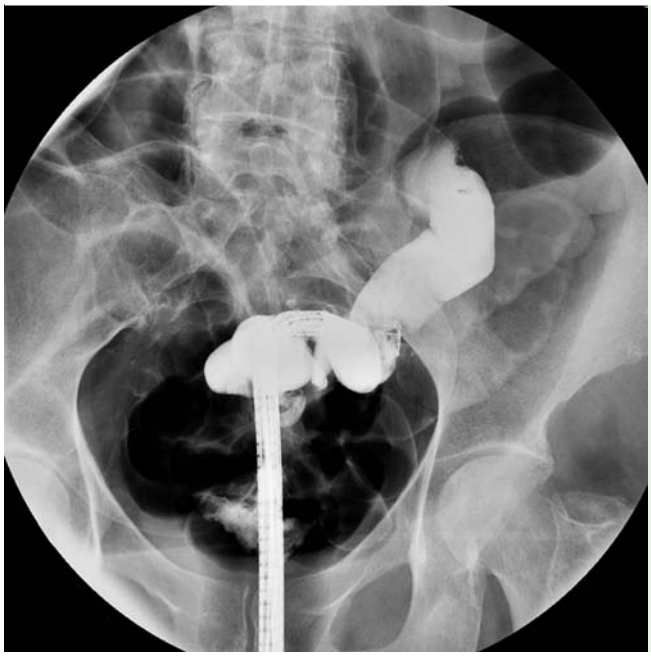

Fig. 4 Watertight closure with no extravasation of contrast medium.

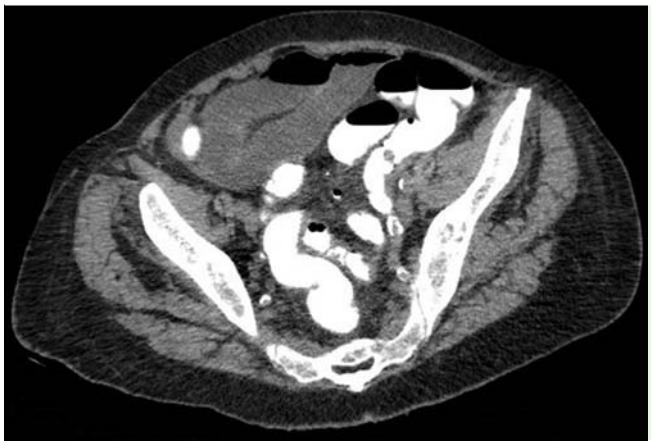

Fig. 5 CT scan with bowel opacification confirmed a sealed clip.

Over-the-scope clip closure of iatrogenic gastrointestinal tract perforations has been successfully demonstrated, and is usually performed in the immediate perioperative setting [1, 2]. We report the first case, to our knowledge, of delayed successful treatment of an iatrogenic colon perforation using an over-the-scope clip.

An 80-year-old woman underwent routine colonoscopy. Her medical history was unremarkable apart from unexplained thrombocytopenia (40 000 platelets/dL). During endoscopy, a perforation occurred at the level of the sigmoid junction with the left colon (▶ **Fig. 1**). At that time, after multidisciplinary discussion, and in view of the successful colonic preparation and the thrombocytopenia, a mini-invasive endoscopic treatment was proposed (the patient being on antibiotics). Two and a half hours later the patient was transferred to our unit for an attempt at clip closure. Using a gastroscope and CO2 insufflation, a 7-mm perforation orifice was visualized. An OTSC 11/6 t clip (Ovesco Endoscopy GmbH, Tübingen, Germany) was then delivered, with aspiration of the edges of the orifice (▶ **Fig. 2**, ▶ **Fig. 3**). Contrast medium study through the endoscope performed at that time did not show any fluid extravasation (▶ **Fig. 4**).

The day after the procedure, the patient presented localized peritoneal irritation and fever (38 °C). Lab tests showed no hyperleukocytosis, but the C-reactive protein level had increased to 204 U/L. Spiral CT with bowel opacification performed then confirmed a sealed clip closure with no free fluid or air in the peritoneal cavity (▶ **Fig. 5**). The patient was kept fasting until bowel transit was re-established 2 days later. She was symptom-free by the

This document was downloaded for personal use only. Unauthorized distribution is strictly prohibited.

postoperative third day. On day 5, she was discharged from the hospital. She is clinically well and symptom-free.

Delayed treatment of an iatrogenic colonic perforation with an over-the-scope clip is a feasible and effective technique that should be considered by expert endoscopists. However, the peritoneal cavity may become contaminated during the delay between perforation and definitive treatment.

Endoscopy_UCTN_Code_TTT_1AQ_2AG

Competing interests: None

Gianfranco Donatelli[1], Bertrand M. Vergeau[1], Jean-Loup Dumont[1], Claude Altmann[1], Stravros Dritsas[2], Parag Dhumane[3], Thierry Tuszynski[1], Bruno Meduri[1]

[1] Unité d'Endoscopie Interventionnelle, Hôpital Privé des Peupliers, Générale de Santé, Paris, France

[2] Service d'Hépatologie, Hôpital Minjoz, Besançon, France

[3] Department of General and Laparoscopic Surgery, Lilavati Hospital and Research Center, Bandra (W), Mumbai, India

References

1 *Donatelli G, Vergeau BM, Dritsas S* et al. Closure with an over-the-scope-clip allows therapeutic ERCP to be safely performed after acute duodenal perforation during diagnostic endoscopic ultrasound. Endoscopy 2013; 45: E392 – 393

2 *Dìez-Redonod P, Bianco JL, Lorenzo-Pelayo S* et al. A novel system for endoscopic closure of iatrogenic colon perforations using the Ovesco clip and omental patch. Rev Esp Enferm Dig 2012; 104: 550 – 552

Bibliography

DOI http://dx.doi.org/10.1055/s-0034-1365796
Endoscopy 2014; 46: E285–E286
© Georg Thieme Verlag KG
Stuttgart · New York
ISSN 0013-726X

Corresponding author
Dr. Gianfranco Donatelli
Hôpital Privé des Peupliers, Générale de Santé
8 Place de l'Abbé G. Hénocque
75013 Paris
France
donatelligianfranco@gmail.com

This document was downloaded for personal use only. Unauthorized distribution is strictly prohibited.