

Chemosaturation with Percutaneous Hepatic Perfusions of Melphalan for Hepatic Metastases: Experience from Two European Centers

Chemosaturation mittels perkutaner hepatischer Perfusion von Melphalan zur Behandlung von Lebermetastasen: Erfahrungen von zwei europäischen Zentren

Authors

T. J. Vogl¹, S. Zangos¹, J. E. Scholtz¹, F. Schmitt¹, S. Paetzold², J. Trojan³, F. Orsi⁴, G. Lotz⁵, P. Ferrucci⁶

Affiliations

Affiliation addresses are listed at the end of the article.

Key words

- melphalan
- liver
- metastases
- hepatic perfusion
- hemofiltration
- safety

Zusammenfassung



Ziel: Chemosaturation mit perkutaner hepatischer Perfusion (PHP; Hepatic CHEMOSAT[®] Delivery System; Delcath Systems Inc, USA) ist ein minimalinvasives, wiederholbares regionales Therapieverfahren bei nicht resezierbaren Lebermetastasen, das mithilfe eines Systems aus Kathetern und Filtern das venöse hepatische Blut vom Systemkreislauf isoliert und eine hochdosierte Chemotherapeutikagabe über die hepatischen Arterien ermöglicht. Der venöse hepatische Abfluss wird zur Reduktion von Nebenwirkungen des Chemotherapeutikums vor dem Rückführen in den systemischen Kreislauf gefiltert. Wir berichten über unsere Erfahrungen mit Chemosaturation-PHP an zwei europäischen Zentren.

Material und Methoden: 14 Patienten zeigten nicht resezierbare hepatische Metastasen solider Tumore; 13 Patienten wurden in 1–3 Therapiesitzungen mittels Chemosaturation-PHP behandelt. Melphalan 2,0 (n=1) und 3,0 (n=12) mg/kg wurde 30 Minuten in die hepatischen Arterien infundiert. Für das Tumoransprechen waren 12 Patienten auswertbar.

Ergebnisse: Komplette Remission wurde in einem Patienten beobachtet (Cholangiokarzinom, n=1), partielle Remission in 6 Patienten (Aderhautmelanom, n=3; malignes Melanom, n=3), 5 Patienten zeigten stable disease (Aderhautmelanom, n=3; Brustkrebs, n=1; Magenkarzinom, n=1). Milde bis mäßige filterassoziierte Nebenwirkungen (z.B. Thrombozytopenie, Anämie) wurden unmittelbar nach der Behandlung beobachtet. Grad 3/4 Melphalan-assoziierte Panzytopenien entwickelten sich nach 1–2 Wochen. Alle hämatologischen Ereignisse wurden effektiv mit Transfusionen und/oder anderen unterstützenden Maßnahmen behandelt. Mit dem neuen, hocheffizienten Filtersystem gab es geringere Nebenwirkungen und eine beschleunigte Erholung. In einem Fall musste das Verfahren aufgrund von einer heparininduzierten

Abstract



Purpose: Chemosaturation with percutaneous hepatic perfusion (PHP; Hepatic CHEMOSAT[®] Delivery System; Delcath Systems Inc, USA) is a minimally invasive, repeatable regional therapy for unresectable hepatic metastases. It uses a system of catheters and filters to isolate hepatic venous blood from the systemic circulation, allowing delivery of high-dose chemotherapy to the hepatic artery. Effluent hepatic venous blood is filtered before being returned to the systemic circulation, thereby reducing exposure to chemotherapy. We describe our experiences with chemosaturation-PHP at 2 European centers.

Materials and Methods: 14 patients presented unresectable hepatic metastases from solid tumors; 13 received 1–3 sessions of chemosaturation-PHP. Melphalan 2.0 (n=1) or 3.0 (n=12) mg/kg was given as a 30-minute infusion into the hepatic artery. 12 patients were evaluable for tumor response.

Results: One complete (cholangiocarcinoma, n=1) and 6 partial responses (ocular, n=3 or cutaneous melanoma, n=3) were observed, 5 patients had stable disease (ocular melanoma, n=3; breast cancer, n=1; gastric cancer, n=1). Mild to moderate filter-related toxicity (i.e. thrombocytopenia, anemia) was observed immediately post-procedure. Grade 3/4 melphalan-related pancytopenia developed after 1–2 weeks. All hematological events were managed effectively with transfusions and/or other supportive measures. The new high-efficiency filter showed milder toxicity and faster recovery. In one case, chemosaturation-PHP was abandoned prematurely due to heparin-induced vaginal bleeding, and one patient died due to retroperitoneal hemorrhage from heparin anti-coagulation.

Conclusion: Chemosaturation-PHP for non-resectable liver metastases is a feasible treatment option when performed by an experienced mul-

received 20.2.2013
accepted 26.12.2013

Bibliography

DOI <http://dx.doi.org/10.1055/s-0034-1366081>
Published online: 11.4.2014
Fortschr Röntgenstr 2014; 186: 937–944 © Georg Thieme Verlag KG Stuttgart · New York · ISSN 1438-9029

Correspondence

Prof. Thomas J. Vogl

Institut für Diagnostische und Interventionelle Radiologie,
J. W. Goethe-Universität
Frankfurt
Theodor-Stern Kai 7
60596 Frankfurt
Germany
Tel.: ++49/69/63 01 72 77
Fax: ++49/69/63 01 72 58
T.vogl@em.uni-frankfurt.de

vaginalen Blutung vorzeitig abgebrochen werden und ein Patient starb aufgrund retroperitonealer Blutung unter Heparinantikoagulation.

Schlussfolgerung: Chemosaturation-PHP nicht resektabler Lebermetastasen ist eine geeignete Behandlungsoption, die von einem erfahrenen, multidisziplinären Team durchgeführt werden kann. Es scheint ein aussichtsreiches regionales Verfahren für Patienten ohne andere effektive Behandlungsmöglichkeiten zu sein.

Introduction

The liver has a unique dual blood supply which makes regional treatment possible. Whereas normal hepatocytes receive their blood primarily from the portal vein, liver tumors are supplied almost exclusively (up to 95%) by the hepatic artery [1]. This allows isolation of the hepatic arterial inflow and venous outflow, and selective delivery of cytotoxic drugs to unresectable liver metastases while sparing healthy liver tissue. Regional chemotherapy procedures include hepatic arterial infusion, percutaneous hepatic perfusion, transarterial (chemo)embolization (TACE) and selective internal radiation therapy [2].

Chemosaturation with percutaneous hepatic perfusion (chemosaturation-PHP) has been developed as a minimally invasive and repeatable regional therapy. It relies on placing a unique double-balloon catheter percutaneously into the inferior vena cava to isolate the hepatic venous blood. High doses of chemotherapy can then be infused directly into the hepatic artery. A fenestrated section in the double-balloon catheter allows the isolated hepatic blood to be filtered extra-corporeally before being returned to the systemic circulation. The feasibility of chemosaturation-PHP has been shown in several studies of patients with unresectable hepatic metastases or primary hepatic cancer [4–9].

Chemosaturation-PHP has been developed commercially (Hepatic CHEMOSAT® Delivery System; Delcath Systems Inc., New York, NY) to make the procedure simpler and more widely accessible. A formal clinical trial program for the Hepatic CHEMOSAT® Delivery System is ongoing; phase I [9], II [10, 11] and III studies [12, 13] have recently been completed. The phase I study established that melphalan 3.0 mg/kg was the maximum tolerated dose deliverable by chemosaturation-PHP [9]. An overall response rate (i. e., complete plus partial response) of 50% was also documented in patients with metastatic ocular melanoma [9]. These favorable results prompted a randomized multicenter phase III trial comparing chemosaturation-PHP delivery of melphalan with best alternative care (BAC) in 93 patients with unresectable hepatic metastases from ocular or cutaneous melanoma. When compared with BAC, chemosaturation-PHP was associated with a significant 6.5-month improvement in hepatic progression-free survival, the primary study endpoint (median 8.1 vs. 1.6 months with BAC; hazard ratio 0.34; $p < 0.0001$) [13].

Melphalan was selected as the chemotherapeutic agent for the formal clinical trial program of the Hepatic CHEMOSAT® Delivery System on the basis of several observations. Firstly, it does not cause significant liver toxicity even when given at myeloablative doses [14, 15]. Secondly, melphalan delivered by operative isolated hepatic perfusion has previously shown efficacy in patients with hepatic metastases from a variety of cancers, including melanoma [16–19], colorectal cancer [20–22], hepatocellular carcinoma [23], and neuroendocrine tumors [24]. These data show that the melphalan doses deliverable by hepatic perfusion are adequate for efficacy against a range of solid tumors. Lastly, mel-

ti-disciplinary team. It may be a promising regional therapy for patients with no effective treatment options.

Citation Format:

► Vogl TJ, Zangos S, Scholtz JE et al. Chemosaturation with Percutaneous Hepatic Perfusion of Melphalan for Hepatic Metastases: Experience from Two European Centers. *Fortschr Röntgenstr* 2014; 186: 937–944

phalan is widely available and relatively inexpensive, making it an accessible choice for clinics around the world.

The purpose of the present article is to describe our experiences with the Hepatic CHEMOSAT® Delivery System in patients with unresectable hepatic metastases treated at two European centers. It describes the first patients treated in Europe with this delivery system. In addition, a second-generation high-efficiency filter was approved for use in conjunction with the Hepatic CHEMOSAT® Delivery System in Europe in 2012. The phase I, II and III clinical trials were performed using the first-generation filter, so the present report includes the first clinical data with the new filter.

Patients and Methods

Patients

Between January 2012 and February 2013, 14 consecutive patients with unresectable hepatic metastases from various solid tumors underwent chemosaturation-PHP with melphalan at the Frankfurt University Hospital ($n = 7$) and the European Institute of Oncology in Milan ($n = 7$). Both centers adhered to the Hepatic CHEMOSAT® Delivery System product instructions with regard to contraindications and precautions. Data evaluation was performed retrospectively.

Pre-procedural assessments

Prior to treatment, a physical examination, laboratory tests, and comprehensive imaging including computed tomography (CT) of the thorax and abdomen, upper abdominal magnetic resonance imaging (MRI) and, if clinically indicated, a brain MRI, bone scintigraphy or positron emission tomography (PET) scan were performed. The day before (Frankfurt) or the same day (Milan) of treatment, a complete visceral angiogram was performed to identify potential variant vascular anatomy. Embolization of selected arterial branches supplying the gastrointestinal tract was performed as needed to avoid inadvertent administration of chemotherapy into gastrointestinal or visceral arterial branches.

Treatment

Patients received melphalan delivered using the Hepatic CHEMOSAT® Delivery System (► Fig. 1). The procedure was performed under general anesthesia in an interventional radiology suite. Melphalan was given at a dose of 3.0 mg/kg ideal body weight (maximum 220 mg/treatment) as a 30-minute infusion into the hepatic artery. Venous effluent blood was filtered via the extracorporeal hemofiltration circuit during and for 30 minutes after each infusion. Percutaneous venous access was performed under ultrasound guidance in order to reduce the number of puncture attempts and any possible cause of bleeding. Heparin (400 IU/kg body weight) was administered during the procedure to ensure free extracorporeal flow and filtration.

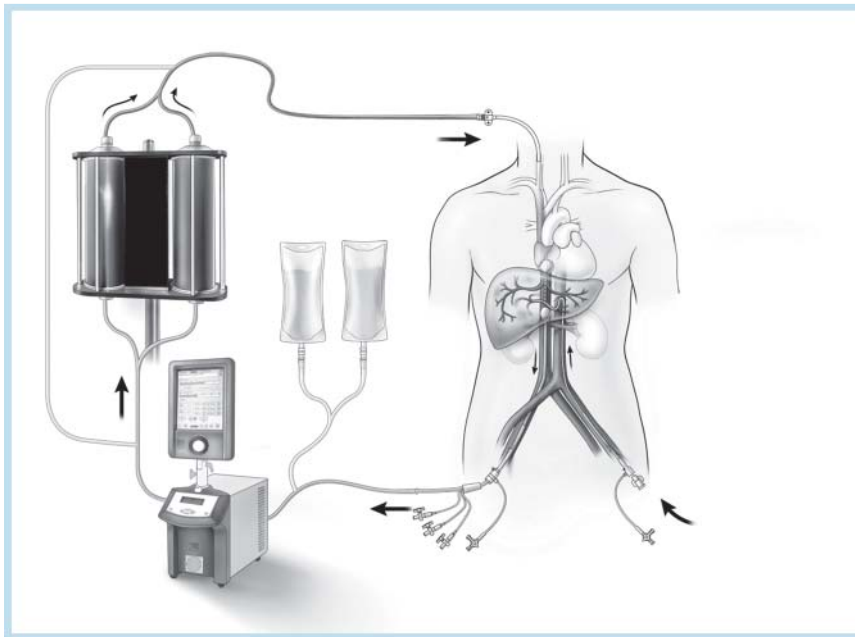


Fig. 1 Schematic diagram of the chemosaturations-PHP delivery system (Hepatic CHEMOSAT® Delivery System; Delcath Systems Inc., New York, NY) which consists of a closed circuit of catheters and filters designed to deliver chemotherapy to the hepatic artery and then filter effluent hepatic venous blood before it is returned to the systemic circulation.

Abb. 1 Schematische Darstellung des Chemosaturations-PHP Zuführsystems (Hepatic CHEMOSAT® Delivery System; Delcath Systems Inc., New York, NY) bestehend aus einem geschlossenen Kreislauf aus Kathetern und Filtern, welches der Infusion der Chemotherapie in die Leberarterie dient sowie das hepatisch venöse Blut filtert, bevor es in den systemischen Kreislauf zurückgeführt wird.

Response and toxicity

CT, MRI and/or PET scans of the liver were performed at 4- to 8-week intervals. Tumor response of liver lesions was assessed using RECIST criteria [25]. Systemic and local adverse events were classified by the National Cancer Institute Common Terminology Criteria for Adverse Events, version 3.0. Only systemic events (which did not normalize within 24 hours) and elevations of hepatic transaminases (which did not normalize within 7 days) were reported.

Results



Patients

Patient demographics and tumor characteristics are shown in **Table 1**. Patients had ocular (n=8) or cutaneous melanoma (n=3), breast cancer (n=1), gastric cancer (n=1) and cholangiocarcinoma (n=1). All patients, except for 1, had metastases confined to the liver. All patients had disease progression despite receiving a range of other treatments for hepatic metastases.

Chemosaturations-PHP

13 patients received treatment; melphalan was not administered in 1 patient because of vaginal bleeding. Patients treated in Frankfurt received a single chemosaturations-PHP treatment, and patients treated in Milan received 1–3 treatments. A total of 18 (Frankfurt, n=6; Milan n=12) chemosaturations-PHP procedures were performed. The interval between repeat treatments ranged from 57–177 days. The recommended melphalan dose of 3 mg/kg was given in all patients but one who received a 2 mg/kg dose because of aberrant hepatic vascularization.

The first-generation filter only was used in 3 patients (Frankfurt, n=2; Milan n=1), the second-generation filter only was used in 7 patients (Frankfurt, n=4, Milan, n=3), and 3 patients (Milan, n=3) were treated using the first-generation filter for their first treatment and the second-generation filter for repeat treatment(s).

Table 1 Baseline characteristics.

Tab. 1 Angaben zu Behandlung und Patienten.

	Frankfurt (n = 7)	Milan (n = 7)	total (n = 14)
<i>gender, n</i>			
male	4	3	7
female	3	4	7
<i>age, years</i>			
median	53	54	54
range	43–64	43–74	43–74
<i>primary tumor, n</i>			
ocular melanoma	5	3	8
cutaneous melanoma	1	2	3
gastric cancer	0	1	1
breast cancer	1	0	1
cholangiocarcinoma	0	1	1
extrahepatic disease, n	1	0	1
<i>eastern cooperative oncology group status</i>			
0	7	7	14
<i>karnofsky index</i>			
100 %	7	7	14
<i>child-pugh score</i>			
a	7	7	14
<i>prior therapy for hepatic metastases, n</i>			
transarterial chemoembolization	4	1	5
systemic chemotherapy	4	6	10
hepatic resection	3	1	4
microwave ablation	1	0	1
selective internal radiotherapy	1	0	1
radiofrequency ablation	1	1	2

Procedural care

Frankfurt experience

Preprocedural embolization was necessary in 6 patients because gastroduodenal artery (GDA) branches were close to the proper hepatic artery. In one patient with metastases in both liver lobes, chemotherapy was injected into the right hepatic artery rather than the proper hepatic artery to avoid unwanted infusion of

the gastrointestinal vessels. One patient developed hepatic arterial spasm during the angiogram which was treated successfully with intra-arterial glyceryl trinitrate 0.6 mg. On inflation of the occlusion balloons and establishment of the hemofiltration circulation, transient hypotension was seen in all patients. The median total procedure time was 225 (range, 145–270) minutes. The average venovenous bypass time was 74 (range, 68–81) minutes which included positioning and inflation of the occlusion balloons, the melphalan infusion and washout period.

Milan experience

Preprocedural embolization was performed in 6 patients. GDA coiling was necessary in 2 patients because the proper hepatic artery was very short. Right gastric artery embolization was also necessary in 1 of these patients. 3 patients underwent embolization of the right phrenic arteries. In all patients but one, superselective drug injection was achieved by separately cannulating the left and right arteries. One of the patients in whom the hepatic infusion system had previously been implanted was treated separately through the left and right hepatic arteries because of the presence of new tiny vessels from a previously coiled GDA, feeding the duodenum and pancreas.

Hospitalization

Frankfurt experience

After chemosaturatation-PHP, patients were kept in the intensive care unit (ICU) or recovery room and transferred to the ward within a maximum of 24 hours when no complications occurred. Patients remained in the hospital for 4–8 days.

Milan experience

After treatment, all patients were admitted to the ICU for an average of 12 hours, except for one patient who died in the ICU 30 hours post-treatment. There was no difference between the first- and second-generation filters in terms of hospital stay (average 5.5 days).

Tumor response

1 complete response (Milan, n=1) and 6 partial responses (Frankfurt, n=2; Milan, n=4) according to RECIST criteria were observed. Stable disease was documented in a further 5 patients (Frankfurt, n=4; Milan, n=1). 2 patients were not evaluable for tumor response (procedure abandoned because of vaginal bleeding, Frankfurt, n=1; patient died shortly after treatment, Milan, n=1).

Frankfurt experience

One patient with cutaneous melanoma and multiple liver metastases (diameter ≤ 20 mm) had a tumor response (tumor volume decrease 95%) after one chemosaturatation-PHP treatment (Fig. 2). The residual tumor was treated successfully with vemurafenib plus laser-induced thermotherapy (LITT). On the MRI scan 3 months after chemosaturatation-PHP, no more perfused tumor was visible. The patient remained tumor-free for 10 months; disease recurrence (>50 hepatic lesions) was documented 13 months after treatment. Another patient with multiple liver metastases from ocular melanoma had a partial response (Fig. 3). Stable disease (tumor volume decrease $<5\%$) was observed in a patient with hepatic and bone metastases from breast cancer. Two months after chemosaturatation-PHP, the follow-up MRI scan

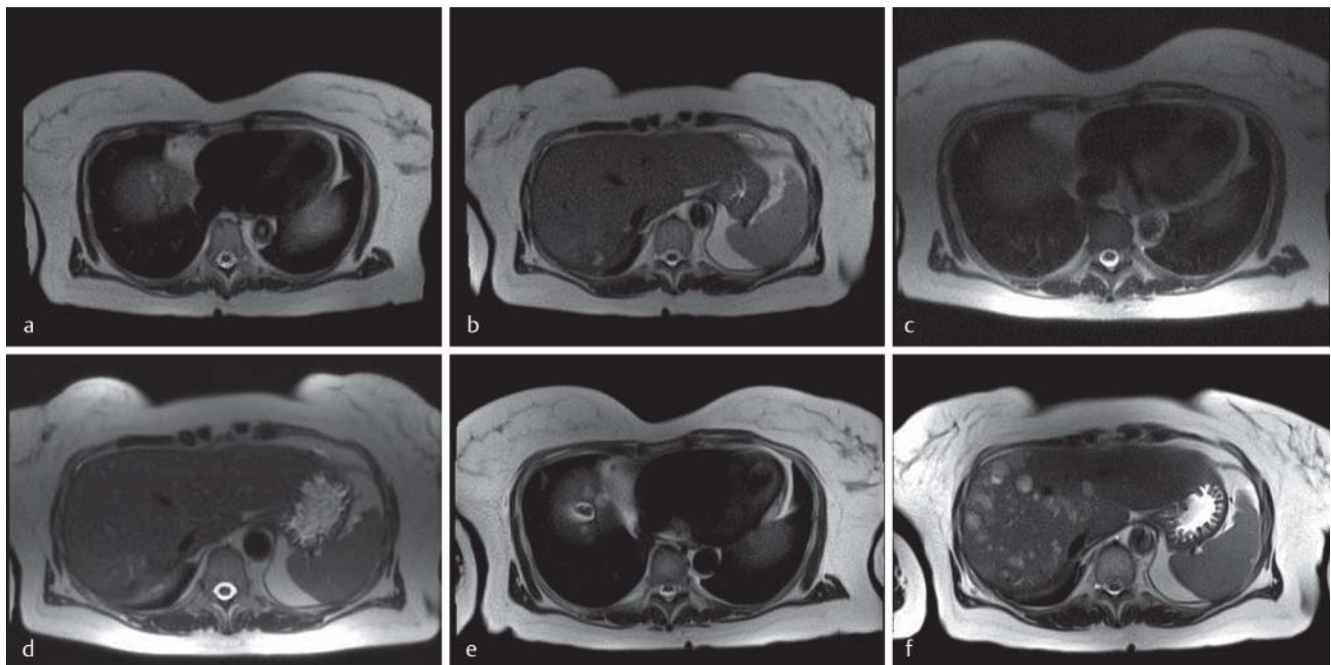


Fig. 2 Magnetic resonance images (T2 haste) of a patient with diffuse liver metastases from malignant melanoma **a, b** and the corresponding images taken 4 weeks after chemosaturatation-PHP **c, d** with significant reduction in the size of the metastases (partial response). After two treatments with laser-induced thermotherapy, full hepatic remission, which lasted for 10 months, occurred. Regional disease recurrence (>50 single lesions) was documented 13 months after treatment **e, f**.

Abb. 2 MRT-Bilder (T2 haste) eines Patienten mit diffusen Lebermetastasen eines malignen Melanoms **a, b** und die entsprechenden Bilder 4 Wochen nach der Chemosaturatation-PHP **c, d** mit deutlicher Größenreduktion der Metastasen (partielle Remission). Nach zweimaliger Behandlung des Restbefundes mittels laserinduzierter Thermotherapie zeigte sich eine hepatische Vollremission, welche für 10 Monate andauerte. Dann entwickelte der Patient 13 Monate nach der Behandlung ein regionales Rezidiv mit mehr als 50 Einzelläsionen **e, f**.

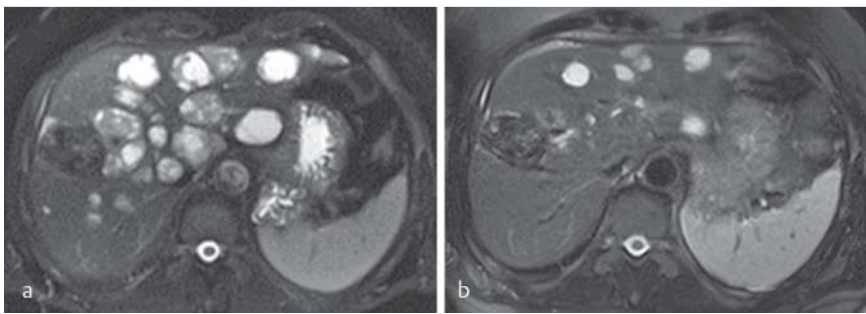


Fig. 3 Magnetic resonance images (T2 haste) pre-treatment **a** and 8 weeks post-treatment **b** of a patient with metastatic ocular melanoma. The liver metastases showed a reduction in size of over 30% (partial response).

Abb. 3 MRT-Bilder (T2 haste) vor **a** und 8 Wochen nach der Behandlung **b** eines Patienten mit metastasiertem Aderhautmelanom. Die Lebermetastasen zeigen eine Größenreduktion von über 30% (partielle Remission).

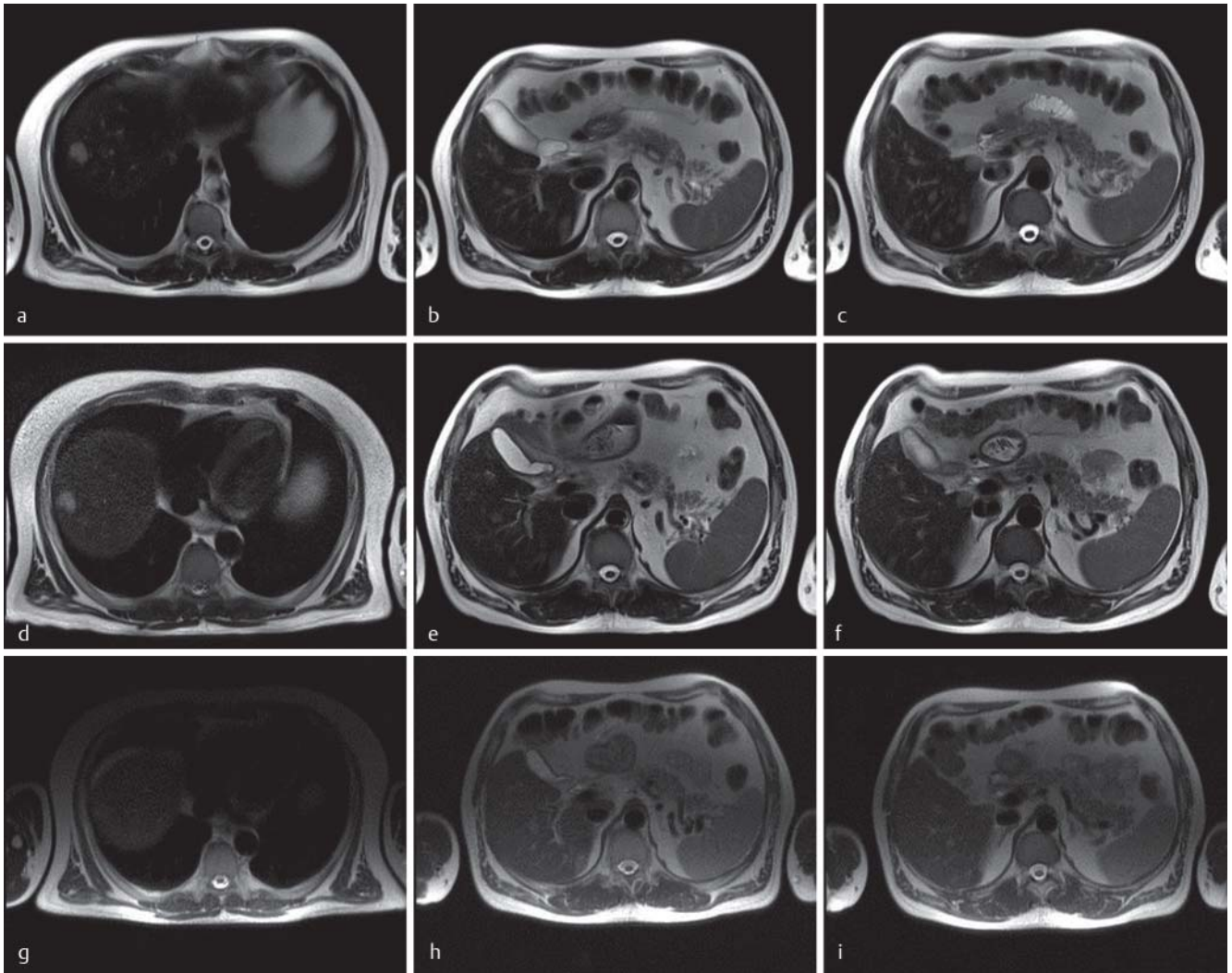


Fig. 4 Magnetic resonance images (T2 haste) of the liver of a patient with ocular melanoma who was treated with chemosaturation-PHP with melphalan **a–c**. Stable disease of diffuse small metastases was observed 8 weeks after treatment **d–f**. Without any further therapy, the patient had a partial response in the liver 6 months after chemosaturation-PHP **g–i**.

Abb. 4 MRT-Bilder (T2 haste) einer Leber von einem Patienten, der mittels Chemosaturation-PHP mit Melphalan behandelt wurde **a–c**. 4 Wochen nach der Behandlung wurde eine stabile Situation diffuser kleiner Metastasen beobachtet **d–f**. Ohne weitere Therapiemaßnahmen wies der Patient 6 Monate nach der Chemosaturation-PHP eine partielle Remission in der Leber auf **g–i**.

showed disease progression in the liver. Ten months after treatment, the patient died from progression of liver metastases. The remaining 3 patients with stable disease had ocular melanoma. Two months after chemosaturation-PHP, stable disease was maintained in 1 patient. Without any further therapy, the follow-up 6 months post-treatment imaging showed a partial re-

sponse which is still ongoing 2 months later (◉ **Fig. 4**). In another patient with bilobar disease, melphalan was infused only into the right hepatic artery, and complete hepatic perfusion was not achieved. Tumor response was evaluated only in the perfused right hepatic lobe (◉ **Fig. 5**). The first follow-up after treatment showed stable disease in the right liver lobe and disease progres-

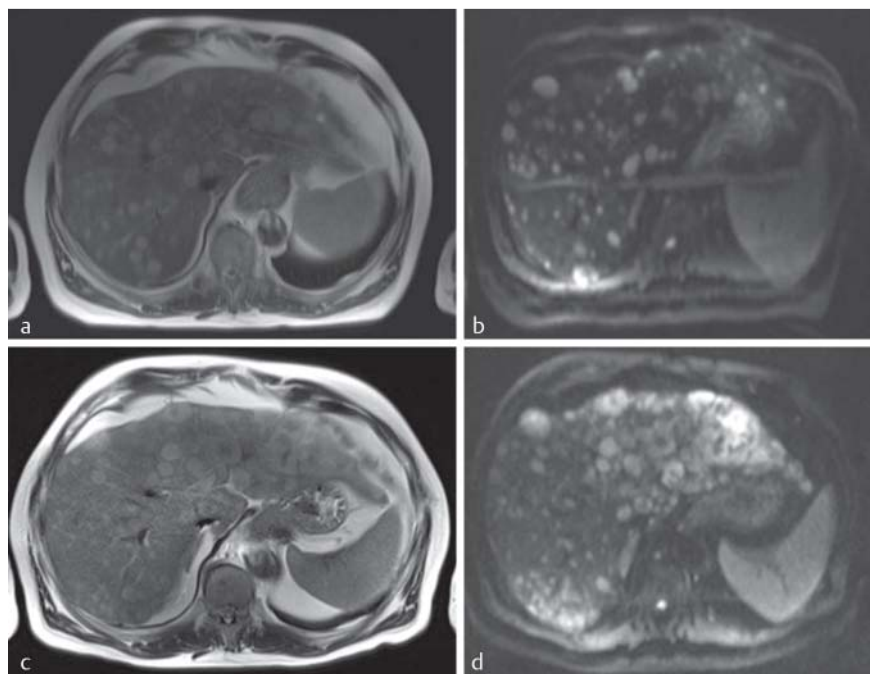


Fig. 5 Magnetic resonance images (MRI) of a 64-year-old man with metastatic ocular melanoma **a, b**. Due to vascular abnormalities, only the right liver lobe was treated with a single chemosaturation-PHP treatment. The postoperative MRI scans **c, d** showed stable disease in the right lobe, whereas disease progression occurred in the left lobe. (**a, c**: T2-haste, **b, d**: T2-TSE).

Abb. 5 MRT-Aufnahmen eines 64-jährigen Mannes mit metastasiertem Aderhautmelanom **a, b**. Aufgrund vaskulärer Anomalien wurde nur der rechte Leberlappen in einer einzelnen CS-PHP-Behandlung therapiert. Die postoperativen MRT-Aufnahmen **c, d** zeigten „stable disease“ – Status im rechten Leberlappen bei gleichzeitigem Krankheitsfortschritt im linken Leberlappen. (**a, c**: T2-haste, **b, d**: T2-TSE).

sion in the untreated left lobe. The left lobe was subsequently treated with TACE. However, disease progression in both liver lobes was documented after 2 months and the patient died shortly afterwards. In the other patient with metastatic ocular melanoma, the left and right hepatic arteries were cannulated separately and the right liver lobe was perfused with 2/3 of the melphalan dose and the left one with the remaining 1/3. One month after chemosaturation-PHP, stable disease was seen in the right liver lobe, whereas disease progression occurred in the left lobe. A follow-up scan 2 months post-treatment showed progressive disease in the whole liver. The patient died 6 months after treatment from massive progression of liver metastases.

Milan experience

Of the 6 patients evaluable for response, 1 patient with biliary tract adenocarcinoma achieved complete remission 6 months after chemosaturation-PHP. 2 patients with ocular melanoma had partial responses (MRI and PET) after the first of 3 sessions of chemosaturation-PHP. One of these patients remained stable with minimal disease after 2 further sessions (MRI/PET-negative but some small nodules visible). The other patient showed disease progression in the liver and bones after the third procedure, 1 year after the first session. One patient with cutaneous melanoma showed a partial response (MRI and PET) after the first chemosaturation-PHP session. The patient then received 4 courses of ipilimumab and recently had a second chemosaturation-PHP session. One patient with gastric cancer had a mixed response due to parasitic hepatic arteries that were not included during chemoperfusion. He had 3 consecutive liver resections before chemoperfusion. A huge portion of liver parenchyma, close to the previous resections, was fed by several arteries from the intercostal and mammary arteries. Lesions located within the non-perfused hepatic parenchyma grew after treatment, while metastases within the chemoperfused parenchyma showed a partial response. Because it was not possible to manage this kind of hepatic vascular supply, a second chemosaturation-PHP session was not scheduled. One patient with cutaneous melanoma

had a mixed response after the first perfusion, due to the growth of some lesions deep within segment 7, located under the dome. A phrenic artery feeding that area was occluded immediately before the second session and a partial response was documented in all target liver lesions (tumor volume reduction > 40%). Unfortunately, this patient subsequently developed multiple lung metastases.

Toxicity Frankfurt experience

In the 2 patients treated with the first-generation filter, both developed grade 1/2 increases in liver transaminases in the first 2 days after chemosaturation-PHP; all values returned to baseline levels within 1 week. Grade 1/2 fatigue, nausea and fever within the first 5 days after treatment were also reported. In both patients, grade 1/2 bone marrow suppression was observed initially. However, nadir blood cell counts were reached after 11–12 days and both patients were hospitalized for 8–9 days because of grade 3/4 pancytopenia. Grade 3/4 leukocytopenia was treated with filgrastim for 8–9 days in both patients, and antibiotics were required in 1 patient. Platelet transfusions were required for grade 3/4 thrombocytopenia (n=2), and 2 units of packed red blood cells (RBC) were required for grade 3 anemia (n=1). Of the 4 patients treated with the new filter system, 1 patient developed grade 1/2 pancytopenia after treatment which worsened to grade 3/4 pancytopenia after 1 week necessitating hospitalization for 6 days. However, only the leukocytopenia required treatment (filgrastim for 3 days plus an antibiotic). The second patient received a lower dose of melphalan and, with the exception of grade 1 anemia, did not experience any systemic adverse events. The last 2 patients both developed grade 1 anemia, grade 3/4 leukocytopenia and grade 2 or 4 thrombocytopenia and were treated as outpatients with platelet concentrates. Granulocyte colony-stimulating factor (G-CSF) was given for 4 days. No significant increases in transaminases occurred.

A premenopausal patient developed vaginal bleeding after systemic heparinization. Treatment was stopped before melphalan

administration. A gynecological examination showed that the event was most likely caused by heparin-induced bleeding of the endometrium. The patient recovered without sequelae.

Milan experience

Four patients were treated with the first-generation filter and all of them required multiple platelet and/or RBC transfusions after the procedure. One patient had grade 4 leukocytopenia, grade 3 anemia and grade 4 thrombocytopenia; the patient developed febrile neutropenia was admitted to the hospital to receive intravenous antibiotics and other support therapies. Three patients developed grade 4 leukocytopenia, grade 2/3 anemia and grade 1 or 4 thrombocytopenia which required transfusions without hospitalization. All of these patients had grade 2/3 fatigue and received filgrastim for at least 10 days. 3 of these 4 patients underwent 1–2 more sessions of chemoperfusion with the second-generation filter. These procedures were associated with markedly reduced hematological toxicity (grade 1 anemia) without any need for blood or platelet transfusions; G-CSF was required for 4 days only. All 3 patients experienced milder fatigue (grade 1). Of the 3 patients treated with the second-generation filter only, a similar toxicity profile was evident in 1 patient, while another patient developed febrile pancytopenia requiring transfusions because of a hepatic vascular shunt that avoided drug filtering. No patient had significant liver dysfunction, and grade 1–2 liver toxicity related to drug exposure was not influenced by the type of filter used. The remaining patient, who had a large fast-growing liver metastasis from ocular melanoma, died of a retroperitoneal giant hematoma 30 hours after chemosaturation-PHP. A *post-mortem* necropsy revealed multisite vascular bleeding with no damage to the inner surface of the abdominal veins and arteries. This unusual complication was most likely related to heparin which was needed for extracorporeal circulation.

Discussion

Chemosaturation-PHP is a minimally invasive, repeatable technique which delivers high doses of chemotherapy directly to tumors in the liver while limiting systemic toxicity through hemofiltration of the hepatic venous blood. Recently completed clinical trials performed in the US confirm the efficacy of chemosaturation-PHP delivery of melphalan in the treatment of patients with hepatic metastases from melanoma [12, 13] and neuroendocrine tumors [10, 11].

Our experience with chemosaturation-PHP at the University Hospital Frankfurt and the European Institute of Oncology is supportive of the findings of the clinical trial program, although it is too early to make definitive statements about tumor response rates and patient survival. Still, the data offer a number of insights. A complete response was documented in 1 patient with cholangiocarcinoma and partial responses were observed in a further 6 patients with ocular or cutaneous melanoma, giving an overall response rate of 50% in the total patient sample (n = 14). Of note, one of the melanoma patients became tumor-free after further treatment with LITT plus vemurafenib. The response lasted for 10 months before a recurrence in the liver was detected. At the time of writing, this patient is still alive with progression of liver metastases. 4 of the other 5 melanoma patients are also alive 7 to 18 months after their first chemosaturation-PHP session; all of them had disease restricted to the liver but were in progression after previous treatments and

had no other therapeutic options (BRAF and C-kit wild type). The last melanoma patient died after 9 months. These observations compare favorably with the shorter median overall survival times typically reported in patients with liver metastases from cutaneous [26] or ocular melanoma [27, 28]. In addition, 5 other patients with ocular melanoma, gastric cancer or breast cancer experienced clear clinical benefit from the procedure, opening up the possibility of combining chemosaturation-PHP with other systemic treatments.

The toxicities observed in our patients were consistent with the profile of events documented in clinical trials [9, 11]. Mild to moderate filter-related toxicity, i.e. thrombocytopenia and anemia resulting from the removal of platelets and RBC by the hemofiltration system, was observed immediately after the procedure. Only patients treated with the first-generation filter needed platelet and RBC transfusions. Persistent and more severe melphalan-related pancytopenia tended to emerge later. Although these events were generally grade 3/4 in severity, they were predictable and were managed effectively in all patients with supportive measures. Transient increases in liver transaminases (grade 1/2) were also observed during the post-procedural period in some patients resulting from procedural manipulation of the liver rather than melphalan. In all cases, values returned to baseline levels within 1 week. Other systemic events were mild (nausea, vomiting, fever), apart from fatigue which significantly influenced patient performance after treatment with the first-generation filter. Two events were attributed to heparin which is routinely administered during chemosaturation-PHP to facilitate extracorporeal blood flow and hemofiltration. In one case the procedure was stopped prematurely due to vaginal bleeding, and in another case a perioperative death resulting from a retroperitoneal hematoma occurred.

In April 2012, a second-generation high-efficiency filter (98% bench-testing efficiency; Delcath Systems Inc., data on file) for use with the chemosaturation-PHP delivery system became commercially available in Europe. In Milan, three patients were treated initially with the first-generation filter and then switched to the new filter for repeated treatments, providing a unique opportunity to compare toxicities with the two systems. In these patients, toxicity with the new filter system was less severe and patients required fewer supportive measures (i.e., no transfusions, shorter courses of colony-stimulating factors, reduced fatigue). Further studies are required to confirm this positive trend. A phase III study to evaluate chemosaturation-PHP in the treatment of hepatocellular carcinoma is planned in Frankfurt, and the new filter system will also be investigated further.

In summary, chemosaturation-PHP for the treatment of non-resectable liver metastases is a feasible treatment option when performed by an experienced multi-disciplinary team. Hematological events, which are the predominant toxicities associated with chemosaturation-PHP, are predictable and manageable with appropriate supportive care. Based on our findings, we believe that chemosaturation-PHP is a promising technique for patients for whom there are no effective treatments.

Affiliations

- ¹ Department of Diagnostic and Interventional Radiology, University Hospital of Frankfurt
- ² Department of Dermatology, Venerology and Allergology, University Hospital of Frankfurt
- ³ Department of Medicine I, University Hospital of Frankfurt
- ⁴ Unit of Interventional Radiology, European Institute of Oncology, Milan
- ⁵ Department of Anesthesiology, Intensive Care Medicine and Pain Therapy, University Hospital of Frankfurt
- ⁶ Translational Research on Melanoma, European Institute of Oncology, Milan

References

- 1 *Breedis C, Young G.* The blood supply of neoplasms in the liver. *Am J Pathol* 1954; 30: 969–977
- 2 *Vogl TJ, Mack MG, Eichler K et al.* Chemoperfusion und -embolisation von Lebermetastasen [Chemoperfusion and embolization in the treatment of liver metastases]. *Fortschr Röntgenstr* 2011; 183: 12–23
- 3 *Beheshti MV, Denny DF Jr, Glickman MG et al.* Percutaneous isolated liver perfusion for treatment of hepatic malignancy: preliminary report. *J Vasc Interv Radiol* 1992; 3: 453–458
- 4 *Ravikumar TS, Pizzorno G, Bodden W et al.* Percutaneous hepatic vein isolation and high-dose hepatic arterial infusion chemotherapy for unresectable liver tumors. *J Clin Oncol* 1994; 12: 2723–2736
- 5 *Curley SA, Newman RA, Dougherty TB et al.* Complete hepatic venous isolation and extracorporeal chemofiltration as treatment for human hepatocellular carcinoma: a phase I study. *Ann Surg Oncol* 1994; 1: 389–399
- 6 *Hwu WJ, Salem RR, Pollak J et al.* A clinical-pharmacological evaluation of percutaneous isolated hepatic infusion of doxorubicin in patients with unresectable liver tumors. *Oncol Res* 1999; 11: 529–537
- 7 *van Etten B, Brunstein F, van Ijken MG et al.* Isolated hypoxic hepatic perfusion with orthograde or retrograde flow in patients with irresectable liver metastases using percutaneous balloon catheter techniques: a phase I and II study. *Ann Surg Oncol* 2004; 11: 598–605
- 8 *Verhoef C, de Wilt JH, Brunstein F et al.* Isolated hypoxic hepatic perfusion with retrograde outflow in patients with irresectable liver metastases; a new simplified technique in isolated hepatic perfusion. *Ann Surg Oncol* 2008; 15: 1367–1374
- 9 *Pingpank JF, Libutti SK, Chang R et al.* Phase I study of hepatic arterial melphalan infusion and hepatic venous hemofiltration using percutaneously placed catheters in patients with unresectable hepatic malignancies. *J Clin Oncol* 2005; 23: 3465–3474
- 10 *Pingpank JF, Royal RE, Kammula US et al.* High dose intra-arterial melphalan delivered via percutaneous hepatic perfusion (PHP) for patients with unresectable hepatic metastases from primary neuroendocrine tumors. Fort Lauderdale Florida, USA: American Hepato-Pancreato-Biliary Association Annual Meeting; 2008
- 11 *Pingpank J, Royal RE, Kammula US et al.* Percutaneous hepatic perfusion (PHP) with melphalan for patients with unresectable liver metastases of neuroendocrine tumors (MNET) – NCT000960083. *Eur J Cancer* 2011; 47: S478 (Suppl. 1, abstr 6621)
- 12 *Pingpank JF, Hughes MS, Faries MB et al.* A phase III random assignment trial comparing percutaneous hepatic perfusion with melphalan (PHP-mel) to standard of care for patients with hepatic metastases from metastatic ocular or cutaneous melanoma. *J Clin Oncol* 2010; 28 (suppl; abstr LBA8512)
- 13 *Pingpank JF, Hughes M, Alexander HR et al.* Percutaneous hepatic perfusion (PHP) vs. best alternative care (BAC) for patients (pts) with melanoma liver metastases – efficacy update of the Phase 3 Trial (NCT00324727). *Eur J Cancer* 2011; 47: S653 (Suppl 1, abstr 9304)
- 14 *Lazarus HM, Herzig RH, Graham-Pole J et al.* Intensive melphalan chemotherapy and cryopreserved autologous bone marrow transplantation for the treatment of refractory cancer. *J Clin Oncol* 1983; 1: 359–367
- 15 *Leff RS, Thompson JM, Johnson DB et al.* Phase II trial of high-dose melphalan and autologous bone marrow transplantation for metastatic colon carcinoma. *J Clin Oncol* 1986; 4: 1586–1591
- 16 *Alexander HR, Libutti SK, Bartlett DL et al.* A phase I-II study of isolated hepatic perfusion using melphalan with or without tumor necrosis factor for patients with ocular melanoma metastatic to liver. *Clin Cancer Res* 2000; 6: 3062–3070
- 17 *Alexander HR Jr, Libutti SK, Pingpank JF et al.* Hyperthermic isolated hepatic perfusion using melphalan for patients with ocular melanoma metastatic to liver. *Clin Cancer Res* 2003; 9: 6343–6349
- 18 *Noter SL, Rothbarth J, Pijl ME et al.* Isolated hepatic perfusion with high-dose melphalan for the treatment of uveal melanoma metastases confined to the liver. *Melanoma Res* 2004; 14: 67–72
- 19 *Rizell M, Mattson J, Cahlin C et al.* Isolated hepatic perfusion for liver metastases of malignant melanoma. *Melanoma Res* 2008; 18: 120–126
- 20 *van Iersel LB, Gelderblom H, Vahrmeijer AL et al.* Isolated hepatic melphalan perfusion of colorectal liver metastases: outcome and prognostic factors in 154 patients. *Ann Oncol* 2008; 19: 1127–1134
- 21 *Alexander HR Jr, Bartlett DL, Libutti SK et al.* Analysis of factors associated with outcome in patients undergoing isolated hepatic perfusion for unresectable liver metastases from colorectal center. *Ann Surg Oncol* 2009; 16: 1852–1859
- 22 *Rothbarth J, Pijl ME, Vahrmeijer AL et al.* Isolated hepatic perfusion with high-dose melphalan for the treatment of colorectal metastasis confined to the liver. *Br J Surg* 2003; 90: 1391–1397
- 23 *Feldman ED, Wu PC, Beresneva T et al.* Treatment of patients with unresectable primary hepatic malignancies using hyperthermic isolated hepatic perfusion. *J Gastrointest Surg* 2004; 8: 200–207
- 24 *Grover AC, Libutti SK, Pingpank JF et al.* Isolated hepatic perfusion for the treatment of patients with advanced liver metastases from pancreatic and gastrointestinal neuroendocrine neoplasms. *Surgery* 2004; 136: 1176–1182
- 25 *Therasse P, Arbuck SG, Eisenhauer EA et al.* New guidelines to evaluate the response to treatment in solid tumors. European Organization for Research and Treatment of Cancer, National Cancer Institute of the United States, National Cancer Institute of Canada. *J Natl Cancer Inst* 2000; 92: 205–216
- 26 *Rose DM, Essner R, Hughes TM et al.* Surgical resection for metastatic melanoma to the liver: the John Wayne Cancer Institute and Sydney Melanoma Unit experience. *Arch Surg* 2001; 136: 950–955
- 27 *Papastefanou VP, Cohen VML.* Uveal melanoma. *J Skin Cancer* 2011; 573974, Epub 2011 Jun 30
- 28 *Feldman ED, Pingpank JF, Alexander HR Jr.* Regional treatment options for patients with ocular melanoma metastatic to the liver. *Ann Surg Oncol* 2004; 11: 290–297