

Establishment of Functional and Molecular Ultrasound for Breast Cancer Xenograft Imaging

Etablierung von funktionellem und molekularem Ultraschall für die Bildgebung von Brustkrebsmodellen

Author

J. Bzyl

Affiliation

Institute for Experimental Molecular Imaging, RWTH Aachen University, Aachen

Key words

- breast
- ultrasound
- angiogenesis
- animal investigations

Zusammenfassung

Die vorliegende Arbeit wurde in European Radiology und als Dissertation an der RWTH Aachen veröffentlicht und wurde am Institut für Experimentelle Molekulare Bildgebung der RWTH Aachen durchgeführt.

Abstract

The present work was originally published in European Radiology and as a PhD thesis at the RWTH Aachen University and was conducted at the Institute for Experimental Molecular Imaging at the RWTH Aachen University.

Citation Format:

- ▶ Bzyl J. Establishment of Functional and Molecular Ultrasound for Breast Cancer Xenograft Imaging. Fortschr Röntgenstr 2014; 186: 377–379

This article was awarded with the Promotionspreis 2013

received 16.12.2013
accepted 10.2.2014

Bibliography

DOI <http://dx.doi.org/10.1055/s-0034-1366187>
Published online: 2014
Fortschr Röntgenstr 2014; 186: 377–379 © Georg Thieme Verlag KG Stuttgart · New York · ISSN 1438-9029

Correspondence

Frau Dr. Jessica Bzyl
Institute for Experimental Molecular Imaging, RWTH Aachen University
Pauwelsstraße 20
52074 Aachen
Germany
Tel.: ++49/241/8 08 01 16
Fax: ++49/241/8 03 38 20 06
jessica.bzyl@gmx.de

The present work was originally published in European Radiology [1, 2] and as a PhD thesis at the RWTH Aachen University [3] and was conducted at the Institute for Experimental Molecular Imaging at the RWTH Aachen University.

Among women, breast cancer is the most frequently diagnosed cancer worldwide. Accurate and sensitive imaging techniques are needed to help decrease the mortality rate by early detection of breast cancer. Contrast-enhanced ultrasound with non-targeted microbubbles in patients was shown to possibly help to predict prognosis and to noninvasively detect highly aggressive breast cancers [4]. This technique is called functional ultrasound. Due to their size of 2–5 µm, the microbubbles stay strictly intravascular and the relative blood volume (rBV) of a tumor can be determined, reflecting its angiogenic activity and thus, the tumor's aggressiveness. A further technique for the characterization of the breast cancer's aggressiveness may be molecular ultrasound imaging. The microbubbles, now targeted to tumor-endothelial angiogenic markers, bind to their specific target upon injection and a relative quantification of marker expression within the tumor endothelium can be performed noninvasively. In the present work two types of microbubbles were used [1, 2]. For molecular ul-

trasound this was BR55. A heterodimer selectively binding to human and murine vascular endothelial growth factor receptor type 2 (VEGFR-2) was conjugated to DSPE-PEG-2000-NH₂ which was then incorporated into the microbubbles' lipid shell. A detailed description can be found in [5]. VEGFR-2 is one of the most characterized tumor-angiogenic markers. For functional ultrasound BR38 was applied, consisting of non-targeted, PEGylated microbubbles, i.e. microbubbles with a Polyethylenglycol (PEG) brush. Their lipid shell contains DPPE-MPEG 5000 that contributes to a long persistence of the microbubbles in the blood system [6]. Both, BR38 and BR55 were designed for clinical application.

In the first study the circulating characteristics of BR55 and BR38 microbubbles in healthy mice and their ability to characterize the angiogenic activity of differently aggressive human breast adenocarcinomas were evaluated [1]. BR38 showed a long blood half-life of more than ten minutes and a relatively slow uptake by the liver. For clinical use the long circulation time of BR38 might be beneficial because it allows an intensive examination of one or even several different organs. The VEGFR-2 targeted BR55 microbubbles had a relatively short blood half-life of about 4 min. An early accumulation of these microbubbles was ob-

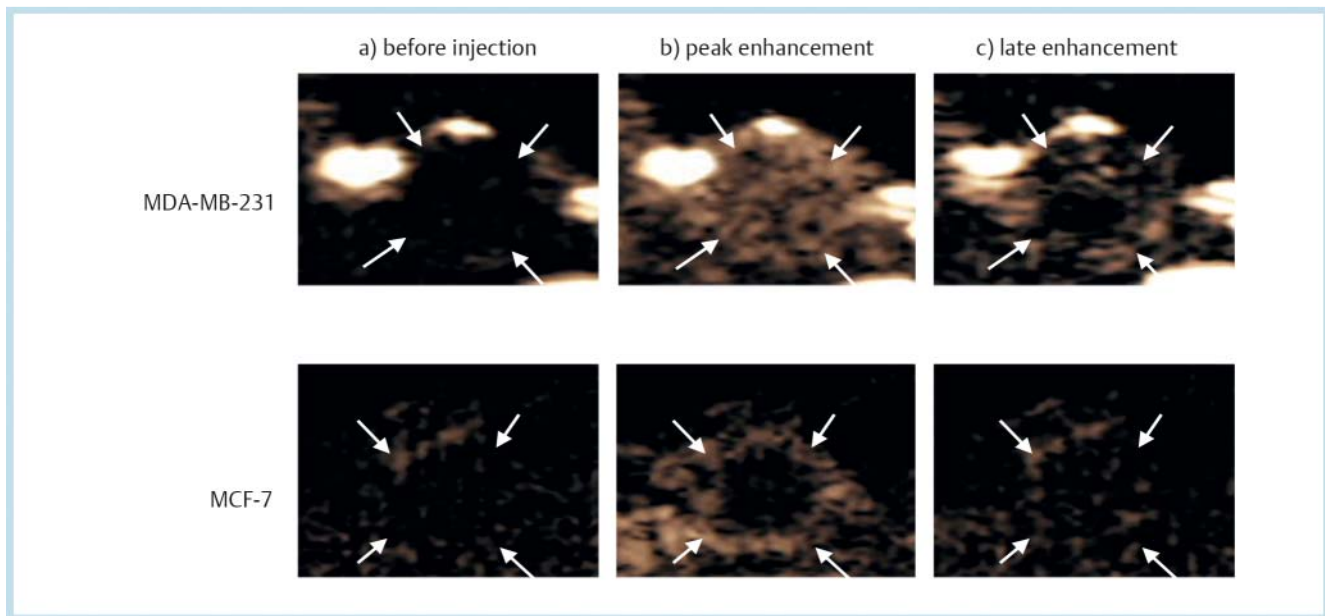


Fig. 1 Ultrasound images showing s. c. breast cancer xenografts before **a)** and after injection of BR55 microbubbles. There is a higher peak enhancement in more aggressive MDA-MB-231 compared to less aggressive MCF-7 tumours approximately 1 minute after injection **b)** due to circulating microbubbles. Ten minutes after injection **c)** contrast enhancement is still higher in MDA-MB-231 and is mostly due to receptor bound BR55. Reproduced from: Jessica Bzyl, Wiltrud Lederle, Anne Rix, et al. (2011) Molecular and functional ultrasound imaging in differently aggressive breast cancer xenografts using two novel ultrasound contrast agents (BR55 and BR38). *Eur Radiol* 21(9): 1988 – 95.

Abb. 1 Ultraschallbilder von Brustkrebsmodellen vor **a)** und nach Injektion von BR55 Mikrobubbles. Etwa eine Minute nach Injektion **b)** war das Peak Enhancement in den aggressiveren MDA-MB-231 höher als in den weniger aggressiven MCF-7-Tumoren. Zehn Minuten nach Injektion **c)** ist die Kontrastverstärkung in MDA-MB-231 immer noch höher und resultiert aus rezeptorgebundenen BR55. Entnommen aus: Jessica Bzyl, Wiltrud Lederle, Anne Rix, et al. (2011) Molecular and functional ultrasound imaging in differently aggressive breast cancer xenografts using two novel ultrasound contrast agents (BR55 and BR38). *Eur Radiol* 21(9): 1988 – 95.

served in the liver which led to their rapid clearance from the blood. The fast elimination of freely circulating microbubbles is strongly desired in order to minimize background signals, as BR55 is designed to assess VEGFR-2 expression.

In highly aggressive, estrogen-independent MDA-MB-231 and less aggressive, estrogen-dependent MCF-7 breast cancer xenografts, both BR55 and BR38 proved to be very well suited for distinguishing and characterizing the different angiogenic activity. Although the more aggressive breast tumors showed a significantly higher rBV compared to the less aggressive model determined by functional ultrasound using BR38, the differences in the angiogenic activity between both tumor models were more distinct with the molecular information obtained with BR55 molecular ultrasound imaging (● Fig. 1). All data was validated by quantitative immunofluorescence.

In the second study 3-dimensional molecular and functional ultrasound imaging comprising the whole of small developing MCF-7 tumors of only 2 mm in diameter compared to larger tumors was performed [2]. Reliable imaging of the VEGFR-2 expression with BR55 microbubbles was possible for all tumor sizes (● Fig. 2). However, due to the particularly high VEGFR-2 expression in the smallest tumors, molecular ultrasound may detect micro-tumors even more sensitively than larger tumors. These results indicate that molecular ultrasound imaging may improve the detection of small invasive breast carcinomas, which are known to overexpress VEGFR2 on the endothelium [7]. In contrast, the degree of vascularization assessed by functional ultrasound with BR38 was more or less constant in all tumor sizes. This phenomenon was elucidated by immunofluorescence analysis which strongly indicated vessel maturation. Vessel maturation

is characterized by more stabilized vessels due to a close association of vessel supporting cells with the endothelium, like α -SMA-expressing pericytes. Furthermore, vessel maturation is characterized by the down-regulation of VEGFR-2 expression. In consequence, maturing vessels have an enlarged lumen resulting in a higher blood volume. Significantly enlarged and significantly more α -SMA positive vessels in larger tumors were observed. In addition, the number of vessels was decreased in the larger tumors compared to the 2 mm tumors, thus explaining the constant rBV for all tumor sizes measured by functional ultrasound. In conclusion, these two studies show how beneficial molecular ultrasound imaging with clinically applicable microbubbles might be in regards to a noninvasive characterization of breast cancer aggressiveness and an early detection of small breast lesions.

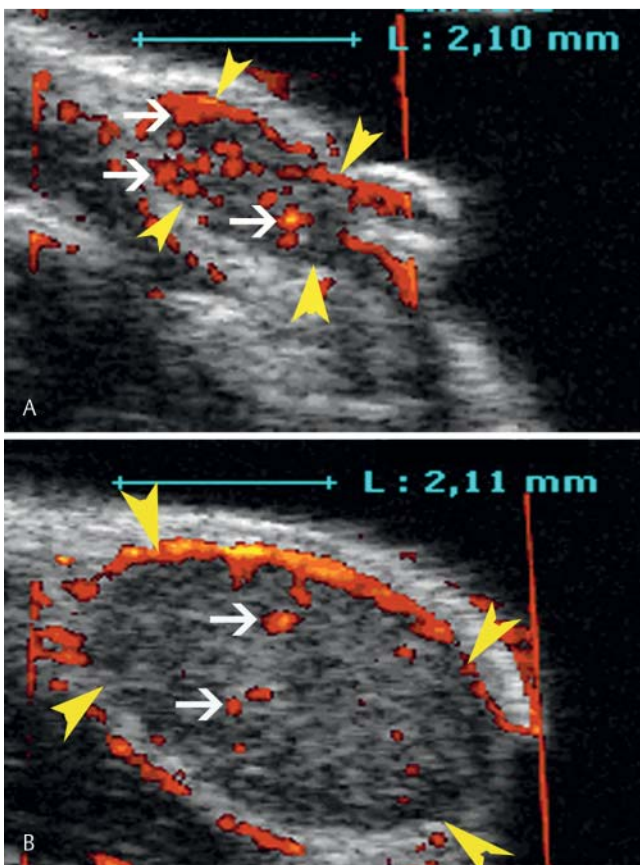


Fig. 2 Representative images of **A)** a 4 mm³ and **B)** a 34 mm³ MCF-7 tumor (arrowheads). On the contrast-enhanced image signals of BR55 microbubbles can be seen as an overlay (white arrows show representative signals). In the 4 mm³ tumors significantly more signals of BR55 microbubbles were detected compared with all other tumor sizes. Reproduced from: Jessica Bzyl, Moritz Palmowski, Anne Rix, et al. (2013) The high angiogenic activity in very early breast cancer enables reliable imaging with VEGFR2-targeted microbubbles (BR55). *Eur Radiol* 23(2): 468 – 75.

Abb. 2 Repräsentative Bilder **A)** eines 4 mm³ und **B)** eines 34 mm³ großen MCF-7-Tumors (Pfeilspitzen). In dem kontrastverstärkten Bild sind die Signale der BR55 Mikrobubbles dargestellt (weiße Pfeile deuten auf repräsentative Signale). In den 4 mm³ großen Tumoren konnten signifikant mehr BR55-Signale detektiert werden als in Tumoren aller anderen Größen. Entnommen aus: Jessica Bzyl, Moritz Palmowski, Anne Rix, et al. (2013) The high angiogenic activity in very early breast cancer enables reliable imaging with VEGFR2-targeted microbubbles (BR55). *Eur Radiol* 23(2): 468 – 75.

References

- 1 Bzyl J, Lederle W, Rix A et al. Molecular and functional ultrasound imaging in differently aggressive breast cancer xenografts using two novel ultrasound contrast agents (BR55 and BR38). *Eur Radiol* 2011; 21: 1988 – 1995
- 2 Bzyl J, Palmowski M, Rix A et al. The high angiogenic activity in very early breast cancer enables reliable imaging with VEGFR2-targeted microbubbles (BR55). *Eur Radiol* 2013; 23: 468 – 475
- 3 Bzyl J. Establishment of functional and molecular ultrasound imaging with novel, clinically translatable contrast agents for assessing the angiogenic status of two differently aggressive breast cancer xenografts. RWTH Aachen Library 2012
- 4 Wan CF, Du J, Fang H et al. Enhancement patterns and parameters of breast cancers at contrast-enhanced US: correlation with prognostic factors. *Radiology* 2012; 262: 450 – 459
- 5 Pillai R, Marinelli ER, Fan H. A phospholipid-PEG2000 conjugate of a vascular endothelial growth factor receptor 2 (VEGFR2)-targeting heterodimer peptide for contrast-enhanced ultrasound imaging of angiogenesis. *Bioconjug Chem* 2010; 21: 556 – 562
- 6 Schneider M, Anantharam B, Arditì M et al. BR38, a new ultrasound blood pool agent. *Invest Radiol* 2011; 46: 486 – 494
- 7 Smith NR, Baker D, James NH et al. Vascular endothelial growth factor receptors VEGFR-2 and VEGFR-3 are localized primarily to the vasculature in human primary solid cancers. *Clin Cancer Res* 2010; 16: 3548 – 3561