

Successful re-intervention with metal stent trimming using argon plasma coagulation after endoscopic ultrasound-guided hepaticogastrostomy

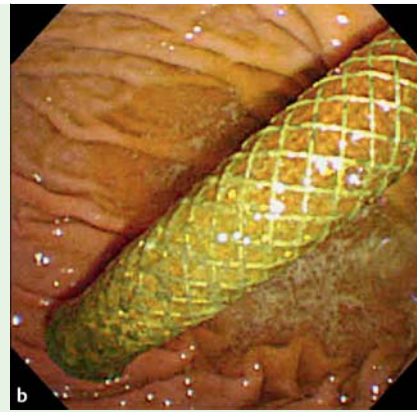
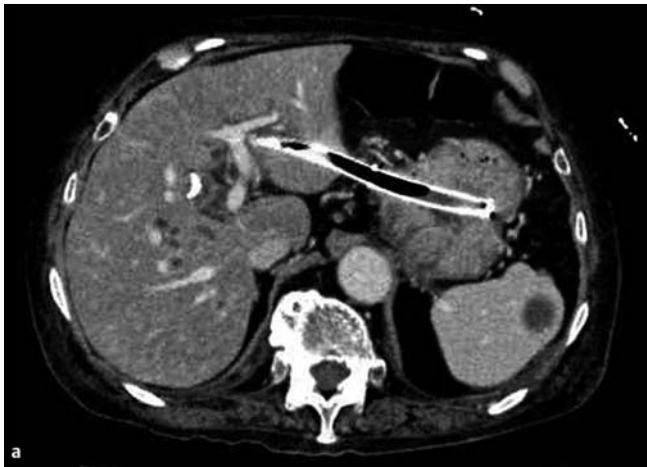


Fig. 1 Protrusion into the stomach of the long self-expandable metal stent (SEMS) used for endoscopic ultrasound-guided hepaticogastrostomy (EUS-HGS): **a** on computed tomography (CT) scan; **b** on endoscopy.

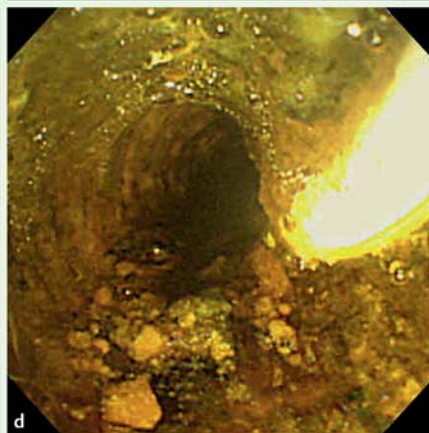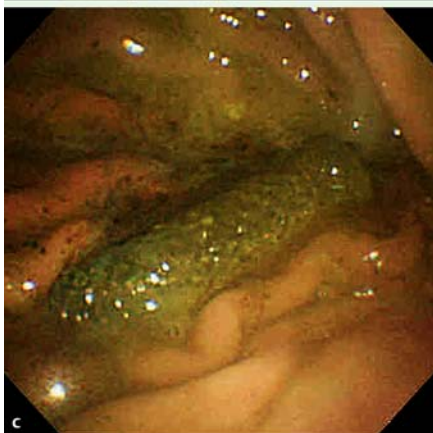
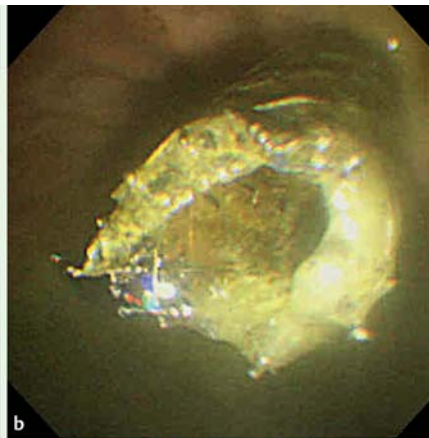
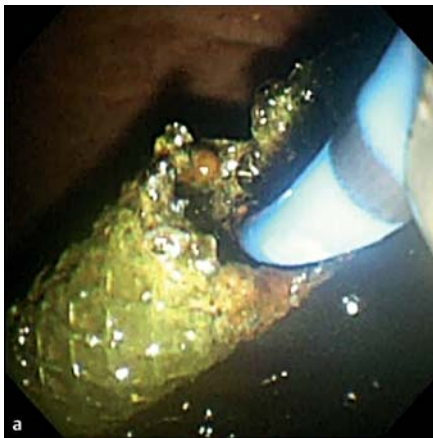


Fig. 2 Views during endoscopy showing: **a** the self-expandable metal stent (SEMS) being trimmed with argon plasma coagulation (APC); **b** the shortened SEMS in situ; **c** the fragment of SEMS, which was subsequently removed with grasping forceps; **d** the sludge being removed with a retrieval balloon after successful bile duct cannulation.

Recently, endoscopic ultrasound (EUS)-guided biliary drainage has been introduced as an alternative method after failed endoscopic biliary drainage, particularly in patients with a pre-existing duodenal obstruction [1–3]. A longer self-expandable metal stent (SEMS) is usually used for EUS-guided hepaticogastrostomy (EUS-HGS) to prevent stent migration. However, re-intervention after EUS-HGS is challenging because of the protrusion of the SEMS into the stomach. Metal stent trimming using argon plasma coagulation (APC) has been reported to be a useful option for stent-related complications such as dislocation [4,5]. We report a case in which successful re-intervention after EUS-HGS was made possible by metal stent trimming using APC. A nonagenarian woman with advanced ampullary cancer was admitted to our center. She had a history of endoscopic transpapillary bile duct stenting and duodenal stenting covering the papilla, followed by EUS-HGS with an 8-mm diameter, 12-cm long, silicone-covered nitinol braided stent, with a 1-cm uncovered portion at the proximal end (Niti-S biliary S-type; Taewoong Medical, Seoul, South Korea).

The patient developed recurrent cholangitis caused by sludge formation 3 months after HGS. As she showed a good performance status, we attempted therapeutic endoscopic intervention via the HGS site; however, intervention was difficult be-

cause of the protrusion of the long SEMS (● Fig. 1). Therefore, stent trimming was performed with APC using an electrosurgical generator (ICC200; ERBE Elektromedizin, Tübingen, Germany) (● Fig. 2a, b; ● Video 1). Subsequently, the fragment of SEMS was removed using grasping forceps through the scope channel (● Fig. 2c). Successful bile duct cannulation was achieved using a standard endoscopic retrograde cholangiopancreatography (ERCP) catheter and a 0.025-inch guidewire. The sludge in the bile duct was confirmed on a cholangiogram and was removed with a retrieval balloon catheter

Video 1

Trimming of the protruding long self-expandable metal stent (SEMS) was performed using argon plasma coagulation (APC).

Video 2

Successful bile duct cannulation was achieved using a standard endoscopic retrograde cholangiopancreatography (ERCP) catheter and a 0.025-inch guidewire. The sludge was removed with a retrieval balloon.

(● Fig. 2d; ● Video 2). Finally, a 5-Fr straight nasobiliary drainage tube was placed. The procedure was completed without any adverse events. Metal stent trimming using APC may be an effective option for re-intervention after EUS-HGS.

Endoscopy_UCTN_Code_TTT_1AR_2AZ

Competing interests: None

Kei Yane, Akio Katanuma, Hiroyuki Maguchi, Kuniyuki Takahashi, Manabu Osanai, Toshifumi Kin, Satoshi Ikarashi, Ryuki Minami, Manabu Sen-yo, Itsuki Sano, Hajime Yamazaki

Center for Gastroenterology,
Teine-Keijinkai Hospital, Sapporo, Japan

References

- 1 *Khashab MA, Fujii LL, Baron TH* et al. EUS-guided biliary drainage for patients with malignant biliary obstruction with an indwelling duodenal stent (with videos). *Gastrointest Endosc* 2012; 76: 209–213
- 2 *Khashab MA, Valeshabad AK, Leung W* et al. Multicenter experience with performance of ERCP in patients with an indwelling duodenal stent. *Endoscopy* 2014; 46: 252–225
- 3 *Ogura T, Masuda D, Imoto A* et al. EUS-guided hepaticogastrostomy combined with fine-gauge antegrade stenting: a pilot study. *Endoscopy* 2014; 46: 416–421
- 4 *Ishii K, Itoi T, Sofuni A* et al. Endoscopic removal and trimming of distal self-expandable metallic biliary stents. *World J Gastroenterol* 2011; 17: 2652–2657
- 5 *Hamada T, Nakai Y, Isayama H* et al. Trimming a covered metal stent during hepaticogastrostomy by using argon plasma coagulation. *Gastrointest Endosc* 2013; 78: 817

Bibliography

DOI <http://dx.doi.org/10.1055/s-0034-1377388>
Endoscopy 2014; 46: E391–E392
© Georg Thieme Verlag KG
Stuttgart · New York
ISSN 0013-726X

Corresponding author

Kei Yane, MD
Center for Gastroenterology
Teine-Keijinkai Hospital
1-jo 12-chome, Maeda, Teine-ku
Sapporo 006-8555
Japan
Fax: +81-11-6852967
k.yane3@gmail.com