

Diagnosis and management of iatrogenic endoscopic perforations: European Society of Gastrointestinal Endoscopy (ESGE) Position Statement



Authors

Gregorios A. Paspatis¹, Jean-Marc Dumonceau², Marc Barthet³, Søren Meisner⁴, Alessandro Repici⁵, Brian P. Saunders⁶, Antonios Vezakis⁷, Jean Michel Gonzalez³, Stine Ydegaard Turino⁴, Zacharias P. Tsiamoulos⁶, Paul Fockens⁸, Cesare Hassan⁹

Institutions

Institutions are listed at the end of article.

Bibliography

DOI <http://dx.doi.org/10.1055/s-0034-1377531>
Published online: 21.7.2014
Endoscopy 2014; 46: 693–711
© Georg Thieme Verlag KG
Stuttgart · New York
ISSN 0013-726X

Corresponding author

Gregorios A. Paspatis, MD
Gastroenterology Department
Benizelion General Hospital
Heraklion, Crete
Greece 71409
Fax: +30-2810-368018
gpaspatis@gmail.com

This Position Paper is an official statement of the European Society of Gastrointestinal Endoscopy (ESGE). It addresses the diagnosis and management of iatrogenic perforation occurring during diagnostic or therapeutic digestive endoscopic procedures.

Main recommendations

1 ESGE recommends that each center implements a written policy regarding the management of iatrogenic perforation, including the definition of procedures that carry a high risk of this complication. This policy should be shared with the radiologists and surgeons at each center.

2 In the case of an endoscopically identified perforation, ESGE recommends that the endoscopist reports: its size and location with a picture; endoscopic treatment that might have been possible; whether carbon dioxide or air was used for insufflation; and the standard report information.

3 ESGE recommends that symptoms or signs suggestive of iatrogenic perforation after an endoscopic procedure should be carefully evaluated and documented, possibly with a computed tomography (CT) scan, in order to prevent any diagnostic delay.

4 ESGE recommends that endoscopic closure should be considered depending on the type of perforation, its size, and the endoscopist expertise available at the center. A switch to carbon dioxide insufflation, the diversion of luminal content, and decompression of tension pneumoperitoneum or tension pneumothorax should also be done.

5 After closure of an iatrogenic perforation using an endoscopic method, ESGE recommends that further management should be based on the estimated success of the endoscopic closure and on the general clinical condition of the patient. In the case of no or failed endoscopic closure of the iatrogenic perforation, and in patients whose clinical condition is deteriorating, hospitalization and surgical consultation are recommended.

Abbreviations:

CI	confidence interval
CT	computed tomography
DBE	double-balloon enteroscopy
EGD	esophagogastroduodenoscopy
EMR	endoscopic mucosal resection
ERCP	endoscopic retrograde cholangiopancreatography
ESD	endoscopic submucosal dissection
EUS	endoscopic ultrasound
ESGE	European Society of Gastrointestinal Endoscopy
OTSC	over-the-scope clip
PICO	participants, interventions, comparators, outcomes

RCT	randomized controlled trial
SEMS	self-expandable metal stent
SEPS	self-expandable plastic stent
TTS	through-the-scope

Introduction

Iatrogenic perforation of the gastrointestinal tract related to diagnostic or therapeutic endoscopy is a rare but severe adverse event, associated with significant morbidity and mortality. The absolute number of iatrogenic perforations is likely to increase [1], because of the widespread implementation of endoscopic screening programs and the expansion of the indications for therapeutic

endoscopy. Improvements in the endoscopic and surgical treatments of iatrogenic perforations might substantially reduce the associated morbidity and mortality, underlining the importance of correct diagnosis and management of these events [2]. Because of the lack of high quality studies, mainly due to the rarity of these adverse events, clinical/radiological/surgical strategies to deal with iatrogenic perforation are unclear. The clinical outcome of the patients depends on the timing and efficacy of such interventions, so that the lack of well-defined strategies may by itself be responsible for a suboptimal outcome.

In this Position Statement, ESGE aimed to define the main risk factors for iatrogenic perforations as well as clear diagnostic and therapeutic algorithms for their management. ESGE issues these recommendations as a position statement rather than a guideline because of the scarcity of high quality studies.

Methods

ESGE commissioned this Position Statement. The development process included meetings and online discussions among members of the committee during December 2012 and November 2013. Subgroups were formed, each in charge of a series of clearly defined key questions. The guideline committee chairs (G.P., C.H., J.M.D.) worked with the subgroup leaders (A.R., M.B., J.M.D., S.M., B.S.) to identify pertinent search terms that included: iatrogenic perforations, endoscopy, clips, surgery, as well as terms pertinent to specific key questions. For ease of literature searching, key questions were formulated using PICO (participants, interventions, comparators, outcomes) methodology [3].

Searches were performed on Medline (via Pubmed) and the Cochrane Central Register of Controlled Trials up to October 2013. Articles were first selected by title; their relevance was then assessed by reviewing full-text articles, and publications with content that was considered irrelevant were excluded. Because of the lack of well-designed studies on the diagnosis and management of iatrogenic perforations, quality of evidence and strength of recommendations were not formally graded [4].

Each subgroup developed draft proposals that were presented to the entire group for general discussion during a meeting held in December 2013 (Frankfurt, Germany). Further details on the methodology of ESGE guidelines have been reported elsewhere [4].

In April 2014, a draft prepared by G.P. was sent to all group members. After agreement on a final version, the manuscript was reviewed by two experts selected by the ESGE Governing Board and it was sent to all ESGE individual members and societies for comments/endorsement. It was then submitted to the journal *Endoscopy* for publication.

This Position Paper was issued in 2014 and will be considered for update in 2018. Any interim updates will be noted on the ESGE website: <http://www.esge.com/esge-guidelines.html>.

Recommendations and statements

Evidence statements and recommendations are stated in italics. For ease of clinical use general recommendations and statements are given first followed by in the recommendations and statements for specific organs. A summary of the recommendations and statements is presented in [Table 1](#).

General policy

ESGE recommends that each center implements a written policy regarding the management of iatrogenic perforations, including the definition of procedures that carry a high risk of this complication. This policy should be shared with the radiologists and surgeons at each center.

Iatrogenic perforations are associated with a high risk of morbidity and mortality. Such risks can probably be reduced by using an evidence-based algorithm for diagnosis and management. As outlined below, awareness of the risk factors, prompt availability of adequate radiological imaging, as well as clinical, endoscopic and surgical competence may be expected to substantially improve patient outcome. Because of its complexity, this condition is better managed by a multidisciplinary approach, including endoscopic, radiological, and surgical competences that need to be readily available.

In particular, the existence of a clear policy may prevent a situation where iatrogenic perforation has catastrophic consequences because of the non-availability of appropriate clinical, radiological, or surgical expertise. Although iatrogenic perforation is relatively rare, it is not a completely unpredictable adverse event. Some procedures appear to carry a relatively high risk, allowing a simple stratification between low risk and high risk procedures. It is reasonable to assume that implementation of policies before and not after the introduction of the procedure would by itself minimize the morbidity and mortality risk associated with endoscopic perforation. For instance, the simple awareness that a particular procedure is at high risk of esophageal perforation should indicate that the procedure should not be performed unless a surgeon with adequate thoracic competence is available. Similarly, lack of training with or non-availability of dedicated endoscopic devices would unnecessarily expose patients with iatrogenic perforations to surgical risks. Moreover, failure to use computed tomography (CT) instead of plain film radiography to detect subtle perforations may result in diagnostic delay. Thus the management team for iatrogenic perforations seems to resemble that of stroke and gastrointestinal bleeding units, where prompt collaboration and availability of required competences has led to better clinical outcomes [5, 6]. The availability of dedicated protocols may also represent a structural quality indicator for the health system.

Reporting

In the case of an endoscopically identified perforation, ESGE recommends that the endoscopist reports: its size and location with a picture; endoscopic treatment that might have been possible; whether carbon dioxide or air was used for insufflation; and the standard report information.

Acute iatrogenic perforation during endoscopy is defined as the presence of gas or luminal contents outside the gastrointestinal tract [7]. The timing of diagnosis is critical for management and patient outcome [8–10]. Endoscopy shows a high sensitivity and specificity for diagnosis of iatrogenic perforation [11]. Concerns that air insufflation associated with endoscopy may worsen the extraluminal contamination associated with perforation have not been conclusively demonstrated in any recent study; therefore such concerns should not prevent adequate reporting of the perforation characteristics and should not prevent possible treatment. In the case of an endoscopically recognized perforation, a

Table 1 Iatrogenic endoscopic perforations: summary of recommendations from the European Society of Gastrointestinal Endoscopy (ESGE).

- ESGE recommends that each center implements a written policy regarding the management of iatrogenic perforation, including the definition of procedures that carry a high risk of this complication. This policy should be shared with the radiologists and surgeons at each center.
- In the case of an endoscopically identified perforation, ESGE recommends that the endoscopist reports: its size and location with a picture; endoscopic treatment that might have been possible; whether carbon dioxide or air was used for insufflation; and the standard report information.
- ESGE recommends that symptoms or signs suggestive of iatrogenic perforation after an endoscopic procedure should be carefully evaluated and documented, possibly with a computed tomography (CT) scan, in order to prevent any diagnostic delay.
- ESGE recommends that endoscopic closure should be considered depending on the type of perforation, its size, and the endoscopist expertise available at the center. A switch to carbon dioxide insufflation, the diversion of luminal content, and decompression of tension pneumoperitoneum or tension pneumothorax should also be done.
- After closure of an iatrogenic perforation using an endoscopic method, ESGE recommends that further management should be based on the estimated success of the endoscopic closure and on the general clinical condition of the patient. In the case of no or failed endoscopic closure of the iatrogenic perforation, and in patients whose clinical condition is deteriorating, hospitalization and surgical consultation are recommended.
- ESGE suggests that endoscopic dilations, mucosal resection/submucosal dissection, and foreign body removal should be considered to carry an increased risk of esophageal or gastric perforation.
- ESGE recommends endoscopic treatment for esophageal and gastric perforations using clips or other devices, especially for perforations < 10 mm. Temporary stent placement is particularly useful for large esophageal perforations. For gastric perforation > 10 mm, use of over-the-scope clips (OTSCs) or omental patching, or the combined technique using an endo-loop and through-the-scope (TTS) clips are recommended. If such treatment is unfeasible or fails, or in the case of clinical deterioration, hospitalization and surgical consultation are recommended. General principles of management also include nil-by-mouth regimen, with intravenous administration of proton pump inhibitors, broad spectrum antibiotics, fluids, and on-demand pain medication.
- The most common causes of perforations related to endoscopic retrograde cholangiopancreatography (ERCP) are sphincterotomy (56%) and guide-wire manipulation (23%). ESGE suggests that precut, Billroth II gastrectomy, and biliary stricture dilation should be considered to entail increased risk for biliopancreatic perforation.
- The majority of ERCP-related ductal or periampullary duodenal perforations can be managed nonsurgically. The indications for surgery are a major contrast medium leak, severe sepsis despite nonsurgical management, severe peritonitis, and fluid collections or unsolved problems (e. g., retained hardware) that cannot be solved by nonsurgical means. After careful patient selection, nonsurgical management is successful in more than 90% of patients.
- For the nonsurgical management of ERCP-related ductal or periampullary duodenal perforation, ESGE recommends antibiotics and nasogastric or nasoduodenal aspiration in all patients; stenting of the perforated duct (or of the biliary duct in the case of periampullary perforation) on a case-by-case basis; and total parenteral nutrition in undernourished patients as well as in patients in whom adequate enteral feeding is presumed not to be feasible for ≥ 7 days. Cross-sectional imaging should be performed during follow-up and, if a liquid collection is disclosed, percutaneous drainage should be considered. The efficacy of TTS clips in closing periampullary perforations is unknown.
- ESGE suggests that altered anatomy, stricture dilation in Crohn's disease, dilation of gastrojejunal stricture after gastric bypass, endoscopic submucosal dissection (ESD) and, in patients with altered anatomy, double-balloon enteroscopy (DBE) are risk factors for duodenal and small-bowel perforation.

- In type I (i. e. nonperivaterian) duodenal perforations, ESGE recommends endoscopic treatment if the iatrogenic perforations is recognized immediately and, in the case of failure of endoscopic treatment, immediate surgery. If the duodenal perforation is diagnosed later (> 12 h), management should be surgical in the case of contrast medium extravasation or of persistent large fluid collection at CT scan, or if the patient's condition deteriorates. If the patient is in good condition without extravasation of contrast medium or persistent large fluid collection seen at CT, the patient should be treated conservatively without intervention. For iatrogenic perforations in the small bowel, the ESGE recommends surgical treatment although some iatrogenic perforations caused by dilation of a stricture at a gastrojejunal anastomosis (GJA) may be treated conservatively.
- ESGE recommends that complex endoscopic mucosal resection (EMR), endoscopic submucosal dissection (ESD), and balloon dilation procedures should be considered to carry increased risk of colorectal perforation. Older age, co-morbidity, inflammatory colonic disease, use of hot biopsy forceps, and endoscopist inexperience are other significant risk factors for iatrogenic perforations at colonoscopy.
- ESGE recommends the use of TTS endoclips for small holes and OTSCs for larger ones. Adequate colon preparation is an important factor when contemplating endoscopic treatment of iatrogenic perforations. All patients treated conservatively should be watched closely by a multidisciplinary team in the immediate post-procedure period. Immediate surgical repair is required in the case of larger perforations or where endoscopic closure has failed or where the patient's clinical condition is deteriorating.

comprehensive and clear written report is critical in driving further management. Thus, incomplete reporting – that may be dictated by the fear of future medicolegal litigation – may expose patients to needless diagnostic or therapeutic delays and cause a suboptimal outcome. A clear report stating that the endoscopic therapy applied to the iatrogenic perforation was effective is likely to represent by itself an indication not to proceed to surgery, whilst a report of failure to close a perforation may warn against any delay in surgical treatment. Awareness about the use of carbon dioxide or air may be critical in the interpretation of endoscopic and clinical findings. In order to simplify surgical access, an accurate description of the size and location of the iatrogenic perforations is also required [12]. The availability of photographic documentation of the perforated area may be useful for the multidisciplinary approach, and also for legal considerations.

ESGE recommends that symptoms or signs suggestive of iatrogenic perforation after an endoscopic procedure should be carefully evaluated and documented, possibly with a computed tomography (CT) scan, in order to prevent any diagnostic delay.

Iatrogenic perforations are not always recognized at endoscopy. For instance, in a study spanning 10 years of practice, only 68% of colonoscopy-related perforations were diagnosed within 24 hours [13], so that a high level of suspicion for perforation is required when evaluating some post-endoscopy symptoms, especially following procedures with a high risk of perforation. Early diagnosis has been shown to substantially impact the post-perforation outcome, mainly because it allows potential surgical intervention in an uncontaminated setting [14]. An early search for iatrogenic perforations should be prompted by unusual abdominal pain with distension, chest pain, subcutaneous emphysema, or shortness of breath, while iatrogenic perforation at a later stage is associated with more severe symptoms or signs, such as systemic inflammatory response, hypotension, and mental confusion.

Chest and abdominal plain film radiography are considered to be suboptimal compared with CT scanning [15]. The advantages of CT over plain film radiography include the ability to detect small

amounts of gas in the peritoneum, retroperitoneum or mediastinum, as well as the ability to use luminal contrast to evaluate the efficacy of endoscopic perforation closure.

CT also has a higher sensitivity than plain film radiography for the detection of extraluminal liquids or small pneumothorax. In detail, CT imaging has the higher accuracy for showing small quantities of free air, fluid collections, or empyema in the mediastinum and/or pleural or peritoneal cavity and it provides better definition of adjacent structures [15]. The ingestion of water-soluble contrast prior to CT adds accuracy because it may display the site of extravasation [16].

After endoscopic resection, small air bubbles caused by transmural injection may be seen in the absence of actual iatrogenic perforation [9, 17]. Pneumomediastinum or pneumoperitoneum, without any endoscopic evidence of perforation, can be shown by CT scans in 31%–63% of all gastroesophageal endoscopic submucosal dissection (ESD) procedures [18, 19]. Thus, radiologic findings should always be interpreted in conjunction with endoscopic and clinical findings.

Treatment

ESGE recommends that endoscopic closure should be considered depending on the type of the perforation, its size, and the endoscopist expertise available at the center. A switch to carbon dioxide endoscopic insufflation, the diversion of luminal content, and decompression of tension pneumoperitoneum or tension pneumothorax should also be done.

Randomized controlled studies performed in animal models have shown that the endoscopic closure of iatrogenic perforations is feasible, prevents peritonitis and, compared with surgery, limits adhesions [20, 21]. Thus, it may be decisive in influencing patient outcome, and need for surgery following iatrogenic perforation. Different devices may be applied, mainly according to the size of the iatrogenic perforation. It is unlikely, however, that holes larger than 3 cm may be endoscopically treated.

Clean contents of the gastrointestinal lumen and adequate expertise of the endoscopist are prerequisites for successful endoscopic closure of iatrogenic perforations. Nasogastric or nasoduodenal tubes should be used for diversion of gastrointestinal fluids, as appropriate. Although early involvement of the surgeon is advisable, his/her presence is not required for the endoscopic treatment of the iatrogenic perforation, as the endoscopist usually has more experience than the surgeon in endoscopic closure of iatrogenic perforations.

In the case of hemodynamic or breathing disorders caused by air under tension, decompression should be done as an emergency measure [22]. In a Japanese series, half of the patients underwent successful peritoneal decompression during the procedure [23] (**Video e1**, available online).

Carbon dioxide insufflation is generally recommended during long gastrointestinal endoscopy procedures in patients without severe underlying pulmonary disease [24]. Switching from air to carbon dioxide for insufflation in the case of unexpected iatrogenic perforation may prevent tension-pneumothorax, tension-pneumomediastinum, or tension-pneumopericardium, and the abdominal compartment syndrome, although supporting data are lacking [24, 25].

After closure of an iatrogenic perforation using an endoscopic method, ESGE recommends that further management should be

based on the estimated success of the endoscopic closure and on the general clinical condition of the patient. In the case of no or failed endoscopic closure of the iatrogenic perforation, and in patients whose clinical condition is deteriorating, hospitalization and surgical consultation are recommended.

In the case of iatrogenic perforation, hospitalization is nearly always required. However, selected patients with asymptomatic iatrogenic perforation treated endoscopically may be discharged, but close follow-up should be considered [26].

All patients admitted to the hospital should be treated with general supportive measures including intravenous antibiotics, nothing by mouth, and close multidisciplinary follow-up. Parenteral nutrition is recommended in undernourished patients or in well-nourished patients with expected non-alimentation for ≥ 7 days [27]. Close clinical multidisciplinary monitoring (by endoscopists, surgeons, and intensive care physicians) is required, with special attention to signs of sepsis and peritonitis that could lead to urgent surgical management.

Early surgery is generally to be preferred in patients with large perforations, generalized peritonitis, ongoing sepsis, deteriorating clinical condition, after failure of percutaneous drainage, or with an active leak or with presence of a definite amount of free fluid detected at CT that cannot be drained percutaneously. Iatrogenic perforations that are diagnosed late (particularly duodenal iatrogenic perforations) also require surgical drainage, which carries a high morbidity and mortality [8, 9, 14, 28, 29].

Gastroesophageal perforations

High risk gastroesophageal procedures

ESGE suggests that endoscopic dilations, mucosal resection/submucosal dissection and foreign body removal should be considered to carry an increased risk of esophageal or gastric perforation.

Esophagus: high risk procedures

Most esophageal perforations are associated with therapeutic endoscopic maneuvers, and occur in the thoracic part of the esophagus [30, 31]. Iatrogenic perforation is the most frequently reported major complication of esophageal dilation [30]. The risk is low (0.09%–2.2%) for simple ring or peptic strictures [30], and much higher for strictures that are complex (angulated, multiple, or long), caustic, or radiation-induced [32, 33]. The perforation rate in pneumatic dilation for achalasia has been reported to range broadly between 0.4% and 14%, and it seems to be lower if a 30-mm balloon is used first with an interval, stepwise approach [34, 35].

Endoscopic resections have also been associated with esophageal perforations: retrospective series on endoscopic mucosal resection (EMR) (mostly for Barrett's esophagus) have reported perforation rates between 0% and 3% [36, 37].

Video e1



Inoue & Fockens draining a pneumoperitoneum



Online content including video sequences viewable at: www.thieme-connect.de

Comparably low rates of perforation (2.4%) have been reported by Japanese authors for endoscopic submucosal dissection (ESD) of squamous cell cancer [38]; these have been confirmed by limited European series [39,40].

Finally, regarding foreign bodies, a large, irregular, or sharp shape, impaction in the esophagus for a very long duration, and a history of repeated intentional foreign body ingestion are all risk factors for esophageal perforation [41]. Passage of transesophageal echocardiography probes has also been associated with iatrogenic perforation.

Stomach: high risk procedures

Iatrogenic gastric perforations are most often related to therapeutic procedures, including: gastroenteric anastomosis dilation (2%) [42]; overdistension during argon plasma coagulation or cryotherapy (<0.5%); standard snare polypectomy; EMR (0.5%) and, more frequently, ESD [43]. Additional risk factors during EMR and ESD are: the presence of an ulcer or unhealthy (e.g. irradiated) tissues [44], age >80 years, large tumor size, location of the lesion in the thinner upper region, and long duration of the resection [43,45,46].

Treatment of gastroesophageal perforations

ESGE recommends endoscopic treatment for esophageal and gastric perforations using clips or other devices, especially for perforations ≤10 mm. Temporary stent placement is particularly useful for large esophageal perforations. For gastric perforations >10 mm, use of over-the-scope clips (OTSCs) or omental patching, or the combined technique using an endoloop and through-the-scope (TTS) clips are recommended. If such treatment is unfeasible or fails, or in the case of clinical deterioration, hospitalization and surgical consultation are recommended. General principles of management also include nil-by-mouth regimen, with intravenous administration of proton pump inhibitors, broad spectrum antibiotics, fluids, and on-demand pain medication.

Esophagus: treatment

Some of the prerequisites or conditions that favor successful general and endoscopic management include: early recognition and treatment (<24 hours) of the perforation; small size of the defect (<1 cm for through-the-scope [TTS] clips, <2 cm for OTSCs); a clean esophagus with little or no passage of its content into the mediastinum; lack of patient co-morbidities, and absence of clinical instability following perforation; treatment by an experienced interventional endoscopist; and management by an experienced multidisciplinary team [9,16,47–49]. A perforation located in the cervical esophagus has more potential for successful conservative management because of anatomical factors; the fascial planes of the neck reduce the risk of contamination of the mediastinal organs [16,48]. Generally, if the patient is unstable after perforation then surgery is indicated. If recognition of the perforation is late (>24 hours) and radiology shows free perforation and/or important fluid collections in the mediastinum/pleural cavity, or if the patient has co-morbidities, then surgery is indicated [9,48,50]. Similarly, surgery must be advocated when there is no local endoscopic expertise in advanced therapeutic maneuvers or when there is evidence of leak persistence after previous endoscopic treatment.

The main endoscopic management options for esophageal perforations include closure with clips, and diversion of enteral con-

tents with stents, or endoscopic vacuum therapy (Table 2). In a systematic review, TTS clips were reported as a successful method (in all cases) for closing esophageal perforations ranging from 3 to 25 mm (median size 10 mm) [51]. A limitation of TTS clips is their restricted ability to close large defects because of their limited wingspan; moreover TTS clips cannot approximate perforation edges when there is scarring or inflammation in cases of late treatment or previous unsuccessful attempts [52]. Larger esophageal perforations may be treated using the OTSC. In a recent European multicenter cohort study, enrolling 36 consecutive cases of iatrogenic perforation, [2] all of 5 esophageal perforations were successfully closed endoscopically, using a combination of OTSC and TTS clips (n=3) or OTSCs only (n=2) to close the defect. Temporary stent placement has also been proposed for the treatment of mid and lower esophageal perforations [53]. Table 2 summarizes the outcome after treatment, with partially covered self-expandable metal stents (PC-SEMSs), or fully covered self-expandable metal stents (FC-SEMSs), as well as self-expandable plastic stents (SEPSs). In perforations spanning the gastroesophageal junction, the use of PC-SEMS is preferred because of the migration risk of FC-SEMS, particularly in the absence of stricture. Stents are deemed particularly useful for treatment of large esophageal perforations [54,55], and in cases of malignancy-associated perforation where they also contribute to relief of dysphagia [56].

Vacuum therapy enhances the formation of granulation tissue and healing by secondary intention, by reducing bacterial contamination, secretions, and edema. Endoscopic vacuum therapy is achieved using a sponge attached to the tip of a nasogastric tube that is placed on the site of perforation under endoscopic guidance [57,58].

Oral intake must be interrupted for an adequate period (i.e., at least 5 days). The patient should be treated with intravenous broad spectrum antibiotics, proton pump inhibitors, and fluid reconstitution. On-demand pain medication should be administered intravenously. Partial diversion of the luminal content may be achieved by insertion of a nasogastric tube, which, when possible, should be placed under endoscopic vision and left with continuous controlled suction [9,59]. Placement of a nasogastric tube in a patient with a small perforation that has been correctly sealed is not recommended because of the risk of dislodging the clips. Nasogastric tubes have not been used after the placement of self-expandable metal stents (SEMSs) for esophageal fistula sealing [60].

If radiologic investigations show fluid collection and/or the formation of empyema in the mediastinum and/or pleural cavity, percutaneous drainage is indicated.

Mortality after esophageal perforation is high despite any definitive surgical or conservative strategy. Analysis of 75 studies showed a pooled mortality of 11.9% (95% confidence interval [95%CI] 9.7–14.3; 75 studies with 2971 patients) with a mean hospital stay of 32.9 days (95%CI 16.9–48.9; 28 studies with 1233 patients) [61].

Stomach: treatment

When the perforation is diagnosed during or within 12 hours of endoscopy, endoscopic closure has been associated with good patient outcome. If the perforation is asymptomatic and recognized later than 12 hours, the approach may be conservative. In a recent retrospective series [62], 38 patients with perforations were initially treated nonoperatively. The majority showed neither clinical evidence of peritonitis nor required interventions

Table 2 Efficacy of endoscopic treatment for esophageal iatrogenic perforation.

First author, year	Study design	Type of treatment	Patients, n	Technical success, %	Clinical success, %	Complications, %	Mortality, %
Eroglu, 2009 [78]	Retrospective	SEMS	4	100	n.a.	0	0
Freeman, 2009 [79]	Prospective	SEPS	19	100	89	24	0
Salminen, 2009 [80]	Retrospective	SEMS	8	100	75	25	37.5
Amrani, 2009 [81]	Prospective	SEMS	2	100	100	0	0
Leers, 2009 [82]	Prospective	SEMS	9	100	n.a.	n.a.	<6
Kiernan, 2010 [83]	Retrospective	SEMS	8	100	75	n.a.	12
Vallböhmer, 2010 [59]	Retrospective	SEMS	12	100	n.a.	8	0
Van Heel, 2010 [55]	Prospective	SEMS/SEPS	31	100	97	33	21
Schmidt, 2010 [84]	Retrospective	SEMS+endoclip	21 + 1	100	n.a.	n.a.	<13.3
Swinnen, 2011 [85]	Retrospective	SEMS	23	100	n.a.	n.a.	n.a.
Làzàr, 2011 [86]	Retrospective	Endoclip	1	100	100	0	0
Dai, 2011 [87]	Prospective	SEPS	5	n.a.	83	n.a.	n.a.
D'Cunha, 2011 [88]	Retrospective	SEMS/SEPS	15	95	60	13	6.7
Baron, 2012 [71]	Retrospective	Novel OTSC	1	100	100	0	0
Lin, 2014 [89]	Retrospective	Mesh-covered stents	9	100	n.a.	4	55.6
Biancari, 2013 [90]	Retrospective	Unspecified stents + endoclips	11 + 1	100	n.a.	25	46
Wilson, 2013 [91]	Retrospective	SEMS	7	100	n.a.	n.a.	n.a.
Wahed, 2013 [92]	Retrospective	Unspecified stent	2	100	0	n.a.	100
Voermans, 2012 [2]	Prospective, multicenter	OTSC	5	100	100	0	0
Schweigert, 2013 [93]	Retrospective	SEMS/SEPS	13	100	15	85	15
Sato, 2013 [94]	Retrospective	Endoclip	1	100	100	0	0
Heits, 2014 [95]	Prospective	Vacuum therapy	10	100	90	20	10
Hadj, 2012 [96]	Retrospective	OTSC + SEMS	1	100	100	0	0
Biancari, 2014 [97]	Retrospective	SEMS/endoclips	67	100	15	34	19.4

n.a., not available; OTSC, over-the-scope clip; SEMS, self-expandable metal stent; SEPS, self-expandable plastic stent

beyond conservative management and only 18% required surgery. The only factors associated with failure of nonoperative treatment were free fluid or contrast extravasation seen on CT scan (75% vs. 23%, $P < .005$, and 33% vs. 0%, $P = .047$), respectively). The morbidity in operated patients after initial nonoperative management was equivalent to that observed in patients who underwent initial operative management (63% vs. 61%; P value not significant); however mortality was greater in those who underwent operative management after failed endoscopic treatment than in those who underwent initial operative management (43% vs 21%, $P = 0.09$).

In the case of late recognition of perforation, conservative management may be attempted after a CT scan evaluation that confirms the absence of peritoneal effusion and with close monitoring for signs of sepsis. Late recognition of gastric perforations with septic symptoms is generally associated with peritonitis due to leak of intra-abdominal fluid. These patients generally require surgical management (● Fig. 1).

Endoscopic treatment for small gastric defects (<10 mm)

In the case of perforations smaller than 10 mm (the opening width of TTS clips) with a linear shape, endoscopic clipping is an acceptable method and should be attempted [63]. Sometimes, the clip placement may be difficult because of the location of the perforation. In such cases, the recently described band ligation technique [64] can be an interesting alternative. In the literature there are only a few papers on acute endoscopic iatrogenic perforations of the stomach, with to date a total of 145 patients having been treated with endoclips [65]. In detail, eight studies

on acute iatrogenic perforations after EMR or ESD procedures have been reported and TTS clips were used in all these studies. Pooling these studies, the overall success rate using TTS clips was >99% (● Table 3).

Endoscopic treatment for large gastric defects (>10 mm)

TTS clips alone are not recommended for perforations >10 mm. In the case of perforations measuring 10–30 mm, the OTSC system has been the most evaluated technique and it has demonstrated its efficacy in clinical studies for the management of postoperative leaks or fistulas [66–69]. Regarding acute gastric perforations, four relevant papers have highlighted the efficacy of OTSC (● Table 4) [2, 70–72] with a total success rate of more than 95% (22 patients). All of these experimental and clinical studies recommend OTSCs for the management of gastric defects between 10 and 30 mm in diameter, with or without the use of grasping devices to place them. However, perforations >20 mm are challenging to manage endoscopically, requiring experience and the availability of surgery in case of failure. If the OTSC technique is unavailable, the combined technique using TTS clips plus endo-loop can be recommended [73–75]. When the omentum is visible through the defect, the omental patch technique may be recommended [63, 76], especially if the defect is very large (● Table 5). The use of the new suturing devices must be restricted to expert centers and/or the setting of clinical trials.

Finally, the nonsurgical treatment of gastric perforations may include the use of removable fully covered self-expandable metal stents (FC-SEMSs) or self-expandable plastic stents (SEPSs); these stents are indicated for perforations caused by dilation of a gas-

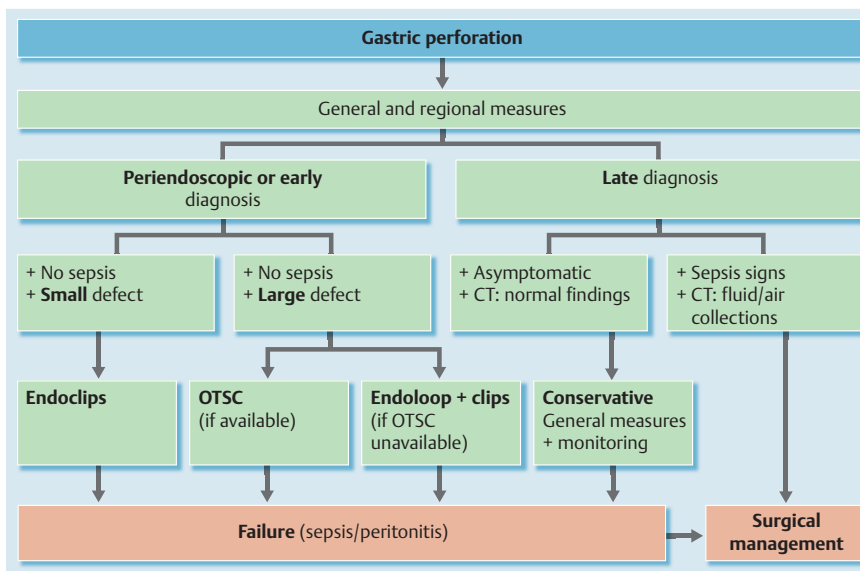


Fig. 1 Algorithm for the management of gastric iatrogenic perforations. CT, computed tomography; OTSC, over-the-scope clip.

Table 3 Results of endoscopic management of gastric perforation with through-the-scope (TTS) clips.

First author, year	Type	n	Pathologies	Technique	Success rate	Others
Binmoeller, 1993 [98]	Case report	1	Leiomyoma	TTS clipping	100 %	–
Albuquerque, 2004 [99]	Case report	1	Adenoma	TTS clipping	100 %	–
Katsinelos, 2004 [100]	Case report	1	Adenoma (HGD)	TTS clipping	100 %	–
De Caro, 2009 [101]	Case report	1	Adenocarcinoma in situ	TTS clipping	100 %	–
Kim, 2000 [102]	Case report	1	Adenocarcinoma in situ	TTS clipping	100 %	–
Tsunada, 2003 [76]	Retrospective, case series	7	Early gastric cancer	TTS clipping (6) Omental patch (1)	100 %	1 large defect
Fujishiro, 2006 [18]	Retrospective, case series	11	Early gastric cancer	TTS clipping	100 %	Mean discharge time 12.1 days
Minami, 2006 [63]	Retrospective	121	Early gastric cancer	< 1 cm: TTS clipping > 1 cm: omental patch	98.3 %	2 surgeries
Total	–	144	–	–	>99 %	For defects < 10 mm

HGD, high grade dysplasia

Table 4 Results of endoscopic management of gastric perforation with over-the-scope clips (OTSCs).

First author, year	Type	n	Perforation cause	OTSCs, n	Success rate	Size
Baron, 2012 [71]	Retrospective	2	Iatrogenic	2	100 %	–
Kirschniak, 2011 [70]	Retrospective	7	Iatrogenic (1 ESD)	7	100 %	–
Voermans, 2012 [2]	Prospective	6	Iatrogenic: ESD, EMR, EUS	6	100 %	<30 mm
Nishiyama, 2013 [72]	Retrospective	7	Iatrogenic: ESD, scope/ulcer	13	86 % (6/7)	Mean diameter 30 mm 1 failure, 50 mm
Total	–	22	Iatrogenic	28	95 %	For 10-mm to 30-mm defects

ESD, endoscopic submucosal dissection; EMR, endoscopic mucosal resection; EUS, endoscopic ultrasound.

This document was downloaded for personal use only. Unauthorized distribution is strictly prohibited.

Table 5 Results of endoscopic management of gastric perforation with omental patch, band ligation, or the combined technique using endoclips plus endoloop

First author, year	Type	n	Perforation cause	Method	Success rate	Size
Minami, 2006 [63]	Retrospective	121	Iatrogenic perforations (ESD/EMR)	Omental patch	98.3 %	> 10 mm
Tsunada, 2003 [76]	Case report	1	After EMR procedure	Omental patch	100 %	Large perforation
Han, 2013 [64]	Case series	5	After ESD (3), EMR (1), biopsy (1)	Band ligation	100 %	5 to 11 mm
Shi, 2013 [103]	Retrospective	20	Full-thickness resections of tumors	Endoloop + endoclips	100 %	Median size 15 mm (0.4–30)
Zhong, 2012 [104]	Retrospective	14	Full-thickness resections of tumors	Endoloop + endoclips	100 %	0.6 to 30 mm

ESD, endoscopic submucosal dissection; EMR, endoscopic mucosal resection

troenteric anastomosis, or dilation of an antral stricture, or related to cystogastrostomy [77].

The nonsurgical treatment of gastric perforations should include placement of a nasogastric tube under endoscopic control. It should be connected to suction for 1 day after the treatment of the perforation [63].

Perivaterian (periampullary) and biliopancreatic ductal perforation



High risk procedures: ERCP-related perforations

The most common causes of perforations related to endoscopic retrograde cholangiopancreatography (ERCP) are sphincterotomy (56%) and guidewire manipulation (23%). ESGE suggests that precut, Billroth II gastrectomy, and biliary stricture dilation should be considered to entail increased risk for biliopancreatic perforation.

In a review of studies that reported on ERCP-related complications of any type in a total of 16 855 patients, amongst whom 50%–100% had undergone a therapeutic procedure depending on individual studies, perforation was reported in 101 patients (0.6%, 95% confidence interval [CI] 0.48–0.72) with a perforation-related mortality of 9.90% (95% [CI] 3.96–15.84) [105]. Other studies listed in Table 6 reported ERCP-related perforations in any location and in the periampullary area/biliopancrea-

tic ducts in 0.43% (95%CI 0.37–0.59) and 0.33% (95%CI 0.28–0.48), respectively, of 115 747 patients.

The causes of perforation were endoscopic sphincterotomy, guidewire manipulation, stricture dilation, and stent insertion or migration in 56%, 23%, 4%, and 3% of cases, respectively; perforations were located in the periampullary area, the bile ducts and the pancreatic ducts in 65%, 25%, and 1.4% of cases, respectively (Table 7).

Independent risk factors for ERCP-related perforations include precut, Billroth II gastrectomy, intramural injection of contrast medium, procedure duration, sphincter of Oddi dysfunction, a dilated common bile duct, and biliary stricture, as identified in two studies [106, 107].

ESGE recommends that ERCP-related perforations be described according to the classification by Stapfer et al.: type I, lateral or medial wall duodenal perforation; type II, perivaterian injuries; type III, distal bile duct injuries; type IV retroperitoneal air alone [108].

Treatment: ERCP-related perforations

The majority of ERCP-related ductal or periampullary duodenal perforations can be managed nonsurgically. The indications for surgery are a major contrast medium leak, severe sepsis despite nonsurgical management, severe peritonitis, and fluid collections or unsolved problems (e.g., retained hardware) that cannot be

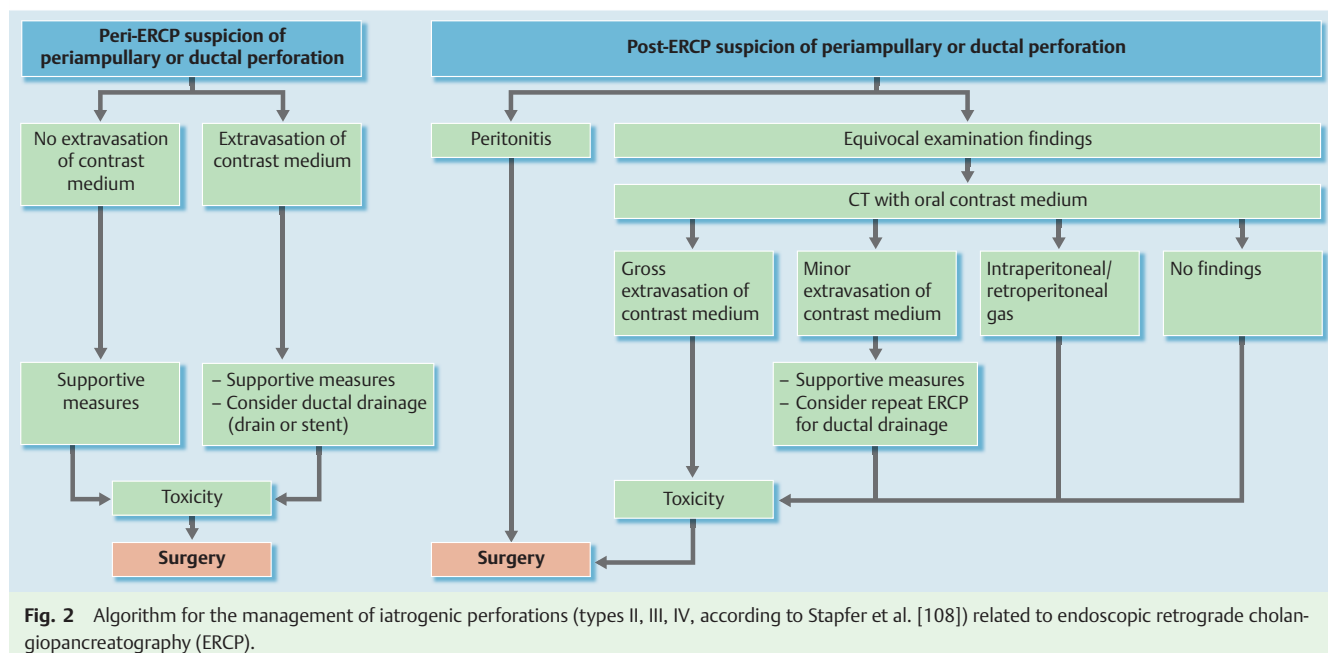


Fig. 2 Algorithm for the management of iatrogenic perforations (types II, III, IV, according to Stapfer et al. [108]) related to endoscopic retrograde cholangiopancreatography (ERCP).

Table 6 Incidence of perforations related to endoscopic retrograde cholangiopancreatography (ERCP), and requirement for surgery.

First author, year	Study design	n	Perforation		Type II, III, IV ¹		Surgery required in types II, III, IV, n
			n	%	n	%	
Assalia, 2007 [120]	Prospective	3 104	22	0.70	20	0.64	1
Avgerinos, 2009 [121]	Retrospective	4 358	15	0.34	6	0.13	5
Dubecz, 2012 [122]	Retrospective	12 232	11	0.08	4	0.03	1
Enns, 2002 [106]	Retrospective	9 314	33	0.35	28	0.30	3
Fatima, 2007 [28]	Retrospective	12 427	75	0.60	67	0.53	15
Howard, 1999 [110]	Retrospective	6 040	40	0.66	36	0.59	1
Kayhan, 2004 [115]	Retrospective	3 124	17	0.54	15	0.48	4
Kim, 2011 [123]	Retrospective	7 638	13	0.17	9	0.11	4
Kim, 2012 [124]	Retrospective	11 048	68	0.61	55	0.49	Not reported
Knudson, 2008 [116]	Retrospective	4 919	32	0.65	26	0.52	8
Kwon, 2012 [125]	Retrospective	8 381	53	0.63	32	0.38	1
Mao, 2008 [126]	Retrospective	2 432	9	0.37	9	0.37	3
Morgan, 2009 [127]	Retrospective	12 817	24	0.18	12	0.09	0
Polydorou, 2011 [12]	Retrospective	9 880	44	0.44	37	0.37	6
Stapfer, 2000 [108]	Retrospective	1 413	14	0.99	9	0.63	4
Wu, 2006 [128]	Retrospective	6 620	30	0.45	25	0.37	7
Total		115 747	500	0.43	390	0.33	63 (18.8%) ²

¹ According to Stapfer's classification [108] (type I, lateral or medial wall duodenal perforation; type II, perivaterian injuries; type III, distal bile duct injuries, type IV retroperitoneal air alone).

² Percentage was calculated after exclusion of the results reported by Kim et al. [124].

Table 7 Assumed etiology of 405 type II, III, IV¹ perforations related to endoscopic retrograde cholangiopancreatography (ERCP).

First author, year	Endoscopic sphincterotomy, n	Guidewire, n	Dilation of strictures, n	Other instruments, n	Stent insertion or migration, n	Unknown, n
Alfieri, 2013 [112]	15	1	–	–	–	8
Assalia, 2007 [120]	17	2	–	–	1	–
Avgerinos, 2009 [121]	3	–	–	3	–	–
Dubecz, 2012 [122]	3	1	–	–	–	–
Enns, 2002 [106]	13	13	2	–	–	–
Fatima, 2007 [28]	11	24	5	9	7	11
Howard, 1999 [110]	22	14	–	–	–	–
Kayhan, 2004 [115]	15	–	–	–	–	–
Kim, 2011 [123]	3	4	–	2	–	–
Kim, 2012 [124]	25	23	–	2	–	–
Knudson, 2009 [116]	11	–	–	–	3	8
Kwon, 2012 [125]	24	2	6	–	–	–
Mao, 2008 [126]	9	–	–	–	–	–
Morgan, 2009 [127]	12	–	–	–	–	–
Polydorou, 2011 [12]	30	2	2	3	–	–
Stapfer, 2000 [108]	6	3	–	–	–	–
Wu, 2006 [128]	11	7	–	–	–	7
Total	230 (56%)	96 (23%)	15 (3.7%)	19 (4.6%)	11 (2.7%)	34 (8%)

¹ According to Stapfer's classification (type I, lateral or medial wall duodenal perforation; type II, perivaterian injuries; type III, distal bile duct injuries, type IV retroperitoneal air alone) [108]

solved by nonsurgical means. After careful patient selection, nonsurgical management is successful in more than 90% of patients.

An algorithm (● Fig. 2) summarizes ESGE's recommendations on how to select the most individually appropriate management of ductal or periampullary duodenal ERCP-related perforation. In patients initially managed nonsurgically following ductal or periampullary ERCP-related perforation, the morbidity and mortality rates were 7% and 3%, respectively; surgery was eventually required in approximately 6% of cases. These figures were calculated for the 220 patients included in seven studies (● Table 8). No significant difference was found between patients with type II vs. type III perforation, after initial nonsurgical management, in terms of final requirement for surgery, morbidity, or mortality.

A recent review of duodenal, periampullary, and ductal ERCP-related perforations found that nonsurgical management, applied in 62% of patients, was successful in 92.9% of those patients [109]. In 335 patients with ductal or periampullary perforation and final outcome detailed in ● Table 6, surgery was required in 19% of the cases.

Early diagnosis and prompt treatment are vital for a better outcome [110,111]. The choice between surgical vs. nonsurgical management should be guided by the site and degree of the leak and by the patient's condition [106,109,111–114]. Suspected ductal and periampullary perforations should be assessed by an early contrast medium study, during ERCP or using CT scan, and documentation should be retained for medicolegal purposes.

Table 8 Outcome after initial nonsurgical management of type II, III, IV¹ perforations related to endoscopic retrograde cholangiopancreatography (ERCP) in selected series.

First author, year	Type II					Type III					Type IV				
	n	Standard treatment ²	Surgery ³ , n (%)	Morbidity, n (%)	Mortality, n (%)	n	Standard treatment ²	Surgery ³ , n (%)	Morbidity, n (%)	Mortality, n (%)	n	Standard treatment ²	Surgery ³ , n (%)	Morbidity, n (%)	Mortality, n (%)
Assalia, 2007 [120]	20	Antibiotics Nasogastric/ nasoduodenal aspiration	2 (10)	0	1 (5)	2	Antibiotics Nasogastric/ nasoduodenal aspiration	0	0	0	1	Antibiotics Nasogastric/ nasoduodenal aspiration	0	0	0
Enns, 2002 [106]	13	Antibiotics Nil-by-mouth regimen	2 (16)	0	0	14	Antibiotics Nil-by-mouth regimen	1 (7)	2 (14)	0	1	Antibiotics Nil-by-mouth regimen	0	0	0
Fatima, 2007 [28]	15	Antibiotics Nasogastric/ nasoduodenal aspiration Percutaneous/ endoscopic bi- liopancreatic drainage ²	0	0	1 (7)	32	Antibiotics Nasogastric/ nasoduodenal aspiration Percutaneous/ endoscopic bilopancreatic drainage ²	0	0	2 (6)	6	Antibiotics Nil-by-mouth regimen	0	0	0
Howard, 1999 [110]	22	Antibiotics Nasogastric/ nasoduodenal aspiration Biliary stent or nasobiliary drainage	3 (14)	3 (14)	1 (5)	14	Antibiotics Nasogastric/ nasoduodenal aspiration Biliary stent or nasobiliary drainage	0	3 (21)	0	0	-	-	-	-
Kwon, 2012 [125]	24	Antibiotics Total parenter- al nutrition	0	5 (21)	1 (4)	8	Antibiotics Total parenter- al nutrition	1 (13)	1 (13)	0	0	-	-	-	-
Morgan, 2009 [127]	12	Antibiotics Nasogastric/ nasoduodenal aspiration	0	1 (8)	0	0	-	-	-	-	0	-	-	-	-
Polydorou, 2011 [12]	29	Antibiotics Total parenter- al nutrition	5 (17)	1 (3)	0	5	Antibiotics Nasogastric/ nasoduodenal aspiration	0	2 (40)	0	2	Antibiotics Nasogastric/ nasoduodenal aspiration	0	0	0
Total	135		12 (9)	10 (7)	4 (3)	75	-	2 (3)	6 (8)	2 (3)	10	0	0	0	0

¹ According to Stapfer's classification [108]; figures were extracted for each type of perforation as accurately as possible from published data.² Where appropriate³ Surgery describes operations performed to treat the perforation itself and/or its complications, not the primary disease for which ERCP was performed.

Major periampullary or ductal contrast medium leaks are usually recognized as an indication for immediate surgery [109, 111].

For the nonsurgical management of ERCP-related ductal or periampullary duodenal perforation, ESGE recommends antibiotics and nasogastric or nasoduodenal aspiration in all patients; stenting of the perforated duct (or of the biliary duct in the case of periampullary perforation) on a case-by-case basis; and total parenteral nutrition in undernourished patients as well as in patients in whom adequate enteral feeding is presumed not to be feasible for ≥ 7 days. Cross-sectional imaging should be performed during follow-up and, if a liquid collection is disclosed, percutaneous drainage should be considered. The efficacy of TTS clips in closing periampullary perforations is unknown.

Modalities available for the nonsurgical management of ERCP-related ductal or periampullary duodenal perforation include:

- ▶ Antibiotics and nasogastric or nasoduodenal aspiration, used in most case series.
- ▶ Stenting, consistently used by some authors to divert fluids from the perforation site, [110, 112] but on a case-by-case basis by others (e.g., in 12 [48%] of 25 patients treated nonoperatively by Enns et al.), with no significantly different results [106]. Another concern about stenting is the impact of abandoning scheduled ERCP tasks because of recognition of perforation during the ERCP procedure. Following ERCP-related perforation, a significant proportion of patients may refuse ERCP and prefer surgery although repeat ERCP has been reported to succeed in treating the primary biliopancreatic disease in up to 100% of patients [106, 115].
- ▶ Total parenteral nutrition, mentioned in a single study [12], is recommended in European guidelines for postoperative parenteral nutrition if complications impede adequate enteral feeding for at least 7 days and in undernourished patients [27]. Using mean duration of hospital stay as a proxy for the fasting period following ERCP-related perforation, we conclude that total parenteral nutrition is required in a minority only of well-nourished patients who are successfully treated nonoperatively.
- ▶ Abdominal fluid collections are commonly drained percutaneously in the first place; this was performed in 13 (6%) of the 209 patients listed in **Table 8** with wide variations between studies (0 to 20%). Endosonography-guided transenteric stenting has been proposed as an alternative for draining bilomas [113].
- ▶ TTS clips have been used by some authors in an attempt to close perforations, but in the absence of controlled trials the true efficacy of this measure is unknown [28, 112, 116].
- ▶ Somatostatin has not been tested in patients with a peri-ERCP pancreatic duct perforation. It improves closure of postoperative enterocutaneous fistulas compared with placebo [117–119].

Duodenal and small bowel perforation

High risk procedures: duodenum and small bowel

ESGE suggests that altered anatomy, stricture dilation in Crohn's disease, dilation of gastrojejunal stricture after gastric bypass, endoscopic submucosal dissection (ESD) and, in patients with altered anatomy, double-balloon enteroscopy (DBE) are risk factors for duodenal and small-bowel perforation.

Duodenum: high risk procedures

In a retrospective case series of 72 iatrogenic perforations following esophagogastroduodenoscopy (EGD), the incidence of perforation was 0.033% (25 were in the duodenum, for an incidence of 0.01%) [62].

Perforations of the lateral or medial wall of the duodenum caused by the endoscope itself (type I in Stapfer's classification) are usually large and carry a high mortality (28% in the study by Merchea et al.) [62, 108]. The main risk factor for this type of perforation is Billroth II gastrectomy [124].

Among therapeutic procedures, ESD has a particularly high risk of perforation, with a perforation rate of 35.7% reported in a retrospective study of 14 patients [129]. Delayed perforation after ESD is more frequent in the duodenum (14%) than after gastric (0.45%) and colorectal ESD (0.3%–0.7%) [130–132]. The high incidence of delayed perforations may be due to the thinness of the duodenal wall, coupled with proteinolysis or chemical irritation by pancreatic enzymes and bile juice. However, endoscopic mucosal resection (EMR) seems to be safe in the duodenum. No case of perforation was reported in two studies evaluating 47 cases in total [133, 134].

Small bowel: high risk procedures

DBE-related perforations in the small bowel are rare. In a German prospective study of 2245 DBE examinations, only 3 perforations were observed (incidence 0.1%), with 2 of these occurring after polypectomy (1.5% of 137 polypectomies) [135]. A large retrospective study of DBE complications in nine US centers showed a iatrogenic perforation rate of 0.4% with a significantly higher incidence of iatrogenic perforations in patients with altered surgical anatomy (3%) [136]. In the last 5 years there have been three case reports describing capsule endoscopy in patients with Crohn's disease leading to retention and perforation [137–139]. One perforation is reported in a small prospective case series (n = 13) of DBE with stricture dilation in Crohn's disease [140]. Dilation of gastrojejunal anastomotic strictures after gastric bypass surgery carries an iatrogenic perforation rate of between 0 and 4.5% [141].

Treatment: duodenum and small bowel

In type I (i.e. nonperivaterian) duodenal perforations, ESGE recommends endoscopic treatment if the iatrogenic perforation is recognized immediately and, in the case of failure of endoscopic treatment, immediate surgery. If the duodenal perforation is diagnosed later (> 12 h), management should be surgical in the case of contrast medium extravasation or of persistent large fluid collection at CT scan, or if the patient's condition deteriorates. If the patient is in good condition without extravasation of contrast medium or persistent large fluid collection seen at CT, the patient should be treated conservatively without intervention.

For iatrogenic perforations in the small bowel, ESGE recommends surgical treatment although some iatrogenic perforations caused by dilation of stricture at a gastrojejunal anastomosis (GJA) may be treated conservatively.

Duodenum: treatment

In the case of immediate recognition of perforation, an endoscopic closure should be attempted. This is effective in a minority of cases only (17 [22%] of 76 cases listed in **Table 9**). In the 76 cases listed in **Table 9** endoscopic closure was possible in 18

Table 9 Reports of treatments of duodenal iatrogenic perforation (type I) since September 2008¹

First author, year	n	Procedure	Endoscopic closure, n (system used)	Surgery, n	Conservative, n	Standard treatment	Mortality, n (%)
Avgerinos, 2009 [121]	9	ERCP		9	–	–	0
Palanivelu, 2008 [144]	1	ERCP		1	–	Broad spectrum antibiotics + Nil-by-mouth regimen + Nasoduodenal aspiration + Parenteral nutrition	0
Ahlawat, 2009 [145]	1	EUS	1 (endoclips)	–	–	Broad spectrum antibiotics + Nil-by-mouth regimen	0
Honda, 2009 [146]	2	ESD	1 (endoclips)	1 (delayed perforation)	–	–	0
Nakagawa, 2010 [147]	1	ERCP	1 (endoclip + endoloops)	–	–	Broad spectrum antibiotics + Nil-by-mouth regimen + Parenteral nutrition + Proton pump inhibitor	0
Farhat, 2011 [148]	1	ESD	1 (endoclips)	–	–	–	0
Lee, 2010 [149]	4	ERCP	4 (endoclips)	–	–	Broad spectrum antibiotics + Parenteral nutrition + Proton pump inhibitor	0
Polydorou, 2011 [12]	7	ERCP	–	6	1	–	2 (29)
Ercan, 2012 [150]	17	ERCP	–	17	–	Broad spectrum antibiotics + Nil-by-mouth regimen + Nasoduodenal aspiration	8 (47)
Kim, 2012 [124]	9	ERCP	–	8	1	Broad spectrum antibiotics	Not reported
Fanning, 2012 [151]	1	ERA	1 (endoclips)	–	–	Broad spectrum antibiotics	0
Samarasena, 2012 [152]	1	ERA	1 (endoclips, endo-loop, and fibrin glue)	–	–	Broad spectrum antibiotics + Nil-by-mouth regimen + Nasoduodenal aspiration	0
Hadj Amor, 2012 [96]	1	EMR	(OTSC, endoclips, and stent)	–	–	–	0
Gubler, 2012 [153]	2	ERA	2 (OTSC)	–	–	Broad spectrum antibiotics + Nil-by-mouth regimen	0
Matsumoto, 2013 [154]	3	ESD	–	2	1	–	0
Rabie, 2013 [155]	10	ECRP	–	3	7	–	1 (10)
Nishiyama, 2013 [72]	1	ESD	1 (OTSC)	–	–	–	–
Jung, 2013 [129]	5	ESD	3 (endoclips)	2	–	Nasoduodenal aspiration	–
Summary	76		17	49	10	–	11 (16)

ERCP, endoscopic retrograde cholangiopancreatography; EUS, endoscopic ultrasound; ESD, endoscopic submucosal dissection; ERA, endoscopic resection of adenomas; EMR, endoscopic mucosal resection; OTSC, over-the-scope clip.

¹ Several reports fail to inform about standard treatment and the management of the perforation.

(24%) cases and it was successful in 17 (clinical success rate after successful endoscopic closure of duodenal perforation, 94.4%). In the 17 cases with successful endoscopic closure, 11 perforations with a maximum diameter of 13 mm were successfully treated with TTS clips, 2 perforations of 10 mm and 30 mm were treated with a combination of TTS clips and endoloops, and 4 perforations with a maximum diameter of 28 mm were treated with an OTSC. The dimensions of the lesion are rather unclear in the articles but in most cases the number indicates the maximum lesion size. Immediate endoscopic closure is believed to be technically easier compared with a delayed attempt because the perforation margins are soft, not yet being involved by inflammation [72]. A successful therapeutic ERCP following treatment with an OTSC for acute duodenal perforation that occurred during diagnostic endoscopic ultrasonography (EUS) has been reported [142].

If the iatrogenic perforation is diagnosed several hours after the endoscopy and the patient shows symptoms of generalized peritonitis and/or sepsis, the only option is surgery. Avgerinos et al. found in a retrospective review of 15 cases of duodenal iatrogenic perforations that mortality dramatically increases with late (>24

h) surgical management [121]. These authors described a clinico-radiographic test to choose between a surgical or a conservative treatment for ERCP-related duodenal iatrogenic perforation. If an abdominal radiograph showed free intraperitoneal air, an abdominal CT scan with oral water-soluble contrast was carried out. Extravasation of contrast in the intra-abdominal cavity or the presence of extradigestive fluid indicated surgical exploration, whereas nonsurgical treatment was possible in the absence of these factors (● Fig. 3) [121].

Small bowel: treatment

● **Table 10** summarizes the case reports on treatments of small-bowel iatrogenic perforations published since September 2008. Out of 32 patients with small-bowel iatrogenic perforations, 19 underwent surgery, 5 patients were treated conservatively, 1 laceration was closed with an OTSC and in 7 cases the management was not reported. All of the 5 patients who were treated conservatively had iatrogenic perforations following endoscopic dilation of a GJA.

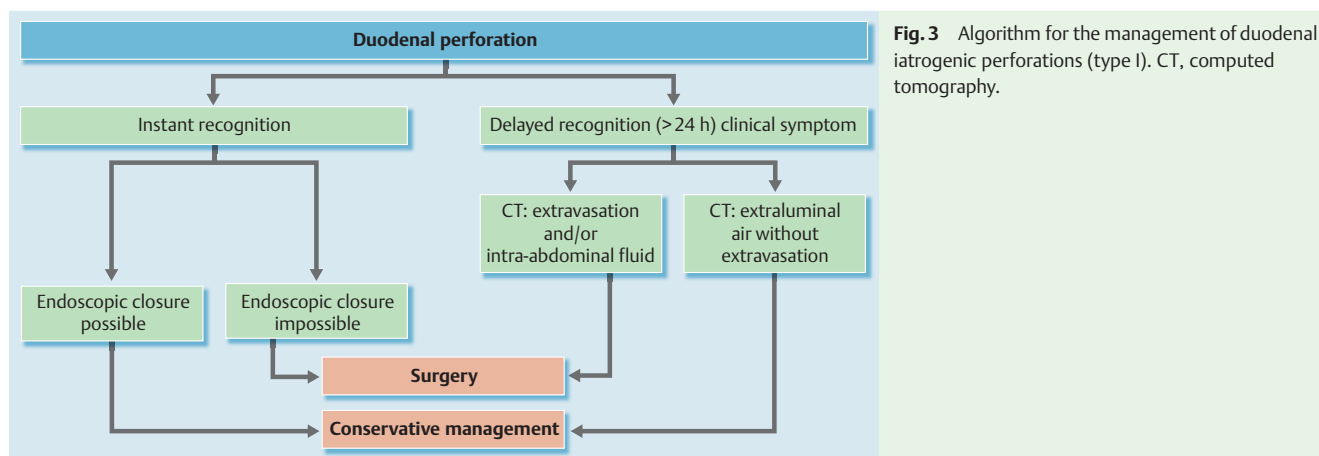


Fig. 3 Algorithm for the management of duodenal iatrogenic perforations (type I). CT, computed tomography.

Table 10 Reports of treatments of small-bowel perforation since September 2008.

First author, year	n	Procedure	Endoscopic closure, n (system used)	Surgery, n	Conservative, n	Standard treatment ¹	Mortality (%)
Um, 2008 [139]	1	Capsule endoscopy	–	1	–	–	0
Gerson, 2009 [136]	10	DBE	–	10	–	–	1 (10)
Despott, 2009 [140]	1	DBE	–	1	–	–	0
Teruel, 2009 [156]	1	Colonoscopy	–	1	–	–	0
Möschler, 2011 ¹ [135]	3	DBE	–	–	–	–	0
Campos, 2012 ¹ [157]	14	Dilation of GJA	–	5	5	Broad spectrum antibiotics + Nil-by-mouth regimen	0
Yitzhak, 2012 [138]	1	Capsule endoscopy	–	1	–	–	0
Balmadrid, 2013 [143]	1	SBE-PEJ	OTSC	–	–	Broad spectrum antibiotics	0
Summary	32		1	19	5	–	1 (3)

DBE, double-balloon enteroscopy; GJA, gastrojejunal anastomosis; SBE-PEJ, single balloon enteroscopy-percutaneous endoscopic jejunostomy

¹ No description of the management of all perforations.

Until recently surgery has been the only choice for management and only one case report, as mentioned above, describes an endoscopic closure, using the OTSC system, of a small-bowel laceration near the ligament of Treitz [143]. Surgery should still be the first choice in the management of small-bowel iatrogenic perforations.

Colorectal perforations

High risk procedures in the colorectum

ESGE recommends that complex EMR, ESD, and balloon dilation procedures should be considered to carry increased risk of colorectal perforation.

Older age, co-morbidity, inflammatory colonic disease, use of hot biopsy forceps, and endoscopist inexperience are other significant risk factors for iatrogenic perforations at colonoscopy.

Risk factors include female gender, presumably related to pelvic adhesions, major co-morbidities and greater age (weakened colonic wall tissues) [13, 158–160]. Risk may also be increased during surveillance colonoscopy in patients with colitis such as inflammatory bowel disease [161]; however, the colonoscopic surveillance for long-standing extensive ulcerative colitis has proved to be safe with no significant complications when biopsies are obtained with caution [162].

The sigmoid colon and the rectosigmoid junction are the most common sites of diagnostic perforation due to direct mechanical injury via shearing forces applied by the shaft or tip of the colonoscope during endoscope insertion [14, 163]. Pericolonic adhesions (from previous gynecological surgery or abdominal inflammation) and severe diverticular disease may increase the risk of perforation, particularly when large-caliber instruments and excessive force are used [164]. Traumatic antimesenteric tears of the colonic wall are less common elsewhere but can occur at the flexures because of excessive tip force or in the rectum during retroflexion [165]. Cecal perforation can also occur because of barotrauma, particularly if gas is introduced above an area of stenosis [166]; barotrauma is probably less likely when carbon dioxide is used, compared with air, as the former is absorbed more quickly.

Iatrogenic perforation has been reported in 0.03%–0.8% of diagnostic colonoscopies and flexible sigmoidoscopies in both the symptomatic and screening settings [167–169].

Therapeutic colonoscopy carries a small but significant risk of perforation (up to 5%), particularly following advanced polypectomy. However, high risk procedures such as endoscopic balloon dilation, applied to treat ileocolonic anastomotic strictures as in Crohn's disease, may entail perforation rates up to 11% [170]. Regarding the use of SEMs in the setting of acute malignant colonic obstruction, retrospective studies demonstrate a perforation rate

of 5%–9% [171,172]. The British Society of Gastroenterology (BSG) audit of colonoscopy demonstrated that the risk of perforation at diagnostic examinations was 1:923 compared with 1:460 following polypectomy [173]. The Munich Polypectomy Study reports a risk of 1.1% for colorectal perforation when polyps were larger than 10mm in the right colon or 20mm in left colon or when there were multiple polyps [174]. Equivalent results were reported by a French national survey, reporting a perforation rate of 3.6% after EMR polypectomy in the lower gastrointestinal tract [175].

For piecemeal EMR of polyps larger than 20mm, two experienced centers reported acceptably low perforation rates of 1.3% and 0.003% [176,177]. Conversely, the perforation rate for colorectal ESD is higher but varies depending on the experience of the operator. Predictive risk factors for iatrogenic perforations during colorectal ESD such as submucosal fibrosis and tumor size should be also considered because they may complicate ESD, being associated with a higher perforation incidence of 20.4% [178]. Early Japanese experience with ESD showed a perforation risk of 5%–10%, although current literature demonstrates a lower perforation risk ranging from 1.9% to 4.7% [179,180]. An early multicenter report of colorectal ESD from France reported a high perforation rate (18.1%) [148]; but more recently other centers have described more acceptable perforation rates of 2%–12%, in line with the early experience from Japan [181]. In the past, hot biopsy forceps have been applied to destroy small polyps but recent animal studies demonstrate a potential hazard for deep thermal injury with transmural necrosis found in a high proportion of cases [182]. Anecdotal reports of delayed hemorrhage and perforation following hot biopsy have led many centers to abandon the use of this technique particularly in the right colon.

The risk of iatrogenic perforation appears to be operator-dependent; non-gastroenterologist endoscopists and endoscopists who perform only a low number of cases being associated with an increased risk of iatrogenic perforation [1,159].

Investigations such as abdominal plain film radiography or CT scan are commonly performed in the case of clinically suspected

or diagnosed perforation to verify the presence of air or fluid collections or injected contrast material. Abdominal CT is the most sensitive examination for detecting gas or liquid leaks [183]; water-soluble contrast enema per rectum is seldom used to detect concealed perforation.

Treatment in the colorectum

ESGE recommends the use of TTS endoclips for small holes and OTSCs for larger ones. Adequate colon preparation is an important factor when contemplating endoscopic treatment of iatrogenic perforations. All patients treated conservatively should be watched closely by a multidisciplinary team in the immediate post-procedure period. Immediate surgical repair is required in the case of larger perforations or where endoscopic closure has failed or where the patient's clinical condition is deteriorating.

Air or gas entry into the peritoneal cavity is a hallmark of iatrogenic perforation but does not necessarily cause infective peritonitis unless egress of luminal contents occurs. The recognition of colorectal wall tears may be immediate at the time of the procedure or can be delayed for up to 3 days [184,185].

A conservative strategy is possible when a perforation site is recognized early, enabling an urgent closure without the spillage of gut contents. Rapid endoscopic intervention with clip placement and the use of carbon dioxide may limit the volume of extraluminal insufflation and subsequently the need for surgery [186,187]. When there is no evidence of intraperitoneal contamination by fecal contents, free air may either resolve spontaneously within a week or progress to a compartment syndrome [188]. In this case, a tension pneumoperitoneum develops requiring an immediate release of trapped intraperitoneal air. However, if fecal contents are present, then the optimal management is surgery.

The decision to attempt endoscopic closure of an iatrogenic perforation depends on multiple factors, including the size and the cause of iatrogenic perforation, the endoscopist's experience and the accessories available at the time. With immediate endo-

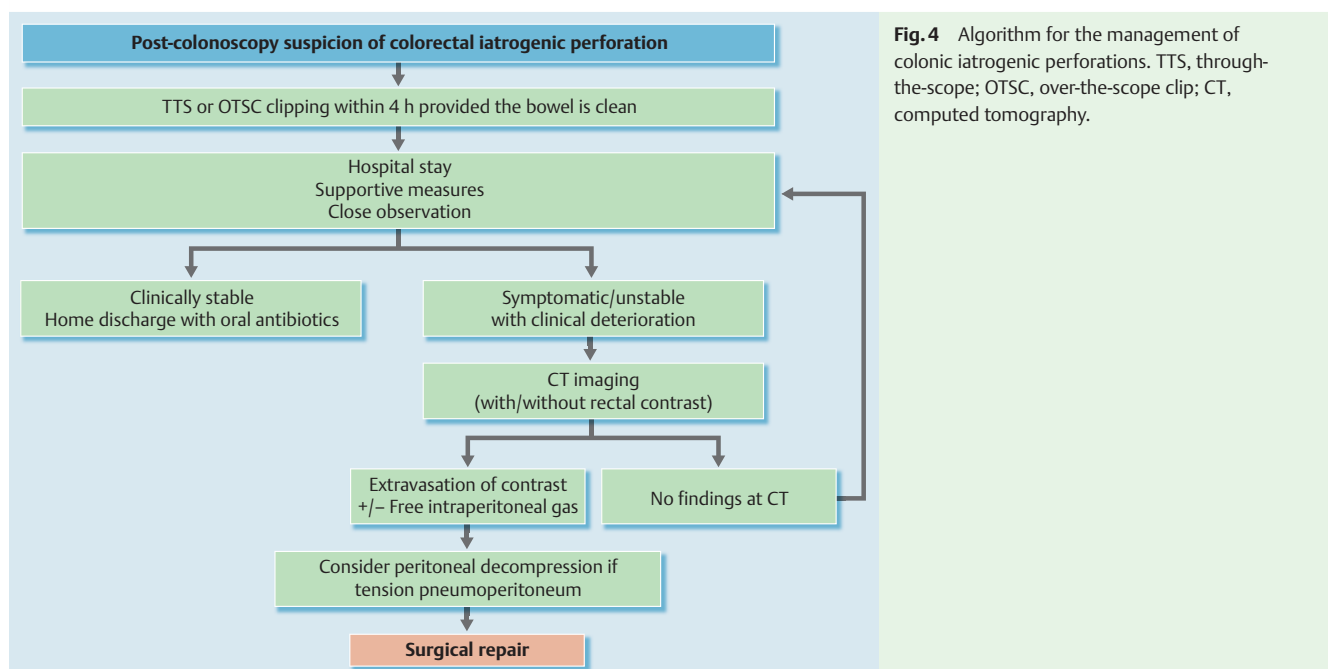


Fig. 4 Algorithm for the management of colonic iatrogenic perforations. TTS, through-the-scope; OTSC, over-the-scope clip; CT, computed tomography.

scopic closure of the defect, superficial apposition of the mucosa and submucosal layers seems sufficient to obtain adequate wound healing at the perforation site and to achieve a good non-surgical outcome [189].

Early endoscopic closure of an iatrogenic perforation smaller than 20 mm, using either TTS clips or OTSC, is likely to be effective, with overall technical and clinical success rates of 93% and 89% respectively [2, 190, 191]. Electrocautery injury may induce colorectal perforations which are amenable to both TTS clip and OTSC clipping, in particular during ESD where there is a high risk of microperforation [68, 178]. It has been reported that TTS clipping is more effective for closure of therapeutic perforations that are less than 10 mm than for diagnostic perforations where defects are blunter and larger in size [192, 193]. Recent systematic reviews based mainly on case series, report that the OTSC technique is also a safe, easy to handle, and efficacious method for treating both diagnostic and therapeutic colorectal perforations [194, 195]. Band ligation has been reported as a salvage therapy after failed clipping [196].

An early endoscopic sign, during the post-polypectomy examination of the resected polyp, is the “target sign” showing full-thickness muscle tissue surrounded by submucosa [26]. In this case, an iatrogenic perforation is strongly suspected and immediate endoscopic clipping is indicated. Occasionally, a perforation is diagnosed post-procedurally and if preparation is still adequate (within 4 hours after the procedure) endoscopic therapy may also be considered (► Fig. 4).

Concomitant administration of intravenous fluids, broad spectrum antibiotics and close monitoring of vital signs are always recommended in each suspected or diagnosed colorectal perforation, to prevent clinical deterioration. Empirical medical treatment should possibly be undertaken promptly, prior to confirmation of perforation by appropriate radiological means.

A clear indication for surgery is a complicated or failed endoscopic closure with an ongoing leak that is causing feculent peritonitis [197]. Minimally invasive laparoscopic treatment of perforations has become the preferred surgical option and is now widely accepted and practiced [198]. Preliminary data have demonstrated that the laparoscopic approach resulted in decreased morbidity and length of hospital stay as well as reduced abdominal wall scarring [199].

Conclusions

Despite the lack of high quality studies, there is substantial evidence, particularly in the colorectum, that a few simple risk factors may be used to stratify the risk of iatrogenic perforation for each organ, allowing anticipation of higher probability of iatrogenic perforation. Moreover, there is compelling evidence that endoscopic treatment by means of clipping or stenting is effective

in the management of iatrogenic perforations, especially for small breaches. Additionally, the wide implementation of CT allows early diagnosis of iatrogenic perforations in subtle cases, preventing harmful delays in conservative or surgical management. All these factors support the implementation of proactive policies to minimize the morbidity and mortality related to iatrogenic perforation. There is an urgent need for high quality studies to clarify the efficacy and safety of the proposed policies. The main issues to be addressed are reported in ► Table 11.

ESGE guidelines represent a consensus of best practice based on the available evidence at the time of preparation. They may not apply in all situations and should be interpreted in the light of specific clinical situations and resource availability. Further controlled clinical studies may be needed to clarify aspects of these statements, and revision may be necessary as new data appear. Clinical consideration may justify a course of action at variance to these recommendations. ESGE guidelines are intended to be an educational device to provide information that may assist endoscopists in providing care to patients. They are not rules and should not be construed as establishing a legal standard of care or as encouraging, advocating, requiring, or discouraging any particular treatment.

Competing interests: None

Institutions

- ¹ Gastroenterology Department, Benizelion General Hospital, Heraklion, Crete, Greece
- ² Gedyt Endoscopy Center, Buenos Aires, Argentina
- ³ LBA UMR T24, Faculty of Medicine, Aix-Marseille University, Marseille, France
- ⁴ Endoscopy Unit, Digestive Disease Center, Bispebjerg Hospital, University of Copenhagen, Copenhagen, Denmark
- ⁵ Department of Gastroenterology, Digestive Endoscopy Unit, IRCCS Istituto Clinico Humanitas, Milan, Italy
- ⁶ Wolfson Unit for Endoscopy, St Mark's Hospital & Imperial College, London, UK
- ⁷ Second Department of Surgery, Aretaieion University Hospital, Athens, Greece
- ⁸ Department of Gastroenterology and Hepatology, Academic Medical Center, University of Amsterdam, Amsterdam, the Netherlands
- ⁹ Digestive Endoscopy Unit, Catholic University, Rome, Italy

References

- ¹ Bielawska B, Day AG, Lieberman DA et al. Risk factors for early colonoscopic perforation include non-gastroenterologist endoscopists: a multivariable analysis. *Clin Gastroenterol Hepatol* 2014; 12: 85–92
- ² Voermans RP, Le Moine O, von Renteln D. Efficacy of endoscopic closure of acute perforations of the gastrointestinal tract. *Clin Gastroenterol Hepatol* 2012; 10: 603–608
- ³ Akobeng AK. Principles of evidence based medicine. *Arch Dis Child* 2005; 90: 837–840
- ⁴ Dumonceau JM, Hassan C, Riphaus A et al. European Society of Gastrointestinal Endosc (ESGE) Guideline Development Policy. *Endoscopy* 2012; 44: 626–629
- ⁵ Jauch EC, Saver JL, Adams HP Jr. et al. Guidelines for the early management of patients with acute ischemic stroke: a guideline for healthcare professionals from the American Heart Association/American Stroke Association. *Stroke* 2013; 44: 870–947
- ⁶ Lu Y, Loffroy R, Lau JY et al. Multidisciplinary management strategies for acute non-variceal upper gastrointestinal bleeding. *Br J Surg* 2014; 101: E34–E50
- ⁷ Cotton PB, Eisen GM, Aabakken L et al. A lexicon for endoscopic adverse events: report of an ASGE workshop. *Gastrointest Endosc* 2010; 71: 446–454

Table 11 Main issues for research

– What is the long-term morbidity of iatrogenic perforations successfully treated with clips?
– What is the necessity of carbon dioxide use during ESD?
– What is the feasibility of combined techniques (endoclips + endoloop) in closing large defects?
– What training is required for inserting OTSCs in the case of iatrogenic perforations?

ESD, endoscopic submucosal dissection; OTSC, over-the-scope clip

- 8 Raju GS, Saito Y, Matsuda T et al. Endoscopic management of colonoscopic perforations (with videos). *Gastrointest Endosc* 2011; 74: 1380–1388
- 9 Baron TH, Wong Kee Song LM, Zielinski MD et al. A comprehensive approach to the management of acute endoscopic perforations (with videos). *Gastrointest Endosc* 2012; 76: 838–859
- 10 Jin YJ, Jeong S, Kim JH et al. Clinical course and proposed treatment strategy for ERCP-related duodenal perforation: a multicenter analysis. *Endoscopy* 2013; 45: 806–812
- 11 Kuppusamy MK, Felisky C, Kozarek RA et al. Impact of endoscopic assessment and treatment on operative and non-operative management of acute oesophageal perforation. *Br J Surg* 2011; 98: 818–824
- 12 Polydorou A, Vezakis A, Fragulidis G et al. A tailored approach to the management of perforations following endoscopic retrograde cholangiopancreatography and sphincterotomy. *J Gastrointest Surg* 2011; 15: 2211–2217
- 13 Anderson ML, Pasha TM, Leighton JA. Endoscopic perforation of the colon: lessons from a 10-year study. *Am J Gastroenterol* 2000; 95: 3418–3422
- 14 Paspatis GA, Vardas E, Theodoropoulou A et al. Complications of colonoscopy in a large public county hospital in Greece. A 10-year study. *Dig Liver Dis* 2008; 40: 951–957
- 15 Kowalczyk L, Forsmark CE, Ben-David K et al. Algorithm for the management of endoscopic perforations: a quality improvement project. *Am J Gastroenterol* 2011; 106: 1022–1027
- 16 Carratt PW Jr., Low DE. Advances in the management of esophageal perforation. *Thorac Surg Clin* 2011; 21: 541–555
- 17 Tamiya Y, Nakahara K, Kominato K et al. Pneumomediastinum is a frequent but minor complication during esophageal endoscopic submucosal dissection. *Endoscopy* 2010; 42: 8–14
- 18 Fujishiro M, Yahagi N, Kakushima N et al. Successful nonsurgical management of perforation complicating endoscopic submucosal dissection of gastrointestinal epithelial neoplasms. *Endoscopy* 2006; 38: 1001–1006
- 19 Maeda Y, Hirasawa D, Fujita N et al. Mediastinal emphysema after esophageal endoscopic submucosal dissection: its prevalence and clinical significance. *Dig Endosc* 2011; 23: 221–226
- 20 Raju GS, Fritscher-Ravens A, Rothstein RI et al. Endoscopic closure of colon perforation compared to surgery in a porcine model: a randomized controlled trial (with videos). *Gastrointest Endosc* 2008; 68: 324–332
- 21 Fritscher-Ravens A, Hampe J, Grange P et al. Clip closure versus endoscopic suturing versus thoracoscopic repair of an iatrogenic esophageal perforation: a randomized, comparative, long-term survival study in a porcine model (with videos). *Gastrointest Endosc* 2010; 72: 1020–1026
- 22 Lin BW, Thanassi W. Tension pneumoperitoneum. *J Emerg Med* 2010; 38: 57–59
- 23 Fu K, Ishikawa T, Yamamoto T et al. Paracentesis for successful treatment of tension pneumoperitoneum related to endoscopic submucosal dissection. *Endoscopy* 2009; 41: E245
- 24 Dellon ES, Hawk JS, Grimm IS et al. The use of carbon dioxide for insufflation during GI endoscopy: a systematic review. *Gastrointest Endosc* 2009; 69: 843–849
- 25 Wang WL, Wu ZH, Sun Q et al. Meta-analysis: the use of carbon dioxide insufflation vs. room air insufflation for gastrointestinal endoscopy. *Aliment Pharmacol Ther* 2012; 35: 1145–1154
- 26 Swan MP, Bourke MJ, Moss A et al. The target sign: an endoscopic marker for the resection of the muscularis propria and potential perforation during colonic endoscopic mucosal resection. *Gastrointest Endosc* 2011; 73: 79–85
- 27 Braga M, Ljungqvist O, Soeters P et al. ESPEN guidelines on parenteral nutrition: surgery. *Clin Nutr* 2009; 28: 378–386
- 28 Fatima J, Baron TH, Topazian MD et al. Pancreaticobiliary and duodenal perforations after periampullary endoscopic procedures: diagnosis and management. *Arch Surg* 2007; 142: 448–454
- 29 Castellvi J, Pi F, Sueiras A et al. Colonoscopic perforation: useful parameters for early diagnosis and conservative treatment. *Int J Colorect Dis* 2011; 26: 1183–1190
- 30 Ben-Menachem T, Decker GA, Early DS et al. Adverse events of upper GI endoscopy. *Gastrointest Endosc* 2012; 76: 707–718
- 31 Soreide JA, Konradsson A, Sandvik OM et al. Esophageal perforation: clinical patterns and outcomes from a patient cohort of Western Norway. *Dig Surg* 2012; 29: 494–502
- 32 Broor SL, Lahoti D, Bose PP et al. Benign esophageal strictures in children and adolescents: etiology, clinical profile, and results of endoscopic dilation. *Gastrointest Endosc* 1996; 43: 474–477
- 33 Karnak I, Tanyel FC, Buyukpamukcu N et al. Esophageal perforations encountered during the dilation of caustic esophageal strictures. *J Cardiovasc Surg (Torino)* 1998; 39: 373–377
- 34 Boeckxstaens GE, Annese V, des Varannes SB et al. Pneumatic dilation versus laparoscopic Heller's myotomy for idiopathic achalasia. *N Engl J Med* 2011; 364: 1807–1816
- 35 Campos GM, Vittinghoff E, Rabl C et al. Endoscopic and surgical treatments for achalasia: a systematic review and meta-analysis. *Ann Surg* 2009; 249: 45–57
- 36 Moss A, Bourke MJ, Hourigan LF et al. Endoscopic resection for Barrett's high-grade dysplasia and early esophageal adenocarcinoma: an essential staging procedure with long-term therapeutic benefit. *Am J Gastroenterol* 2010; 105: 1276–1283
- 37 Pouw RE, Seewald S, Gondrie JJ et al. Stepwise radical endoscopic resection for eradication of Barrett's oesophagus with early neoplasia in a cohort of 169 patients. *Gut* 2010; 59: 1169–1177
- 38 Shimizu Y, Takahashi M, Yoshida T et al. Endoscopic resection (endoscopic mucosal resection/ endoscopic submucosal dissection) for superficial esophageal squamous cell carcinoma: current status of various techniques. *Dig Endosc* 2013; 25: 13–19
- 39 Neuhaus H, Terheggen G, Rutz EM et al. Endoscopic submucosal dissection plus radiofrequency ablation of neoplastic Barrett's esophagus. *Endoscopy* 2012; 44: 1105–1113
- 40 Repici A, Hassan C, Carlino A et al. Endoscopic submucosal dissection in patients with early esophageal squamous cell carcinoma: results from a prospective Western series. *Gastrointest Endosc* 2010; 71: 715–721
- 41 Peng A, Li Y, Xiao Z et al. Study of clinical treatment of esophageal foreign body-induced esophageal perforation with lethal complications. *Eur Arch Otorhinolaryngol* 2012; 269: 2027–2036
- 42 Ukleja A, Afonso BB, Pimentel R et al. Outcome of endoscopic balloon dilation of strictures after laparoscopic gastric bypass. *Surg Endosc* 2008; 22: 1746–1750
- 43 Yoo JH, Shin SJ, Lee KM et al. Risk factors for perforations associated with endoscopic submucosal dissection in gastric lesions: emphasis on perforation type. *Surg Endosc* 2012; 26: 2456–2464
- 44 Imagawa A, Okada H, Kawahara Y et al. Endoscopic submucosal dissection for early gastric cancer: results and degrees of technical difficulty as well as success. *Endoscopy* 2006; 38: 987–990
- 45 Chung IK, Lee JH, Lee SH et al. Therapeutic outcomes in 1000 cases of endoscopic submucosal dissection for early gastric neoplasms: Korean ESD Study Group multicenter study. *Gastrointest Endosc* 2009; 69: 1228–1235
- 46 Toyokawa T, Inaba T, Omote S et al. Risk factors for perforation and delayed bleeding associated with endoscopic submucosal dissection for early gastric neoplasms: analysis of 1123 lesions. *J Gastroenterol Hepatol* 2012; 27: 907–912
- 47 Ben-David K, Lopes J, Hochwald S et al. Minimally invasive treatment of esophageal perforation using a multidisciplinary treatment algorithm: a case series. *Endoscopy* 2011; 43: 160–162
- 48 Kuppusamy MK, Hubka M, Felisky CD et al. Evolving management strategies in esophageal perforation: surgeons using nonoperative techniques to improve outcomes. *J Am Coll Surg* 2011; 213: 164–171
- 49 Soreide JA, Viste A. Esophageal perforation: diagnostic work-up and clinical decision-making in the first 24 hours. *Scand J Trauma Resusc Emerg Med* 2011; 19: 66
- 50 Bhatia P, Fortin D, Inculet RI et al. Current concepts in the management of esophageal perforations: a twenty-seven year Canadian experience. *Ann Thorac Surg* 2011; 92: 209–215
- 51 Qadeer MA, Dumot JA, Vargo JJ et al. Endoscopic clips for closing esophageal perforations: case report and pooled analysis. *Gastrointest Endosc* 2007; 66: 605–611
- 52 Daram SR, Tang SJ, Wu R et al. Benchtop testing and comparisons among three types of through-the-scope endoscopic clipping devices. *Surg Endosc* 2013; 27: 1521–1529
- 53 van Boeckel PG, Sijbring A, Vleggaar FP et al. Systematic review: temporary stent placement for benign rupture or anastomotic leak of the oesophagus. *Aliment Pharmacol Ther* 2011; 33: 1292–1301
- 54 Johnsson E, Lundell L, Liedman B. Sealing of esophageal perforation or ruptures with expandable metallic stents: a prospective controlled study on treatment efficacy and limitations. *Dis Esoph* 2005; 18: 262–266

- 55 van Heel NC, Haringsma J, Spaander MC et al. Short-term esophageal stenting in the management of benign perforations. *Am J Gastroenterol* 2010; 105: 1515–1520
- 56 Seven G, Irani S, Ross AS et al. Partially versus fully covered self-expanding metal stents for benign and malignant esophageal conditions: a single center experience. *Surg Endosc* 2013; 27: 2185–2192
- 57 Ahrens M, Schulte T, Egberts J et al. Drainage of esophageal leakage using endoscopic vacuum therapy: a prospective pilot study. *Endoscopy* 2010; 42: 693–698
- 58 Loske G, Schorsch T, Muller C. Intraluminal and intracavitary vacuum therapy for esophageal leakage: a new endoscopic minimally invasive approach. *Endoscopy* 2011; 43: 540–544
- 59 Vallbohmer D, Holscher AH, Holscher M et al. Options in the management of esophageal perforation: analysis over a 12-year period. *Dis Esoph* 2010; 23: 185–190
- 60 Dumonceau JM, Cremer M, Lalmand B et al. Esophageal fistula sealing: choice of stent, practical management, and cost. *Gastrointest Endosc* 1999; 49: 70–78
- 61 Biancari F, D'Andrea V, Paone R et al. Current treatment and outcome of esophageal perforations in adults: systematic review and meta-analysis of 75 studies. *World J Surg* 2013; 37: 1051–1059
- 62 Merchea A, Cullinane DC, Sawyer MD et al. Esophagogastroduodenoscopy-associated gastrointestinal perforations: a single-center experience. *Surgery* 2010; 148: 876–880
- 63 Minami S, Gotoda T, Ono H et al. Complete endoscopic closure of gastric perforation induced by endoscopic resection of early gastric cancer using endoclips can prevent surgery (with video). *Gastrointest Endosc* 2006; 63: 596–601
- 64 Han JH, Lee TH, Jung Y et al. Rescue endoscopic band ligation of iatrogenic gastric perforations following failed endoclip closure. *World J Gastroenterol* 2013; 19: 955–959
- 65 Mangiavillano B, Viaggi P, Masci E. Endoscopic closure of acute iatrogenic perforations during diagnostic and therapeutic endoscopy in the gastrointestinal tract using metallic clips: a literature review. *J Dig Dis* 2010; 11: 12–18
- 66 Surace M, Mercky P, Demarquay J-F et al. Endoscopic management of GI fistulae with the over-the-scope clip system (with video). *Gastrointest Endosc* 2011; 74: 1416–1419
- 67 von Renteln D, Denzer UW, Schachschal G et al. Endoscopic closure of GI fistulae by using an over-the-scope clip (with videos). *Gastrointest Endosc* 2010; 72: 1289–1296
- 68 Parodi A, Repici A, Pedroni A et al. Endoscopic management of GI perforations with a new over-the-scope clip device (with videos). *Gastrointest Endosc* 2010; 72: 881–886
- 69 Manta R, Manno M, Bertani H et al. Endoscopic treatment of gastrointestinal fistulas using an over-the-scope clip (OTSC) device: case series from a tertiary referral center. *Endoscopy* 2011; 43: 545–548
- 70 Kirschniak A, Subotova N, Zieker D et al. The Over-The-Scope Clip (OTSC) for the treatment of gastrointestinal bleeding, perforations, and fistulas. *Surg Endosc* 2011; 25: 2901–2905
- 71 Baron TH, Song LM, Ross A et al. Use of an over-the-scope clipping device: multicenter retrospective results of the first U.S. experience (with videos). *Gastrointest Endosc* 2012; 76: 202–208
- 72 Nishiyama N, Mori H, Kobara H et al. Efficacy and safety of over-the-scope clip: including complications after endoscopic submucosal dissection. *World J Gastroenterol* 2013; 19: 2752–2760
- 73 Martinek J, Ryska O, Tuckova I et al. Comparing over-the-scope clip versus endoloop and clips (KING closure) for access site closure: a randomized experimental study. *Surg Endosc* 2013; 27: 1203–1210
- 74 Matsuda T, Fujii T, Emura F et al. Complete closure of a large defect after EMR of a lateral spreading colorectal tumor when using a two-channel colonoscope. *Gastrointest Endosc* 2004; 60: 836–838
- 75 Ladas SD, Kamberoglou D, Vlachogiannakos J et al. Combined use of metallic endoclips and endoloops using a single-channel scope in closing iatrogenic perforations and fistulas: two case reports and a literature review. *Eur J Gastroenterol Hepatol* 2014; 26: 119–122
- 76 Tsunada S, Ogata S, Ohyama T et al. Endoscopic closure of perforations caused by EMR in the stomach by application of metallic clips. *Gastrointest Endosc* 2003; 57: 948–951
- 77 Iwashita T, Lee JG, Nakai Y et al. Successful management of perforation during cystogastrostomy with an esophageal fully covered metallic stent placement. *Gastrointest Endosc* 2012; 76: 214–215
- 78 Eroglu A, Turkyilmaz A, Aydin Y et al. Current management of esophageal perforation: 20 years experience. *Dis Esoph* 2009; 22: 374–380
- 79 Freeman RK, Van Woerkom JM, Vyverberg A et al. Esophageal stent placement for the treatment of spontaneous esophageal perforations. *Ann Thorac Surg* 2009; 88: 194–198
- 80 Salminen P, Gullichsen R, Laine S. Use of self-expandable metal stents for the treatment of esophageal perforations and anastomotic leaks. *Surg Endosc* 2009; 23: 1526–1530
- 81 Amrani L, Menard C, Berdah S et al. From iatrogenic digestive perforation to complete anastomotic disunion: endoscopic stenting as a new concept of "stent-guided regeneration and re-epithelialization". *Gastrointest Endosc* 2009; 69: 1282–1287
- 82 Leers JM, Vivaldi C, Schäfer H et al. Endoscopic therapy for esophageal perforation or anastomotic leak with a self-expandable metallic stent. *Surg Endosc* 2009; 10: 2258–2262
- 83 Kiernan PD, Khandhar SJ, Fortes DL et al. Thoracic esophageal perforations. *Am Surg* 2010; 76: 1355–1362
- 84 Schmidt SC, Strauch S, Rosch T et al. Management of esophageal perforations. *Surg Endosc* 2010; 24: 2809–2813
- 85 Swinnen J, Eisendrath P, Rigaux J et al. Self-expandable metal stents for the treatment of benign upper GI leaks and perforations. *Gastrointest Endosc* 2011; 73: 890–899
- 86 Lazar Gjr, Paszt A, Simonka Z et al. A successful strategy for surgical treatment of Boerhaave's syndrome. *Surg Endosc* 2011; 25: 3613–3619
- 87 Dai Y, Chopra SS, Kneif S et al. Management of esophageal anastomotic leaks, perforations, and fistulae with self-expanding plastic stents. *J Thorac Cardiovasc Surg* 2011; 141: 1213–1217
- 88 D'Cunha J, Rueth NM, Groth SS et al. Esophageal stents for anastomotic leaks and perforations. *J Thorac Cardiovasc Surg* 2011; 142: 39–46
- 89 Lin Y, Jiang G, Liu L et al. Management of thoracic esophageal perforation. *World J Surg* 2014; 38: 1093–1099
- 90 Biancari F, Gudbjartsson T, Mennander A et al. Treatment of esophageal perforation in octogenarians: a multicenter study. *Dis Esoph Oct 10* [Epub ahead of print] 2013
- 91 Wilson JL, Louie BE, Farivar AS et al. Fully covered self-expanding metal stents are effective for benign esophagogastric disruptions and strictures. *J Gastrointest Surg* 2013; 17: 2045–2050
- 92 Wahed S, Dent B, Jones R et al. Spectrum of oesophageal perforations and their influence on management. *Br J Surg* 2014; 101: E156–E162
- 93 Schweigert M, Beattie R, Solymosi N et al. Endoscopic stent insertion versus primary operative management for spontaneous rupture of the esophagus (Boerhaave syndrome): an international study comparing the outcome. *Am Surg* 2013; 79: 634–640
- 94 Sato H, Inoue H, Ikeda H et al. Clinical experience of esophageal perforation occurring with endoscopic submucosal dissection. *Dis Esoph Aug 27* [Epub ahead of print] 2013
- 95 Heits N, Stapel L, Reichert B et al. Endoscopic endoluminal vacuum therapy in esophageal perforation. *Ann Thorac Surg* 2014; 97: 1029–1035
- 96 Hadj Amor WB, Bonin EA, Vitton V et al. Successful endoscopic management of large upper gastrointestinal perforations following EMR using over-the-scope clipping combined with stenting. *Endoscopy* 2012; 44: E277–E278
- 97 Biancari F, Saarnio J, Mennander A et al. Outcome of patients with esophageal perforations: a multicenter study. *World J Surg* 2014; 38: 902–909
- 98 Binmoeller KF, Grimm H, Soehendra N. Endoscopic closure of a perforation using metallic clips after snare excision of a gastric leiomyoma. *Gastrointest Endosc* 1993; 39: 172–174
- 99 Albuquerque W, Arantes V. Large gastric perforation after endoscopic mucosal resection treated by application of metallic clips (video). *Endoscopy* 2004; 36: 752–753
- 100 Katsinelos P, Beltsis A, Paroutoglou G et al. Endoclippping for gastric perforation after endoscopic polypectomy: an alternative treatment to avoid surgery. *Surg Laparosc Endosc Percutan Tech* 2004; 14: 279–281
- 101 De Caro G, Pagano N, Malesci A et al. Endoclippping for gastric perforation secondary to second session of EMRC in locally residual early gastric cancer: a case report. *Dig Liver Dis* 2009; 41: E32–E34
- 102 Kim HS, Lee DK, Jeong YS et al. Successful endoscopic management of a perforated gastric dysplastic lesion after endoscopic mucosal resection. *Gastrointest Endosc* 2000; 51: 613–615
- 103 Shi Q, Chen T, Ren Z et al. [Complete closure of large gastric defects after endoscopic full-thickness resection, using endoloop and metallic clip interrupted suture. *Endoscopy* 2013; 45: 329–334
- 104 Zhong Y, Shi Q, Yao L et al. [Complete closure of gastric wall defect after endoscopic full-thick resection with metal clips and endoloop

- snare]. *Zhonghua Wei Chang Wai Ke Za Zhi* (Chinese Journal of Gastrointestinal Surgery) 2012; 15: 280–284 [Article in Chinese]
- 105 *Andriulli A, Loperfido S, Napolitano G* et al. Incidence rates of post-ERCP complications: a systematic survey of prospective studies. *Am J Gastroenterol* 2007; 102: 1781–1788
 - 106 *Enns R, Eloubeidi MA, Mergener K* et al. ERCP-related perforations: risk factors and management. *Endoscopy* 2002; 34: 293–298
 - 107 *Loperfido S, Angelini G, Benedetti G* et al. Major early complications from diagnostic and therapeutic ERCP: a prospective multicenter study. *Gastrointest Endosc* 1998; 48: 1–10
 - 108 *Stapfer M, Selby RR, Stain SC* et al. Management of duodenal perforation after endoscopic retrograde cholangiopancreatography and sphincterotomy. *Ann Surg* 2000; 232: 191–198
 - 109 *Machado NO*. Management of duodenal perforation post-endoscopic retrograde cholangiopancreatography. When and whom to operate and what factors determine the outcome? A review article *JOP* 2012; 13: 18–25
 - 110 *Howard TJ, Tan T, Lehman GA* et al. Classification and management of perforations complicating endoscopic sphincterotomy. *Surgery* 1999; 126: 658–663
 - 111 *Preetha M, Chung YF, Chan WH* et al. Surgical management of endoscopic retrograde cholangiopancreatography-related perforations. *ANZ J Surg* 2003; 73: 1011–1014
 - 112 *Alfieri S, Rosa F, Cina C* et al. Management of duodeno-pancreato-biliary perforations after ERCP: outcomes from an Italian tertiary referral center. *Surg Endosc* 2013; 27: 2005–2012
 - 113 *Shami VM, Talreja JP, Mahajan A* et al. EUS-guided drainage of bilomas: a new alternative? *Gastrointest Endosc* 2008; 67: 136–140
 - 114 *Chung RS, Sivak MV, Ferguson DR*. Surgical decisions in the management of duodenal perforation complicating endoscopic sphincterotomy. *Am J Surg* 1993; 165: 700–703
 - 115 *Kayhan B, Akdogan M, Sahin B*. ERCP subsequent to retroperitoneal perforation caused by endoscopic sphincterotomy. *Gastrointest Endosc* 2004; 60: 833–835
 - 116 *Knudson K, Raeburn CD, McIntyre RC* et al. Management of duodenal and pancreaticobiliary perforations associated with periampullary endoscopic procedures. *Am J Surg* 2008; 196: 975–981
 - 117 *Rahbour G, Siddiqui MR, Ullah MR* et al. A meta-analysis of outcomes following use of somatostatin and its analogues for the management of enterocutaneous fistulas. *Ann Surg* 2012; 256: 946–954
 - 118 *Coughlin S, Roth L, Lurati G* et al. Somatostatin analogues for the treatment of enterocutaneous fistulas: a systematic review and meta-analysis. *World J Surg* 2012; 36: 1016–1029
 - 119 *Koti RS, Gurusamy KS, Fusai G* et al. Meta-analysis of randomized controlled trials on the effectiveness of somatostatin analogues for pancreatic surgery: a Cochrane review. *HPB (Oxford)* 2010; 12: 155–165
 - 120 *Assalia A, Suissa A, Ilivitzki A* et al. Validity of clinical criteria in the management of endoscopic retrograde cholangiopancreatography related duodenal perforations. *Arch Surg* 2007; 142: 1059–1064
 - 121 *Avgerinos DV, Llaguna OH, Lo AY* et al. Management of endoscopic retrograde cholangiopancreatography: related duodenal perforations. *Surg Endosc* 2009; 23: 833–838
 - 122 *Dubecz A, Ottmann J, Schweigert M* et al. Management of ERCP-related small bowel perforations: the pivotal role of physical investigation. *Can J Surg* 2012; 55: 99–104
 - 123 *Kim BS, Kim IG, Ryu BY* et al. Management of endoscopic retrograde cholangiopancreatography-related perforations. *J Korean Surg Soc* 2011; 81: 195–204
 - 124 *Kim J, Lee SH, Paik WH* et al. Clinical outcomes of patients who experienced perforation associated with endoscopic retrograde cholangiopancreatography. *Surg Endosc* 2012; 26: 3293–3300
 - 125 *Kwon W, Jang J-Y, Ryu JK* et al. Proposal of an endoscopic retrograde cholangiopancreatography-related perforation management guideline based on perforation type. *J Korean Surg Soc* 2012; 83: 218–226
 - 126 *Mao Z, Zhu Q, Wu W* et al. Duodenal perforations after endoscopic retrograde cholangiopancreatography: experience and management. *J Laparoendosc Adv Surg Tech A* 2008; 18: 691–695
 - 127 *Morgan KA, Fontenot BB, Ruddy JM* et al. Endoscopic retrograde cholangiopancreatography gut perforations: when to wait! When to operate! *Am Surg* 2009; 75: 477–483
 - 128 *Wu HM, Dixon E, May GR* et al. Management of perforation after endoscopic retrograde cholangiopancreatography (ERCP): a population-based review. *HPB (Oxford)* 2006; 8: 393–399
 - 129 *Jung JH, Choi KD, Ahn JY* et al. Endoscopic submucosal dissection for sessile, nonampullary duodenal adenomas. *Endoscopy* 2013; 45: 133–135
 - 130 *Hanaoka N, Uedo N, Ishihara R* et al. Clinical features and outcomes of delayed perforation after endoscopic submucosal dissection for early gastric cancer. *Endoscopy* 2010; 42: 1112–1115
 - 131 *Abe Y, Inamori M, Iida H* et al. Clinical characteristics of patients with gastric perforation following endoscopic submucosal resection for gastric cancer. *Hepatogastroenterology* 2009; 56: 921–924
 - 132 *Saito Y, Fukuzawa M, Matsuda T* et al. Clinical outcome of endoscopic submucosal dissection versus endoscopic mucosal resection of large colorectal tumors as determined by curative resection. *Surg Endosc* 2010; 24: 343–352
 - 133 *Conio M, De Ceglie A, Filiberti R* et al. Cap-assisted EMR of large, sporadic, nonampullary duodenal polyps. *Gastrointest Endosc* 2012; 76: 1160–1169
 - 134 *Alexander S, Bourke MJ, Williams SJ* et al. EMR of large, sessile, sporadic nonampullary duodenal adenomas: technical aspects and long-term outcome (with videos). *Gastrointest Endosc* 2009; 69: 66–73
 - 135 *Moschler O, May A, Muller MK* et al. Complications in and performance of double-balloon enteroscopy (DBE): results from a large prospective DBE database in Germany. *Endoscopy* 2011; 43: 484–489
 - 136 *Gerson LB, Tokar J, Chiorean M* et al. Complications associated with double balloon enteroscopy at nine US centers. *Clin Gastroenterol Hepatol* 2009; 7: 1177–1182
 - 137 *Palmer JS, Marenah K, El Madani F* et al. Small bowel perforation following capsule endoscopy: a case report. *Ann R Coll Surg Engl* 2011; 93: E69–E70
 - 138 *Yitzhak A, Bayme M, Perry ZH* et al. Small bowel perforation after capsule endoscopy in a patient with occult gastrointestinal bleeding and undiagnosed Crohn's disease. *Am Surg* 2012; 78: E159–E161
 - 139 *Um S, Poblete H, Zavotsky J*. Small bowel perforation caused by an impacted endocapsule. *Endoscopy* 2008; 40: E122–E123
 - 140 *Despott EJ, Gupta A, Burling D* et al. Effective dilation of small-bowel strictures by double-balloon enteroscopy in patients with symptomatic Crohn's disease (with video). *Gastrointest Endosc* 2009; 70: 1030–1036
 - 141 *Espinel J, Pinedo E*. Stenosis in gastric bypass: Endoscopic management. *World J Gastrointest Endosc* 2012; 4: 290–295
 - 142 *Donatelli G, Vergeau BM, Dritsas S* et al. Closure with an over-the-scope clip allows therapeutic ERCP to be safely performed after acute duodenal perforation during diagnostic endoscopic ultrasound. *Endoscopy* 2013; 45: E392–E393
 - 143 *Balmadrid B, Ross A*. Severe laceration in a percutaneous endoscopic jejunostomy placement resolved with over-the-scope clips. *Gastrointest Endosc* 2013; 45: 783–784
 - 144 *Palanivelu C, Jategaonkar PA, Rangarajan M* et al. Laparoscopic management of a retroperitoneal duodenal perforation following ERCP for periampullary cancer. *JLS* 2008; 12: 399–402
 - 145 *Ahllawat SK, Haddad N*. Repair of an EUS-induced duodenal perforation with endoscopic clips. *Acta Gastroenterol Belg* 2009; 72: 361–364
 - 146 *Honda T, Yamamoto H, Osawa H* et al. Endoscopic submucosal dissection for superficial duodenal neoplasms. *Dig Endosc* 2009; 21: 270–274
 - 147 *Nakagawa Y, Nagai T, Soma W* et al. Endoscopic closure of a large ERCP-related lateral duodenal perforation by using endoloops and endoclips. *Gastrointest Endosc* 2010; 72: 216–217
 - 148 *Farhat S, Chaussade S, Ponchon T* et al. Endoscopic submucosal dissection in a European setting. A multi-institutional report of a technique in development. *Endoscopy* 2011; 43: 664–670
 - 149 *Lee TH, Bang BW, Jeong JI* et al. Primary endoscopic approximation suture under cap-assisted endoscopy of an ERCP-induced duodenal perforation. *World J Gastroenterol* 2010; 16: 2305–2310
 - 150 *Ercan M, Bostanci EB, Dalgic T* et al. Surgical outcome of patients with perforation after endoscopic retrograde cholangiopancreatography. *J Laparoendosc Adv Surg Tech A* 2012; 22: 371–377
 - 151 *Fanning SB, Bourke MJ, Williams SJ* et al. Giant laterally spreading tumors of the duodenum: endoscopic resection outcomes, limitations, and caveats. *Gastrointest Endosc* 2012; 75: 805–812
 - 152 *Samarasena JB, Nakai Y, Park DH* et al. Endoscopic closure of an iatrogenic duodenal perforation: a novel technique using endoclips, endoloop, and fibrin glue. *Endoscopy* 2012; 44: E424–E425

- 153 Gubler C, Bauerfeind P. Endoscopic closure of iatrogenic gastrointestinal tract perforations with the over-the-scope clip. *Digestion* 2012; 85: 292–307
- 154 Matsumoto S, Miyatani H, Yoshida Y. Endoscopic submucosal dissection for duodenal tumors: a single-center experience. *Endoscopy* 2013; 45: 136–137
- 155 Rabie ME, Mir NH, Al Skaini MS et al. Operative and non-operative management of endoscopic retrograde cholangiopancreatography-associated duodenal injuries. *Ann R Coll Surg Engl* 2013; 95: 285–290
- 156 Teruel C, Garcia XA, Ledo A et al. Small intestine perforation after colonoscopy: rare complication in patients with previous abdominal surgery. *Endoscopy* 2009; 41: E116
- 157 Campos JM, Mello FS, Ferraz AA et al. Endoscopic dilation of gastrojejunal anastomosis after gastric bypass. *Arq Bras Cir Dig* 2012; 25: 283–289
- 158 Korman LY, Overholt BF, Box T et al. Perforation during colonoscopy in endoscopic ambulatory surgical centers. *Gastrointest Endosc* 2003; 58: 554–557
- 159 Rabeneck L, Paszat LF, Hilsden RJ et al. Bleeding and perforation after outpatient colonoscopy and their risk factors in usual clinical practice. *Gastroenterology* 2008; 135: 1899–1906
- 160 Saunders BP, Fukumoto M, Halligan S et al. Why is colonoscopy more difficult in women? *Gastrointest Endosc* 1996; 43: 124–126
- 161 Navaneethan U, Kochhar G, Phull H et al. Severe disease on endoscopy and steroid use increase the risk for bowel perforation during colonoscopy in inflammatory bowel disease patients. *J Crohns Colitis* 2012; 6: 470–475
- 162 Rutter MD, Saunders BP, Wilkinson KH et al. Thirty-year analysis of a colonoscopic surveillance program for neoplasia in ulcerative colitis. *Gastroenterology* 2006; 130: 1030–1038
- 163 Luning TH, Keemers-Gels ME, Barendregt WB et al. Colonoscopic perforations: a review of 30,366 patients. *Surg Endosc* 2007; 21: 994–997
- 164 Putcha RV, Burdick JS. Management of iatrogenic perforation. *Gastroenterol Clin North Am* 2003; 32: 1289–1309
- 165 Tribonias G, Konstantinidis K, Theodoropoulou A et al. Rectal perforation caused by colonoscopic retroflexion. *Gastrointest Endosc* 2010; 71: 662
- 166 Loffeld RJ, Engel A, Dekkers PE. Incidence and causes of colonoscopic perforations: a single-center case series. *Endoscopy* 2011; 43: 240–242
- 167 Stock C, Ihle P, Sieg A et al. Adverse events requiring hospitalization within 30 days after outpatient screening and nonscreening colonoscopies. *Gastrointest Endosc* 2013; 77: 419–429
- 168 Lee TJ, Rutter MD, Blanks RG et al. Colonoscopy quality measures: experience from the NHS Bowel Cancer Screening Programme. *Gut* 2012; 61: 1050–1057
- 169 Rabeneck L, Saskin R, Paszat LF. Onset and clinical course of bleeding and perforation after outpatient colonoscopy: a population-based study. *Gastrointest Endosc* 2011; 73: 520–523
- 170 Saunders BP, Brown CJ, Lemann M et al. Balloon dilation of ileocolonic strictures in Crohn's disease. *Endoscopy* 2004; 36: 1001–1007
- 171 Small AJ, Coelho-Prabhu N, Baron TH. Endoscopic placement of self-expandable metal stents for malignant colonic obstruction: long-term outcomes and complication factors. *Gastrointest Endosc* 2010; 71: 560–572
- 172 Suzuki N, Saunders BP, Thomas-Gibson S et al. Colorectal stenting for malignant and benign disease: outcomes in colorectal stenting. *Dis Colon Rectum* 2004; 47: 1201–1207
- 173 Bowles CJ, Leicester R, Romaya C et al. A prospective study of colonoscopy practice in the UK today: are we adequately prepared for national colorectal cancer screening tomorrow? *Gut* 2004; 53: 277–283
- 174 Heldwein W, Dollhopf M, Rosch T et al. The Munich Polypectomy Study (MUPS): prospective analysis of complications and risk factors in 4000 colonic snare polypectomies. *Endoscopy* 2005; 37: 1116–1122
- 175 Heresbach D, Kornhauser R, Seyrig JA et al. A national survey of endoscopic mucosal resection for superficial gastrointestinal neoplasia. *Endoscopy* 2010; 42: 806–813
- 176 Moss A, Bourke MJ, Williams SJ et al. Endoscopic mucosal resection outcomes and prediction of submucosal cancer from advanced colonic mucosal neoplasia. *Gastroenterology* 2011; 140: 1909–1918
- 177 Buchner AM, Guarner-Argente C, Ginsberg GG. Outcomes of EMR of defiant colorectal lesions directed to an endoscopy referral center. *Gastrointest Endosc* 2012; 76: 255–263
- 178 Kim ES, Cho KB, Park KS et al. Factors predictive of perforation during endoscopic submucosal dissection for the treatment of colorectal tumors. *Endoscopy* 2011; 43: 573–578
- 179 Toyonaga T, Man-i M, East JE et al. 1,635 Endoscopic submucosal dissection cases in the esophagus, stomach, and colorectum: complication rates and long-term outcomes. *Surg Endosc* 2013; 27: 1000–1008
- 180 Tanaka S, Terasaki M, Kanao H et al. Current status and future perspectives of endoscopic submucosal dissection for colorectal tumors. *Dig Endosc* 2012; 24: 73–79
- 181 Repici A, Hassan C, De Paula Pessoa D et al. Efficacy and safety of endoscopic submucosal dissection for colorectal neoplasia: a systematic review. *Endoscopy* 2012; 44: 137–150
- 182 Metz AJ, Moss A, McLeod D et al. A blinded comparison of the safety and efficacy of hot biopsy forceps electrocauterization and conventional snare polypectomy for diminutive colonic polypectomy in a porcine model. *Gastrointest Endosc* 2013; 77: 484–490
- 183 Zissin R, Hertz M, Osadchy A et al. Abdominal CT findings in nontraumatic colorectal perforation. *Eur J Radiol* 2008; 65: 125–132
- 184 Iqbal CW, Cullinane DC, Schiller HJ et al. Surgical management and outcomes of 165 colonoscopic perforations from a single institution. *Arch Surg* 2008; 143: 701–706
- 185 Ignjatovic A, Saunders BP. A clinical case of delayed caecal perforation. *Gut* 2009; 58: 1170–1171
- 186 La Torre M, Velluti F, Giuliani G et al. Promptness of diagnosis is the main prognostic factor after colonoscopic perforation. *Colorectal Dis* 2012; 14: E23–E26
- 187 Bassan MS, Holt B, Moss A et al. Carbon dioxide insufflation reduces number of postprocedure admissions after endoscopic resection of large colonic lesions: a prospective cohort study. *Gastrointest Endosc* 2013; 77: 90–95
- 188 Gayer G, Hertz M, Zissin R. Postoperative pneumoperitoneum: prevalence, duration, and possible significance. *Semin Ultrasound CT MR* 2004; 25: 286–289
- 189 Raju GS, Ahmed I, Xiao SY et al. Controlled trial of immediate endoluminal closure of colon perforations in a porcine model by use of a novel clip device (with videos). *Gastrointest Endosc* 2006; 64: 989–997
- 190 Magdeburg R, Collet P, Post S et al. Endoclipping of iatrogenic colonic perforation to avoid surgery. *Surg Endosc* 2008; 22: 1500–1504
- 191 Byeon JS. Colonic perforation: can we manage it endoscopically? *Clin Endosc* 2013; 46: 495–499
- 192 Magdeburg R, Sold M, Post S et al. Differences in the endoscopic closure of colonic perforation due to diagnostic or therapeutic colonoscopy. *Scand J Gastroenterol* 2013; 48: 862–867
- 193 Jovanovic I, Zimmermann L, Fry LC et al. Feasibility of endoscopic closure of an iatrogenic colon perforation occurring during colonoscopy. *Gastrointest Endosc* 2011; 73: 550–555
- 194 Singhal S, Changela K, Papafragkakis H et al. Over the scope clip: technique and expanding clinical applications. *J Clin Gastroenterol* 2013; 47: 749–756
- 195 Weiland T, Fehker M, Gottwald T et al. Performance of the OTSC System in the endoscopic closure of iatrogenic gastrointestinal perforations: a systematic review. *Surg Endosc* 2013; 27: 2258–2274
- 196 Han JH, Park S, Youn S. Endoscopic closure of colon perforation with band ligation; salvage technique after endoclip failure. *Clin Gastroenterol Hepatol* 2011; 9: E54–E55
- 197 Cho SB, Lee WS, Joo YE et al. Therapeutic options for iatrogenic colon perforation: feasibility of endoscopic clip closure and predictors of the need for early surgery. *Surg Endosc* 2012; 26: 473–479
- 198 Pilgrim CH, Nottle PD. Laparoscopic repair of iatrogenic colonic perforation. *Surg Laparosc Endosc Percutan Tech* 2007; 17: 215–217
- 199 Bleier JL, Moon V, Feingold D et al. Initial repair of iatrogenic colon perforation using laparoscopic methods. *Surg Endosc* 2008; 22: 646–649