

Cardiovascular Hybrid Imaging using PET/MRI

Kardiovaskuläre Hybridbildgebung mit PET/MRT

Authors

Felix Nensa, Thomas Schlosser

Affiliation

Institute of Diagnostic and Interventional Radiology and Neuroradiology, University Hospital Essen

Key words

- cardiac
- heart
- PET
- MR-imaging
- molecular imaging
- radionuclide imaging

received 3.3.2014
accepted 5.7.2014

Bibliography

DOI <http://dx.doi.org/10.1055/s-0034-1385009>
Published online: 3.9.2014
Fortschr Röntgenstr 2014; 186: 1094–1101 © Georg Thieme Verlag KG Stuttgart · New York · ISSN 1438-9029

Correspondence

Dr. Felix Nensa
Institute of Diagnostic and Interventional Radiology and Neuroradiology, University Hospital Essen
Hufelandstraße 55
45147 Essen
Germany
Tel.: ++49/201/72 38 45 95
Fax: ++49/201/7 23 15 48
Felix.Nensa@uk-essen.de

Abstract



The following overview provides a summary of the state of the art and research as well as potential clinical applications of cardiovascular PET/MR imaging. PET/MRI systems have been clinically available for a few years, and their use in cardiac imaging has been successfully demonstrated. At this period in time, some of the technical difficulties that arose at the beginning have been solved; in particular with respect to MRI-based attenuation correction, caution should be exercised with PET quantification. In addition, many promising technical options are still in the developmental stage, such as MRI-based motion correction of PET data resulting from simultaneous MR acquisition, and are not yet available for cardiovascular imaging. On the other hand, PET/MRI has been used to demonstrate significant pathologies such as acute and chronic myocardial infarction, myocarditis or cardiac sarcoidosis; future applications in clinical routine or within studies appear to be possible. In coming years additional studies will have to be performed to prove diagnostic gain at a reasonable cost-benefit ratio before valid conclusions are possible regarding the clinical utility and future of cardiovascular PET/MR imaging.

Key Points:

- ▶ The feasibility of cardiovascular PET/MRI has been successfully demonstrated and application in clinical routine is possible.
- ▶ Initial experience suggests added value of PET/MRI with FDG in pathologies like acute myocardial infarction, myocarditis, cardiac sarcoidosis and cardiac tumors.
- ▶ Technical improvements in the field of attenuation correction and MRI-based motion correction as well as new PET tracers could result in new applications for cardiovascular PET/MRI in next years.

Citation Format:

- ▶ Nensa Felix. Kardiovaskuläre Hybridbildgebung mit PET/MRT. Fortschr Röntgenstr 2014; 186: 1094–1101

Zusammenfassung



Die folgende Übersichtsarbeit gibt eine kurze Zusammenfassung zum Stand der Technik und Forschung sowie zu potentiellen klinischen Einsatzgebieten der kardiovaskulären PET/MRT Bildgebung. Nachdem PET/MRT Systeme seit wenigen Jahren klinisch verfügbar sind, konnte deren Einsatz bei der Herzbildgebung bereits erfolgreich demonstriert werden. Zum gegenwärtigen Zeitpunkt sind bereits einige technische Schwierigkeiten aus der Anfangszeit gelöst, wobei insbesondere in Bezug auf die MRT basierte Schwächungskorrektur weiterhin Vorsicht bei der PET Quantifizierung geboten ist. Auch befinden sich vielversprechende technische Möglichkeiten, wie die MRT-basierte Bewegungskorrektur der PET-Daten, die sich durch die simultane Akquisition ergeben, noch in einem frühen Entwicklungsstadium und sind noch nicht für die kardiovaskuläre Bildgebung verfügbar. Demgegenüber wurden bereits einige wichtige Pathologien, wie akute und chronische Herzinfarkte, Myokarditis oder kardiale Sarkoidose mittels PET/MRT dargestellt und zukünftige Anwendungen in der klinischen Routine oder innerhalb von Studien erscheinen möglich. In den nächsten Jahren werden weitere Studien zunächst einen diagnostischen Zugewinn bei vertretbarem Kosten-Nutzen-Verhältnis belegen müssen, bevor valide Aussagen zur klinischen Wertigkeit und Zukunft der kardiovaskulären PET/MRT Bildgebung möglich sind.

Introduction

Currently MRI has very high value when clinically assessing cardiovascular characteristics, including the quantification of left and right ventricular function, myocardial perfusion, blood flow measurement in vessels next to the heart, MR angiography, assessment of global and regional wall motion abnormalities and valve function as well as multi-parametric tissue classification. On the other hand, PET imaging represents the gold standard for various cardiovascular issues. PET imaging supports, among other things, precise quantification of resting myocardial perfusion and coronary blood flow reserve, direct and specific visualization of metabolic processes as well as quantification on the molecular level. Although there is some overlap between both modalities, there are some applications in which complementary information can be obtained via simultaneous PET/MR imaging in the case of cardiovascular issues. The following overview provides a summary of the state of the art in research as well as potential clinical applications of cardiovascular PET/MR imaging.

Technology

Scanner

Several approaches are available to generate fused PET/MRI data. For some time the only possible solution was to use software to register and fuse separately acquired PET and MRI data. Although this approach functions relatively well for body areas with little deformability such as the head, imaging the heart poses problems with respect to coregistration due to patient breathing and the heart's own movement as well as patient positioning [1]. Sequential PET/MRI systems should provide improvement of coregistration if the patient undergoes both examinations in a row on a mobile table system without repositioning [2]. Compared with this, completely integrated PET/MRI systems can run both modalities simultaneously, thus minimizing the likelihood of movement-related misregistration, while reducing the examination time due to parallelization and additionally allowing chronologically coregistered in-vivo observation of physiological processes [3]. In addition, techniques have been developed which utilize temporal and spatial coregistration, in order to provide motion correction of PET data using temporally high-resolution MRI data recorded in parallel [4]. Recent advances in this area suggest a relevant utility of this technology for simultaneous PET/MR cardiac imaging [5]. By means of generally good coregistration, integrated acquisition of both modalities allows partial compensation of data from information obtained from higher-resolution MRI, compared to lower spatial resolution and resulting partial volume effects of PET [6].

Attenuation correction

Since neither a radioactive rod source nor a CT for creating an attenuation map (μ -map) of the patient is available during simultaneous PET/MR imaging, other technologies must be used. Two methods should be particularly mentioned in this regard. Existing CT data records can be registered to the acquired MRI data in an atlas which can then be used as a basis for determining the attenuation map.

However, due to variations in human anatomy, this requires a large database of CT data sets and considerable computational overhead. Further, deviations due to surgical intervention, implants or diseases such as osteoporosis can only be insufficiently accounted for. Another option for the creation of attenuation maps is software-based segmentation of MRI data into tissue classes with defined attenuation coefficients. The currently most common method is based on the use of a 2-point Dixon MRI sequence and segmentation in the background, lung, fat and soft tissue (Fig. 1) [7]. In addition to the imprecision arising from a limited number of tissue classes and attendant attenuation coefficients, bones (and calcifications) are being classified as soft tissue according to this method. In an MR image, air and bone are difficult to distinguish, but bone has a high attenuation coefficient, the result is a systematic underestimation of absorption when calculating attenuation maps [3, 7]. To counter this problem, newer techniques have been developed, based on so-called "ultrashort echo time" (UTE) sequences, which can visualize tissue with a very short $T2^*$ (including bone). Whereas there have been improvements in segmentation of the head, this technique has not yet been established in cardiac imaging due to the limited field of view (FOV). During cardiovascular imaging, due to breathing, cardiac movements, and blood vessel pulsation, physical shifts can occur between the MRI-generated acquisition map and PET acquisition volume, resulting in inaccurate correlation of attenuation coefficients. In this instance as well, MRI-based movement correction of PET data has shown itself to be a promising approach. MRI segmentation-based attenuation correction has been demonstrated to be a reliable procedure with regard to visual assessment of PET data; however, quantitative PET imaging based on this must be considered with caution [7, 8]. Although PET quantification within longitudinal studies such as therapy monitoring could be utilized, additional improvements in MRI-based attenuation correction used for quantitative PET imaging are needed for integrated PET/MRI procedures.

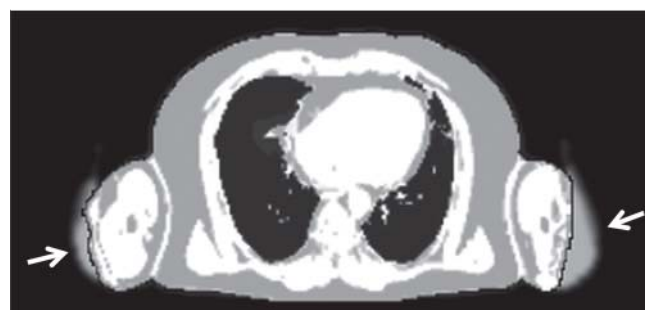

Fig. 1 An attenuation map based on segmentation of 2-point Dixon MR images in axial layer orientation through the thorax (Siemens Biograph mMR, syngo MR B20P). Due to the limited MRI field of view in the case of large patients, frequently appearing truncation artifacts in the region of the arms were partially corrected from PET emission data (arrows) using maximum likelihood reconstruction of attenuation and activity (MLAA). One should also note that the attenuation map does not differentiate between soft tissue (e. g. muscle) and bone which results in underestimation of PET signals during quantitative assessment.

Coils

While in sequential PET/MRI studies there are no restrictions regarding usable coils, in integrated PET/MRI, special systems with low attenuation for 511 keV photons must be employed, so that the coils can be disregarded during the creation of attenuation maps. Alternatively, other methods have been described which allow integration of attenuation coefficients of standard coil systems into the coefficient map after these have been previously measured in a CT scanner; however, the expansion of the attenuation map presumes knowledge of the exact coil length in the acquired image area [3].

ECG gating

Most MRI sequences as well as reconstruction of PET data recorded in list mode require a sufficiently good ECG signal in order to control or selectively use data from an acquired image of a specific cardiac phase. In contrast to PET examinations in PET/CT procedures, during integrated PET/MRI, it must be kept in mind that ECG signals can be significantly influenced by the magnetic field and radio frequency pulses, thus requiring special care when applying the electrodes and monitoring the signal. The relatively long duration of the simultaneous MRI examination can be used almost in its entirety for the parallel acquisition of PET data; this compensates for the loss of PET acquisition time caused by ECG gating, and results in high PET image quality [8].

Post-processing and evaluation

Whereas there is a variety of software applications permitting generic operations such as coregistration and fusion of PET and MRI data records, to-date there is no commercially available software package supporting dedicated processing and evaluation of PET/MRI-based cardiac studies. Therefore separate standard software has to be used for cardiac MRI and PET studies, and generic software used for fusion. However, applications have been developed for scientific use which can be adapted to specific requirements for evaluation and visualization of cardiac PET/MRI examinations [9, 10].

Patient preparation

Currently the most commonly used tracer for PET imaging is 2-Deoxy-2-[¹⁸F]fluoroglucose (FDG). It should be noted that a healthy heart muscle is a very insulin-sensitive tissue that can metabolize glucose as well as fatty acids, which must be kept in mind during interpretation of myocardial FDG enrichment. Therefore, depending on the purpose of the examination, the patient is prepared with one of two objectives: either to raise the insulin level to favor the uptake of glucose by cardiomyocytes (viability imaging), or by means of a low insulin level and alternatively provide fatty acids to keep the uptake of glucose into the cardiomyocytes as low as possible (inflammation, tumor) [11, 12]. The literature describes several methods in this regard. In the clinical routine at our institute, two procedures have been shown to be reliable and uncomplicated. For viability imaging, patients fast prior to the examination; the glucose level of diabetic patients should be below 150 mg/dl (8.3 mmol/l). Prior to FDG injection, the patient receives 75 g glucose orally (commercially available preparation for a glucose tolerance test). For a diagnosis of inflammation

and tumors, the patient receives a diet low in carbohydrates about 24 hours prior to the examination. On the morning of the examination, the patient consumes a particularly high-fat breakfast, and 15 minutes prior to the FDG injection, unfractionated Heparin is injected (50 IE/kg body weight), which has the additional effect of releasing free fatty acids into the blood.

Clinical application options

▼ Acute myocardial infarction

During initial studies of simultaneous cardiac imaging with PET/MRI, the feasibility of FDG PET/MRI was shown in patients with acute myocardial infarction, and possible imaging protocols for related examinations were presented (◉ Fig. 2) [8, 13, 14]. One study reported on a patient with early interventional reperfusion after coronary artery occlusion that showed reduced glucose utilization in the perfusion territory of the culprit artery but did not show myocardial necrosis in terms of late gadolinium-enhancement. [8]. Further studies likewise indicate that decreased glucose utilization of the myocardium after acute myocardial infarction comprises not only the necrotic myocardial scar, but still vital myocardium in the bordering regions of the scar affected by the ischemia [15]. If these observations can be confirmed in further studies, the area at risk would be measurable via PET/MRI, and the portion of salvaged myocardium could be quantified. Among other things, this could be utilized as a success parameter in studies regarding cardioprotection.

Other studies using PET/MRI have shown that after diet conversion of myocardial metabolism to fatty acid metabolism, the inflammatory reaction in the myocardial scar after myocardial infarction can be observed due to increased glucose utilization [14, 16]; this could be used to guide new therapies to modulate infarct healing. Likewise, imaging of angiogenesis in the course of infarct healing uses special PET tracers such as $\alpha\beta 3$ Integrin; in the future this may result in additional applications of cardiac PET/MRI [17].

Chronic myocardial infarction

Patients with chronic myocardial infarction have also been examined using simultaneous FDG PET/MRI. It has been reported that there is basically good correlation between segments with reduced glucose utilization, late gadolinium enhancement (LGE) and regional wall motion abnormalities (◉ Fig. 3) [8]. However, older comparative studies suggest that LGE could be superior to FDG PET in the detection of narrow subendocardial infarcts and quantification of the transmural infarct scar [18]. Therefore it remains to be seen, whether areas of application of simultaneous PET/MRI in the case of chronic myocardial infarction can be established beyond basic research. A very promising application in the area of ischemic cardiomyopathy could be the preoperative identification of patients who could benefit from coronary revascularization. Although quantification of myocardial blood flow (MBF) with PET perfusion tracers in integrated PET/MRI appears to be possible [14], it is not yet certain whether this offers significant advantages over perfusion measurement using MRI contrast media. Com-

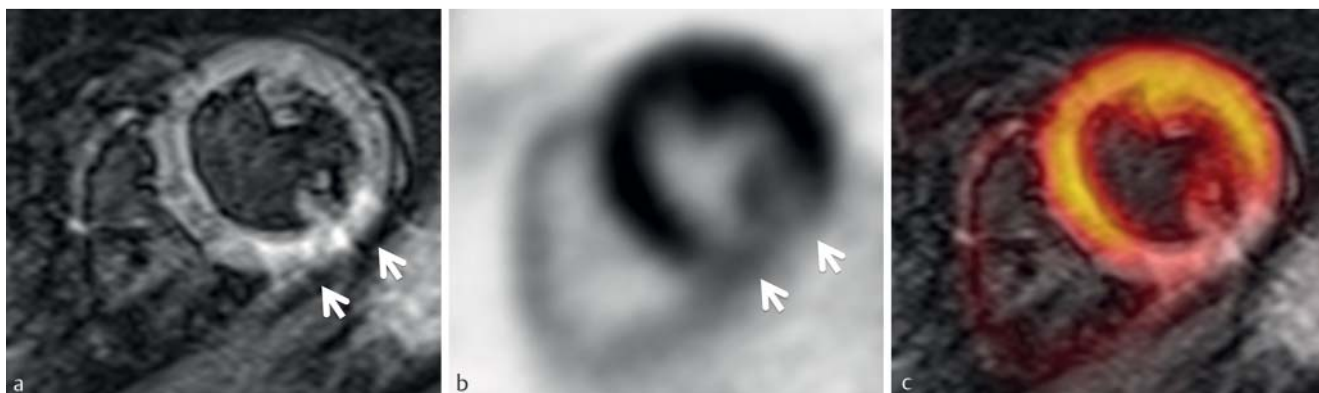


Fig. 2 Simultaneous FDG PET/MRI examination in a 59-year-old patient with a 7-day-old myocardial infarction after an interventional reperfusion of the right coronary artery. The T2-weighted short axis image shows edema in the inferior and inferoseptal myocardium (a, arrows), which visually cor-

relates well with the significantly reduced glucose utilization of the affected myocardial section in the PET (b, arrows). The good correlation is illustrated by the fusion c.

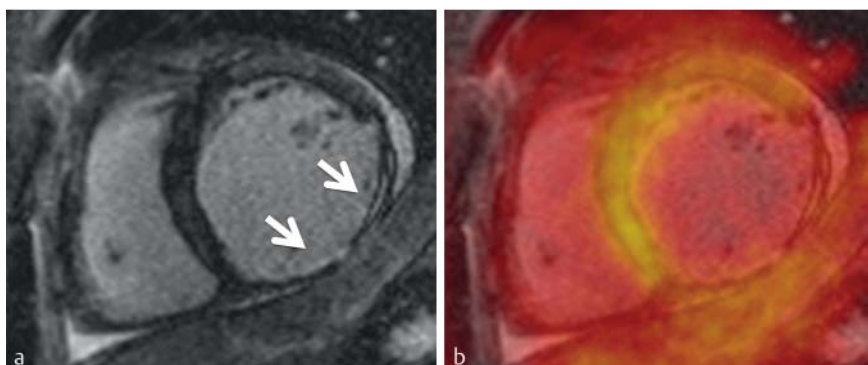


Fig. 3 Simultaneous FDG PET/MRI examination in a 55-year-old patient with coronary heart disease and older myocardial scar in the right perfusion region of the right coronary artery. The left short axis image using late gadolinium enhancement shows the extended scar in the posterior wall (a, arrows). Fusion with the PET examination performed in parallel b shows significantly reduced glucose utilization in the region of the myocardial scar.

pared to the usual MRI contrast agents, some PET tracers (e. g. $^{15}\text{O}\text{-H}_2\text{O}$ or $^{18}\text{F}\text{-Flurpiridaz}$) demonstrate an almost linear relationship between MBF and myocardial extraction. In addition, PET enables the acquisition of the entire myocardium during perfusion measurement. On the other hand, MRI contrast media are more economical, readily available (especially short-lived positron emitters such as ^{15}O , ^{11}C or ^{13}N require a cyclotron in the direct vicinity of the PET/MRI scanner) and do not expose patients to additional radiation.

Myocarditis and sarcoidosis

Since the imaging of inflammation using FDG PET has attracted more scientific and clinical interest in recent years [19], possible applications in the area of cardiovascular PET/MRI have also been evaluated. Consequently several cases of cardiac sarcoidosis have been investigated using FDG PET/MRI and published [14, 20–22]. Since cardiac involvement is a strong predictor of a fatal outcome in sarcoidosis, early detection of this complication is of great importance. For both MRI and FDG PET sufficient sensitivities and specificities have been reported for the diagnosis of cardiac sarcoidosis [23], while so far no prospective studies regarding additional utility of PET/MRI have been published. On the other hand, it is known that MRI using LGE can reveal myocardial scarring with great sensitivity, where glucose uptake can be used as a surrogate parameter of the activity of inflammation. Thus, in theory, it is conceivable that PET/MRI could be used to differentiate between residual scar-

ring and active infiltrates, as well as provide monitoring in the course of therapy [24, 25].

Imaging of infectious myocarditis continues to represent a diagnostic challenge [26]; thus an evaluation of integrated PET/MRI holds promise here as well. The inflammatory changes of the myo- and pericardium in viral myocarditis have been recently demonstrated using FDG PET/MRI in a short case report [27]. Future studies will have to show whether the use of PET/MRI provides greater accuracy in the detection of myocarditis or possible use in therapeutic follow-up. In the long term, new PET tracers directed specifically toward the structures affected by the inflammation response could support additional advances in the imaging of inflammatory myocardial changes [28]. Since younger patients are frequently affected by inflammatory diseases of the heart, and in comparison to oncological diseases, are subject to a lower mortality rate, an argument could be made for the use of PET/MRI with respect to regular therapeutic monitoring due to lower radiation exposure compared to PET/CT.

Cardiac tumors

Despite the outstanding role of MR imaging in cardiac tumors and widespread use of PET/CT imaging in oncology, to-date no related studies or case histories have been published regarding the employment of PET/MRI for displaying cardiac tumors. A single older case history of cardiac metastasis in a patient with squamous epithelial cancer of the

lung demonstrates the use of post-hoc fused PET-MRI [29]. A study of the differentiation of benign and malignant cardiac tumors using FDG PET/CT showed high diagnostic accuracy (sensitivity 100%, specificity 86%) compared to the histopathological reference standard [30]. Due to the excellent morphological resolution of soft tissue processes of the heart in MRI and additional anatomical and functional tissue contrast through the use of special sequences, PET/MRI could yield additional improvement in the assessment of malignancy and local staging of local propagation of cardiac tumors. Future studies will evaluate the value of PET/MRI with regard to these indications.

Congestive heart failure

In Germany, congestive heart failure is the most common reason for hospitalization as well as one of the most frequent causes of death [31]. With MRI, cardiac function as well as possible causes of heart failure can be assessed, including different forms of cardiomyopathy, heart valve malfunction or congenital heart defects. Sympathetic innervation of the heart can be demonstrated using special PET tracers, such as ^{11}C -hydroxyephedrine (HED) or ^{124}I -metaiodobenzylguanidine (MIBG) (• Fig. 4) [32]. So far no studies have been published regarding the sympathetic innervation of the heart by means of PET/MRI; however, possible concerns such as risk stratification with respect to sudden cardiac death or therapy monitoring could be possible applications for PET/MRI in the case of congestive heart failure [33]. Yet it should be kept in mind that PET/MRI examinations of patients with pacemakers or implanted cardioverter-defibrillators (ICD) are inappropriate due to MRI contradictions.

Rare cardiomyopathies

Cardiomyopathies are a heterogeneous group of diseases with various causes, frequently genetic in nature and can be part of a general systemic disease [34]. Although frequent common characteristics of cardiomyopathies such as myocardial hypertrophy or dilation are readily observable with imaging procedures, the underlying pathomechanisms frequently cannot be visualized. PET/MRI applications to display rare cardiomyopathies might be developed in research, since a combination of high anatomical resolution, functional MRI sequences and PET tracers designed for specific target structures could be useful in the elucidation of pathophysiological relationships. There has been a report of tako-tsubo cardiomyopathy in which FDG PET/MRI was used to demonstrate increased glucose uptake in myocardial sections affected by neurogenic movement disorder [35]. In another case, FDG PET/MRI was used to disclose reduced glucose utilization in fibrotic myocardial segments in hypertrophic cardiomyopathy [36]. The increasing availability of PET tracers used to disclose beta amyloid, originally developed for imaging plaques in dementia patients, holds the promise of promoting in PET/MRI imaging of cardiac amyloidosis [37]. Using tracers such as HED, MIBG or ^{11}C -CGP-12 177 (CGP), PET/MRI could expand the diagnostic spectrum with respect to ventricular tachycardia and ventricular fibrillation related to cardiomyopathy such as right ventricular outflow tract tachycardia (RVO-VT) or idiopathic ventricular fibrillation (IVF) marked by pre- and post-synaptic impairments of the sympathetic innervation of the myocardium [38]. Whether clinical applications of

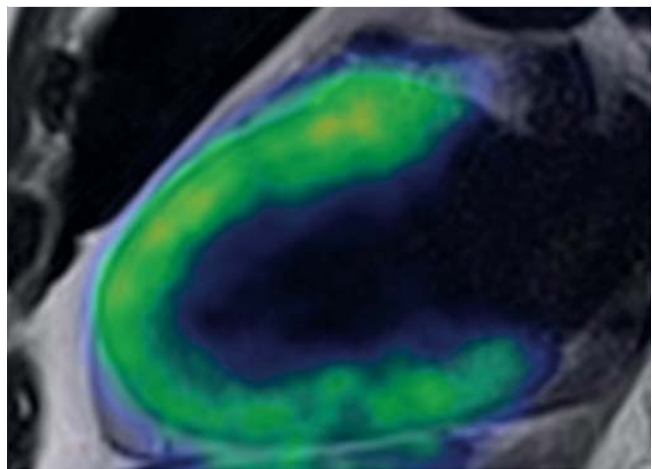


Fig. 4 Fused 2-chamber view from a T2-weighted MR image and a simultaneous PET examination with ^{124}I -metaiodobenzylguanidine (MIBG). MIBG is a norepinephrine analogue that accumulates via a pre-synaptic re-uptake mechanism in the adrenergic nervous system. This enables a quantitative and morphologically detailed evaluation of the integrity and function of the adrenergic nervous system in diseases such as cardiac failure or diabetic cardiovascular autonomic neuropathy.

PET/MRI for the imaging of rare cardiomyopathies can progress beyond research should be clarified in coming years, and is likely to depend largely on the establishment and approval of new PET tracers.

Arteriosclerosis (plaques)

While the establishment of clinical procedures based on the determination of macroscopic calcification of coronary arteries in the assessment of the risk of cardiovascular events is increasing, recently scientific interest has focused on the detection of those plaques particularly vulnerable to rupture. Due to the high sensitivity of nuclear medical methods for the demonstration of metabolic processes, PET/CT procedures offer considerable promise in this regard (• Fig. 5). Various studies have investigated FDG accumulation as a correlate of metabolic activity in arteriosclerotic plaques as well as the response of inflammation to drug therapy has been demonstrated using PET/CT [39]. Only recently Joshi et al. showed that ruptured plaques in coronary arteries could be detected after myocardial infarction by using the PET tracer ^{18}F -sodium fluoride, long-used in skeletal imaging, in coronary arteries [40]. It remains to be seen, however, whether this technology can be used to detect plaques prior to rupturing, at a juncture where intervention might be possible. On the other hand, preclinical studies have already demonstrated new PET tracers like matrix metalloproteinase inhibitors to show plaque vulnerability [41]. While in these studies PET/CT was used, the application of PET/MRI could provide advantages, despite lower temporal and spatial resolution. Thus certain plaque elements could be better differentiated from one another using MRI, as shown in a preclinical study using contrast agents containing iron oxide [42]. Moreover, in the future, new techniques based on parallel MRI acquisition for movement and partial volume effect correction of the PET signal could particularly improve PET imaging of coronary arteries, since this is especially affected by motion artifacts [6, 43].

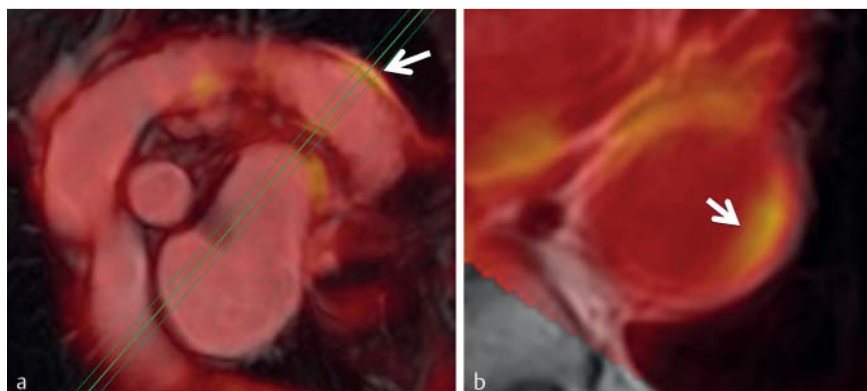


Fig. 5 Simultaneous FDG PET/MRI examination in a 78-year-old patient with coronary heart disease and aortic sclerosis. The fusion of a 3DFLASH MR image and PET in parasagittal **a** and axial **b** layer orientation indicate arteriosclerotic plaques in the aortic wall with increased glucose utilization.

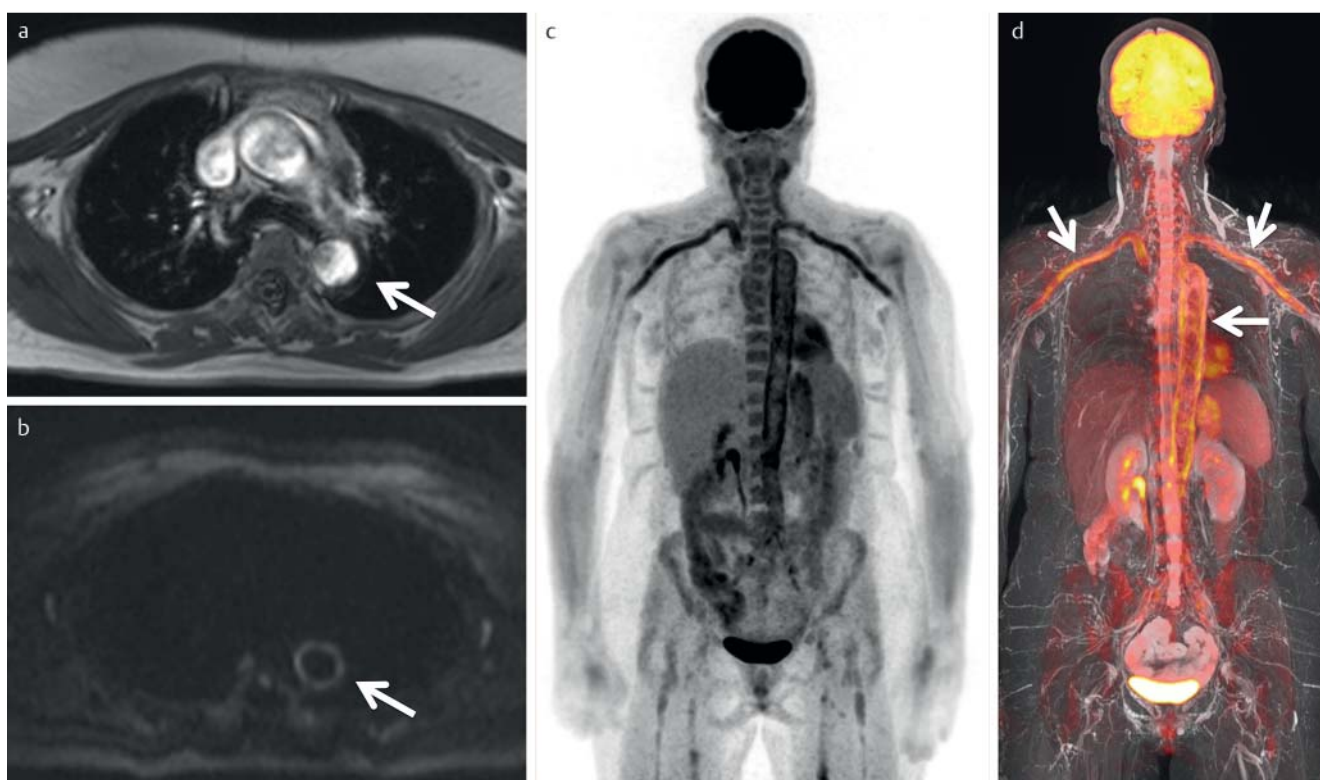


Fig. 6 FDG PET/MRI examination of a patient with a form of giant cell arteritis in which only the aorta and large arteries were affected. The axial T1-weighted MR image after contrast medium injection shows a hypointense thickening (max. 8 mm) in the aortic wall (**a**, arrow). The axial diffusion weighted image (b value 500 s/mm²) shows a hyperintense T2 shine-

through signal in the aortic wall (**b**, arrow). The coronary maximum intensity projection (MIP, slab: 150 mm) of PET data **c** and fusion with a T2-weighted MR image (**d**, arrow) show increased glucose utilization in the inflamed blood vessel walls.

The feasibility of PET/MRI imaging has already been demonstrated in a small group of 6 male patients with increased risk of arteriosclerosis. Ripa et al. were able to show that a PET/MRI of the carotid arteries is possible and that the measured SUVs correlated well with those values subsequently obtained using PET/CT [44]. Whether PET/MRI imaging of arteriosclerotic lesions will take hold remains to be seen, however.

Vasculitis

In addition to inflammatory changes of the myocardium, PET can demonstrate and quantify similar changes to the vascular wall. Although the use of FDG PET/CT has been increasingly es-

tablished clinically regarding such indications [45], PET/MRI can likewise be employed here (► **Fig. 6**). In the case of such indications which primarily affect young patients (e.g. Takayasu's arteritis or Kawasaki syndrome), PET/MRI offers an obvious advantage due to the possible reduction of radiation exposure. At present it cannot be foreseen whether additional benefits might follow from the multi-parametric imaging, multiple tissue contrasts or simultaneous MR angiography.

Outlook

Although cardiovascular imaging using hybrid PET/MRI is still under initial evaluation, some applications with potential utilization in the clinical routine or within studies have already been identified further studies need to prove a diagnostic advantage, not the least of which is an acceptable cost-benefit of this new imaging modality. Only time will tell whether in coming years cardiovascular PET/MR imaging will widely establish itself clinically, will be employed in a few specialized centers, or remain purely as a research platform.

References

- Nekolla SG, Martinez-Moeller A, Saraste A. PET and MRI in cardiac imaging: from validation studies to integrated applications. *Eur J Nucl Med Mol Imaging* 2009; S121–S130
- Torigian DA, Zaidi H et al. PET/MR Imaging: Technical Aspects and Potential Clinical Applications. *Radiology* 2013; 1: 26–44
- Quick HH. Integrated PET/MR. *J Magn Reson Imaging* 2013; 2: 243–258
- Ouyang J, Li Q, El Fakhri G. Magnetic resonance-based motion correction for positron emission tomography imaging. *Semin Nucl Med* 2013; 1: 60–67
- Petibon Y, Ouyang J et al. Cardiac motion compensation and resolution modeling in simultaneous PET-MR: a cardiac lesion detection study. *Phys Med Biol* 2013; 7: 2085–2102
- Wang H, Fei B. An MR image-guided, voxel-based partial volume correction method for PET images. *Med Phys* 2012; 1: 179–195
- Martinez-Möller A, Souvatzoglou M et al. Tissue classification as a potential approach for attenuation correction in whole-body PET/MRI: evaluation with PET/CT data. *J Nucl Med* 2009; 4: 520–526
- Nensa F, Poeppel TD et al. Hybrid PET/MR Imaging of the Heart: Feasibility and Initial Results. *Radiology* 2013; 2: 366–373
- Nekolla SG, Miethaner C et al. Reproducibility of polar map generation and assessment of defect severity and extent assessment in myocardial perfusion imaging using positron emission tomography. *Eur J Nucl Med* 1998; 9: 1313–1321
- Nensa F, Poeppel TD, Beiderwellen KJ et al. Standardized Comparison of Glucose Metabolism and Late Gadolinium-enhancement in Patients with Acute Myocardial Infarction Using Parametric Polar Maps in Cardiac PET/MRI. Paper presented at: 2013 Annual Meeting of the Radiological Society of North America; December 3, 2013. Chicago, USA:
- Dilsizian V, Bacharach SL et al. PET myocardial perfusion and metabolism clinical imaging. *J Nucl Cardiol* 2009; 4: 651
- Harisankar CN, Mittal BR et al. Utility of high fat and low carbohydrate diet in suppressing myocardial FDG uptake. *J Nucl Cardiol* 2011; 5: 926–936
- Schlosser T, Nensa F et al. Hybrid MRI/PET of the heart: a new complementary imaging technique for simultaneous acquisition of MRI and PET data. *Heart* 2012; 99 (5): 351–352
- Rischpler C, Nekolla SG et al. Hybrid PET/MR Imaging of the Heart: Potential, Initial Experiences, and Future Prospects. *J Nucl Med* 2013; 54 (3): 402–415
- Nensa F, Poeppel TD, Beiderwellen KJ et al. Cardiac PET/MRI with 18F-FDG: Feasibility and Initial Results in Patients with Acute Myocardial Infarction. Paper presented at: 2013 Annual Meeting of the Radiological Society of North America; December 3, 2013. Chicago, USA
- Lee WW, Marinelli B et al. PET/MRI of Inflammation in Myocardial Infarction. *J Am Coll Cardiol* 2012; 2: 153–163
- Kramer CM, Sinusas AJ et al. Multimodality imaging of myocardial injury and remodeling. *J Nucl Med* 2010; 107S–121S
- Hunold P, Brandt-Mainz K et al. Evaluation of myocardial viability with contrast-enhanced magnetic resonance imaging—comparison of the late enhancement technique with positron emission tomography. *Fortschr Röntgenstr* 2002; 7: 867–873
- Haroon A, Zumla A, Bomanji J. Role of fluorine 18 fluorodeoxyglucose positron emission tomography-computed tomography in focal and generalized infectious and inflammatory disorders. *Clin Infect Dis* 2012; 9: 1333–1341
- O'Meara C, Menezes LJ et al. Initial experience of imaging cardiac sarcoidosis using hybrid PET-MR – a technologist's case study. *J Cardiovasc Magn Reson* 2013; 15 (1): T1, DOI: 10.1186/1532-429X-15-S1-T1
- White JA, Rajchl M et al. Active cardiac sarcoidosis: first clinical experience of simultaneous positron emission tomography-magnetic resonance imaging for the diagnosis of cardiac disease. *Circulation* 2013; 22: e639–e641
- Schneider S, Batrice A et al. Utility of multimodal cardiac imaging with PET/MRI in cardiac sarcoidosis: implications for diagnosis, monitoring and treatment. *Eur Heart J* 2013; 35 (5): 312
- Schatka I, Bengel FM. Advanced imaging of cardiac sarcoidosis. *J Nucl Med* 2014; 55 (1): 99–106
- Soussan M, Augier A et al. Functional Imaging in Extrapulmonary Sarcoidosis: FDG-PET/CT and MR Features. *Clin Nucl Med* 2013; 39 (2): e146–e159
- Sobic-Saranovic DP, Grozdic IT et al. Responsiveness of FDG PET/CT to Treatment of Patients With Active Chronic Sarcoidosis. *Clin Nucl Med* 2013; 7: 516–521
- Friedrich MG, Sechtem U et al. Cardiovascular magnetic resonance in myocarditis: A JACC White Paper. *J Am Coll Cardiol* 2009; 17: 1475–1487
- Nensa F, Poeppel TD et al. Multiparametric assessment of myocarditis using simultaneous positron emission tomography/magnetic resonance imaging. *Eur Heart J* 2014; DOI: 10.1093/eurheartj/ehu086 Epub 2014 Feb 26
- Wu C, Li F et al. PET imaging of inflammation biomarkers. *Theranostics* 2013; 7: 448–466
- Probst S, Seltzer A et al. The appearance of cardiac metastasis from squamous cell carcinoma of the lung on F-18 FDG PET/CT and post hoc PET/MRI. *Clin Nucl Med* 2011; 4: 311–312
- Rahbar K, Seifarth H et al. Differentiation of malignant and benign cardiac tumors using 18F-FDG PET/CT. *J Nucl Med* 2012; 6: 856–863
- Neumann T, Biermann J et al. Heart failure: the commonest reason for hospital admission in Germany: medical and economic perspectives. *Dtsch Arztebl Int* 2009; 16: 269–275
- Lautamäki R, Tipre D, Bengel FM. Cardiac sympathetic neuronal imaging using PET. *Eur J Nucl Med Mol Imaging* 2007: S74–S85
- Hacker M, Weiss M. MIBG-Szintigrafie des Herzens MIBG Scintigraphy of the Heart. *Nuklearmedizin* 2009; 1: 23–27
- Maron BJ, Towbin JA et al. Contemporary definitions and classification of the cardiomyopathies: an American Heart Association Scientific Statement from the Council on Clinical Cardiology, Heart Failure and Transplantation Committee; Quality of Care and Outcomes Research and Functional Genomics and Translational Biology Interdisciplinary Working Groups; and Council on Epidemiology and Prevention. *Circulation* 2006; 14: 1807–1816
- Ibrahim T, Nekolla SG et al. Simultaneous Positron Emission Tomography/Magnetic Resonance Imaging Identifies Sustained Regional Abnormalities in Cardiac Metabolism and Function in Stress-Induced Transient Midventricular Ballooning Syndrome. *Circulation* 2012; 21: e324–e326
- Kong E-J, Lee S-H, Cho I-H. Myocardial Fibrosis in Hypertrophic Cardiomyopathy Demonstrated by Integrated Cardiac F-18 FDG PET/MR. *Nuclear Medicine and Molecular Imaging* 2013; 3: 196–200
- Sachchithanatham S, Wechalekar AD. Imaging in systemic amyloidosis. *Br Med Bull* 2013: 41–56
- Schäfers M, Wichter T et al. Cardiac 123I-MIBG uptake in idiopathic ventricular tachycardia and fibrillation. *J Nucl Med* 1999; 40: 1–5
- Tahara N, Kai H et al. Simvastatin attenuates plaque inflammation: evaluation by fluorodeoxyglucose positron emission tomography. *J Am Coll Cardiol* 2006; 9: 1825–1831
- Joshi NV, Vesey AT et al. 18F-fluoride positron emission tomography for identification of ruptured and high-risk coronary atherosclerotic plaques: a prospective clinical trial. *Lancet* 2013; 383 (9918): 705–713
- Hermann S, Starsichova A et al. Non-FDG imaging of atherosclerosis: will imaging of MMPs assess plaque vulnerability? *J Nucl Cardiol* 2012; 3: 609–617
- Metz S, Beer AJ et al. Characterization of carotid artery plaques with USPIO-enhanced MRI: assessment of inflammation and vascularity as in vivo imaging biomarkers for plaque vulnerability. *Int J Cardiovasc Imaging* 2011; 6: 901–912
- Chun SY, Reese TG et al. MRI-based nonrigid motion correction in simultaneous PET/MRI. *J Nucl Med* 2012; 8: 1284–1291

- 44 Ripa RS, Knudsen A *et al.* Feasibility of simultaneous PET/MR of the carotid artery: first clinical experience and comparison to PET/CT. *Am J Nucl Med Mol Imaging* 2013; 4: 361 – 371
- 45 Glaudemans AW, de Vries EF *et al.* The use of (18)F-FDG-PET/CT for diagnosis and treatment monitoring of inflammatory and infectious diseases. *Clin Dev Immunol* 2013; DOI: 10.1155/2013/623036 Epub 2013 Aug 21