Successful Retrieval of the Detached Porous Metallic Tip of a Mechanical Aspiration Catheter during Thrombectomy in a Case with May–Thurner Syndrome: A Case Report

Alpaslan Yavuz, MD[1] Çagatay Andiç, MD[2] Ali Kemal Gür, MD[1] Cemil Göya, MD[3] Aydın Bora, MD[1] Mehmet Beyazal, MD[1]

[1] Department of Interventional Radiology, Yüzüncü Yıl University Hospital, Van, Turkey
[2] Department of Interventional Radiology, Baskent University Hospital, Adana, Turkey
[3] Department of Radiology, Dicle University Hospital, Diyarbakir, Turkey

Address for correspondence Alpaslan Yavuz, MD, Yüzüncü Yıl University Hastanesi, Kampüs, 65100, Van, Turkey (e-mail: dralpyavuz@hotmail.com).

Int J Angiol 2016;25:e32–e36.

Abstract

Modern, minimally invasive techniques used to treat deep venous thrombosis, such as percutaneous mechanical thrombectomy (PMT) and catheter-directed thrombolysis, have gained worldwide acceptance. PMT has the advantage of speed and is also associated with improved outcomes, shortened hospital stays, and low complication rates. The main complications associated with PMT have been primarily due to iatrogenic vascular damage resulting in perforation, embolic occlusion, and arteriovenous fistula formation; to date, there has been no publication in the literature describing complications resulting from device failure. We present an unusual complication of PMT resulting from detachment of the catheter tip during thrombectomy and bailout technique employed.

Keywords
- deep venous thrombosis
- percutaneous mechanical thrombectomy
- May-Thurner syndrome

Early detection and treatment of deep venous thrombosis (DVT) are of vital importance for the treatment procedure to meet with success and avoid possible long-term complications. In particular, patients with iliofemoral DVT have the highest risk of developing postthrombotic syndrome and postphlebitic syndrome, which can lead to lifelong complications.[1] May–Thurner syndrome (MTS) has been recognized as a frequent cause of DVT since it was first described by May and Thurner in 1957. Surgical repair has been the traditional treatment for DVT, but as treatment options were developed for acute–subacute DVT resulting from MTS, endovascular intervention became an alternative to surgery.[2–4] Thrombectomy with manual catheter-directed aspiration, thrombectomy by mechanical devices, and thrombolytic drug-based techniques are all in use for declotting. Vascular rupture, distal embolization, and arteriovenous fistula have been reported as complications of percutaneous mechanical thrombectomy (PMT); however, no cases have been reported to date describing complications due to device failure during mechanical thrombectomy. This presentation describes the detachment of the distal metallic tip of the mechanical aspiration catheter (Aspirex S, Straub Medical AG, Wangs, Switzerland) while performing thrombectomy in a case of MTS and the bailout technique required to overcome this complication. To our knowledge, this is the first case of its type that has been reported in the literature.

Case Report

A 72-year-old male patient referred with diffuse swelling of the left leg of approximately 2-months' duration was brought to our emergency department. The swelling had gradually

published online
September 29, 2014

Copyright © 2016 by Thieme Medical Publishers, Inc., 333 Seventh Avenue, New York, NY 10001, USA. Tel: +1(212) 584-4662.

DOI http://dx.doi.org/10.1055/s-0034-1389260.
ISSN 1061-1711.

This document was downloaded for personal use only. Unauthorized distribution is strictly prohibited.

become more severe, especially over the last 2 weeks. Physical examination revealed a tender erythematous swelling of the left leg extending from the ankle to the thigh with a noticeable increase in diameter compared with the right leg; arterial pulses were palpable in bilateral lower extremities. Lower extremity Doppler ultrasound (US) examination revealed an extensive iliofemoral DVT. Thoracic and abdominal computed tomographic (CT) scan with intravenous contrast was obtained to rule out an occult pulmonary embolism and evaluate for the presence of thrombus extension. The pulmonary arteries were free of thrombi. CT images and maximum intensity projection reconstruction images revealed normal arterial anatomy and left iliac vein compression by the left common iliac artery, suggesting a diagnosis of MTS. Left thigh edema and evident thrombosis of the common femoral vein that extended down to involve the superficial femoral vein were also detected by CT (►**Fig. 1**). The decision was made to perform percutaneous endovascular therapy.

The patient was initially administered by bolus intravenous (i.v.) injection of 5,000 IU heparin and started on i.v. heparin infusion of 15 IU/kg/h (initial maximum rates of 1,200 IU/h). The procedure was performed under local anesthesia. Initially, a retrievable inferior vena cava (IVC) filter (Option, Angiotech Pharmaceuticals, Vancouver, British Columbia, Canada) was placed just below the levels of renal veins via right jugular vein approach (►**Fig. 2**). Endovascular access for thrombectomy was established by US-guided puncture of the ipsilateral popliteal vein using a 21-G chiba needle with the patient in the prone position. A 6F vascular sheath was placed (Avanti, Cordis Europa NV, Roden, The Netherlands) into the popliteal vein. A 0.018-inch guidewire with a hydrophilic-coated distal tip was advanced through the stenotic segment of the common iliac vein into the IVC using a 5F vertebral catheter for support. PMT was performed using a 6F Aspirex S mechanical thrombectomy catheter. Thrombectomy device was initially checked whether any technical or physical failures exist, and no defect was determined. The system was advanced into the IVC to clear the thrombotic remnants. Catheter was advanced through the compressed-stenotic common iliac vein segment by minimal quadrant rotational maneuver. However, the distal tip of the thrombectomy device became detached while the shaft of the device was being pulled back through the stenotic segment of the common iliac vein (►**Fig. 3**). The shaft was removed,

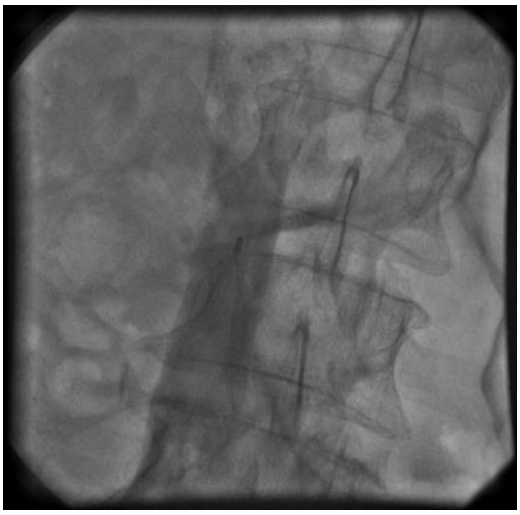

Fig. 2 A retrievable inferior vena cava filter was placed via right jugular vein approach before performing mechanical thrombectomy to prevent potential embolic complications.

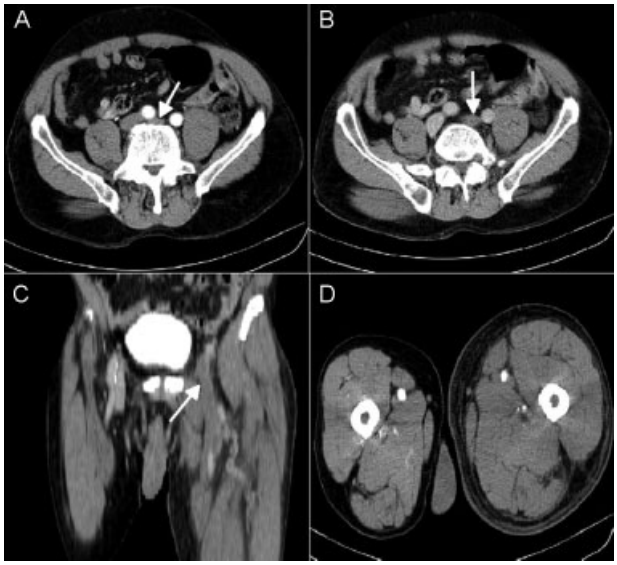

Fig. 1 Computed tomography (CT) with biphasic administration of intravenous (i.v.) contrast agent: (A) The left common iliac vein was compressed against the fifth lumbar vertebrae by the overlying right common iliac artery at arterial phase (white arrow). (B) Reduced density of the left common iliac vein due to thrombosis at venous phase (white arrow). (C) Coronal reformat CT image revealing hypodense, thrombotic common, and superficial femoral vein with extended diameter (white arrow). (D) Evident swelling of left thigh.

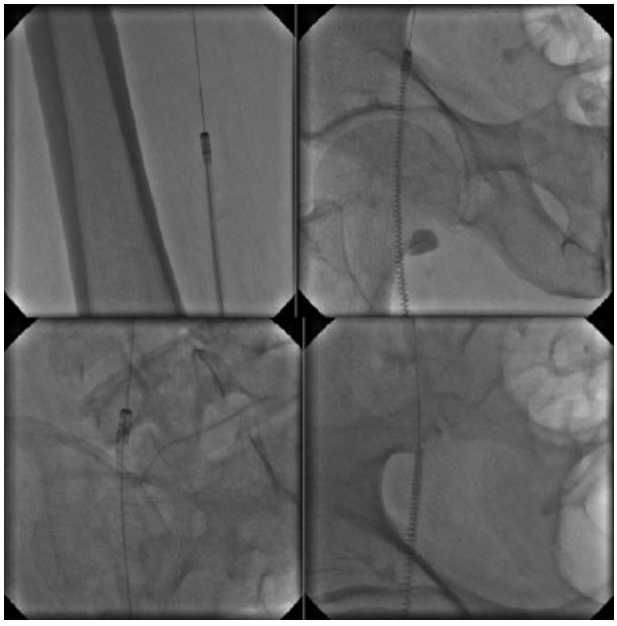

Fig. 3 Angiographic images of mechanical thrombectomy catheter before and after detachment: undamaged catheter at the level of the (A) superficial vein and (B) common iliac vein. (C) Detached catheter tip. (D) Catheter shaft without distal part.

This document was downloaded for personal use only. Unauthorized distribution is strictly prohibited.

Fig. 4 Shaft of the thrombectomy catheter without distal part was led out from the vascular sheath.

while the guidewire was left in place with the detached metallic part remaining within the proximal region of the stenotic iliac segment (►**Fig. 4**). We did not remove the guidewire to avoid releasing the foreign body into the venous system. A 12 mm self-expandable Wallstent (Boston Scientific Inc., Natick, MA) was placed to widen the stenotic segment of the common iliac vein. A snare catheter was introduced into the IVC through the guidewire; the detached tip was then caught and pulled through the guidewire to the level of the popliteal vein (►**Fig. 5**). After removing the vascular sheath, the detached tip was withdrawn from the popliteal vein through a 2 cm percutaneous incision (►**Fig. 6**). The procedure was terminated to avoid additional complications that might have resulted from either the incision or anticoagulation. Patient was administered with low-molecular-weighted heparin—enoxaparin (Clexane, Sanofi, Paris, France) for a period of 6 days (subcutaneous administration of Clexane 6,000 anti-Xa/0.6 mL, twice per day with a 12-hour interval) till the following treatment session.

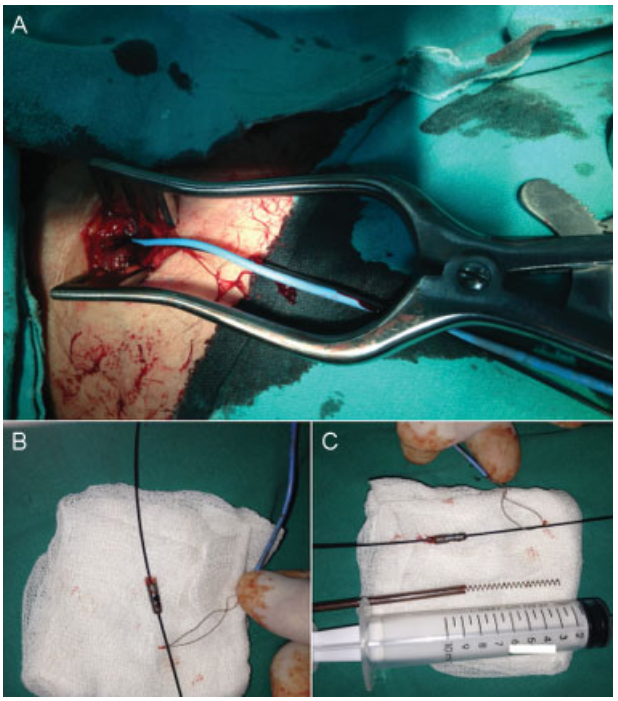

Fig. 6 (A) Popliteal incision performed to remove the metallic tip from the popliteal vein. (B) Detached catheter tip which was caught by the snare catheter. (C) Detached catheter tip and distal shaft of the thrombectomy catheter without cap.

One week later, the remaining thrombus was treated with manual aspiration thrombectomy using a 9F guiding catheter via the ipsilateral popliteal vein. An additional 12 mm self-expandable metallic stent (Protégé, eV3 medical,

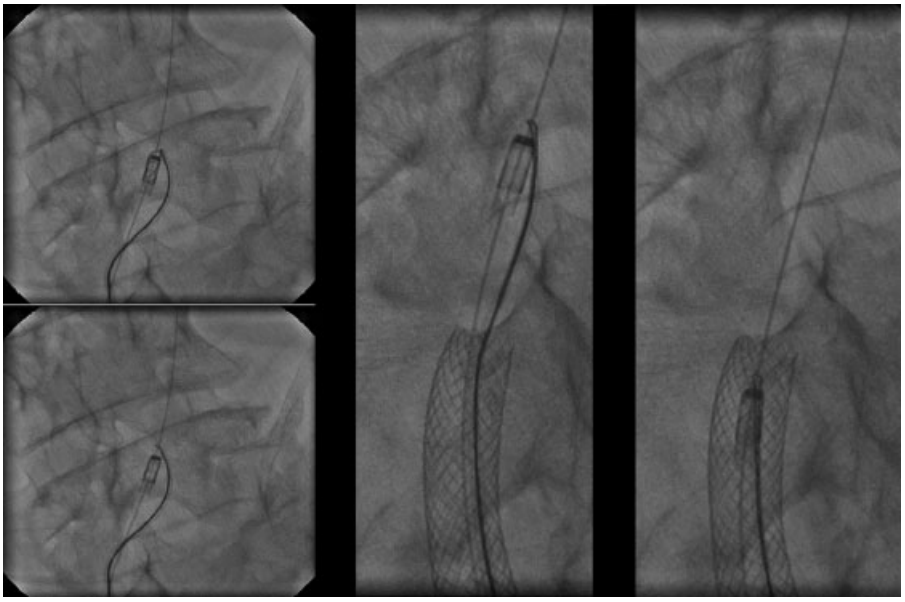

Fig. 5 Bailout technique of the detached metallic tip; caught and pulled back with a snare catheter.

This document was downloaded for personal use only. Unauthorized distribution is strictly prohibited.

Fig. 7 Control venography revealed the restoration of uninterrupted blood flow through the vein (patients were placed in the prone position).

Plymouth, MN) was placed to achieve patency of the common iliac and the external iliac veins. A check venography demonstrated uninterrupted blood flow through the vein (►**Fig. 7**).

Discussion

MTS is a frequent but rarely diagnosed condition in which patients develop iliofemoral DVT due to an anatomical variation of the left iliac vein. In 1957, May and Thurner explained this phenomenon by revealing the presence of abnormal vascular thickening of the left common iliac vein at the point where it was crossed by the overlying right common iliac artery and compressed against the fifth lumbar vertebra.[5] Despite the relatively high incidence of this anatomical variation, the clinical prevalence of MTS-related DVT is surprisingly low, reportedly occurring in only 2 to 3% of all lower extremity DVTs.[6] However, the well-known predominance of left-sided DVT suggests that diagnoses of MTS may be missed, leading to a decrease in prevalence and an apparent low rate of occurrence.[7] The traditional therapeutic modality for the treatment of MTS is an open surgical repair of the affected vein; however, the standard of care has since evolved into using thrombolytics combined with endovascular interventions. Catheter-directed thrombolysis combined with PMT has been recommended primarily as a less invasive treatment option for the management of DVT in patients with MTS.[2,3] The use of self-expanding stents with 12 to 14 mm diameters has been suggested.[3] Hölper et al reported the 2-year iliac vein patency rates of iliac stents to be between 95 and 100% in MTS patients.[4] PMT devices allow for rapid clot removal as well as decreased frequency, dose, and duration of fibrinolytic therapy. The advantages of these devices over local thrombolysis include rapid establishment of luminal patency, increased efficiency by requiring only a single catheterization session, fewer laboratory tests for monitoring coagulation parameters, and a decreased risk of remote bleeding.[8] Kasirajan et al highlighted the occurrence of pulmonary embolism and venous valve damage as potential complications of PMT.[9] Moreover, vascular perforation, iatrogenic arteriovenous fistula formation, and distal embolization have also been reported with PMT.[10] Thus far, there have been no reports of complications resulting from the detachment of the tip of a mechanical thrombectomy catheter. In our case, we preferred to use the mechanical aspiration catheter Aspirex S to clear the thrombus from the left lower extremity. Thrombus aspiration was then aggressively performed in the external iliac, common, and superficial veins. However, the porous-metallic tip of the catheter detached from the shaft while retracting the system caudally through the stenotic-compressed segment of the iliac vein. Bailout of the detached part was successfully achieved by the use of a snare catheter. Thrombus clearance of the Aspirex S catheter was satisfactory, but in our opinion, the neck of the catheter which connects the tip with the shaft was simply wrenched even by our limited rotational maneuver (less than semicircle). We considered the cause of the metallic tip's disconnection as: the outer coat of the system has a relatively stiff structure; thus, if any discordant spins occur between the catheter shaft and metallic tip (may due to the embedding of the tip in vascular stenosis or wall) can induce significant swirl damages at catheter "neck" even when the maneuver was performed within quadrant–semicircle limits. Thereby, particular attention is necessary while passing the system through the stenotic vascular segments.

In conclusion, PMT is widely used in the treatment of patients with acute and subacute DVT, including patients who have underlying iliac vein compression syndrome. PMT devices, Aspirex in this particular case, should be used carefully when there is iliac vein stenosis due to MTS.

Funding
No technical, secretarial, or financial contribution was used for this study.

Conflict of Interest
Authors declare that they have no conflict of interest and have no relationship with any financial fund.

References

1 Nyamekye I, Merker L. Management of proximal deep vein thrombosis. Phlebology 2012;27(2, Suppl 2):61–72
2 Moudgill N, Hager E, Gonsalves C, Larson R, Lombardi J, DiMuzio P. May-Thurner syndrome: case report and review of the literature involving modern endovascular therapy. Vascular 2009;17(6): 330–335
3 Suwanabol PA, Tefera G, Schwarze ML. Syndromes associated with the deep veins: phlegmasia cerulea dolens, May-Thurner syndrome, and nutcracker syndrome. Perspect Vasc Surg Endovasc Ther 2010;22(4):223–230
4 Hölper P, Kotelis D, Attigah N, Hyhlik-Dürr A, Böckler D. Longterm results after surgical thrombectomy and simultaneous stenting for

This document was downloaded for personal use only. Unauthorized distribution is strictly prohibited.

symptomatic iliofemoral venous thrombosis. Eur J Vasc Endovasc Surg 2010;39(3):349–355
5 May R, Thurner J. The cause of the predominantly sinistral occurrence of thrombosis of the pelvic veins. Angiology 1957;8(5):419–427
6 O'Sullivan GJ, Semba CP, Bittner CA, et al. Endovascular management of iliac vein compression (May-Thurner) syndrome. J Vasc Interv Radiol 2000;11(7):823–836
7 Thijs W, Rabe KF, Rosendaal FR, Middeldorp S. Predominance of left-sided deep vein thrombosis and body weight. J Thromb Haemost 2010;8(9):2083–2084
8 Bush RL, Lin PH, Lumsden AB. Management of thrombosed dialysis access: thrombectomy versus thrombolysis. Semin Vasc Surg 2004;17(1):32–39
9 Kasirajan K, Gray B, Ouriel K. Percutaneous AngioJet thrombectomy in the management of extensive deep venous thrombosis. J Vasc Interv Radiol 2001;12(2):179–185
10 Bérczi V, Deutschmann HA, Schedlbauer P, Tauss J, Hausegger KA. Early experience and midterm follow-up results with a new, rotational thrombectomy catheter. Cardiovasc Intervent Radiol 2002;25(4):275–281

This document was downloaded for personal use only. Unauthorized distribution is strictly prohibited.