

Expression of Corticosteroid-Binding Globulin CBG in the Human Heart

Authors

H. H. Schäfer¹, V. M. Gebhart¹, K. Hertel², G. F. Jirikowski¹

Affiliations

¹Institute of Anatomy II, University Hospital Jena, Friedrich Schiller University, Jena, Germany

²Institute of Pathology, HELIOS Klinikum Erfurt, Erfurt, Germany

Key words

- human myocardium
- adrenal steroids
- mineralocorticoid receptor
- stress hormones
- corticosteroid binding globulin

Abstract

Glucocorticoids are known to be involved in myocardial regeneration and destruction. Cardiomyocytes are mostly devoid of nuclear glucocorticoid receptors (GRs) and it is generally assumed that effects of adrenal steroids in heart are mediated through the mineralocorticoid receptor (MR). Here we used immunocytochemistry to study localization of corticosteroid binding globulin (CBG) in semithin sections of human cardiac tissue samples. With staining of consecutive sections we examined colocalization with GR and MR immunoreactivities. While GR staining was almost undetectable, a portion of myocytes with MR immunostained nuclei was found. Almost all cardiomyocytes exhibited CBG immunostaining in cytoplasm and on the cell

membrane. Most pronounced CBG immunoreactivities were found in Purkinje fibers and in smooth muscle cells of arterial walls. With RT-PCR, we found in homogenates of cardiac tissue detectable levels of CBG encoding mRNA. Our findings indicate that CBG is expressed in human heart. Known cardiac effects of adrenal steroids may in part be mediated through the binding globulin and its putative membrane receptor in addition to nuclear steroid receptors and direct genomic action. Highlights of our study: Human cardiomyocytes express mineralocorticoid receptors, but are mostly free of nuclear glucocorticoid receptors. CBG is expressed in myocardium and in Purkinje fibers. CBG in heart is colocalized with mineralocorticoid receptor. Endothelia and smooth muscle cells of arterial walls show colocalization of CBG and MR.

received 07.07.2014

accepted 26.08.2014

Bibliography

DOI <http://dx.doi.org/10.1055/s-0034-1389957>

Published online:

September 24, 2014
Horm Metab Res 2015;

47: 596–599

© Georg Thieme Verlag KG

Stuttgart · New York

ISSN 0018-5043

Correspondence

G. F. Jirikowski

Institut für Anatomie II

Universitätsklinikum Jena

Teichgraben 7

07743 Jena

Tel.: +49/3641/938 553

Fax: +49/3641/938 552

Gustav.Jirikowski@med.

uni-jena.de

Introduction

Systemic stress response includes neuroendocrine activation of the hypothalamo-pituitary-adrenal (HPA) axis. Adrenal steroid hormones are known to have an impact on volume regulation, salt retention, and myocardial remodeling [1]. While chronically elevated plasma levels of cortisol lead to hypertrophy of cardiomyocytes [2], aldosterone has been linked to inflammation and fibrosis of the heart [3]. Both, cortisol and aldosterone seem to be ligands with similar affinities for the cardiac mineralocorticoid receptor (MR) and it is likely that cortisol is actually the primary ligand for the MR in heart [3]. Glucocorticoids (GCs) seem to act mainly as antagonists on the cardiac MR [4], which suggests that high stress levels might be cardioprotective to some extent. Indeed it has been shown that low cortisol levels after myocardial infarction are associated with a poorer early prognosis [5,6]. Controversially, other data indicate that perma-

nently elevated plasma cortisol levels are associated with higher morbidity and mortality and increased cardiovascular risk [7]. In an experimental setting with adrenal ectomized rats, administration of cortisol and dexamethasone increased infarct size [8]. In this light it remains unclear how systemic adrenal steroids affect the heart: The beneficial effects of MR inhibitors may relate to a blockade of mineralocorticoids [9]; however, the actions of glucocorticoids need to be reinvestigated in this context. Cardiac remodeling has been shown to occur even in MR-deficient mice [10]. So some of the GC effects on cardiomyocytes may involve mechanisms independent from nuclear MR. While a huge body of clinical and physiological literature exists in this field, there are only few morphological studies in humans so far.

Corticosteroid-binding globulin (CBG) is a heterodimeric glycoprotein [11] with high affinities to GC mineralocorticoids (MC). CBG is primarily expressed in liver [12], capable of binding more

than 95% of systemic glucocorticosteroids. CBG is thought to be involved in systemic steroid transport and buffering, thus enhancing bioavailability of GC and MC. Recently intrinsic expression of steroid-binding globulins was observed in brain, testis, and heart [13]. CBG may be involved in known rapid non-genomic effects of adrenal steroids [14].

In the present study, we addressed the question after an intrinsic expression of CBG in human heart and its possible colocalization with nuclear GR or MR. We used immunocytochemical staining of consecutive semithin sections for high resolution light microscopy. RT-PCR of RNA extracts from tissue homogenates was performed to identify CBG encoding transcripts in human heart.

Materials and Methods



Tissue preparation

Histochemical experiments were performed in accordance with the German law. Use of human tissues was approved by the local ethics committee, protocol # 3086-03/11. Tissue samples of myocardium were obtained during routine dissection of individuals who had no history of cardiac problems and who had passed away for reasons other than cardiac failure. Samples from human liver were used for controls of PCR (samples were provided by Prof. H. Kosmehl, Department of Pathology, Helios Klinikum Erfurt). Post mortem time was <48 h. Samples from males (n=7) and from females (n=5) were subjected to immersion fixation with 4% paraformaldehyde in PBS (0.1 M sodium phosphate buffer pH 7.2, containing 0.9% NaCl) overnight at 4 °C. After washing in PBS, tissue blocks were dehydrated through ascending ethanol series and embedded in EPON. Acetonitrile was used as intermedium, polymerization was performed at 60 °C for 3 days. Serial semithin sections (1 µm) were cut with a Reichert Ultracut microtome and collected on glass slides (Superfrost®, Merck, Darmstadt, Germany). For biochemical experiments formaldehyde fixation was omitted. Such tissue samples were dissected and rapidly frozen in liquid nitrogen (LN₂).

Immunohistochemistry

EPON resin was removed from semithin sections by incubation in 10% sodium methoxide (2 min at RT), followed by rinsing in 1:1 methanol/benzene (2 min at RT) and 2× acetone, 2 min each at room temperature (RT). After washing in PBS, consecutive sections were incubated with either anti-CBG (C-20, goat polyclonal IgG, Santa Cruz Biotechnology) at a dilution of 1:1 000 in PBS containing 2% normal goat serum (PBS-NGS), with anti-GR (ab9568, mouse monoclonal antibody, Abcam), or with anti-MR (ab 62532, rabbit polyclonal antibody, Abcam), both diluted 1:500 in PBS-NGS. Incubation time was overnight at 4 °C. Sections were washed in PBS (3×15 min) and incubated with either anti-mouse IgG, with anti-rabbit IgG or with anti-goat IgG (Sigma, Aldrich, München, Germany) for 2 h at RT, both diluted 1:200 in PBS-NGS. After washing (3×15 min), peroxidase anti-peroxidase soluble complex (produced in either mouse, rabbit, or goat) was applied (Sigma, Aldrich, München, Germany) 1:200 in PBS-NGS for 2 h at RT. Reaction product was visualized with diaminobenzidine and H₂O₂ in PBS (FAST Kit, Sigma, Aldrich, München, Germany). Immunocytochemical controls were carried out with the respective normal serum instead of the specific antibodies. After rinsing in distilled water sections were dehydrated through ascending ethanol series, cleared in xylene, and

coverslipped with Entellan® (Merck Darmstadt, Germany). Sections were evaluated with an Olympus BX 50 photomicroscope with interference contrast illumination.

RNA extraction and PCR

RNA was isolated by TRIzol® extraction. Frozen samples were thawed in 1 ml of TRIzol® (Thermo Fisher Scientific Inc. München, Germany) and homogenized by sonication, followed by incubation for 5 min at RT. Tubes were shaken by hand for 15 s after adding 0.2 ml of chloroform (Roth, Karlsruhe, Germany). Samples were again incubated for 3 min at RT and then centrifuged at 12 000×g for 15 min at 4 °C. The aqueous phase, containing RNA was moved into a new tube. To precipitate RNA, 0.5 ml isopropanol was added, followed by 10 min incubation at RT. Thereafter, samples were centrifuged for 10 min at 12 000×g at 4 °C. After discarding the supernatant, 1 ml of 75% ethanol was added and the pellet was resuspended by brief vortexing. After a final centrifugation at 7 500×g for 5 min at 4 °C, the supernatant was removed and the pellet air-dried. Total RNA was dissolved in 50 µl of RNase-free water and incubated for 15 min at 55 °C.

For reverse transcription and PCR, the QIAGEN OneStep RT-PCR kit was used. Intron-spanning primers were designed using the publicly available genomic coding sequences, (<http://www.ncbi.nlm.nih.gov/entrez>) (<http://genome.ucsc.edu/cgi-bin/hgGateway>) and the public domain primer design software Primer 3 (http://frodo.wi.mit.edu/cgi-bin/primer3/primer3_www.cgi). The primer sequences were: CBG sense, – 5'-CAC CAA CCA GGA AAA TTT CT-3'; CBG antisense, – 5'-AGT GGG ATT TGG ACT GCA GG-3', resulting in a 302 bp amplification product [15]. PCR for β-actin was performed as control: Forward primer: 5'-CAC ACT GTG CCC ATC TAT GA-3' and – reverse primer: 5'-CCG ATA GTG ATG ACC TGA CC-3' with a product size of 272 bp. Primer sets were purchased from Biomol GmbH, Germany.

Reverse transcription was conducted at 50 °C for 30 min. PCR was run in a T3 Thermocycler (Biometra, Göttingen, Germany) under the following conditions: The initial activation step was 95 °C for 15 min followed by 3-step cycling of 94 °C for 30 s, 53 °C for 45 s, and 72 °C for 1 min (35 cycles), and a final extension step of 72 °C for 10 min. Final PCR product was separated on an agarose-gel (1.2%, including ethidium bromide) via electrophoresis (110 V, 60 min). Visualization of the amplification product was performed under ultraviolet light. For estimation of PCR product size a Standard DNA size marker was used (Low range DNA ladder, Jena Bioscience, Germany).

Results



Immunostaining of semithin sections from myocardial samples was combined with high resolution light microscopy. At a section thickness of 1 µm it was possible to identify single cells in several consecutive sections allowing for colocalization of the different antigens. Immunostaining for GR was found in nuclei and in cytoplasm of only scattered myocytes while most of the cardiac muscle cells exhibited specific immunoreactivity for MR. MR staining was mostly confined to nuclei sparing the nucleoli (◉ Fig. 1, panel 1, white asterisk) but occurred also in the perinuclear cytoplasm of many cells. CBG immunoreactivity was observed as granulated reaction product in cytoplasm of almost all myocytes (◉ Fig. 1, panel 2a). CBG was occasionally also found in nuclei. Examination of subsequent sections immun-

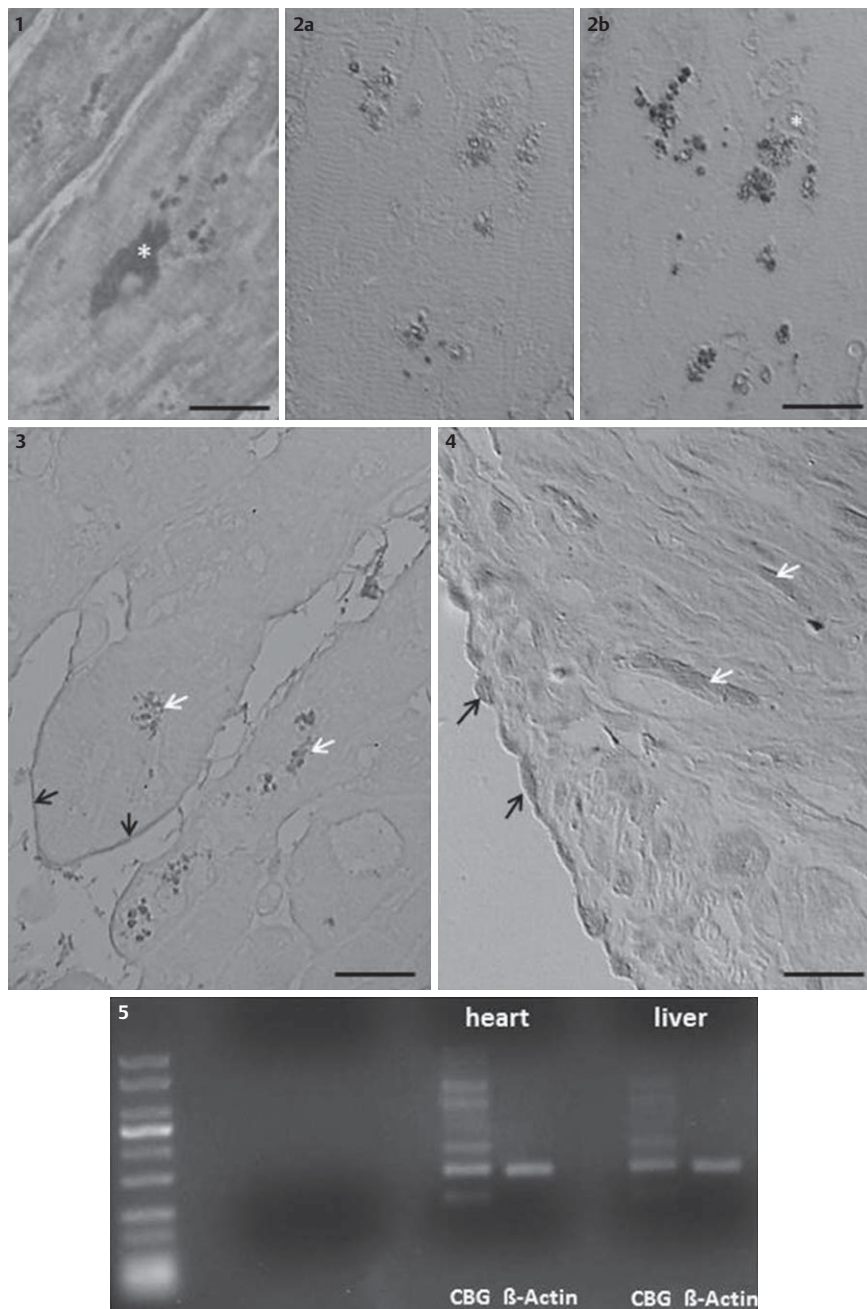


Fig. 1 Panel 1 Nuclear immunoreactivity for MR (white asterisk) in a semithin section of human myocardium. Scale bar = 5 μ m. Panel 2a CBG immunoreactivity was observed as granulated reaction product in cytoplasm of almost all myocytes. The subsequent section stained for MR (panel 2b) reveals colocalization of both CBG and MR. White asterisk marks MR positive but CBG negative nucleus. Scale bar = 8 μ m. Panel 3 CBG staining occurs in cytoplasm of Purkinje fibers (white arrows). In addition CBG is visible in association with the cell membrane (black arrows). Scale bar = 5 μ m. Panel 4 Nuclei of endothelial cells (black arrows) and nuclei of smooth muscle cells within the walls of myocardial arteries contained CBG immunoreactivity (white arrows). Scale bar = 5 μ m. Panel 5 Ethidium bromide gel of PCR products showed bands with a product size of approximately 300 bp, indicating CBG specific transcripts. The amplification product for β -actin was visible as intense bands with a size of 270 bp. RT-PCR from RNA, extracted from human liver was used as control.

stained for MR (► Fig. 1, panel 2b) revealed abundant colocalization of both CBG and MR. CBG staining was most pronounced in Purkinje fibers (► Fig. 1, panel 3, white arrows). Some of these cells showed in addition CBG positive immunoprecipitates associated with the cell membrane (► Fig. 1, panel 3, black arrows). Many of the epithelial cells in endocardium and in vascular endothelia contained CBG positive nuclei (► Fig. 1, panel 4, black arrows), mostly colocalized with MR. The same was true for smooth muscle cells within the walls of myocardial arteries (► Fig. 1, panel 4, black arrows). There were no apparent differences between men and women regarding the immunostained patterns. Immunocytochemical controls were devoid of staining in all cases.

Ethidium bromide gels of PCR products showed bands with a product size of approximately 300 bp, indicating CBG specific transcripts. The amplification product for β -actin was visible as intense bands with a size of 270 bp. RT-PCR from RNA extracted from human liver was used as control (► Fig. 1, panel 5).

Discussion



CBG seems to be expressed in numerous cells within the human heart, most of them MC targets. Our results with RT-PCR indicate intrinsic biosynthesis of the binding globulin. This is in contrast to previous studies, which described the lack of CBG expression in rat heart [16]. This discrepancy may be due to species differences or to differences in immunocytochemical methods. Cardiac CBG found in human heart may be identical with or be rather similar to liver CBG, judging from the equal sizes of both amplification products. Another steroid binding protein, sex hormone binding globulin (SHBG) has previously been shown to occur in human myocardium [13]. Extra hepatic expression of steroid binding globulins has been observed in numerous organs including prostate, testis, and throughout the brain, for review see [14]. Although the functional importance of cardiac CBG is yet to be determined, it seems likely that CBG is involved in adrenal steroid actions on the heart, perhaps in part

independent from nuclear GR. GR immunoreactivity was found only in scattered myocardial cells while MR expression was abundant. It has been suggested that most cardiac effects of GCs are mediated through the MR [17]. Chronic high levels of GCs seem to act in heart mainly as MR antagonists [18] perhaps accounting for tissue damage known to occur in heart upon chronic stress [19].

CBG immunostaining was found in the perinuclear cytoplasm and sometimes associated with the cell membrane. This was especially true for Purkinje fibers, which contained most intense CBG immunoreactivity. It is not yet known whether cellular responses of myocardial cells to chronically elevated GC levels are different from the responses of Purkinje fibers, however, the association of chronic stress with arrhythmia is a well established phenomenon.

CBG was found in most of the endothelial cells of blood vessels within the myocardium and in endocardial cells. Similar observations were made in smooth muscle cells of arterial walls. We have not determined whether endothelial cells and vascular walls outside the heart are also CBG positive. However, the abundance of CBG in these cells indicates functional importance. The known sensitivity of blood vessels to elevated adrenal steroid levels may be linked to ailments including arterial hypertension and small blood vessel disease.

CBG is thought to buffer systemic glucocorticoids and mineralocorticoids, thus regulating the amounts of free hormone [20]. Cardioprotection may therefore be among the functions of CBG expressed in heart. It may be interesting to see whether intrinsic CBG expression is altered in certain cardiac problems. Chronically high systemic cortisol concentrations are associated with a detectable increase of plasma Troponin T, indicating cardiac cell damage [21]. Elevated free corticosterone is a complementary and incremental cardiac event risk predictor in patients afflicted with chronic heart failure [7]. CBG is known to also control aldosterone homeostasis in target tissues. Circulating mineralocorticoid levels as well as steroid biosynthesis are upregulated in pathological states including myocardial infarction, in which both, cortisol and aldosterone are independent predictors of increased mortality risk [22].

CBG has also been associated with nongenomic actions of adrenal steroids including rapid responses [23]. Various authors suggest membrane-associated receptor systems for CBG [14]. Furthermore nonclassical GRs in mitochondria [24] or cytoplasmic receptors [25,26] could be involved in such functions underlying nongenomic responses to a chronically overstimulated HPA axis.

Conflict of Interest

The authors declare that they have no conflict of interest in the authorship or publication of this contribution.

References

- Niebylski A, Boccolini A, Bensi N, Binotti S, Hansen C, Yaciuk R, Gauna H. Neuroendocrine Changes and Natriuresis in Response to Social Stress in Rats. *Stress Health* 2012; 28: 179–185
- Lumbers ER, Boyce AC, Joulianos G, Kumarasamy V, Barner E, Segar JL, Burrell JH. Effects of cortisol on cardiac myocytes and on expression of cardiac genes in fetal sheep. *Am J Physiol Regul Int Comp Physiol* 2005; 288: R567–R574
- Fuller PJ, Yao Y, Yang J, Young MJ. Mechanisms of ligand specificity of the mineralocorticoid receptor. *J Endocrinol* 2012; 213: 15–24
- Baxter JD, Funder JW, Apriletti JW, Webb P. Towards selectively modulating mineralocorticoid receptor function: lessons from other systems. *Mol Cell Endocrinol* 2004; 217: 151–165
- Reynolds RM, Walker BR, Haw S, Newby DE, Mackay DF, Cobbe SM, Pell AC, Fischbacher C, Pringle S, Murdoch D, Dunn F, Oldroyd K, Macintyre P, O'Rourke B, Pell JP. Low serum cortisol predicts early death after acute myocardial infarction. *Crit Care Med* 2010; 38: 973–975
- Norasyikin AW, Norlela S, Rozita M, Masliza M, Shamsul AS, Nor Azmi K. Adrenal insufficiency in acute coronary syndrome. *Singapore Med J* 2009; 50: 962–966
- Yamaji M, Tsutamoto T, Kawahara C, Nishiyama K, Yamamoto T, Fujii M, Horie M. Serum cortisol as a useful predictor of cardiac events in patients with chronic heart failure: the impact of oxidative stress. *Circ Heart Failure* 2009; 2: 608–615
- Mihailidou AS, Loan Le TY, Mardini M, Funder JW. Glucocorticoids activate cardiac mineralocorticoid receptors during experimental myocardial infarction. *Hypertension* 2009; 54: 1306–1312
- Weir RA, Tsoralis IK, Steedman T, Dargie HJ, Fraser R, McMurray JJ, Connell JM. Aldosterone and cortisol predict medium-term left ventricular remodelling following myocardial infarction. *Eur J Heart Failure* 2011; 13: 1305–1313
- Lothar A, Berger S, Gilsbach R, Rosner S, Ecke A, Barreto F, Bauersachs J, Schutz G, Hein L. Ablation of mineralocorticoid receptors in myocytes but not in fibroblasts preserves cardiac function. *Hypertension* 2011; 57: 746–754
- Hammond GL. Molecular properties of corticosteroid binding globulin and the sex-steroid binding proteins. *Endocrine Rev* 1990; 11: 65–79
- Scrocchi LA, Hearn SA, Han VK, Hammond GL. Corticosteroid-binding globulin biosynthesis in the mouse liver and kidney during postnatal development. *Endocrinology* 1993; 132: 910–916
- Schock HW, Herbert Z, Sigusch H, Figulla HR, Jirikowski GF, Lotze U. Expression of androgen-binding protein (ABP) in human cardiac myocytes. *Horm Metab Res* 2006; 38: 225–229
- Sivukhina EV, Jirikowski GF. Adrenal steroids in the brain: role of the intrinsic expression of corticosteroid-binding globulin (CBG) in the stress response. *Steroids* 2014; 81: 70–73
- Nader N, Raverot G, Emptoz-Bonneton A, Dechaud H, Bonnay M, Baudin E, Pugeat M. Mitotane has an estrogenic effect on sex hormone binding globulin and corticosteroid binding globulin in humans. *J Clin Endocrinol Metab* 2006; 91: 2165–2170
- Kuhn RW, Green AL, Raymoure WJ, Siiteri PK. Immunocytochemical localization of corticosteroid-binding globulin in rat tissues. *J Endocrinol* 1986; 108: 31–36
- Iqbal J, Andrew R, Cruden NL, Kenyon CJ, Hughes KA, Newby DE, Hadoke PW, Walker BR. Displacement of cortisol from human heart by acute administration of a mineralocorticoid receptor antagonist. *J Clin Endocrinol Metab* 2014; 99: 915–922
- Baxter JD, Funder JW, Apriletti JW, Webb P. Towards selectively modulating mineralocorticoid receptor function: lessons from other systems. *Mol Cell Endocrinol* 2004; 217: 151–165
- Coons JC, Barnes M, Kusick K. Takotsubo cardiomyopathy. *Am J Health Syst Pharm* 2009; 66: 562–566
- Sorensen MV, Praetorius HA, Nykjaer A, Willnow T, Leipziger J. Impaired aldosterone responsiveness in corticosteroid binding globulin deficient mice. *Acta Physiol (Oxf)* 2011; 201: 169–177
- Lazzarino AI, Hamer M, Gaze D, Collinson P, Steptoe A. The association between cortisol response to mental stress and high-sensitivity cardiac troponin T plasma concentration in healthy adults. *J Am Coll Cardiol* 2013; 62: 1694–1701
- Güder G. Complementary and incremental mortality risk prediction by cortisol and aldosterone in chronic heart failure. *Circulation* 2007; 115: 1754–1761
- Caldwell J, Jirikowski GF. Sex hormone binding globulin and corticosteroid binding globulin as major effectors of steroid action. *Steroids* 2014; 81: 13–16
- Talaber G, Boldizsar F, Bartis D, Palinkas L, Szabo M, Berta G, Setalo G Jr, Nemeth P, Berki T. Mitochondrial translocation of the glucocorticoid receptor in double-positive thymocytes correlates with their sensitivity to glucocorticoid-induced apoptosis. *Int Immunol* 2009; 21: 1269–1276
- Henley DE, Lightman SL. New insights into corticosteroid-binding globulin and glucocorticoid delivery. *Neuroscience* 2011; 180: 1–8
- Stahn C, Buttgerief F. Genomic and nongenomic effects of glucocorticoids. *Nat Clin Pract Rheumatol* 2008; 4: 525–533