

Endoscopic resection of early esophageal neoplasia in patients with esophageal varices: how to succeed while preventing the bleed

Endoscopic resection is an accepted treatment modality for early esophageal neoplasia [1–3]. In patients with esophageal varices, however, endotherapy is contraindicated, although those patients are also precluded from esophagectomy. In patient 1 (a 66-year-old man), upper endoscopy showed esophageal varices

(grade II–III) and a long Barrett's segment containing a polypoid lesion (Paris 0-Ip) [4]. Endoscopic ultrasound (EUS) revealed varices directly beneath the stalk. We decided to snare the lesion with the Duette MBM device (Cook Endoscopy, Limerick, Ireland) mounted on the endoscope as a precautionary measure that

would enable direct variceal ligation in case of bleeding. The resection was uneventful, and histopathological examination showed an intramucosal adenocarcinoma. At 2 months, a recurrent neoplastic lesion was observed (Paris 0-IIa) at the exact location of the previous resection. This lesion was captured by means of one rubber band by which not only the lesion but also the underlying varix was ligated; however snaring was omitted since this would have led to a massive variceal bleed. During 4.5 years of follow-up, no recurrence was detected. Patient 2 (a 50-year-old man) had short-segment Barrett esophagus, a Paris 0-IIa+

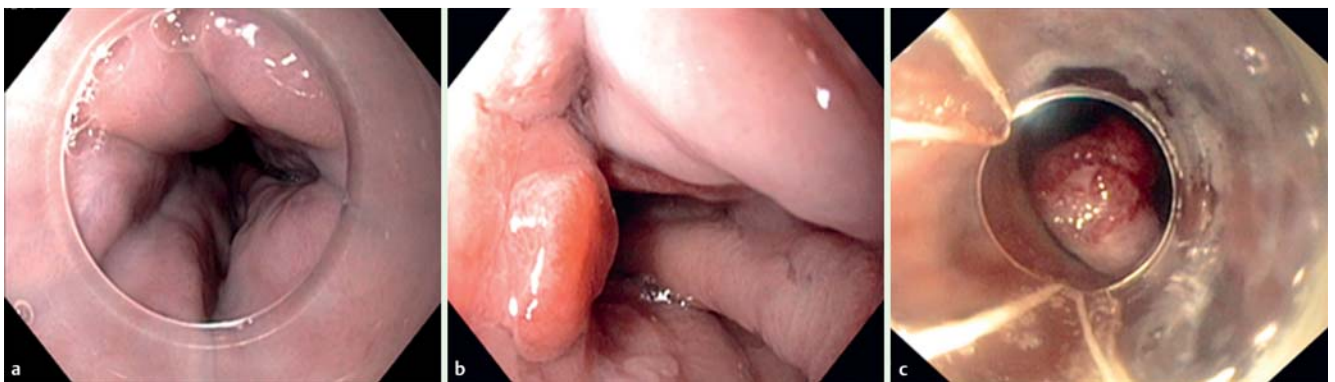

Fig. 1 Endoscopic images of patient 2. **a** Esophageal varices, grade II. **b** An early adenocarcinoma. **c** The lesion after placement of a rubber band. In this case, snaring of the lesion would have led to severe bleeding and was therefore omitted.

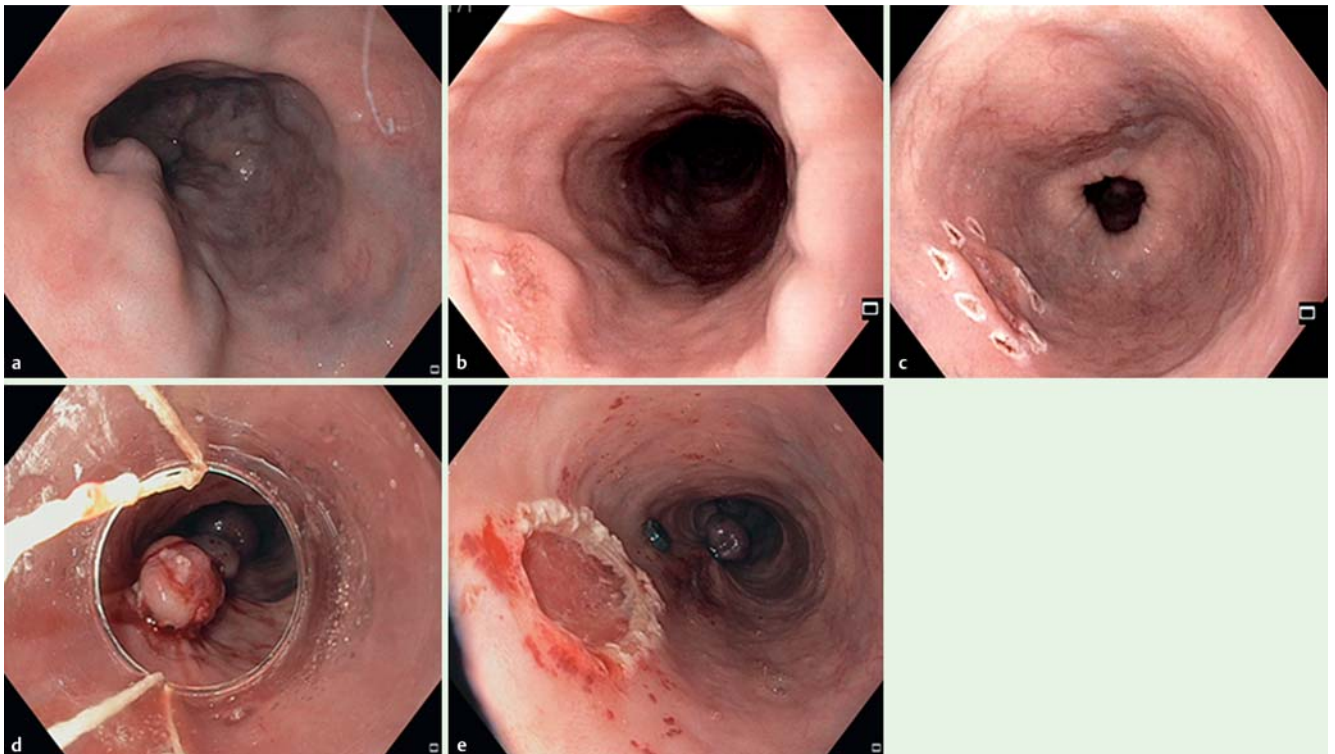


Fig. 2 Endoscopic images of patient 3. **a** Distal esophagus, showing grade II varices. **b** Endoscopic appearance of an early squamous cell carcinoma with a varix directly crossing the lesion. **c** Delineation of the lesion. **d** Rubber band ligation; note that distal to the ligated neoplastic lesion two other pseudopolyps are visible, reflecting the ligation of the feeding varix. **e** The esophagus after removal of the lesion.

IIB lesion (► **Fig. 1**), and esophageal varices (grade II). Biopsies showed adenocarcinoma. EUS revealed varices beneath the lesion, but no pathological lymph nodes. Rubber band ligation (RBL) was performed without subsequent resection. At 9 months after initial treatment, a metachronous lesion was observed, which was also treated with RBL without snaring. At 16 months after primary treatment, no recurrent disease was observed.

In patient 3 (a 66-year-old man), endoscopy showed esophageal varices (grade II), and in the mid-esophagus a Paris 0-IIa lesion (► **Fig. 2**). Biopsies showed squamous cell carcinoma. EUS confirmed the endoscopic impression of one varix running underneath the center of the tumor. Endoscopic resection was preceded by RBL of the varix crossing the lesion. Subsequently, an en bloc resection was done by means of ligate-and-snare using the Duette device. No bleeding occurred. Histopathology showed a squamous cell carcinoma, invading into the submucosa (T1sm3) with a tumor-positive deep resection margin. After discussion in our multidisciplinary team, the patient underwent adjuvant radiotherapy. Follow-up at 4 months showed no signs of residual malignancy.

Few reports have been published that describe the endoscopic treatment of early esophageal neoplasia in patients with esophageal varices [5]. Our case series confirms that the presence of esophageal varices does not necessarily preclude endoscopic management of early esophageal neoplasia. In addition, we describe a new strategy of “ligate and let go”: after ligation of the varix with the overlying early neoplasm, the lesion will become necrotic and will fall off spontaneously. Although this strategy is hampered by the lack of histology, the high surgical risk of these patients would in any case preclude surgery in the event of unfavorable pathology anyway.

Endoscopy_UCTN_Code_TTT_1AO_2AG

Competing interests: None

Hannah T. Künzli, Bas L. A. M. Weusten

Department of Gastroenterology and Hepatology, St. Antonius Hospital Nieuwegein, The Netherlands

References

- 1 *Pouw RE, van Vilsteren FGI, Peters FP et al.* Randomized trial on endoscopic resection-cap versus multiband mucosectomy for piecemeal endoscopic resection of early Barrett's neoplasia. *Gastrointest Endosc* 2011; 74: 35–43
- 2 *Zhang YM, Boerwinkel DF, He S et al.* Prospective feasibility study on the use of multiband mucosectomy for endoscopic resection of early squamous neoplasia in the esophagus. *Endoscopy* 2013; 45: 167–173
- 3 *Alvarez Herrero L, Pouw RE, van Vilsteren FGI et al.* Safety and efficacy of multiband mucosectomy in 1060 resections in Barrett's esophagus. *Endoscopy* 2011; 43: 177–183
- 4 The Paris endoscopic classification of superficial neoplastic lesions: esophagus, stomach, and colon. *Gastrointest Endosc* 2003; 58: S3–S43
- 5 *Inoue H, Endo M, Takeshita K et al.* Endoscopic resection of carcinoma in situ of the esophagus accompanied by esophageal varices. *Surg Endosc* 1991; 5: 182–184

Bibliography

DOI <http://dx.doi.org/10.1055/s-0034-1390777>
Endoscopy 2014; 46: E631–E632
 © Georg Thieme Verlag KG
 Stuttgart · New York
 ISSN 0013-726X

Corresponding author

Hannah T. Künzli, MD
 Department of Gastroenterology and Hepatology
 St. Antonius Hospital, Nieuwegein
 PO Box 2500
 3430 EM Nieuwegein,
 The Netherlands
 Fax: +31-30-6099111
h.kunzli@antoniusziekenhuis.nl