

Intraluminal endoscopic vacuum therapy in a case of ischemia of the blind end of the jejunal loop after Roux-en-Y gastrectomy

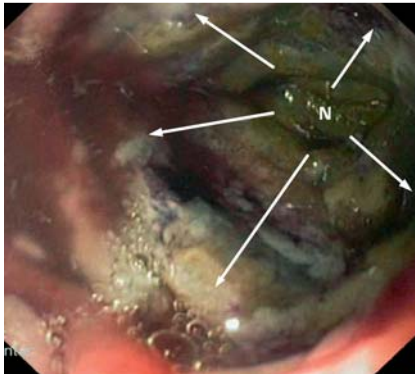


Fig. 1 Necrosis (N) at the bottom of the blind end of the jejunum in a patient who had undergone esophagojejunostomy with an end-to-side Roux-en-Y stapled anastomosis.

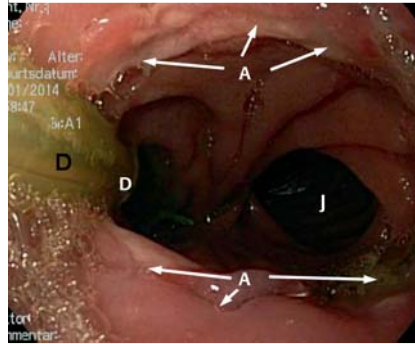


Fig. 2 Endoscopic intraluminal vacuum therapy: the polyurethane foam drainage (D) in situ; anastomosis (A), jejunum (J).

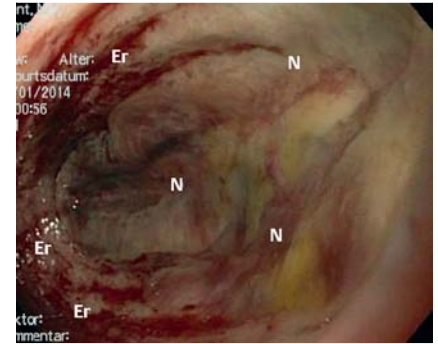


Fig. 3 Day 3 of vacuum therapy: typical erosion pattern (Er), necrosis (N). The necrosis is already reduced.

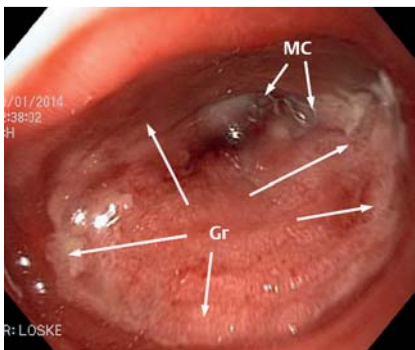


Fig. 4 Day 10 of vacuum therapy: necrosis has disappeared and granulation tissue (Gr) has formed. Some metal suture clamps (MC) can be seen.

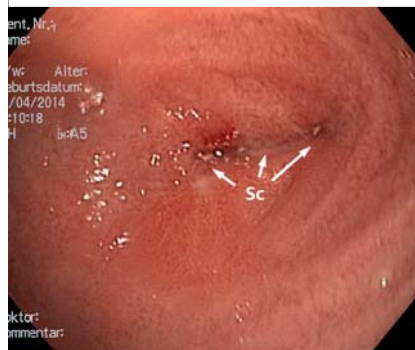

Fig. 5 At 6 weeks after the end of vacuum therapy, re-epithelialized mucosa can be seen, with a small scar (Sc) at the previously necrotic area.

A 43-year-old man underwent a transhiatal gastrectomy and distal esophageal resection because of adenocarcinoma of the gastroesophageal junction (ypT3, ypN0, R0). Esophagojejunostomy was performed with an end-to-side Roux-en-Y stapled anastomosis. The jejunum was shortened using a linear stapler. On postoperative day 3, increasing inflammatory parameters C-reactive protein (CRP) 310 mg/l prompted an endoscopic examination. We found an intact esophagojejunal anastomosis with good perfusion without leakage, but also ischemia at the blind end of the jejunum (● Fig. 1).

According to previously described endoscopic procedures [1], intraluminal endoscopic vacuum therapy was applied immediately after diagnosis. A small-sized

open-pore polyurethane foam drainage (1.5 cm diameter, 3 cm length, Suprasorb CNP Wundschaum; Lohmann & Rauscher, Neuwied, Germany) was placed onto the ischemic mucosa (● Fig. 2). Continuous vacuum was applied using an electronic vacuum device (125 mmHg, intensity 10, V.A.C. Freedom Therapy System; Kinetic Concepts, San Antonio, Texas, USA). The initial endoscopy was done with the patient under general anesthesia.

Vacuum drainage was changed initially on day 3 of therapy. The necrosis was already reduced, and reperfusion could be seen where the sponge had been in contact (● Fig. 3). Therapy was continued for 7 days, by which time the necrotic tissue had completely disappeared, perfusion was restored, and granulation tissue had

grown. Some metal suture clamps could be seen at the bottom of the wound (● Fig. 4). Even though the suture was dehiscent, extraluminal tissue had compartmentalized the wound.

After the end of the therapy the patient was allowed to drink liquid food. The patient left hospital 17 days after the operation, in good condition and with normal nutrition. At follow-up endoscopy 6 weeks later we saw a re-epithelialized mucosa with a tiny scar at the previously necrotic area (● Fig. 5).

To the best of our knowledge this is the first report of endoscopic vacuum treatment in a case of ischemia of the blind end of the jejunum after gastrectomy with end-to-side Roux-en-Y repair. Placement of the open-pore foam intraluminally onto the ischemic area prevented rupture damage of the jejunal suture and leakage complications. No operative treatment was necessary.

Endoscopy_UCTN_Code_TTT_1AO_2AI

Competing interests: Dr. Loske is a consultant for Lohmann & Rauscher.

Gunnar Loske, Tobias Schorsch, Henning Schmidt-Seithe, Christian Müller

Department of General, Abdominal, Thoracic and Vascular Surgery, Katholisches Marienkrankenhaus Hamburg, Germany

Reference

- 1 *Loske G, Schorsch T, Müller C.* Intraluminal and intracavitary vacuum therapy for esophageal leakage: a new endoscopic minimally invasive approach. *Endoscopy* 2011; 43: 540–544

Bibliography

DOI <http://dx.doi.org/10.1055/s-0034-1390913>
Endoscopy 2014; 46: E575–E576
© Georg Thieme Verlag KG
Stuttgart · New York
ISSN 0013-726X

Corresponding author

Gunnar Loske, MD
Marienkrankenhaus Hamburg
Alfredstr. 9
22087 Hamburg
Germany
Fax: +49-40-25461400
loske.chir@marienkrankenhaus.org