

Ectopic varices in a pancreatojejunal anastomosis: a rare cause of hemorrhage

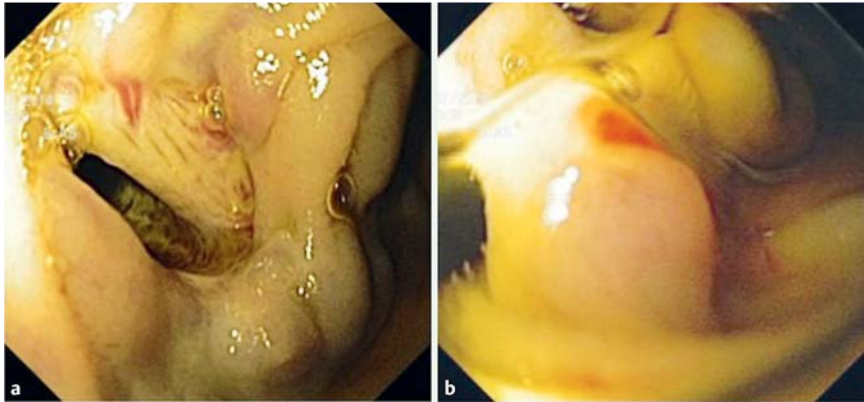


Fig. 1 Views during push enteroscopy in a man with a history of pylorus-preserving pancreatoduodenectomy for pancreatic adenocarcinoma showing: **a** ectopic varices at a pancreatojejunal anastomosis; **b** a rupture point, which was subsequently treated with endoscopic injection therapy.

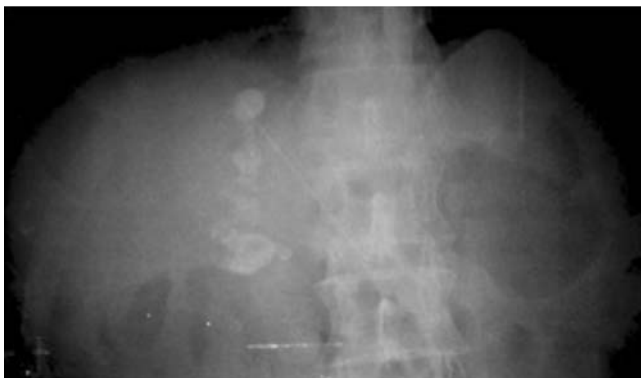

Fig. 2 Abdominal radiograph showing the location and occlusion of the varices after their injection with a mixture of cyanoacrylate and Lipiodol.

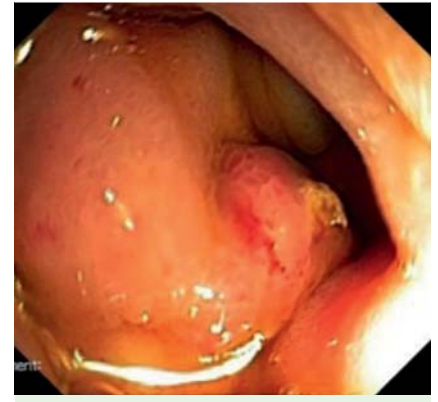

Fig. 3 Follow-up endoscopy 2 weeks later showing obliteration of the ectopic varices.

Ectopic variceal bleeding is a rare cause of gastrointestinal hemorrhage, representing up to 5% of all variceal bleeding episodes [1]. The most common cause of ectopic variceal bleeding is portal hypertension (from both intrahepatic and extrahepatic causes) [2]. In the absence of portal hypertension, other causes may include abdominal surgery, abnormalities in the venous outflow vessels, abdominal vascular thrombosis, hepatocellular carcinoma, pancreatitis, and familial syndromes [2,3]. Ectopic variceal bleeding can pose a diagnostic dilemma and endoscopy plays a major role in the diagnosis and treatment of this condition.

A 56-year-old man presented to the emergency room with a 1-week history of melena. The patient's medical history included a pancreatic adenocarcinoma

treated 2 years previously with a pylorus-preserving pancreatoduodenectomy and chemotherapy. On admission, his vital signs were stable but the results of a laboratory workup showed severe anemia (hemoglobin 6.4 g/dL).

After he had undergone esophagogastroduodenoscopy (EGD) and colonoscopy, both of which were normal, it was decided to perform a push enteroscopy through the afferent and efferent jejunal limbs. Signs of fresh blood were noted in the afferent limb and the pancreatojejunal anastomosis was reached. At the anastomosis, nodular and bluish vascular dilations were seen, suggestive of ectopic varices (● Fig. 1 a). A rupture point was identified (● Fig. 1 b) and treated with injection of 2 mL of a mixture of cyanoacrylate and Lipiodol. Post-treatment abdomi-

nal radiography confirmed the location and occlusion of the varices (● Fig. 2). A follow-up endoscopy 2 weeks later revealed obliterated varices (● Fig. 3) and no additional intervention was required. To the authors' knowledge, this is the first report with imaging of ectopic varices in a pancreatojejunal anastomosis. As well as reporting the successful resolution of this unusual situation with conventional endoscopic therapy, we emphasize the appearance of this abnormality with these rare endoscopic images.

Endoscopy_UCTN_Code_CCL_1AC_2AB

Competing interests: None

**Bruno Moreira Gonçalves¹,
Pedro Bastos¹, Pedro Leão^{2,3,4},
Carla Rolanda^{1,3,4}**

¹ Department of Gastroenterology, Hospital Braga, Braga, Portugal

² Department of General Surgery, Hospital Braga, Braga, Portugal

³ Life and Health Sciences Research Institute (ICVS), School of Health Sciences, University of Minho, Braga, Portugal

⁴ ICVS/3B's – PT Government Associate Laboratory, Braga/Guimarães, Portugal

References

- 1 Akhter M, Haskal ZJ. Diagnosis and management of ectopic varices. *Gastrointest Interv* 2012; 1: 3–10
- 2 Kastanakis M, Anyfantakis D, Katsougris N et al. Massive gastrointestinal bleeding due to isolated jejunal varices in a patient without portal hypertension. *Int J Surg Case Rep* 2013; 4: 439–441
- 3 Helmy A, Kahtani K, Fadda M. Updates in the pathogenesis, diagnosis and management of ectopic varices. *Hepatol Int* 2008; 2: 322–334

Bibliography

DOI <http://dx.doi.org/10.1055/s-0034-1391871>
Endoscopy 2015; 47: E269–E270
© Georg Thieme Verlag KG
Stuttgart · New York
ISSN 0013-726X

Corresponding author

Bruno Moreira Gonçalves, MD
Serviço de Gastreenterologia
Hospital de Braga
Sete Fontes – São Victor
4710-243 Braga
Portugal
Fax: +351-25-3027999
brunommgoncalves@gmail.com