

# Fertility and Pregnancy Outcome after Myoma Enucleation by Minilaparotomy under Microsurgical Conditions in Pronounced Uterus Myomatosis

Fertilität und Schwangerschaftsoutcome nach Myomenukleation per Minilaparotomie unter mikrochirurgischen Bedingungen bei ausgeprägtem Uterus myomatosis

## Authors

K. Floss, G.-J. Garcia-Rocha, S. Kundu, C. S. von Kaisenberg, P. Hillemanns, C. Schippert

## Affiliation

Obstetrics and Gynecology, Medical School of Hannover (MHH), Hannover

## Key words

- myoma
- sterility
- myoma enucleation
- pregnancy outcome
- minilaparotomy
- microsurgery

## Schlüsselwörter

- Myome
- Sterilität
- Myomenukleation
- Schwangerschaftsoutcome
- Minilaparotomie
- Mikrochirurgie



Deutschsprachige  
Zusatzinformationen  
online abrufbar unter:  
[www.thieme-connect.de/  
ejournals/toc/gebfra](http://www.thieme-connect.de/ejournals/toc/gebfra)

**received** 24.7.2014  
**revised** 5.12.2014  
**accepted** 5.12.2014

## Bibliography

**DOI** [http://dx.doi.org/  
10.1055/s-0034-1396163](http://dx.doi.org/10.1055/s-0034-1396163)  
Geburtsh Frauenheilk 2015; 75:  
56–63 © Georg Thieme  
Verlag KG Stuttgart · New York ·  
ISSN 0016-5751

## Correspondence

**Dr. Cordula Schippert, M. D.**  
Medical School of Hannover  
(MHH)  
Obstetrics and Gynecology  
Carl-Neuberg-Straße 1, OE 6410  
30625 Hannover  
Schippert.Cordula@  
mh-hannover.de

## Abstract



**Introduction:** Besides the typical complaints and symptoms, myomas can cause sterility, infertility and complications during pregnancy. Laparoscopic interventions reach their limits with regard to organ preservation and the simultaneous desire to have children in the removal of multiple and larger intramural myoma nodes. The aim of this study is to examine fertility status and pregnancy outcome after myoma removal by minilaparotomy (skin incision maximal 8 cm) in women with pronounced uterus myomatosis.

**Materials and Methods:** This retrospective study makes use of the data from 160 patients with an average age of 34.6 years. Factors analysed include number, size and localisation of the myomas, complaints due to the myoma, pre- and postoperative gravidity, mode of delivery, and complications of birth.

**Results:** Indications for organ-sparing myoma enucleation were the desire to have children (72.5%), bleeding disorders (60%) and pressure discomfort (36.5%). On average 4.95 (SD ± 0.41), maximally 46 myomas were removed. The largest myoma had a diameter of 6.64 cm (SD ± 2.74). 82.5% of the patients had transmural myomas, in 17.5% the uterine cavity was inadvertently opened. On average the operating time was 163 minutes (SD ± 45.47), the blood loss 1.59 g/dL (SD ± 0.955). 60.3% of the patients with the desire to have children became pregnant postoperatively. 75.3% of the pregnancies were on average carried through to the 38th week (28.4% vaginal deliveries, 71.6% Caesarean sections). In the postoperative period there was one case of uterine rupture in the vicinity of a previous scar.

**Discussion:** By means of the microsurgical “mini-laparotomy” even extensive myomatous uterine changes can, in the majority of cases, be operated in an organ-sparing manner with retention of the ability to conceive and to carry a pregnancy

## Zusammenfassung



**Einleitung:** Myome können neben typischen Beschwerden und Symptomen Sterilität, Infertilität und Schwangerschaftskomplikationen verursachen. Laparoskopische Eingriffe stoßen bei der Entfernung multipler und großer intramuraler Myomknoten bez. der Organerhaltung bei vorhandenem Kinderwunsch an ihre Grenzen. Ziel der Arbeit ist, das Fertilitätsvermögen und Schwangerschaftsoutcome nach Myomentfernung per Minilaparotomie (Hautinzision max. 8 cm) bei Frauen mit ausgeprägtem Uterus myomatosis zu untersuchen.

**Material und Methodik:** Die retrospektive Arbeit beinhaltet Daten von 160 Patientinnen mit einem mittleren Alter von 34,6 Jahren. Analysiert wurden Zahl, Größe und Lage der Myome, myombedingte Beschwerden, prä- und postoperative Graviditäten, Entbindungsmodus und Geburtskomplikationen.

**Ergebnisse:** Indikationen zur konservierenden Myomenukleation waren Kinderwunsch (72,5%), Blutungsstörungen (60%) und Druckbeschwerden (36,5%). Im Mittel wurden 4,95 (SD ± 0,41), max. 46 Myome entfernt. Der größte Myomdurchmesser betrug 6,64 cm (SD ± 2,74). In 82,5% lagen transmurale Myome vor, in 17,5% wurde das Cavum uteri intraoperativ ungewollt eröffnet. Die Operationsdauer betrug durchschnittlich 163 min (SD ± 45,47), der Blutverlust 1,59 g/dl (SD ± 0,955). 60,3% der Kinderwunschpatientinnen wurden postoperativ schwanger. 75,3% der Schwangerschaften wurden im Mittel bis zur 38. SSW ausgetragen (28,4% vaginale Geburt, 71,6% Sectiones). Postoperativ trat einmal eine Uterusruptur im Bereich einer alten Sectionarbe auf.

**Diskussion:** Mittels mikrochirurgischer „Mini-Laparotomie“ lassen sich selbst erhebliche myomatöse Uterusveränderungen organerhaltend operieren und die Konzeptionsfähigkeit sowie das

through to maturity of the infant. The risk for a postoperative uterine rupture in a subsequent pregnancy and during delivery is minimal.

## Introduction

Uterine myomas are the most frequent benign hormone-dependent tumours in women of child-bearing age with a prevalence of 50% in European and up to 80% in black African women [1, 2]. Only rarely does a myoma degenerate to a leiomyosarcoma, the prevalence of which lies between 0.4 and 1.80 per 100 000 women [3]. Signs for a malignant degeneration, among others, can be rapid growth or increased vascularisation [4]. Although many women with myomas are at first mostly asymptomatic, later bleeding disorders (dys- and hypermenorrhoea, menorrhagia with anaemia), lower abdominal pain, pressure complaints in the abdomen and defaecation problems or hydronephroses occur in about 50% of them [5]. The symptoms caused by myomas vary individually according to size, location and number of lesions. Myomas can, in addition, cause not only sterility but also infertility. Submucosal and intracavity myomas are accepted as reasons for sterility or infertility due to their endometrial architecture on histology. Larger intramural myomas hinder growth of the pregnant uterus and lead to asymmetrical deformities with escalated contractility of the healthy musculature [6]. Furthermore, myoma-related changes of myometric contractility with negative effects on migration of sperm and transport of embryos as well as obstruction of the proximal tubal segments, impairment of blastocyst implantation due to venous ectasias and atrophy of the endometrium near to the myoma [7] as well as increased expression of angiogenetic factors have been reported [8]. Intramural myomas can restrict the success of in vitro fertilisation (IVF) [9, 10]. During pregnancy an in part considerably increased growth can be seen in about 25% of the myomas, especially in the first trimester. The myoma-related complications of pregnancy and birth include early and late miscarriages, premature onset of labour and rupture of membranes, necrotisation of above all larger myomas, chorio-/endometritis, placental adhesion detachment disorders as well as postpartum haemorrhagias/atonias [6, 7, 11]. Myomas near the cervix can represent an obstacle to delivery. Drug treatment such as ulipristal acetate (Esmya®), GnRH analogues or pure gestagene formulations cannot always be employed when there is a desire to have children. However, GnRH analogues are an effective therapy for uterus myomatosis, albeit associated with significant side effects [12], but in the meantime ulipristal acetate is available as a substance with a markedly lower side effect profile [13, 14]. Apart from drug treatments, there are further invasive and non-invasive methods such as uterine artery embolisation (UAE) [15] or MRI-guided focused ultrasound therapy (MRgFUS). These two procedures are neither without risk nor suitable for all afflicted patients [7, 16–20]. With regard to pregnancy after UAE, there are as yet only few long-term results and the available data reveal rather low pregnancy rates [21] as well as a higher risk of miscarriage [20]. Pregnancy after MRgFUS is in principle possible and can be carried through [22–24]; however, abdominal bleeding, renewed myoma growth and placentation disorders (placenta previa) have been described during the pregnancy [24]. Sufficient and valid long-term results or prospective trials for women with the desire to have children are lacking. In numerous trials the desire to have children is an

Vermögen, eine Schwangerschaft bis zur Reife des Kindes auszutragen, in hohem Maße wiederherstellen. Das Risiko für postoperative Uterusrupturen in graviditate und während der Geburt ist minimal.

exclusion criterion for MRgFUS [22, 25, 26]. According to the present state of knowledge, not only UAE but also MRgFUS are indicated in Germany solely for women after completion of their family planning or, respectively, can only be recommended for patients with myoma-related fertility problems who also suffer from a high-risk of surgery or those who refuse an operation [20, 22, 23, 27].

Organ-sparing myomectomy is an established, fertility-conserving procedure standing alongside hysterectomy [28]. Advantages of the laparoscopic intervention in comparison to conventional laparotomy are less pain [18, 29], lower intraoperative loss of blood [30], mostly shorter operating time in dependence on the original diagnosis, and a lower rate of postoperative adhesions [31]. However, in the case of difficultly accessible or multiple myomas, the operating time can under certain circumstances be longer than that of a conventional laparotomy, so that laparoscopic myoma removal reaches its limits, especially for multiple myomas, complex situations and the patient's desire to have children [32–34].

The aim of this study is to assess the fertility capability and pregnancy outcome after operative removal of myomas by minilaparotomy in a special patient collective. The collective consisted of women with mostly pronounced uterus myomatosis in the form of multiple, larger myomas or myomas in unfavourable locations. The majority of selected women still had a desire to have children, had previously suffered a miscarriage or wished to retain their uterus. Special attention in the data analysis was paid to complications in pregnancy or delivery due to the surgery, and especially to postoperative uterine ruptures.

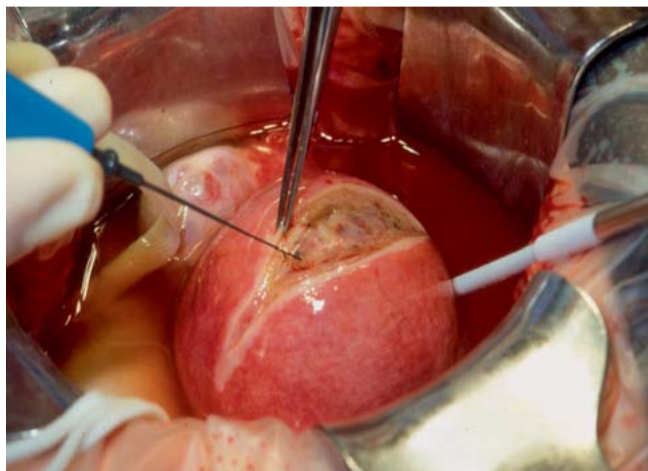
## Materials and Methods

### Recruiting the trial collective

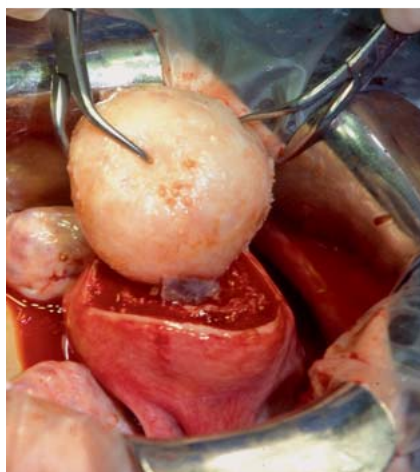
Retrospective data from patients of the Department of Gynaecology and Obstetrics of the Medical University of Hannover in whom a symptomatic uterus myomatosis was operated by minilaparotomy under standardised microsurgical conditions in the period from June 2004 to June 2008 were evaluated. Family planning was not completed for the majority of the selected women. In the first six months after surgery the women were required to use contraception, and at least 18 months had passed prior to data acquisition. The ethics commission of the Medical University of Hannover approved the trial (No. 473).

### Inclusion and exclusion criteria

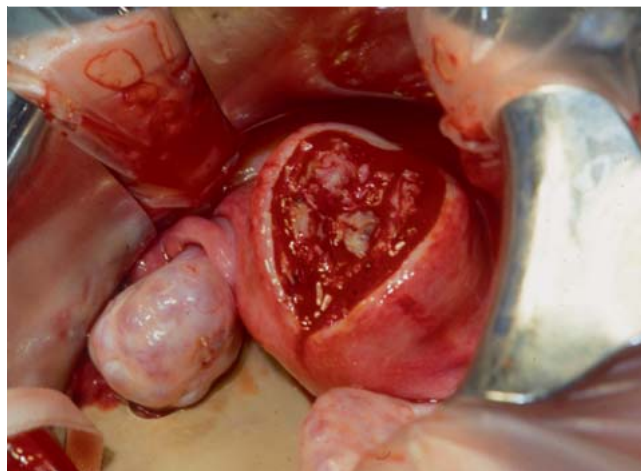
Inclusion criteria were: age  $\leq 42$  years; myoma size at least 5 cm in maximum diameter or 4 cm with hysteroscopically demonstrated cavity contact. When the largest myoma was smaller, at least three myomas had to be resected. Patients with sarcomatous degeneration or the concomitant existence of ovarian or andrological sterility as well as endometriosis rAFS III°/IV° were excluded, since the latter diseases can have a considerable negative influence on fertility ability and thus falsify the analysis of postoperative pregnancy rates.



**Fig. 1** Monopolar incision of the myometrium down to visualisation of the myoma; identification of a transmural fundus myoma with displacement of the cavity (Figures 1–3 from [35]). With permission of Springer Science + Business Media B. V. Special Licensing Department).



**Fig. 2** Enucleation of the fundus myoma while sparing the cavity.



**Fig. 3** Situation after enucleation of the myoma, subsequent multilayer adaptation of the wound cavity with vicryl.

### Surgical procedures

An obligatory hysteroscopy was performed before starting the laparotomy in order to visualise or, respectively, remove intracavitary and submucous myomas, etc. For the minilaparotomy the patient is placed in a supine position and a panhandle incision of ca. 8–10 cm is made. Under bipolar coagulation (Fig. 1) and continuous flushing of the wound site with heparinised Ringer's lactate solution, complete removal of the myomas was carried out with sparing of healthy myometrium and as far as possible avoidance of cavity opening (Fig. 2). The resulting wound cavity (Fig. 3) is closed in two or three layers depending on the depth of the wound with vicryl sutures of size 0 to 2 by Z or individual button sutures according to layer while avoiding cavities. For adhesion prophylaxis the serosa is adapted with 4.0 vicryl individual button sutures.

### Questionnaire/data acquisition

After surgery the patients were questioned about the following items by means of a questionnaire: preoperative as well as postoperative myoma-related complaints (dys- or hypermenorrhoea, pressure sensitivity in lower abdomen, etc.), current desire for

children, previous pregnancies, miscarriages, extrauterine pregnancies, preoperative births, postoperative pregnancies, type of conception (spontaneous or through IVF), course of postoperative pregnancies including possible complications of pregnancy such as miscarriages, extrauterine pregnancies, placental abruption, bleeding and other pathologies that could be freely named. In addition, information was requested about mode of delivery (vaginal spontaneous delivery, vacuum or forceps delivery, primary or, respectively, secondary Caesarean section), possible complications of labour (uterine atony and rupture) and on outcome of the baby (gestation period, birth weight, Apgar). The following data were extracted from the patient records: age, body mass index (BMI), preoperative number of sonographically detected myomas as well as the number of intraoperatively removed myomas, size of the largest myoma (pathology result), localisation and position of the largest myoma, intraoperative opening of the cavity (yes/no), previous operations on the uterus (myoma enucleation, Caesarean section), preoperative therapy with GnRH analogues (yes/no/duration), operation time, intraoperative blood loss, postoperative complications.

### Statistical analysis

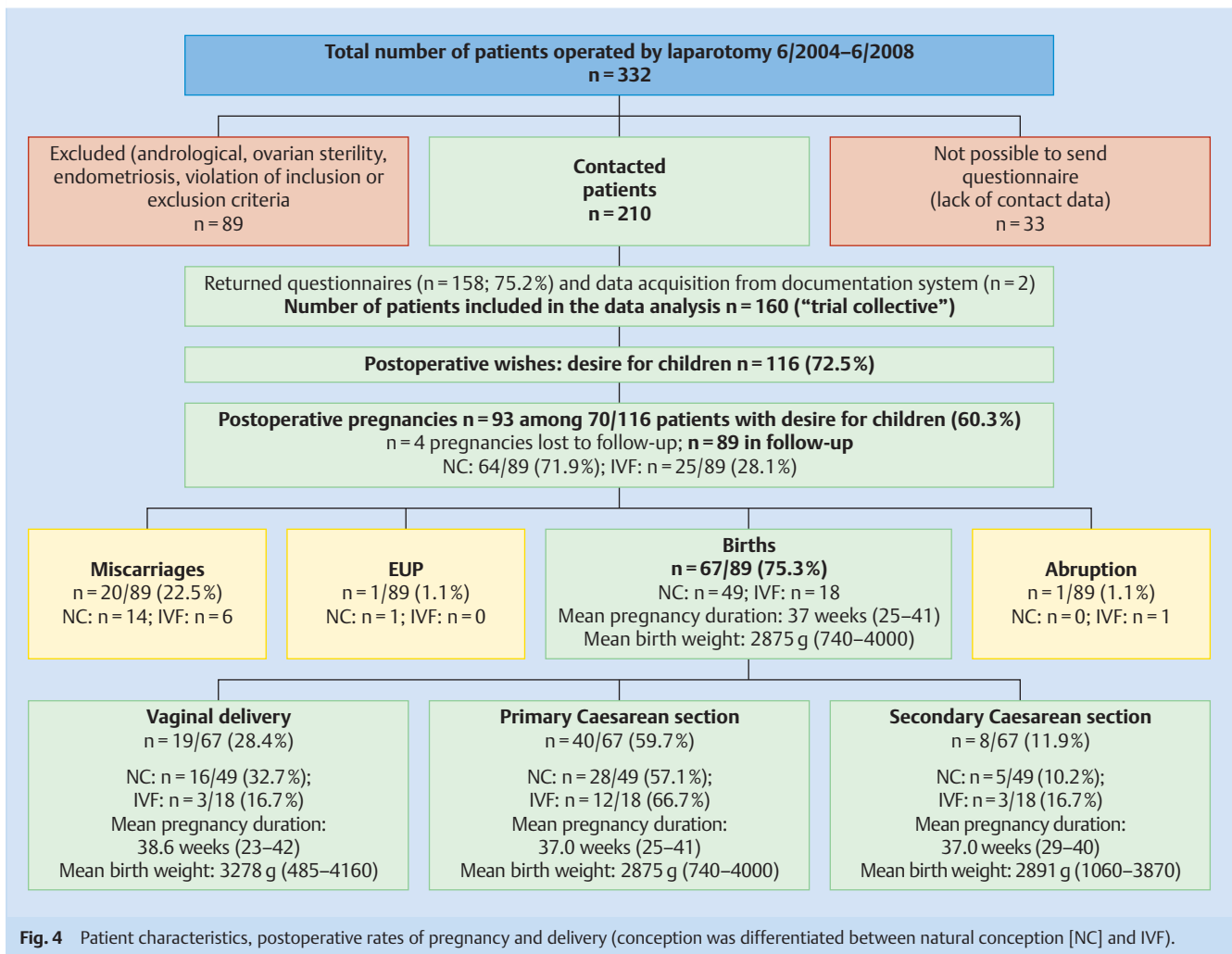
The data were analysed with the help of SPSS 18 and calculated by means of the Wald test. The relationships between symptoms and complaints were determined by the logistic regression method.

### Results



#### Study population

Altogether, 332 patients were operated for benign myomas, 89 women were not included in the study because of andrological (n=3) or, respectively, ovarian sterility (n=4), endometriosis rASRM III°/IV° (n=22) as well as violation of the inclusion or, respectively, exclusion criteria (n=60). 33 women could not be contacted by post. The response rate of the questionnaire amounted to 75.2% (158/210). The details from two further patients could be unambiguously evaluated on the basis of the clinic's internal documentation system so that, altogether, 160 data sets were available for evaluation (Fig. 4).



The average age of the 160 patients amounted to 34.6 years (23–42; SD  $\pm$  3.8), 46.3% of the women were between 35 and 42 years old. The average BMI was 24.7 (17–58; SD  $\pm$  0.43). The indication for myoma enucleation in 72.5% was an unfulfilled desire to have children, in 60% bleeding disorders and in 36.5% pressure complaints. In most cases several symptoms were present concomitantly.

### Operation characteristics

On average 5.0 myomas (SD  $\pm$  0.4; 1–46) were removed. In 52.5% of the women one to three myomas, in two women 14 myomas and in one patient each 15, 19, 22 and 46 myomas were enucleated with preservation of the uterus. In the preoperative ultrasound examinations fewer myomas were detected than were removed intraoperatively (mean value [MV] 1.98; SD  $\pm$  0.11). The maximum diameter of the largest enucleated myoma in each case varied between 1.5 cm and 19 cm, the MV amounted to 6.6 cm (SD  $\pm$  2.74). The surgical characteristics, position and localisation of the largest resected myoma in each patient as well as previous operations and prior treatments with GnRH analogues are summarised in **Table 1**. On average the operating time amounted to 163 minutes (SD  $\pm$  45.5; 75–290 minutes) and was, as to be expected, longer with increasing numbers of myomas to be resected.

### Intra-/postoperative complications: blood loss, cavity opening

The intraoperative blood loss was calculated on the basis of the pre- and postoperative haemoglobin values and amounted on average to 1.6 g/dL (SD  $\pm$  1.0). In one patient who underwent enucleation of 46 myomas three erythrocyte concentrates (ECs) were administered. The patient became pregnant in the postoperative period and delivered her baby by a primary Caesarean section. The intraoperative blood loss does not show a significant correlation with the maximum size ( $p = 0.09$ ) or the increasing number of myomas removed ( $p = 0.54$ ), however there is a tendency to increasing blood loss on removal of larger myomas. A preoperative therapy with GnRH analogues does not correlate with the intraoperative blood loss ( $p = 0.39$ ). Opening of the cavity (17.5%,  $n = 28$ ) occurred significantly more often in cases of anterior wall and posterior wall myomas ( $p = 0.0$ ;  $p = 0.0$ ) and with higher probability when a previous hysteroscopy had shown a protrusion of the myoma into the uterine cavity ( $p = 0.07$ /intramural anterior wall myoma,  $p = 0.0$ /intramural posterior wall myoma). In two women (1.3%) the myomas could not be removed completely due to the danger of loss of the organ. The intra- and, respectively, postoperative complications are listed in **Table 2**.

**Table 1** Operation characteristics: number, maximum size, localisation and position of the removed myomas, proportion of patients with previous laparotomies, myoma recurrences and GnRH analogue pre-treatment in months.

|  | Mean value     | Standard deviation | Variance |
|--|----------------|--------------------|----------|
| Number of removed myomas   | 5.0            | 0.4                | 1–46     |
| ▶ 1 myoma removed  | n = 39 (2.4%)  |                    |          |
| ▶ 2 myomas removed   | n = 24 (15.0%) |                    |          |
| ▶ 3 myomas removed   | n = 21 (13.1%) |                    |          |
| Size of the largest myoma (cm)   | 6.6            | 2.7                | 1.5–19   |
| Operating time (min)   | 163            | 45.5               | 75–290   |
| <b>Localisation of the respective largest enucleated myoma</b>   |                |                    |          |
| Intramural   | 82.5%          |                    |          |
| ▶ with cavity contact  | 50.0%          |                    |          |
| Subserous  | 15.6%          |                    |          |
| Submucous  | 1.9%           |                    |          |
| <b>Position of the respective largest enucleated myoma</b>   |                |                    |          |
| Posterior wall   | 45.6%          |                    |          |
| Anterior wall  | 30.0%          |                    |          |
| Fundus   | 15.0%          |                    |          |
| Lateral wall   | 9.4%           |                    |          |
| <b>Previous therapies/interventions</b>  |                |                    |          |
| Proportion of patients with previous laparotomy (Caesarean section, adnexal procedure, myoma enucleations) | 18.8%          |                    | n = 85   |
| Proportion of patients with myoma recurrence   | 13.3%          |                    | n = 21   |
| Proportion of patients with preoperative consumption of GnRH analogues                                     | 46.3%          |                    | n = 74   |
| ▶ 1 month  | 1.9%           |                    | n = 3    |
| ▶ 2 months   | 24.4%          |                    | n = 39   |
| ▶ 3 months   | 15.0%          |                    | n = 24   |
| ▶ 4 months   | 4.4%           |                    | n = 7    |
| ▶ 5 months   | 0.6%           |                    | n = 1    |

### Postoperative outcome: myoma-related complaints, rates of pregnancies and births

In 88.4% of the patients suffering from preoperative bleeding disorders, there was a marked reduction of the symptoms in the postoperative period. 115 patients (71.9%) were null gravida preoperatively, 28.1% (45 patients) had had at least one pregnancy. The rate of miscarriages amounted to 75.6% (34 women). 72.5% of the operated women (116 patients) expressed the desire to have children, of these 60.3% (70 women) became pregnant after surgery. Altogether, these 70 women experienced 93 pregnancies up to the end of the data acquisition period, 64 by natural conception as well as 25 after IVF. In four pregnancies neither the type of conception nor the outcome of the pregnancy could be determined, and thus these were excluded from the analysis (▶ Fig. 4). 17 patients (14.6% of 116 women with the desire to have children) became pregnant twice after surgery, 4 women (3.4%) three times and 2 women became pregnant 4 times.

### Postoperative complications of pregnancy and birth

20 of the 89 recorded pregnancies (22.5%) ended with a miscarriage, independent of the type of conception ( $p = 0.47$ ). 67 pregnancies (75.3%) were carried through to the end, in 28.4% were completed with a vaginal delivery, the rate of Caesarean sections amounted to 71.6% of all deliveries (59.7% primary, 11.9% secondary). The gestation period was on average (40.4%) 38 weeks. 21.2% of the babies were born prior to the 37th week of preg-

**Table 2** Intra- and postoperative complications.

| Loss of haemoglobin (g/dL)   | median | SD    | variance |
|--|--------|-------|----------|
|  | 1.6    | ± 1.0 | 0–5.2    |
| Intraoperative administration of 3 ECs                               |        |       | n = 1    |
| Intraoperative cavity opening  |        |       | n = 28   |
| Incomplete myoma resection due to danger of hysterectomy             |        |       | n = 2    |
| Postoperative subcutaneous haematoma in abdominal wall with revision |        |       | n = 2    |
| Postoperative syncope with fall and ankle fracture                   |        |       | n = 1    |
| Complication-free course   |        |       | n = 154  |

nancy, 65.4% between the 37th and 40th week, and 13.5% in the 41st to 42nd week. The pregnancy outcomes, gestation periods, modes of delivery, and birth weights of the babies are summarised in ▶ Fig. 4. The average Apgar values were 8.7, 9.6 and 9.8 after one, five and ten minutes, respectively. In one patient a prepartal, silent uterine rupture occurred in the 4th pregnancy after enucleation of 5 myomas (max. size 6 cm without opening of the cavity) with one Caesarean section in the prior case history (1st postoperative pregnancy) and two subsequent miscarriages. In this case the uterine rupture occurred in the 4th pregnancy in the region of the old Caesarean scar but was first noticed in the primary Caesarean section in the 39th week. The uterus could be saved and the baby was vital (2740 g, Apgar 9/10/10). Bleeding prior to the 28th week of pregnancy occurred in eight patients, premature labour pains and postpartum atonias not requiring blood transfusions occurred to two cases each. There were no significant relationships between the occurrence of pregnancy complications and intraoperative opening of the cavity ( $p = 0.46$ ), total number of previous operations ( $p = 0.39$ ), number of myomas removed intraoperatively ( $p = 0.76$ ) or respectively diameter of the largest myoma ( $p = 0.18$ ).

### Discussion

▼ For the patients in our test population, on average, 5.0 myomas (1–46) were removed. In two women 14 myomas were removed, and in one patient each 15, 19, 22 and even 46 myomas were removed with sparing of the uterus. These women had explicitly requested that their uterus should not be removed. The resected myomas on average had a maximum size of 6.6 cm (SD ± 2.7; maximum size 19 cm). Other groups [32,36] have shown that the performance of a minilaparotomy is still justified in cases with extensive findings or, respectively, a so-called “potato sack uterus”. Among our patients a very high percentage (82.5%) had intramural myomas, that have already been demonstrated to possibly lead to sterility, infertility or serious complications of pregnancy [37,38]. Almost 50% of the intramural myomas had, on hysteroscopy, a recognisable link to the cavity. In the case of such a finding an opening of the cavity is always to be feared but occurred in merely 28 of our patients (17.5%).

The intraoperative loss of blood on average was 1.6 g/dL (SD ± 1.0) in our patient collective. We hold the opinion that the minilaparotomy under microsurgical conditions with consequent haemostasis and in spite of the in part pronounced changes of the uterus can be performed in a relatively low blood-loss manner and thus keeping the morbidity for the patient at a low level. Schüring et al. have shown that removal of on average 3.8 myomas of medium size (6.5 cm) by using microsurgical operation techniques leads to a significantly lower blood loss than a conven-

tional laparotomy (1.8 vs. 2.4 g/dL;  $p = 0.007$ ) [35]. Other studies have reported on blood losses of between 2.1 and 3.1 g/dL or, respectively, 150 to 840 mL also after laparoscopic interventions with high blood losses on removal of multiple myomas [39–41]. In some, albeit older studies, the transfusion rate amounted to between 4.2 and 52.4% [42,43]. For the interpretation of these results, it should be critically noted that on use of the decline in haemoglobin for quantification of the intraoperative blood loss a possible iatrogenic dilution effect must be taken into consideration.

The postoperative pregnancy rate of 60.3% is a very satisfactory result when the in part extensive pathologies are taken into consideration. Other studies show pregnancy or, respectively, birth rates of between 50 and 70% depending on the removal of myomas with a smaller average size and lower number [44–47]. Campo et al. reported a 60.9% pregnancy rate after enucleation of myomas with an average diameter of 5.8 cm independent of whether a laparoscopy or a laparotomy was performed [45]. The preoperative miscarriage rate of 57.1% was markedly reduced to 13.8% in this report; this is comparable with our results (reduction of the miscarriage rate from 75.6 to 22.5%). Other studies did not find any differences between myoma removal by laparoscopy, robot-assisted laparoscopy or laparotomy [29,45,48,49].

The rate of Caesarean sections in our patient collective was 71.6% of all deliveries. Higher rates after myoma enucleations have been described by other authors [46] and may be attributed to a higher desire of the parents for safety, especially after conception by IVF. In principle, vaginal delivery is possible after myoma removal; the risk for uterine rupture thereby corresponds ultimately to that for women who have had a prior Caesarean section. The risk for a uterine rupture after a Caesarean section sub partu amounts to between 1 and 17%, the success rate for vaginal delivery attempts after Caesarean section range from 50 to 90% (average 73%) [50,51].

In our patient collective only one uterine rupture occurred during delivery but this was not due to the performed myoma removal but rather to dehiscence of a suture after a Caesarean section for the first postoperative pregnancy; thus in this case a relationship with the myoma enucleation is most unlikely. The risk of an intra- or, respectively, a peripartal rupture of the uterus may be considered as low for the surgical technique described here in spite of the removal of larger or, respectively, multiple myomas. However, the danger of a rupture in spontaneous delivery attempts after enucleation of larger myomas must always be taken into consideration and the respective patient must be informed of this risk and monitored accordingly [52,53]. According to an analysis of larger collectives the incidence of pre- or intrapartal uterine ruptures after laparoscopic myoma removal amounts to 1–10% [46,54–58], after myoma enucleation by laparotomy, this potentially lethal event for mother and baby occurs in 0.2–5.3% of the cases [59,60]. Investigations on this topic have shown that the risk for uterus rupture is four times higher after single layer suturing of the uterus wall than after double layer suturing [61].

One limitation of our study concerns the preoperative administration of GnRH analogues in 46.3% to compensate for a bleeding anomaly. Nowadays this procedure is practically obsolete since in the meantime the highly effective ulipistal acetate (UPA) with its low side effect profile has become available.

In addition, it should be noticed that the performance of reconstructive operations to restore function in the small pelvis requires a long time in order to avoid collateral damage, e.g., to the

tubes and ovaries, due to surgery. The average operating time in our collective of 163 minutes (SD  $\pm 45.5$ ; 75–290 minutes) thus needs to be considered critically even when the rates of intra- and postoperative complications of 1.9% are low. For laparoscopic as well as robot-assisted laparoscopic interventions, however, operating times of between 57 up to 360 minutes have been reported [62–64].

On the whole, adhesions occur more frequently after laparotomies than after laparoscopic procedures [65]. Minimal blood loss operating techniques are thus of particular relevance to avoid postoperative adhesions. Therefore, for pronounced uterus myomatous, an access route via laparotomy with use of microsurgical instruments can be more effective and can reduce perioperative morbidity [35]. Palomba et al. demonstrated that there are no differences in blood loss and the probability of postoperative ileus between myoma removal by laparotomy with a small incision (“mini-laparotomy”) as compared to a laparoscopic intervention [66]. The occurrence of postoperative adhesions after myoma removal and the possible negative impact on fertility (e.g., peritubal adhesions with negative impact on the ovum trapping mechanism) has as yet not been sufficiently evaluated.

Laparoscopy reaches its limits in cases with excessively large and multiple myomas with protrusion into the uterine cavity and the danger of cavity opening [32,34,54,67]. In cases with larger myomas, e.g., of the anterior or posterior uterine wall, as well as softened nodes a laparoscopic procedure must not infrequently be converted into a laparotomy [33,36]. The size of the largest myoma of more than 5 cm has been identified as the most important factor for the intraoperative conversion to a laparotomy [36,62]. With regard to the choice of the surgical approach, there are as yet no guidelines from the Association of Scientific and Medical Societies [Arbeitsgemeinschaft der wissenschaftlichen medizinischen Fachgesellschaften (AWMF)].

We are convinced that, above all, the accurate reconstruction of the uterus wall is of decisive importance for the postoperative outcome and therefore in cases with pronounced myomatous findings the performance of a minilaparotomy can be beneficial. In cases with myomas near to the cavity, opening of the uterine cavity should be avoided whenever possible. Closure of the cavity with suturing of the wound margins in layers (edge-to-edge) is essential for the later fertility [5,48,66]. The physiological contractility function of the uterus should be retained by an exact adaptation of the myometrium layers. This cannot be realised satisfactorily by laparoscopy in cases with extensive findings or, respectively, myomas lying deep in the myometrium and reaching the uterine cavity. A further disadvantage of laparoscopy is the lack of a possibility to palpate the uterus manually intraoperatively in order to detect smaller nodes. This is supported by the high recurrence rates after laparoscopic myomectomies [30].

Prior to surgery, the patient must be fully informed about the known risks through to the need for transfusions or, respectively, the necessity for hysterectomy in cases of life-threatening bleeding and in cases of massive myoma pathologies, the need to abandon the organ-conserving procedure to protect the patient’s life. In the case of women with concomitant endometriosis and tubal function impairments, the corresponding reconstructions through to tubal anastomosis under the microscope can be carried out in the same minilaparotomy session [68], in the ideal case the natural ability to conceive can be restored in this manner.

## Conclusions for Practice

According to literature data, in cases of multinodular uterus myomatosus or, respectively, larger and especially intramural nodes protruding into the cavity, the minimally invasive laparoscopic technique reaches its limits with regard to organ preservation. By means of a minilaparotomy with use of microsurgical techniques with minimal blood loss it is mostly possible not only to achieve the complete removal of all palpable nodes but also an exact closure of the wound cavity. For most of the respective women this means retention of the ability to conceive and the possibility to carry a subsequent pregnancy through to delivery. The perioperative complications are minor due to the tissue sparing surgical technique and the risk for a postoperative rupture of the uterus in a later pregnancy or sub partu is minimal. As a limitation, it must be mentioned that our study was a retrospective observational study, thus a selection bias or confounding factors cannot be excluded. Accordingly a re-evaluation in a prospective control study to compare myoma enucleation per laparoscopy with that by a minilaparotomy would be valuable.

## Conflict of Interest

None.

## References

- 1 McCool WF, Durain D, Davis M. Overview of latest evidence on uterine fibroids. *Nurs Womens Health* 2014; 18: 314–332
- 2 Fernandez H. Uterine fibroids. *Rev Prat* 2014; 64: 540–544
- 3 Koivisto-Korander R, Martinsen JI, Weiderpass E et al. Incidence of uterine leiomyosarcoma and endometrial stromal sarcoma in Nordic countries: results from NORDCAN and NOCCA databases. *Maturitas* 2012; 72: 56–60
- 4 Parker WH, Fu YS, Berek JS. Uterine sarcoma in patients operated on for presumed leiomyoma and rapidly growing leiomyoma. *Obstet Gynecol* 1994; 83: 414–418
- 5 Luciano AA. Myomectomy. *Clin Obstet Gynecol* 2009; 52: 362–371
- 6 Pritts EA, Parker WH, Olive DL. Fibroids and infertility: an updated systematic review of the evidence. *Fertil Steril* 2009; 91: 1215–1223
- 7 Practice Committee of American Society for Reproductive Medicine in collaboration with Society of Reproductive Surgeons. Myomas and reproductive function. *Fertil Steril* 2008; 90 (5 Suppl.): 125–130
- 8 Horne AW, Critchley HO. The effect of uterine fibroids on embryo implantation. *Semin Reprod Med* 2007; 25: 483–489
- 9 Hart R, Khalaf Y, Yeong CT et al. A prospective controlled study of the effect of intramural uterine fibroids on the outcome of assisted conception. *Hum Reprod* 2001; 16: 2411–2417
- 10 Eldar-Geva T, Meagher S, Healy DL et al. Effect of intramural, subserosal, and submucosal uterine fibroids on the outcome of assisted reproductive technology treatment. *Fertil Steril* 1998; 70: 687–691
- 11 Shavell VI, Thakur M, Sawant A et al. Adverse obstetric outcomes associated with sonographically identified large uterine fibroids. *Fertil Steril* 2012; 97: 107–110
- 12 Lethaby A, Vollenhoven B, Sowter M. Pre-operative GnRH analogue therapy before hysterectomy or myomectomy for uterine fibroids. *Cochrane Database Syst Rev* 2001; 2: CD000547
- 13 Donnez J, Tatarchuk TF, Bouchard P et al. Ulipristal acetate versus placebo for fibroid treatment before surgery. *N Engl J Med* 2012; 366: 409–420
- 14 Donnez J, Tomaszewski J, Vazquez F et al. Ulipristal acetate versus leuprolide acetate for uterine fibroids. *N Engl J Med* 2012; 366: 421–432
- 15 David M, Kröncke T. Preoperative uterine artery embolisation for large uterine fibroids with subsequent uterus preservation – three case histories and review of the literature. *Geburtsh Frauenheilk* 2012; 72: 539–542
- 16 Walker WJ, Pelage JP. Uterine artery embolisation for symptomatic fibroids: clinical results in 400 women with imaging follow up. *BJOG* 2002; 109: 1262–1272
- 17 Jacob D, Rafii A. Embolization of uterine arteries for uterine fibroids: state-of-the-art. *Gynecol Obstet Fertil* 2004; 32: 927–936
- 18 Griffiths A, D'Angelo A, Amso N. Surgical treatment of fibroids for subfertility. *Cochrane Database Syst Rev* 2006; 3: CD003857
- 19 Pirard C, Squifflet J, Gilles A et al. Uterine necrosis and sepsis after vascular embolization and surgical ligation in a patient with postpartum hemorrhage. *Fertil Steril* 2002; 78: 412–413
- 20 David M, Kröncke T. Uterine fibroid embolisation – potential impact on fertility and pregnancy outcome. *Geburtsh Frauenheilk* 2013; 73: 247–255
- 21 Firouznia K, Ghanaati H, Jalali AH et al. Uterine artery embolization for treatment of symptomatic fibroids: a review of the evidence. *Iran Red Crescent Med J* 2013; 15: e16699
- 22 Beck A, David M, Kröncke T. Konsensuspapier Magnetresonanz-geführter fokussierter Ultraschall zur Myombehandlung. *Frauenarzt* 2013; 54: 442–444
- 23 Bohlmann MK, Hoellen F, Hunold P et al. High-intensity focused ultrasound ablation of uterine fibroids – potential impact on fertility and pregnancy outcome. *Geburtsh Frauenheilk* 2014; 74: 139–145
- 24 Rabinovici J, David M, Fukunishi H et al. Pregnancy outcome after magnetic resonance-guided focused ultrasound surgery (MRgFUS) for conservative treatment of uterine fibroids. *Fertil Steril* 2010; 93: 199–209
- 25 Gizzo S, Saccardi C, Patrelli TS et al. Magnetic resonance-guided focused ultrasound myomectomy: safety, efficacy, subsequent fertility and quality-of-life improvements, a systematic review. *Reprod Sci* 2014; 21: 465–476
- 26 Abdullah B, Subramaniam R, Omar S et al. Magnetic resonance-guided focused ultrasound surgery (MRgFUS) treatment for uterine fibroids. *Biomed Imaging Interv J* 2010; 6: e15
- 27 Kröncke T, David M. Konsensuspapier Uterusarterienembolisation zur Myombehandlung. *Frauenarzt* 2013; 54: 437–440
- 28 Donnez J, Jadoul P. What are the implications of myomas on fertility? A need for a debate? *Hum Reprod* 2002; 17: 1424–1430
- 29 Mais V, Ajossa S, Guerriero S et al. Laparoscopic versus abdominal myomectomy: a prospective, randomized trial to evaluate benefits in early outcome. *Am J Obstet Gynecol* 1996; 174: 654–658
- 30 Jin C, Hu Y, Chen XC et al. Laparoscopic versus open myomectomy—a meta-analysis of randomized controlled trials. *Eur J Obstet Gynecol Reprod Biol* 2009; 145: 14–21
- 31 Hurst BS, Matthews ML, Marshburn PB. Laparoscopic myomectomy for symptomatic uterine myomas. *Fertil Steril* 2005; 83: 1–23
- 32 Mukhopadhyaya N, De Silva C, Manyonda IT. Conventional myomectomy. *Best Pract Res Clin Obstet Gynaecol* 2008; 22: 677–705
- 33 Al-Talib A. Factors contributing to failure of laparoscopic myomectomy. *Surg Technol Int* 2013; 23: 149–151
- 34 Wen KC, Sung PL, Lee WL et al. Myomectomy for uterine myomas through ultramini-laparotomy. *J Obstet Gynaecol Res* 2011; 37: 383–392
- 35 Schüring AN, Garcia-Rocha GJ, Schlosser HW et al. Perioperative complications in conventional and microsurgical abdominal myomectomy. *Arch Gynecol Obstet* 2011; 284: 137–144
- 36 Dubuisson JB, Fauconnier A, Fourchette V et al. Laparoscopic myomectomy: predicting the risk of conversion to an open procedure. *Hum Reprod* 2001; 16: 1726–1731
- 37 Li TC, Mortimer R, Cooke ID. Myomectomy: a retrospective study to examine reproductive performance before and after surgery. *Hum Reprod* 1999; 14: 1735–1740
- 38 Klatsky PC, Tran ND, Caughey AB et al. Fibroids and reproductive outcomes: a systematic literature review from conception to delivery. *Am J Obstet Gynecol* 2008; 198: 357–366
- 39 Cagnacci A, Pirillo D, Malmusi S et al. Early outcome of myomectomy by laparotomy, minilaparotomy and laparoscopically assisted minilaparotomy. A randomized prospective study. *Hum Reprod* 2003; 18: 2590–2594
- 40 Kunde K, Cortes E, Seed P et al. Evaluation of perioperative morbidity associated with single and multiple myomectomy. *J Obstet Gynaecol* 2009; 29: 737–741
- 41 Vercellini P, Trespidi L, Zaina B et al. Gonadotropin-releasing hormone agonist treatment before abdominal myomectomy: a controlled trial. *Fertil Steril* 2003; 79: 1390–1395
- 42 Golan A, Bukowsky I, Pansky M et al. Pre-operative gonadotrophin-releasing hormone agonist treatment in surgery for uterine leiomyomata. *Hum Reprod* 1993; 8: 450–452

- 43 Stringer NH, Walker JC, Meyer PM. Comparison of 49 laparoscopic myomectomies with 49 open myomectomies. *J Am Assoc Gynecol Laparosc* 1997; 4: 457–464
- 44 Lönnfors C, Persson J. Pregnancy following robot-assisted laparoscopic myomectomy in women with deep intramural myomas. *Acta Obstet Gynecol Scand* 2011; 90: 972–977
- 45 Campo S, Campo V, Gambadauro P. Reproductive outcome before and after laparoscopic or abdominal myomectomy for subserous or intramural myomas. *Eur J Obstet Gynecol Reprod Biol* 2003; 110: 215–219
- 46 Bernardi TS, Radosa MP, Weisheit A et al. Laparoscopic myomectomy: a 6-year follow-up single-center cohort analysis of fertility and obstetric outcome measures. *Arch Gynecol Obstet* 2014; 290: 87–91
- 47 Bulletti C, De Ziegler D, Polli V et al. The role of leiomyomas in infertility. *J Am Assoc Gynecol Laparosc* 1999; 6: 441–445
- 48 Li MH, Leng JH, Shi JH et al. Comparison of postoperative residue, recurrence and pregnancy outcome between laparoscopic and transabdominal myomectomy. *Zhonghua Fu Chan Ke Za Zhi* 2011; 46: 669–673
- 49 Fanfani F, Fagotti A, Bifulco G et al. A prospective study of laparoscopy versus minilaparotomy in the treatment of uterine myomas. *J Minim Invasive Gynecol* 2005; 12: 470–474
- 50 Dannecker C, Hubener C, Toth B et al. Asymptomatic uterine rupture after two spontaneous vaginal deliveries following prior cesarean section. *Gynaekol Geburtshilfliche Rundsch* 2003; 43: 245–249
- 51 Deutsche Gesellschaft für Gynäkologie und Geburtshilfe (DGGG); Board für Pränatal- und Geburtsmedizin; Arbeitsgemeinschaft Materno-fetale-Medizin; Deutsche Gesellschaft für Perinatale Medizin (DPGM). Schwangerenbetreuung und Geburtseinleitung bei Zustand nach Kaiserschnitt. Deutsche Gesellschaft für Gynäkologie und Geburtshilfe (DGGG), Board für Pränatal- und Geburtsmedizin, Arbeitsgemeinschaft Materno-fetale-Medizin, Deutsche Gesellschaft für Perinatale Medizin (DPGM). AWMF 015/021 (S1) 2010
- 52 Society of Obstetricians and Gynaecologists of Canada. SOGC clinical practice guidelines. Guidelines for vaginal birth after previous cesarean birth. Number 155. *Int J Gynaecol Obstet* 2005; 89: 319–331
- 53 Rath W, Surbek D. Geburtseinleitung bei Zustand nach Sectio. *Geburtsh Frauenheilk* 2006; 66: 1143–1149
- 54 Dillon A; for the National Institute for Health and Clinical Excellence. Laparoscopic laser myomectomy. Issued: November 2003. NICE interventional procedure guidance 23. Online: [www.nice.org/ih/ipg23](http://www.nice.org/ih/ipg23); Stand: 2003
- 55 Hurst BS, Matthews ML, Marshburn PB. Laparoscopic myomectomy for symptomatic uterine myomas. *Fertil Steril* 2005; 83: 1–23
- 56 Dubuisson JB, Fauconnier A, Deffarges JV et al. Pregnancy outcome and deliveries following laparoscopic myomectomy. *Hum Reprod* 2000; 15: 869–873
- 57 Bernardi TS, Radosa MP, Weisheit A et al. Laparoscopic myomectomy: a 6-year follow-up single-center cohort analysis of fertility and obstetric outcome measures. *Arch Gynecol Obstet* 2014; 290: 87–91
- 58 Kim MS, Uhm YK, Kim JY et al. Obstetric outcomes after uterine myomectomy: Laparoscopic versus laparotomic approach. *Obstet Gynecol Sci* 2013; 56: 375–381
- 59 Obed JY, Omigbodun A. Rupture of the uterus in patients with previous myomectomy and primary caesarean section scars: a comparison. *J Obstet Gynaecol* 1996; 16: 16–21
- 60 Roopnarinesingh S, Ramsewak S. Rupture of the uterus in patients with previous myomectomy. *J Obstet Gynaecol* 1985; 6: 32–34
- 61 Bujold E, Bujold C, Hamilton EF et al. The impact of a single-layer or double-layer closure on uterine rupture. *Am J Obstet Gynecol* 2002; 186: 1326–1330
- 62 Malzoni M, Sizzi O, Rossetti A et al. Laparoscopic myomectomy: a report of 982 procedures. *Surg Technol Int* 2006; 15: 123–129
- 63 Kim JY, Kim KH, Choi JS et al. A prospective matched case-control study of laparoendoscopic single-site vs. conventional laparoscopic myomectomy. *J Minim Invasive Gynecol* 2014; 21: 1036–1040
- 64 Ardovino M, Ardovino I, Castaldi MA et al. Minilaparoscopic myomectomy: a mini-invasive technical variant. *J Laparoendosc Adv Surg Tech A* 2013; 23: 871–875
- 65 Dubuisson J, Botchorishvili R, Perrette S et al. Incidence of intraabdominal adhesions in a continuous series of 1000 laparoscopic procedures. *Obstet Gynecol* 2010; 203: 111.e1–111.e3
- 66 Palomba S, Zupi E, Falbo A et al. A multicenter randomized, controlled study comparing laparoscopic versus minilaparotomic myomectomy: reproductive outcomes. *Fertil Steril* 2007; 88: 933–941
- 67 Istre O. Management of symptomatic fibroids: conservative surgical treatment modalities other than abdominal or laparoscopic myomectomy. *Best Pract Res Clin Obstet Gynaecol* 2008; 22: 735–747
- 68 Schippert C, Garcia-Rocha GJ, Schaff C et al. Rekonstruktive, organerhaltende Mikrochirurgie bei Störungen der Tubenfunktion: nach wie vor eine Alternative zur In-vitro-Fertilisation (IVF). *Geburtsh Frauenheilk* 2008; 68: 998–1007

Auf Seite 60 im 1. Absatz ist ein Übersetzungsfehler korrigiert worden.