

# Anatomical Reattachment of the TFCC to the Ulnar Fovea Using an ECU Half-Slip

Toshiyasu Nakamura, MD, PhD<sup>1</sup>

<sup>1</sup> Clinical Research Center, International University of Health and Welfare, Department of Orthopaedic Surgery, Sanno Hospital, Tokyo, Japan

Address for correspondence Toshiyasu Nakamura, MD, PhD, Clinical Research Center, International University of Health and Welfare, Department of Orthopaedic Surgery, Sanno Hospital, 8-10-16 Akasaka, Minato-ku, Tokyo, 107-0052, Japan (e-mail: toshiyasu@ae.em-net.ne.jp).

J Wrist Surg 2015;4:15–21.

## Abstract

**Background** Since 1998, we treated 25 wrists with foveal detachment of the triangular fibrocartilage complex (TFCC) by our original reattachment technique using a half-slip of the extensor carpi ulnaris (ECU) tendon with a very small titanium interference screw. We examine the clinical outcome of this procedure with a minimum of 2 years follow-up.

**Patients and Methods** There were 25 wrists of 24 patients (16 right, 7 left, 1 bilateral, mean age, 34.8 years) with a minimum follow-up of 2 years (range 2–7 years, average 3.1). There was a neutral ulnar variance in 19 wrists and positive in 6. In the positive-variance wrists, an ulnar shortening was performed to prevent ulnar abutment before the reattachment. The diagnosis of a TFCC injury was done by arthrogram, magnetic resonance imaging (MRI), and distal radioulnar (DRUJ) arthroscopy. The clinical outcome was evaluated using our original DRUJ evaluating system.

**Technique** A distally based ECU half-slip was harvested, introduced into the TFCC, sutured to the remnant of the TFCC, and pulled out through a 2.5-mm bone tunnel at the center of the fovea. The ECU half-slip was subsequently anchored to the ulnar fovea with a small titanium interference screw.

**Results** At the final follow-up, 21 wrists had no pain, 3 wrists indicated mild pain, and 1 wrist severe pain. One patient had a loss of supination by 30 degrees. The DRUJ was stable in 22 wrists, moderately unstable in 2 wrists, and severely unstable in 1 wrist. There were 21 excellent, 2 good, 1 fair, and 1 poor results.

**Conclusions** Anatomic reattachment of the TFCC to the ulnar fovea using an ECU half-slip tendon is a promising procedure. This technique is effective for severe DRUJ instability due to chronic foveal avulsion of the TFCC.

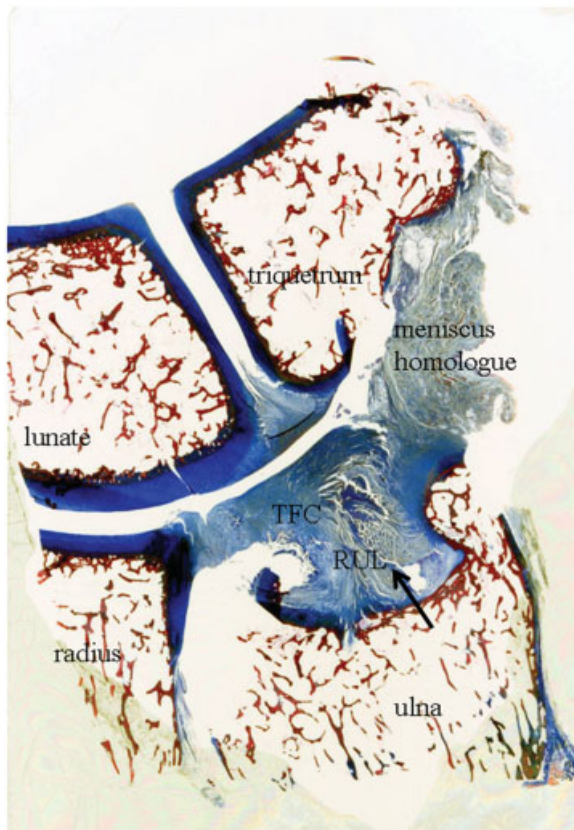
## Keywords

- ▶ reattachment
- ▶ triangular fibrocartilage complex
- ▶ extensor carpi ulnaris
- ▶ foveal avulsion
- ▶ interference screw

The triangular fibrocartilage complex (TFCC) is a fibrocartilage-ligament complex in the ulnar side of the wrist, which consists of the triangular fibrocartilage (TFC; also termed the articular disc or disc proper), the meniscus homologue, the radioulnar ligament (RUL), the ulnolunate ligament, the ulnotriquetral ligament, the ECU sheath floor, and the ulnar joint capsule.<sup>1,2</sup> The TFCC stabilizes the distal radioulnar joint (DRUJ) and ulnocarpal joint, distributes load between the ulna and ulnar carpus, and allows multidirectional motion of the wrist, such as flexion-extension, radial and ulnar deviation, as well as forearm rotation.<sup>1,2</sup>

The RUL, which is the proximal component of the TFCC, is the primary stabilizer of the DRUJ.<sup>3</sup> In histology, the fibers of the RUL arise nearly vertically from the fovea of the ulna and base of the ulnar styloid (▶ **Fig. 1**).<sup>4,5</sup> It then curls radially and separates into palmar and dorsal portions, which pass through the proximal portion of the TFCC, and finally attaches to the radiodistal edge of the sigmoid notch. This unique origin of the fovea-attaching fibers of the RUL allows easy twisting during pronation-supination, which allows nearly 180° of forearm rotation.

Patients with an injury to the TFCC present with ulnar-side wrist pain, DRUJ instability, and/or loss of pronation-supination

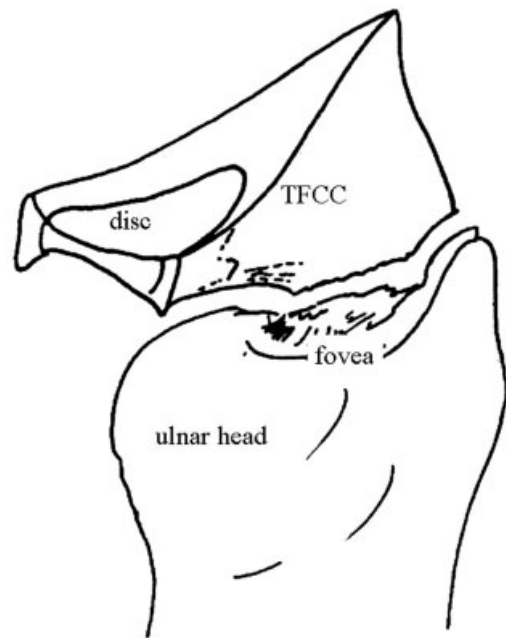


**Fig. 1** Coronal histology of the TFCC demonstrates a nearly vertical origin of the RUL from the fovea of the ulna (arrow).

range. Recent biomechanical and clinical studies have shown that an avulsion of the RUL at the ulnar fovea may result in severe DRUJ instability.<sup>6-9</sup> Foveal avulsion of the TFCC was not described in the Palmer classification,<sup>10</sup> Atzei et al later subclassified Palmer's 1B (peripheral TFCC tear) into a distal tear, a proximal tear (i.e., foveal avulsion) and a combined tear.<sup>11</sup>

Surgical treatment of a foveal avulsion of the RUL is controversial. An ulnar shortening osteotomy (USO) may stabilize the DRUJ because the TFCC is tightened up by the pulling effect from the shortened ulna.<sup>9</sup> However, USO is not indicated in patients with ulnar neutral or ulnar negative variance because of the risk of incongruity between the ulnar head and the sigmoid notch as well as the increased joint pressure after a shortening.<sup>12</sup> When the TFCC is completely avulsed from the fovea (►Fig. 2), an ulnar shortening no longer restabilizes the DRUJ.<sup>13</sup> Arthroscopic<sup>7,14,15</sup> or open<sup>6,9,16,17</sup> repair techniques for foveal avulsions have been recently described. If the foveal avulsion of the TFCC is chronic (> 6 months), however, it is difficult to repair either arthroscopically or in an open fashion.<sup>7</sup> Reconstructive techniques have included reconstruction of the RUL using the flexor carpi ulnaris tendon,<sup>18</sup> palmaris longus tendon free graft<sup>19-22</sup> and Dacron artificial ligament.<sup>23</sup>

Since 1998, we have treated 25 wrists with a foveal detachment of the TFCC by our original reattachment technique using a distally based half-slip of the extensor carpi ulnaris (ECU) tendon that was anchored with an interference screw. This was a simple reattachment technique of the TFCC



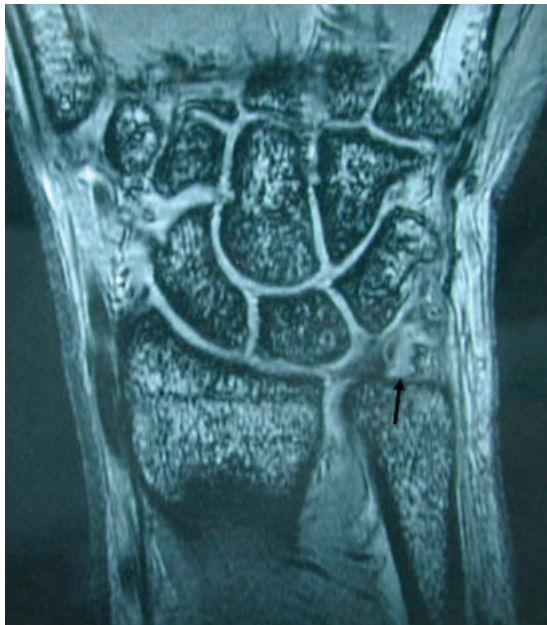**Fig. 2** Illustration of foveal avulsion of the triangular fibrocartilage complex (TFCC).

to the center of the ulnar fovea, which is where the rotational axis of the forearm passes. We retrospectively examined the clinical outcome of this procedure.

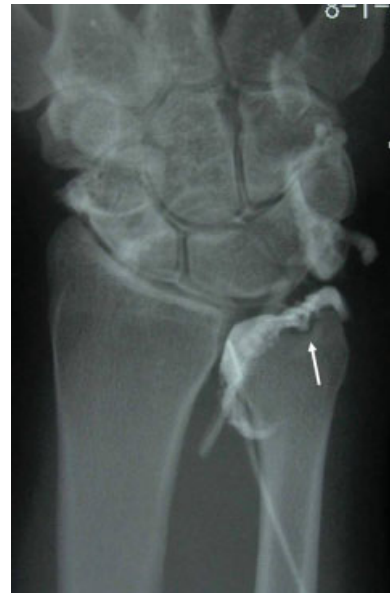## Patients and Methods

Twenty-four patients underwent our original reattachment technique for chronic foveal detachment of the TFCC with severe DRUJ instability with a minimum of 2 years follow up. There were 9 male and 15 female patients. Sixteen involved the right wrist and seven involved the left wrist, with one patient having bilateral involvement. The mean age was 34.8 years (range 13-64). The average follow-up was 3.1 years (range 2-7 years). The mechanism of TFCC avulsion was a fall in 15 instances, sports in 4, traffic accident in 2, and unknown in 4. There was a neutral ulnar variance in 19 patients and a positive variance in 6. There were no negative-ulnar-variance wrists. In the positive-variance wrists, an ulnar shortening was performed to prevent ulnar abutment before the reattachment.

The diagnosis of a foveal detachment was made with either an arthrogram or magnetic resonance imaging (MRI). MRI findings included a high signal intensity at the fovea (►Fig. 3). Dye leakage into the fovea was indicative of a foveal detachment on arthrogram (►Fig. 4). We confirmed that there was a TFCC foveal avulsion through DRUJ arthroscopy. The arthroscopic findings in these cases included a lack of tension of the RUL upon probing with a 23G needle and a complete absence of the RUL, which was often replaced by scar. The clinical results were evaluated preoperatively and at final follow up using our DRUJ evaluating system,<sup>7</sup> pain levels, the range of pronosupination, and DRUJ stability (►Table 1). Pre- and postoperative visual analog scale (VAS) pain measurements and grip power were also evaluated.



**Fig. 3** MRI of the foveal avulsion demonstrates a high-signal-intensity area at the fovea.



**Fig. 4** Arthrogram of the foveal avulsion. The dye leakage into the fovea can be seen (white arrow).

**Indication**

We reserve this reconstruction technique for patients with severe DRUJ instability due to a chronic disruption of the RUL (at least 6 months after the initial injury) (→ Fig. 2).

Radiocarpal arthroscopy can demonstrate only a loss of the trampoline effect as well as loss of peripheral tension on the disc. DRUJ arthroscopy may often demonstrate a complete rupture of the ulnar origin of the TFCC at the fovea (→ Fig. 5).

The technique described is suitable for wrists with a neutral or negative ulnar variance. In wrists with a positive variance, an ulnar shortening is performed to restore an ulnar neutral variance. If the DRUJ is stable after the ulnar shortening, further surgery is not needed. A prerequisite for this procedure is a

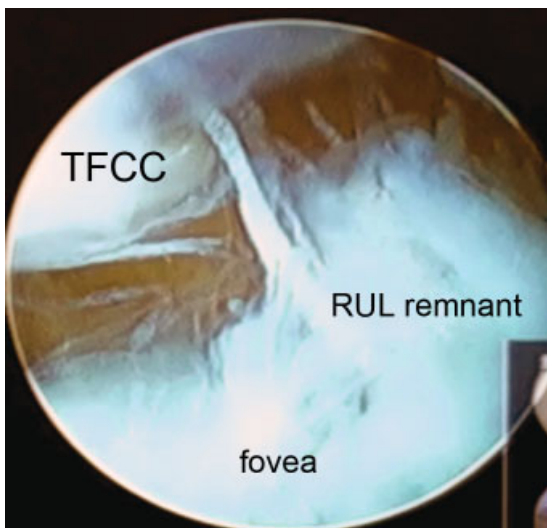
reconstructable peripheral rim of the TFCC that will not tear following the insertion of a tendon graft.

**Contraindication**

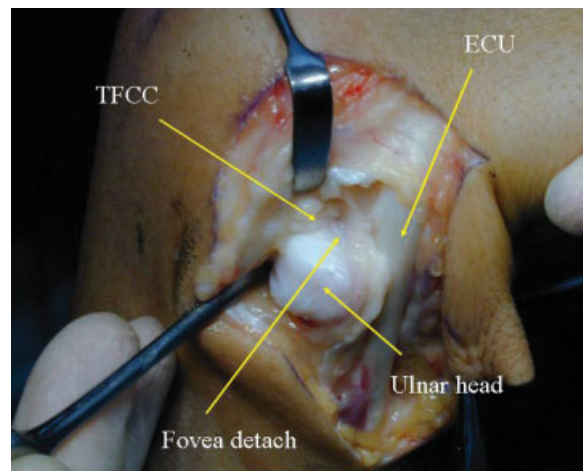
Complete destruction of the TFCC, such as in patients with rheumatoid arthritis, is a contraindication. If the ulnar edge of the TFCC is frayed or in poor condition, other reconstructive techniques should be used. Another contraindication is severe degeneration or osteoarthritic change of the DRUJ, which should be treated by other means.

**Surgical Technique**

A dorsal c-shaped skin incision is used with extension of the 4–5 or 6R portal for radiocarpal arthroscopy and/or DRUJ



**Fig. 5** DRUJ arthroscopy. The RUL is avulsed at the fovea.



**Fig. 6** Intraoperative photograph. The ECU is retracted ulnarly. The RUL fibers are absent.

**Table 1** DRUJ evaluation system

Category	Levels	Points
Pain	Severe (always painful)	0
	Moderate (pain in motion or twisting)	1
	Mild (occasionally painful)	2
	No pain	4
Range of pronation/supination	Less than 100°	0
	100–119°	1
	120–139°	2
	140–159°	3
	More than 159°	4
DRUJ stability	++ (no end point in any direction)	0
	+ (at least one end point either in dorsal or palmar)	1
	± (looser than intact contralateral side)	2
	– (stable DRUJ)	4

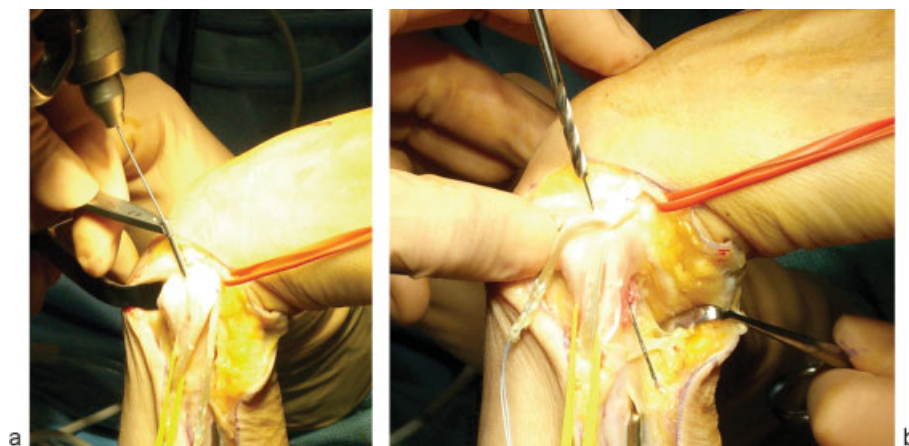
Points of each category were added and evaluated as excellent (11–12 points), good (9–10 points), fair (6–8 points), or poor (0–5 points).

portal for DRUJ arthroscopy. The hand is suspended in finger traps. After the skin flap is elevated, the superficial sensory branches of the ulnar nerve are indentified and preserved. A 3-cm longitudinal incision of the ECU sheath at the DRUJ is made, and the ECU is retracted. After the radial ridge of the ECU subsheath is longitudinally cut, the dorsal capsule of the DRUJ appears just beneath the ECU subsheath. Elevating the dorsal DRUJ capsule from the ulnar head using a knife exposes the DRUJ (►Fig. 6). A small ring elevator is inserted in the DRUJ to dislocate the ulnar head. If there is a detachment or horizontal tear of the TFCC, the ulnar head can be easily dislocated.

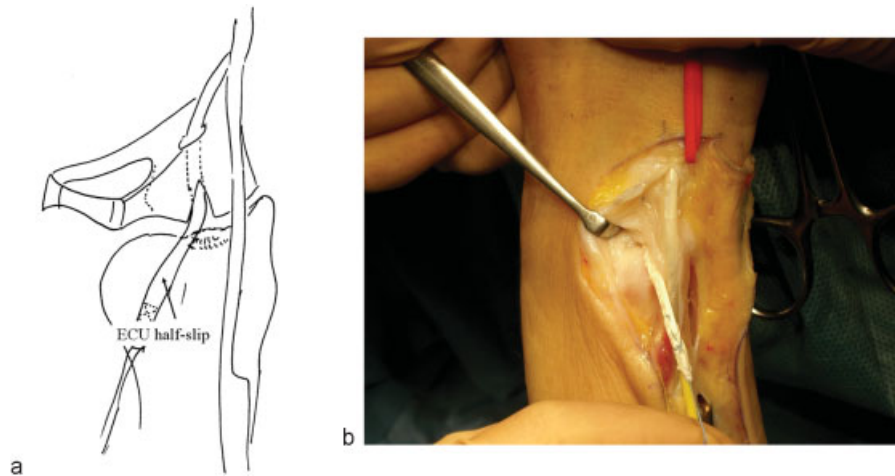
A foveal tear of the RUL is clearly visible after an additional small (5-mm longitudinal) incision is made at the foveal origin of the RUL. Because the direction of the fovea-attaching fibers of the RUL is nearly vertical, a small longitudinal incision does not damage the fibers. The condition of the fibers of the RUL is assessed by pulling the distal remnant with forceps to determine whether it can be sutured.<sup>6,7</sup> If

there is severe degeneration or damage at the RUL, or the fibers are weak, the ligament will be inelastic and easily disrupted. Reattachment of the TFCC using an ECU half-slip is suitable in such cases.

The fovea of the ulna is débrided and scar tissue is removed until bleeding bone is visible. A bone tunnel is made with a 2.5-mm diameter drill from the center of the fovea to the ulnar neck more proximally (►Fig. 7a,b). The position of the bone tunnel at the fovea is made as close to the center of the fovea as possible, which is an isometric point during forearm rotation. A distally based ECU half-slip tendon is then harvested. A 5-mm horizontal incision is made in the floor of the ECU sheath at the ulnocarpal joint level. A curved mosquito forceps is inserted into the peripheral unstable edge of the TFCC and then passed through the horizontal ECU sheath incision. The half-slip tendon is then passed through the edge of the TFCC and sutured to it (►Fig. 8a,b). The ECU half-slip is then passed through the foveal bone tunnel to exit the medial cortex of the ulna using a 4–0 nylon looped stitch. A small



**Fig. 7a,b** (a) A 0.9 mm guide wire is inserted to the center of the fovea. (b) A bone tunnel is created using a 2.5-mm cannulated drill.



**Fig. 8a,b** Illustration (a) and intraoperative view (b) of first step of reattachment of the TFCC. The distally based half-slip of the ECU is introduced into the ulnar edge of the TFCC to the ulnar fovea.

bone peg is then harvested from the cortex of the ulna or radius and is inserted to the bone tunnel (►Fig. 9a,b). The ECU half-slip is then anchored to the ulnar fovea with a small titanium interference screw (►Fig. 10). The capsule and ECU sheath are closed with mattress sutures.

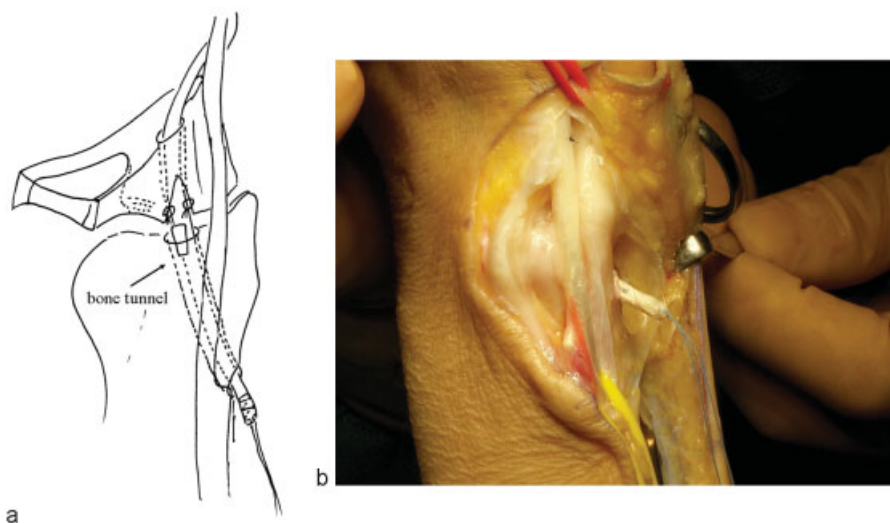
When the TFCC is reattached successfully (►Fig. 11), there should be no DRUJ instability upon testing using a DRUJ ballottement test. Pronation-supination range is usually full, since the TFCC is anchored to the center of the fovea, where the center of forearm rotation passes. After reattaching the TFCC, we prefer to evaluate the condition of the TFC arthroscopically. Tension of the central area of the TFC is increased, which restores the trampoline effect.

The patient is immobilized in a long-arm cast for 2 weeks followed by 3 weeks of a short-arm cast. After removal of the cast at 5 weeks after the surgery, active ROM exercise begins. Seven weeks after the operation, passive ROM exercise by an occupational therapist may be needed, if there is a loss of

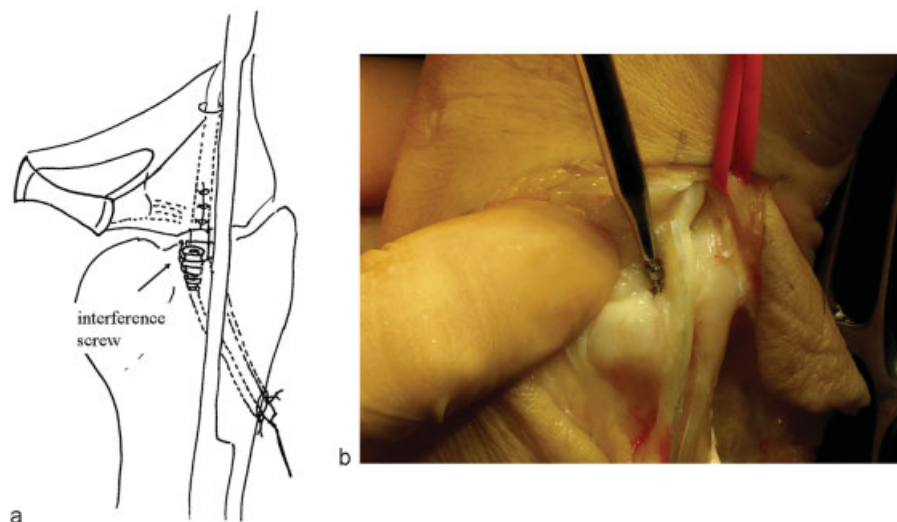
pronation-supination range. Usually, at 8 to 9 weeks after the operation, full pronation-supination range is achieved; then arm curl exercise begins with up to 3 kg weight. Three to 6 months after the operation, the weight may be increased to 5–10 kg. The patient may be back to preinjury sports activity level 9 months after the surgery.

## Results

Preoperatively, 2 patients had mild occasional pain, 16 patients had moderate (in motion or twisting) pain, and 6 patients (7 wrists) had severe consistent pain. Fifteen patients complained of DRUJ laxity. There was no loss of pronosupination range or wrist motion. On physical examination, all of the patients had a positive ulnocarpal stress test and severe DRUJ instability without any endpoint, which corresponded to complete avulsion of the fovea-attaching fibers of the RUL.



**Fig. 9a,b** The avulsed TFCC is sutured to the ECU half-slip at the fovea. The half-slip of the ECU is passed through a 2.5-mm bone tunnel to the proximal ulnar cortex ([a] illustration; [b] intraoperative findings). A small bone peg is already inserted to the bone tunnel at the fovea before an interference screw is inserted.



**Fig. 10a,b** (a) Schematic of the final step of the reattachment of the TFCC. (b) A small interference screw is inserted into the fovea to anchor the ECU strip.

An arthrogram demonstrated a complete avulsion of the TFCC at the fovea in 21 wrists, while there was no dye leakage in 4. An MRI demonstrated a high signal intensity at the ulnar fovea area in all 25 wrists. DRUJ arthroscopy<sup>24</sup> was performed in 20 wrists, which included an avulsion of the RUL in 13, scar tissue without any RUL fiber tension in 4, while no visualization of the fovea was possible due to severe scar tissue formation in 3. Open exploration revealed a complete detachment of the RUL in all wrists.

At final follow-up of average 3.1 years (range, 2–7 years), 20 patients (21 wrists) had no pain, 3 had mild pain at rest (occasionally painful), and 1 patient had severe consistent pain. VAS was decreased from average 7.9 to 1.2. Twenty-four wrists indicated full pronosupination and full wrist flexion-extension, while one patient had a 30 degree loss of supination. The DRUJ was stable in 22 wrists, moderately unstable (at least one end point either in dorsal or palmar) in 2 wrists, and severely unstable (no end point in any direction) in 1 patient. There were 21 excellent, 2 good, 1 fair, and 1 poor

results, with our original DRUJ evaluating system (► **Table 1**) for DRUJ disorders. Grip power was recovered to an average of 91% (83–104%) compared with the intact side.

## Discussion

Considering the three-dimensional structure of the TFCC and of the nearly vertical orientation of the fovea attaching fibers of the RUL,<sup>3–5</sup> it is our opinion that the repaired or reconstructed RUL must be reattached to the center of the fovea of the ulna, which is the isometric point of pronosupination, to prevent any loss of forearm rotation while stabilizing the DRUJ. The direction of the reattached /reconstructed fibers should be along the original fiber direction as much as possible. In chronic situations the peripheral rim of the TFCC can be reattached to the fovea with this technique, provided that the tissue is not too damaged or fragile to hold sutures.<sup>6</sup>

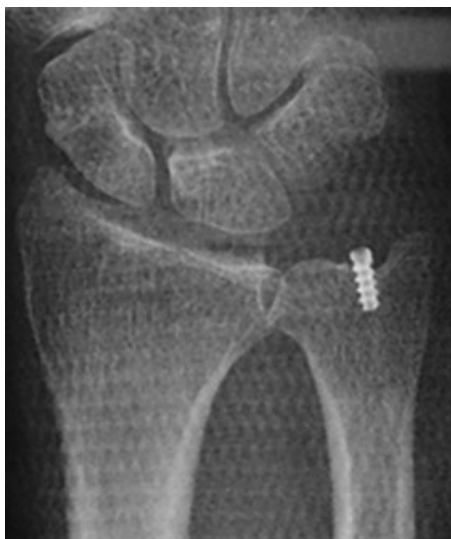In this paper we describe a technique for reconstruction of the avulsed RUL to the ulnar fovea using a ECU half-slip tendon. This technique reproduces the vertical origin of the TFCC at the fovea. Other tendon graft techniques require two bony tunnels (at the sigmoid notch and ulnar head), whereas our technique is performed through a single ulnar tunnel and is easier. The clinical outcomes of this technique have been encouraging at a midterm follow up.

## Conflict of Interest

None

## References

- 1 Palmer AK, Werner FW. The triangular fibrocartilage complex of the wrist—anatomy and function. *J Hand Surg Am* 1981;6(2):153–162
- 2 Nakamura T, Yabe Y, Horiuchi Y. Functional anatomy of the triangular fibrocartilage complex. *J Hand Surg [Br]* 1996;21(5): 581–586
- 3 Nakamura T, Makita A. The proximal ligamentous component of the triangular fibrocartilage complex. *J Hand Surg [Br]* 2000;25(5): 479–486



**Fig. 11** Immediate postoperative radiograph of the reconstruction. Note the interference screw in the center of the fovea.

- 4 Nakamura T, Yabe Y. Histological anatomy of the triangular fibrocartilage complex of the human wrist. *Ann Anat* 2000; 182(6):567–572
- 5 Nakamura T, Takayama S, Horiuchi Y, Yabe Y. Origins and insertions of the triangular fibrocartilage complex: a histological study. *J Hand Surg [Br]* 2001;26(5):446–454
- 6 Nakamura T, Nakao Y, Ikegami H, Sato K, Takayama S. Open repair of the ulnar disruption of the triangular fibrocartilage complex with double three-dimensional mattress suturing technique. *Tech Hand Up Extrem Surg* 2004;8(2):116–123
- 7 Nakamura T, Sato K, Okazaki M, Toyama Y, Ikegami H. Repair of foveal detachment of the triangular fibrocartilage complex: open and arthroscopic transosseous techniques. *Hand Clin* 2011;27(3): 281–290
- 8 Haugstvedt JR, Berger RA, Nakamura T, Neale P, Berglund L, An KN. Relative contributions of the ulnar attachments of the triangular fibrocartilage complex to the dynamic stability of the distal radioulnar joint. *J Hand Surg Am* 2006;31(3): 445–451
- 9 Moritomo H, Masatomi T, Murase T, Miyake J, Okada K, Yoshikawa H. Open repair of foveal avulsion of the triangular fibrocartilage complex and comparison by types of injury mechanism. *J Hand Surg Am* 2010;35(12):1955–1963
- 10 Palmer AK. Triangular fibrocartilage complex lesions: a classification. *J Hand Surg Am* 1989;14(4):594–606
- 11 Atzei A. New trends in arthroscopic management of type 1-B TFCC injuries with DRUJ instability. *J Hand Surg Eur Vol* 2009;34(5): 582–591
- 12 Nishiwaki M, Nakamura T, Nagura T, et al. Ulnar shortening effect on the distal radioulnar joint pressure: a biomechanical study. *J Hand Surg [Br]* 2007;33A:198–205
- 13 Nishiwaki M, Nakamura T, Nakao Y, Nagura T, Toyama Y. Ulnar shortening effect on distal radioulnar joint stability: a biomechanical study. *J Hand Surg Am* 2005;30(4):719–726
- 14 Iwasaki N, Minami A. Arthroscopically assisted reattachment of avulsed triangular fibrocartilage complex to the fovea of the ulnar head. *J Hand Surg Am* 2009;34(7):1323–1326
- 15 Atzei A, Rizzo A, Luchetti R, Fairplay T. Arthroscopic foveal repair of triangular fibrocartilage complex peripheral lesion with distal radioulnar joint instability. *Tech Hand Up Extrem Surg* 2008; 12(4):226–235
- 16 Hermansdorfer JD, Kleinman WB. Management of chronic peripheral tears of the triangular fibrocartilage complex. *J Hand Surg Am* 1991;16(2):340–346
- 17 Sennwald GR, Lauterburg M, Zdravkovic V. A new technique of reattachment after traumatic avulsion of the TFCC at its ulnar insertion. *J Hand Surg [Br]* 1995;20(2):178–184
- 18 Hui FC, Linscheid RL. Ulnotriquetral augmentation tenodesis: a reconstructive procedure for dorsal subluxation of the distal radioulnar joint. *J Hand Surg Am* 1982;7(3):230–236
- 19 Sanders RA, Hawkins B. Reconstruction of the distal radioulnar joint for chronic volar dislocation. A case report. *Orthopedics* 1989;12(11):1473–1476
- 20 Scheker LR, Belliappa PP, Acosta R, German DS. Reconstruction of the dorsal ligament of the triangular fibrocartilage complex. *J Hand Surg [Br]* 1994;19(3):310–318
- 21 Shih JT, Hou YT, Lee HM, Tan CM. Chronic triangular fibrocartilage complex tears with distal radioulnar joint instability: A new method of triangular fibrocartilage complex reconstruction. *J Orthop Surg (Hong Kong)* 2000;8(1):1–8
- 22 Adams BD, Berger RA. An anatomic reconstruction of the distal radioulnar ligaments for posttraumatic distal radioulnar joint instability. *J Hand Surg Am* 2002;27(2):243–251
- 23 Hunter JM, Kirkpatrick WH. Dacron stabilization of the distal ulna. *Hand Clin* 1991;7(2):365–371
- 24 Nakamura T, Matsumura N, Iwamoto T, Sato K, Toyama Y. Arthroscopy of the distal radioulnar joint. *Handchir Mikrochir Plast Chir* 2014;46(5):295–299