

Harlequin Color Change: Neonatal Case Series and Brief Literature Review

Enrico Valerio, MD¹ Alessia Barlotta, MD¹ Eleonora Lorenzon, MD¹ Livio Antonazzo, MD¹
Mario Cutrone, MD²

¹ Department of Woman and Child Health, Medical School, University of Padua, Padova, Italy

² Department of Pediatrics, Ospedale Dell'Angelo, Mestre, Venice, Italy

Address for correspondence Enrico Valerio, MD, Department of Woman and Child Health, Medical School, University of Padua, Via Giustiniani, 3, 35128 Padova, Italy
(e-mail: enrico.valerio.md@gmail.com; enrico.va@inwind.it).

Am J Perinatol Rep 2015;5:e73–e76.

Abstract

First clinical report of Harlequin color change (HCC) phenomenon came in 1952 from Neligan and Strang. Since then, HCC has been described in a fairly broad number of clinical reports involving neonates, infants, children, and adult patients. We here present a small case series of HCC occurring in neonates, pointing out three of the different possible presentations (hemifacial, patchy scattered across the whole body, and hemiscrotal) of this phenomenon. A brief discussion and literature review encompassing epidemiology, clinical features, physiopathology, associated conditions, and differential diagnoses of HCC is then presented. In most cases, HCC represents a benign, idiopathic, and rapidly autoregressive phenomenon, with no need for treatment. Some drugs (especially anesthetics and prostaglandin E) are thought to enhance HCC expression through their influence on the capillary tone in the peripheral vascular bed; this effect is anyway promptly reversible with drug withdrawal. Only in rare circumstances, HCC may act as a clue for serious central nervous system disorders (e.g., meningitis; hypothalamic, brain stem, or sympathetic nervous system lesions); anyway, in these rare occurrences HCC always represents an epiphenomenon of the disease, never acting as the sole sign of the underlying disorder.

Keywords

- ▶ harlequin color change
- ▶ preterm
- ▶ neonate
- ▶ infant
- ▶ dermatology

First clinical report of a curious autonomic vascular phenomenon occurring in neonatal period, characterized by a fleeting split appearance of skin into two well-demarcated color areas, came in 1952 from Neligan and Strang,¹ who named it “Harlequin colour change” (HCC) after the famous Venetian carnival mask dressed in patches of different colors.

Since then, HCC has been described in a fairly broad number of reports involving neonates,^{2–15} infants,^{16–20} children,^{21–24} and adult patients,^{25–58} either as an isolated finding or as secondary to a specific condition (e.g., exercise, iatrogenic damage, and associated diseases).

Case 1

A late preterm male neonate was born vaginally; he was put in antibiotic prophylaxis with IV ampicillin and netilmicin because

of the maternal history of premature rupture of membranes. At 4 days of life, he developed a transient erythematous rash on the right side of the face, on which he was decumbent (▶ Fig. 1); the rest of the body was not interested. The rash rapidly vanished within 2 minutes from its start.

Case 2

A Moroccan male preterm newborn was delivered by caesarean section at 31 + 3 weeks of gestational age because of altered cardiotocographic pattern; he did very well in delivery room, not needing any resuscitation. About 10 minutes after the delivery, during acute crying, he suddenly developed a patchy skin pattern, with regional clear-cut edge cutaneous discoloration of face, right forearm, right leg, and left knee (▶ Fig. 2); skin returned evenly pink in a few minutes.

received
October 22, 2014
accepted after revision
December 30, 2014
published online
March 2, 2015

DOI <http://dx.doi.org/10.1055/s-0035-1545671>.
ISSN 2157-6998.

Copyright © 2015 by Thieme Medical Publishers, Inc., 333 Seventh Avenue, New York, NY 10001, USA.
Tel: +1(212) 584-4662.

License terms



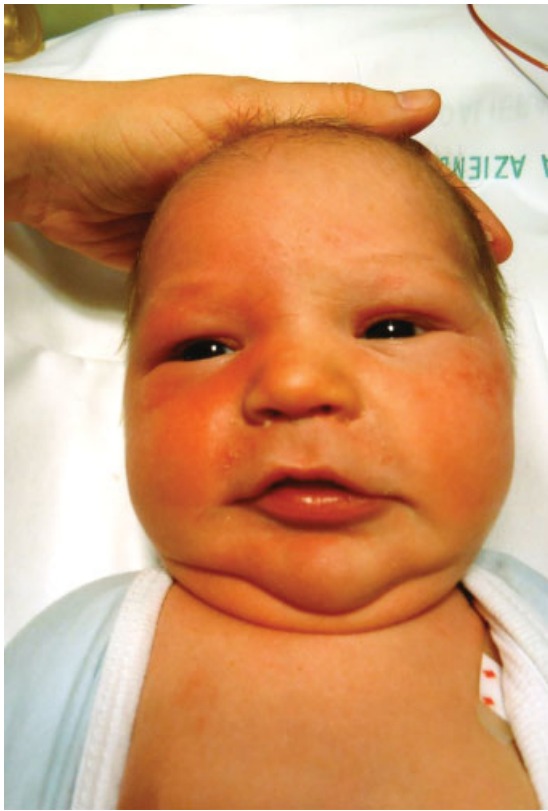


Fig. 1 Facial harlequin color change in a late preterm White newborn administered IV antibiotic therapy for a vaginal delivery with history of premature rupture of membranes; the baby was on his right side when the rash began. Overall phenomenon lasted 2 minutes and then rapidly vanished.

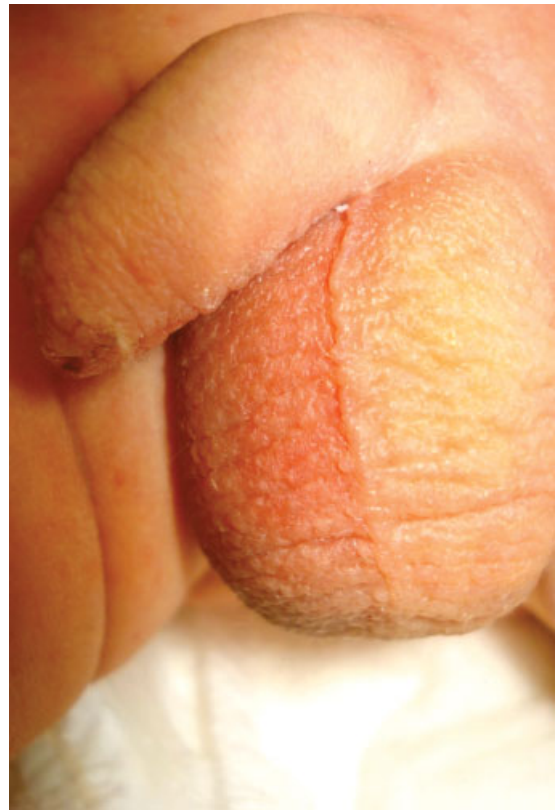

Fig. 3 Harlequin color change of the right hemiscrotum in a term Caucasian neonate after bath. The baby was otherwise asymptomatic. No other skin district was interested. Phenomenon quickly regressed in 1 minute, leaving scrotum evenly pink.

Case 3

A term, healthy neonate developed an altered color of the right hemiscrotum soon after a bath (► **Fig. 3**); no other body region was interested in the phenomenon, which quickly regressed in about 1 minute leaving no trace.

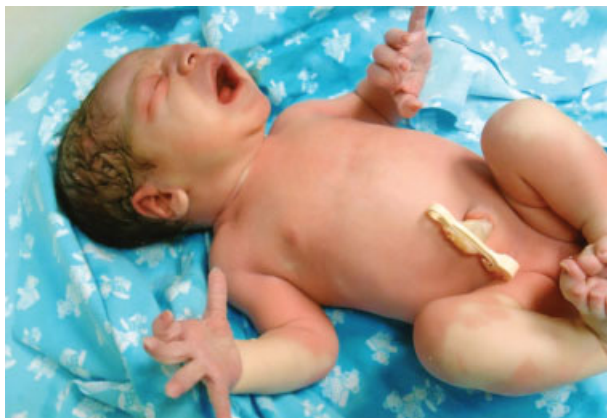

Fig. 2 Harlequin phenomenon in a Moroccan preterm newborn (31 weeks' gestational age). Regional, clear-cut edge skin discoloration started 10 minutes after delivery during intense crying, involving face and right hemibody of the neonate, and vanished minutes after.

Discussion

Epidemiology

HCC appears transiently in as up to 10% of healthy newborns,⁹ more commonly on days 2 to 5 of life,^{9,17} although it has been reported even later in a neonatal age.¹⁴

First reports published about HCC suggest a raised prevalence in "small for gestational age, especially preterm neonates,"¹¹ observation confirmed by some recent articles too^{5,13,20}; on the contrary, several new observations register HCC as a common finding also in full-term neonates.^{6,8,9,14}

Clinical Features

In most cases, HCC expression consists in a sudden change in skin color, more often with a distinct limiting edge along body midline (see ► **Figs. 1** and **3**), dividing neonate body skin into a pale half and a plethoric (usually the decumbent) half¹⁵; occasionally, HCC can present itself in a patchy fashion, again with sharp edge borders (see ► **Fig. 2**),¹⁴ sometimes sparing arms, legs, trunk, face, and/or genitalia.^{2,3} HCC usually is a brief and quickly reversing phenomenon; skin returns uniformly colored in a few minutes.^{8,9}

Of note, most commonly HCC happens in the absence of accompanying signs or symptoms; particularly, no concurrent autonomic dysregulation symptoms (such as respiratory rate, heart beat frequency, pupil diameter, or tone alterations) are evident during an HCC episode.^{6,20}

Physiopathology and Associated Conditions

Exact mechanisms responsible for HCC are still unknown, but quite robust evidence accounts for a sympathetic autonomic dysfunction in the control of peripheral capillary bed tonus, probably because of the hypothalamic functional immaturity in the newborn^{1-3,17-19}; therefore, erythematous and pale skin areas result from unregulated regional capillary vasodilatation and vasoconstriction, respectively.

Associated conditions and medications may possibly accompany and/or enhance HCC phenomenon, either by influencing the peripheral vascular tone and reactivity (prostaglandin E,⁸ some anesthetics^{17,43}) or by being further expressions of central autonomic disturbance (meningitis,⁵ seizures,¹⁸ and—in late childhood and adulthood—headache,^{32,33} parasomnia,⁵¹ and sweating disorders⁵⁴).

HCC can also be associated with congenital, acquired or iatrogenic lesions of hypothalamus, brain stem, cervical sympathetic nervous system, or of the second and third spinal cord thoracic segments.¹⁵ However, most cases of the HCC are classified as idiopathic.^{47,52}

Differential Diagnoses

HCC characteristics make it unlikely to be confused with other systemic rashes. Anamnesis plays a key role in distinguishing HCC from other types of rash (history of fever and flu-like symptoms in parvovirus B19 infection⁵⁹; previous drugs intake in Steven Johnsons syndrome⁶⁰), as does peculiar presentation of HCC (fleeting, well-demarcated rash, usually involving half of the body) in contrast to that of different rashes (generalized and poorly delimited eruption in parvovirus B19 infection⁵⁹; vesicular or papular eruption in varicella⁶¹ and measles,⁶² respectively; pruritic, pomfoid elements in urticaria⁶³; painful red or purplish rash with skin dead and shedding in Steven Johnsons syndrome⁶⁰).

Finally, HCC in the neonate most often is not accompanied by any other significant symptom.

Conclusions and Final Remarks

In most cases, HCC represents a benign, idiopathic, and rapidly autoregressive phenomenon, with no need for treatment. Some drugs (especially anesthetics and prostaglandin E) are thought to enhance HCC expression through their influence on the capillary tone in the peripheral vascular bed; this effect is anyway promptly reversible with drug withdrawal.

Only in rare circumstances, HCC may act as a clue for serious central nervous system disorders (e.g., meningitis; hypothalamic, brain stem, or sympathetic nervous system lesions); anyway, in these rare occurrences HCC always represents an epiphenomenon of the disease, never acting as the sole sign of the underlying disorder.

Conflicts of Interest

None.

References

- Neligan GA, Strang LB. A "harlequin" colour change in the newborn. *Lancet* 1952;2(6743):1005-1007
- Lucky AW. Transient benign cutaneous lesions in the newborn. In: Eichenfield LF, Frieden IJ, Esterly NB, eds. *Neonatal Dermatology*, 2nd ed. Philadelphia, PA: Saunders Elsevier; 2008:85-97
- Morelli JG. Diseases of the neonate. In: Kliegman RM, Behrman RE, Jenson HB, Stanton BF, eds. *Nelson Textbook of Pediatrics*, 18th ed. Philadelphia, PA: Saunders Elsevier; 2007:2661-2664
- Velayuthan S, Sankararaman S. Visual diagnosis: newborn who has unilateral color change. *Diagnosis: Harlequin color change. Pediatr Rev* 2013;34(7):e25-e26
- Lee RS, Wan HS, Chan RL. Harlequin colour change in a newborn with meningitis. *Hong Kong Med J* 2012;18(6):539.e3-539.e4
- Tang J, Bergman J, Lam JM. Harlequin colour change: unilateral erythema in a newborn. *CMAJ* 2010;182(17):E801
- Hartdorff CM, Valks SD. Diagnostic image (328). A neonate with a unilateral red discoloration of the face [in Dutch]. *Ned Tijdschr Geneesk* 2007;151(24):1344
- Rao J, Campbell ME, Krol A. The harlequin color change and association with prostaglandin E1. *Pediatr Dermatol* 2004;21(5):573-576
- Selimoğlu MA, Dilmen U, Karakelleoğlu C, Bitlisli H, Tunnessen WW Jr. Picture of the month. Harlequin color change. *Arch Pediatr Adolesc Med* 1995;149(10):1171-1172
- Baba K, Iino Y. The harlequin color change of the newborn infant. *Paediatr Univ Tokyo* 1962;7:30-31
- Mortensen O, Stougard-Andresen P. Harlequin colour change in the newborn. *Acta Obstet Gynecol Scand* 1959;38:352-358
- Birdsong M, Edmunds JE. Harlequin color change of the newborn; report of a case. *Obstet Gynecol* 1956;7(5):518-521
- Dang D, Zhou W, Liu Y, Wu H. Harlequin color change in two preterm newborns. *J Dermatol* 2014;41(1):102-103
- Rao J, Krol A. Images in clinical medicine. The harlequin color change. *N Engl J Med* 2003;349(10):968
- Januário G, Salgado M. The Harlequin phenomenon. *J Eur Acad Dermatol Venereol* 2011;25(12):1381-1384
- Pearson HA, Cone TE Jr. Harlequin color change in a young infant with tricuspid atresia. *J Pediatr* 1957;50(5):609-612
- Wagner DL, Sewell AD. Harlequin color change in an infant during anesthesia. *Anesthesiology* 1985;62(5):695
- Zelnik N, Nir A, Amit S, Iancu TC. Autonomic seizures in an infant: unusual cutaneous and cardiac manifestations. *Dev Med Child Neurol* 1990;32(1):74-78
- Morrison DA, Bibby K, Woodruff G. The "harlequin" sign and congenital Horner's syndrome. *J Neurol Neurosurg Psychiatry* 1997;62(6):626-628
- Padda GS, Cruz OA, Silen ML, Krock JL. Skin conductance responses in paediatric Harlequin syndrome. *Paediatr Anaesth* 1999;9(2):159-162
- Breunig JdeA, Hartmann M, Freire CF, de Almeida HL Jr. Harlequin syndrome in childhood—case report. *An Bras Dermatol* 2012;87(6):907-909
- Turco GR, Farber NE. Postoperative autonomic deficit: a case of harlequin syndrome. *Anesthesiology* 1996;85(5):1197-1199
- Kerbl R, Schwinger W, Lackner H, Dornbusch HJ, Urban CE. Peripheral harlequin-like thermal imbalance after Wilms' tumor. *J Pediatr* 2000;137(6):887
- Sabir H, Babor F, Kieseier BC, Mayatepek E, Assmann B. Unilateral facial flushing and sweating after physical exercise: Harlequin syndrome. *Klin Padiatr* 2011;223(2):90-91

- 25 Tascilar N, Tekin NS, Erdem Z, Alpay A, Emre U. Unnoticed dysautonomic syndrome of the face: Harlequin syndrome. *Auton Neurosci* 2007;137(1–2):1–9
- 26 Sribnick EA, Boulis NM. Treatment of Harlequin syndrome by costotransversectomy and sympathectomy: case report. *Neurosurgery* 2011;69(1):E257–E259
- 27 Bohlega S, Stigsby B, Al Mohaileb F. Teaching neuroimages: harlequin syndrome caused by lesion of sympathetic regulatory neurons. *Neurology* 2010;74(24):e106
- 28 Oller K, Cao K, Parkerson J, Lezama J. Stop, you're making me blush. *Am J Med* 2011;124(4):301–302
- 29 Kalapesi FB, Krishnan AV, Kiernan MC. Segmental facial anhidrosis and tonic pupils with preserved deep tendon reflexes: a novel autonomic neuropathy. *J Neuroophthalmol* 2005;25(1):5–8
- 30 Mashour GA, Levine W, Ortiz VE. Intraoperative Harlequin syndrome. *Anesth Analg* 2006;102(2):655
- 31 Burlacu CL, Buggy DJ. Intraoperative Harlequin syndrome. *Anesth Analg* 2007;104(3):748–749
- 32 Viana M, Mathias CJ, Goadsby PJ. Headache in three new cases of Harlequin syndrome with accompanying pharmacological comparison with migraine. *J Neurol Neurosurg Psychiatry* 2012;83(6):663–665
- 33 Drummond P, Lance JW. Harlequin syndrome: does a cranial autonomic neuropathy influence headache? *J Neurol Neurosurg Psychiatry* 2012;83(6):577
- 34 Duddy ME, Baker MR. Images in clinical medicine. Harlequin's darker side. *N Engl J Med* 2007;357(20):e22
- 35 Moon SY, Shin DI, Park SH, Kim JS. Harlequin syndrome with crossed sympathetic deficit of the face and arm. *J Korean Med Sci* 2005;20(2):329–330
- 36 Jiménez-Caballero PE. Harlequin syndrome secondary to thoracic chondrosarcoma [in Spanish]. *Rev Neurol* 2008;46(4):252–253
- 37 Díaz-Soto G, Vaquerizo MJ, García-Álvarez C, Villar-Bonet A. Harlequin syndrome post-transsphenoidal pituitary macroadenoma surgery. *Hormones (Athens)* 2012;11:207–209
- 38 Fallon KE, May JJ. Harlequin syndrome in two athletes. *Br J Sports Med* 2005;39(1):e1
- 39 Toll A, Gálvez-Ruiz A. Harlequin syndrome after jogging. *Med J Aust* 2011;195(5):288
- 40 Sarikaya H, Georgiadis D, Baumgartner RW. Harlequin syndrome in spontaneous dissection of the cervical carotid artery. *Neurology* 2008;71(18):1459
- 41 Noda S. Harlequin syndrome due to superior mediastinal neurofibroma. *J Neurol Neurosurg Psychiatry* 1991;54(8):744
- 42 Pradeep PV, Benede AK, Harshita SS, Jayashree B. Harlequin syndrome in a case of toxic goitre: a rare association. *Case Rep Med* 2011;2011:293076
- 43 Tyrrell JR, Trumpelmann P, Chamberlain MH. Harlequin syndrome after extrapleural bupivacaine infusion. *Br J Anaesth* 2012;109(2):295–296
- 44 Umeki S, Tamai H, Yagi S, Soejima R, Higashi Y. Harlequin syndrome (unilateral flushing and sweating attack) due to a spinal invasion of the left apical lung cancer [in Japanese]. *Rinsho Shinkeigaku* 1990;30(1):94–99
- 45 Corbett M, Abernethy DA. Harlequin syndrome. *J Neurol Neurosurg Psychiatry* 1999;66(4):544
- 46 Willaert WI, Scheltinga MR, Steenhuisen SF, Hiel JA. Harlequin syndrome: two new cases and a management proposal. *Acta Neurol Belg* 2009;109(3):214–220
- 47 Lance JW, Drummond PD, Gandevia SC, Morris JG. Harlequin syndrome: the sudden onset of unilateral flushing and sweating. *J Neurol Neurosurg Psychiatry* 1988;51(5):635–642
- 48 Cheshire WP Jr, Low PA. Harlequin syndrome: still only half understood. *J Neuroophthalmol* 2008;28(3):169–170
- 49 Wasner G, Maag R, Ludwig J, et al. Harlequin syndrome—one face of many etiologies. *Nat Clin Pract Neurol* 2005;1(1):54–59
- 50 ten Holter JB, Visser A. Harlequin syndrome [in Dutch]. *Ned Tijdschr Geneesk* 1997;141(51):2495–2499
- 51 Lombardi C, Vetrugno R, Provini F, et al. Harlequin syndrome: an association with overlap parasomnia. *J Neurol Neurosurg Psychiatry* 2004;75(2):341–342
- 52 Biondi A, Persiani R, Zoccali M, Rausei S, Cananzi F, D'Ugo D. Harlequin syndrome. *Ann Thorac Surg* 2009;88(1):304
- 53 Malaviya AP, Ostor AJ. Clinical image: The Harlequin sign—benign blush or the bearer of bad news? *Arthritis Rheum* 2012;64(7):2403
- 54 Freeman R, Waldorf HA, Dover JS. Autonomic neurodermatology (Part II): Disorders of sweating and flushing. *Semin Neurol* 1992;12(4):394–407
- 55 Paul I, Kenny S, McManus K. Apical schwannoma presenting as harlequin syndrome. *Ann Thorac Surg* 2013;96(6):2248
- 56 Lin SH, Chen CI, Liu CC, Du MH, Lam C. An old lady with anterior chest pain and unilateral facial flushing. *Am J Emerg Med* 2012;30(1):248.e1–248.e4
- 57 Hojo N, Saito T, Abe K, Iijima Y. A case of idiopathic harlequin syndrome. *Intern Med* 2011;50(21):2707
- 58 Fernández De Orueta L, Esteban Fernández J, Giménez Sánchez De La Blanca A, García Aguado C. Harlequin syndrome [in Spanish]. *Med Clin (Barc)* 2011;137(8):382
- 59 Kerr JR. Parvovirus B19 infection. *Eur J Clin Microbiol Infect Dis* 1996;15(1):10–29
- 60 Kirchoff MG, Miliszewski MA, Sikora S, Papp A, Dutz JP. Retrospective review of Stevens-Johnson syndrome/toxic epidermal necrolysis treatment comparing intravenous immunoglobulin with cyclosporine. *J Am Acad Dermatol* 2014;71(5):941–947
- 61 Berkoff MC, Brown WD. Varicella after the perinatal period. *Pediatr Rev* 2013;34(11):537–538
- 62 Naim HY. Measles virus. *Hum Vaccin Immunother* 2014;5:e34298
- 63 Spickett G. Urticaria and angioedema. *J R Coll Physicians Edinb* 2014;44(1):50–54