Severe Maternal Pre- and Postpartum Intra-Abdominal Bleeding due to Deciduosis

Schwere prä- und postpartale intraabdominale maternale Blutungen aufgrund einer Deziduose

Authors D. W. Lüdders[1], R.-P. Henke[2], M. Saba[1], L. Raddatz[1], A. Soliman[1], E. Malik[1]

Affiliations
[1] Department of Obstetrics and Gynaecology, University Hospital Oldenburg, Oldenburg
[2] University Hospital Oldenburg, Institute for Pathology, Oldenburg

Key words
- pregnancy
- intra-abdominal bleeding
- deciduosis
- childbed

Schlüsselwörter
- Schwangerschaft
- intraabdominale Blutung
- Deziduose
- Wochenbett

Deutschsprachige Zusatzinformationen online abrufbar unter: www.thieme-connect.de/ejournals/toc/gebfra

Abstract

The term "deciduosis" is used to describe the severe pregnancy-associated occurrence of ectopic decidua with a usually asymptomatic course. We report on two cases of massive maternal intra-abdominal bleeding due to such symptomatic changes. The complications arose at different time points for the two cases: prepartum (26th week of pregnancy) or, respectively, – reported here for the first time – seven days postpartum. As well as differential diagnostic aspects we describe the management of the disease and its possible effects on subsequent pregnancies.

Zusammenfassung

Unter dem Begriff „Deziduose" wird das schwangerschaftsassoziierte Auftreten ektoper Dezidua verstanden, welches zumeist asymptomatisch verläuft. Berichtet wird über 2 Fälle mütterlicher intraabdomineller Massenblutungen aufgrund dieser hier symptomatischen Veränderung. Zu den Komplikationen kam es zu verschiedenen Zeitpunkten in den jeweiligen Fällen: präpartal (26. Schwangerschaftswoche) bzw. – erstmals überhaupt publiziert – 7 Tage postpartal. Neben differenzialdiagnostischen Aspekten werden das Management der Erkrankung und mögliche Auswirkungen auf mögliche Folgegraviditäten diskutiert.

Introduction

Bleeding events, especially in the subpartum and postpartum periods, together with complications due to thromboembolisms and gestosis, are the main causes of maternal morbidity and mortality [1–3].

Extrauterine, intra-abdominal causes for pre- or, respectively, postpartum bleeding are very rare occurrences with only very few typical factors [4]. Besides injuries due to accidents, ruptured aneurysms and haemorrhagic deciduosis are considered to be the main causes.

Deciduosis – the presence of ectopic decidua – is a frequently encountered constellation and occurs in the course of almost all pregnancies (85–100%). However, as a rule deciduosis remains asymptomatic and its detection is usually a coincidental finding on histology [5–6]. Life-threatening complications such as massive intra-abdominal bleeding are an absolute rarity.

We report on two cases of symptomatic, intra-abdominal bleeding due to a histologically confirmed deciduosis. On the basis of these two cases we discuss the rare clinical picture of symptomatic – in part life-threatening for mother and child – haemorrhagic deciduosis in the prepartum and, here reported for the first time, also in the postpartum period and illustrate the problems of making the diagnosis.

Case Reports

Case 1: Massive intra-abdominal bleeding due to erosion of the left pelvis wall by deciduosis

The 36-year-old primigravida presented in the 25 + 2 week of pregnancy at the University Hospital in Oldenburg with the diagnosis of an acute abdomen. On admission the patient exhibited ubiquitous abdominal pain, a marked peritonism and, on sonography, copious free intra-abdominal fluids. The haemoglobin value on admission was 8.5 g/dl but dropped within a short time to 5.2 g/dl. Induction of foetal pulmonary maturation could no longer be initiated due to the fulminant course. After clinical exclusion of appendicitis the

received 31.12.2014
revised 8.2.2015
accepted 10.2.2015

Bibliography
DOI http://dx.doi.org/10.1055/s-0035-1545876
Geburtsh Frauenheilk 2015; 75: 259–262 © Georg Thieme Verlag KG Stuttgart · New York · ISSN 0016-5751

Correspondence
PD Dr. Dörte W. Lüdders
University Hospital Oldenburg
Department of Obstetrics and Gynaecology
Rahel-Strauss-Straße 10
26133 Oldenburg
Doerte.luedders@gmx.de

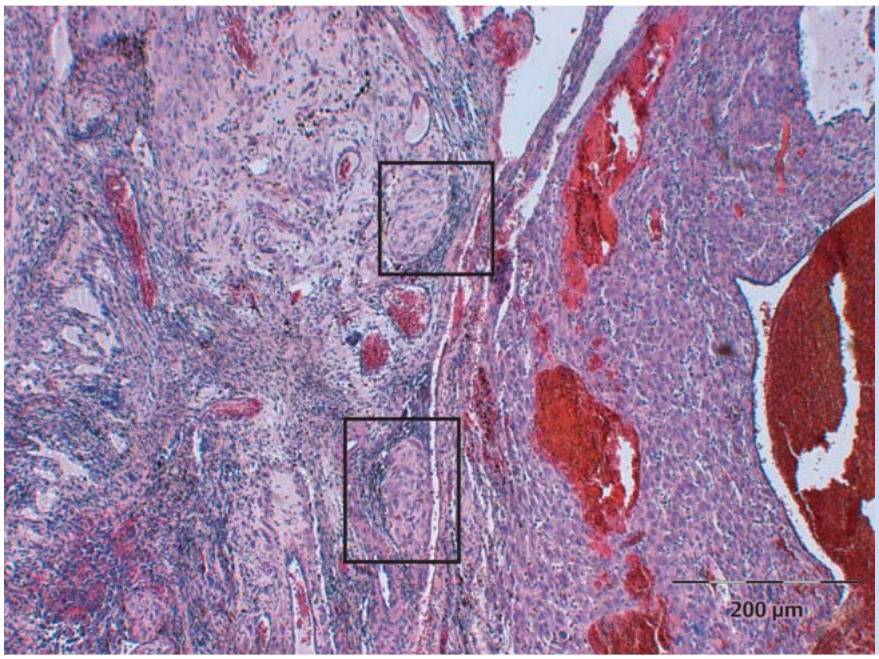

Fig. 1 Connective tissue transformed by deciduosis from the vicinity of the ovary, some characteristic deciduosis nests are stained (haematoxylin and eosin).

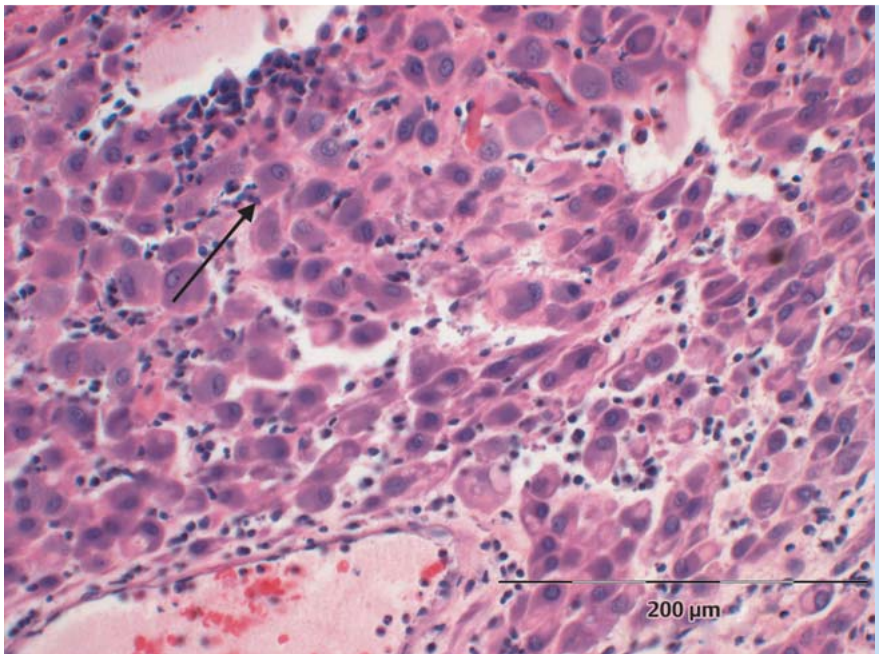

Fig. 2 Large bodied deciduosis cells with broad cytoplasm (arrow) and uniformly contoured nuclei are seen (haematoxylin/eosin).

diagnosis was unclarified abdominal bleeding as indication for a laparotomy with longitudinal incision.

Intraoperatively intraperitoneal bleeding from an eroded artery in the region of the left pelvic wall was seen. Several groups of lesions typical for deciduosis were seen in the vicinity of this pelvic wall and the left ovary so that the tentative diagnosis of pregnancy-associated deciduosis was made intraoperatively. The inflamed areas were removed and a subtle haemostasis initiated. After attaining complete stoppage of the bleeding, a sterile vaginal sonography was performed intraoperatively with visualisation of a normal-frequency foetal cardiac function and unaffected anterior wall placenta. Transabdominal sonography was performed immediately postoperatively and gave the same unremarkable result. The patient was transferred to the intensive care unit for observation. In the course of a control examination four hours postoperatively a highly pathological CTG pattern (bird wings) was observed and led to the indication for an emergency Caesarean section. As expected for the gestational age, an extremely immature female baby was delivered (820 g, Apgar 3/4/7, NapH: 7.19 BE: −7 mmol/l) and immediately transferred to the neonatal intensive care ward.

After a short postoperative monitoring on the ICU the mother was transferred to the maternity ward. Altogether, four erythrocyte concentrates were administered during the course.

After an initially stable period, on the fourth day of life the baby suffered from massive intracranial bleeding in both hemispheres with a lethal result.

Histological work-up of the maternal samples taken intraoperatively confirmed the tentative diagnosis of deciduosis (**Figs. 1** and **2**).

Case 2: Intra-abdominal bleeding from areas of deciduosis in the vicinity of the uterine border on the seventh postoperative day after primary Caesarean section for total placenta praevia totalis in the 35 + 1 week

A 39-year-old women (II gravida 0 para) presented in the 35 + 1 week of pregnancy for a planned Caesarean section due to the existence of a placenta praevia totalis and transverse foetal position. A conspicuous intraoperative finding was that the uterus was twisted by 120°. The left tube was displaced caudally in the vicinity of the uterine cervix. It was not possible to untwist the pregnant uterus and so an oblique incision was made into the accessible part of the uterus. Delivery of the baby was free of problems. After removal of the placenta, the uterus could easily be twisted back into its normal anatomic position. Inspection of the adnexa and uterine cervix revealed small endometrial lesions. The further surgical course was unremarkable.

On the 7th postoperative day the patient developed very severe pain in the vicinity of her left flank. After exclusion of an ascending urinary tract infection and renal congestion, sonography demonstrated increasing amounts of free intra-abdominal fluids. In addition, a progressive decrease in haemoglobin from 10.1 g/dl to 5.8 g/dl within a period of 13 hours was noted, so that – on the assumption of intra-abdominal bleeding – revision by way of an infraumbilical longitudinal laparotomy was undertaken. The suspicion of massive bleeding was confirmed intraoperatively. The bleeding site was identified as a conspicuous area in the region of the left dorsal uterine wall that was macroscopically compatible with deciduosis. A tissue sample was taken, followed by staunching of the bleeding; in addition two erythrocyte concentrates were administered perioperatively. Histological work-up of the tissue sample confirmed the tentative diagnosis of deciduosis.

The subsequent postoperative course was unremarkable. The patient was released home seven days after the revision operation.

Discussion

▼

Deciduosis is a mostly pregnancy associated, large-cell stromal reaction which can occur as ectopic deciduosis in the sera and mucosa of many different organs [7–8]. It can, however, also arise from a secondary decidual transformation of pre-existing extragenital endometrial lesions [9–11].

It only very rarely occurs in the physiological cycle events outside of pregnancy, as it is regulated by the action of ovarian and placental hormones, in particular, the permanently high progesterone level in pregnancy. If deciduosis occurs outside of pregnancy, then above all the progesterone produced in the adrenal gland is responsible for it [5]. During pregnancy the decidua are formed from endometrial stromal cells under the influence of the respective hormones and thus represent a physiological reaction to the progesterone stimulation caused by pregnancy. The earliest reported occurrence of deciduosis was observed on the ovary in the 9th week of pregnancy [7]. Regression of deciduosis begins towards the end of the pregnancy and generally occurs over a period of 4 to 6 weeks [5]. Deciduosis-like changes have, however, also been described during a postpartum period of up to several months [12]. This postpartum regression possibly explains, as described in our case, the acute postpartum haemorrhagic deciduosis. In this case it is possible that an insufficiently advanced regression could have triggered the late massive decidual bleeding. On the other hand another possible explanation for the massive bleeding could also be hormone withdrawal caused by the end of the pregnancy. Both are hypotheses that have not been previously reported in the literature and that also cannot be clarified for our cases. Even so, this is the first report to describe a severe decidual bleeding in childbed.

However, as a general rule, deciduosis remains asymptomatic and its detection is usually an incidental finding on histology of peritoneal biopsies taken during Caesarean sections. Also in most cases it does not have any clinical consequences. The pathogenesis of deciduosis has not yet been completely clarified.

There are various hypotheses but none of them have been unequivocally clarified. On the one hand it is discussed that a deciduosis can develop on the basis of a pre-existing endometriosis. On the other hand a de novo reaction of pluripotent submesothelial stromal cells has been proposed as the cause of deciduosis [13].

From the embryological point of view, intraembryonal coelom epithelium is the source tissue of not only endometrial stroma but also of submesothelial stroma. Intraembryonal coelom epithelium is, in addition, the source tissue of serosa of the pleura and pericardium as well as of the peritoneal cavity. This can be deduced from the widely differing localisations of deciduosis lesions that can become apparent through the corresponding localisation-dependent clinical symptoms [4, 13].

In its clinical spectrum of symptoms, deciduosis may rather exhibit unspecific changes in varying degrees of severity. The range of clinical symptoms can thus vary from shortage of breath, haemoptyses, pneumothorax, ileus symptomatics, progressive anaemia and increasing infection parameters through to the most severe and massive intra-abdominal bleeding with acute abdomen. However, these life-threatening complications are very rare and only sporadic cases have been described in the literature [9, 11, 13–15].

Massive intra-abdominal bleeding can occur as a result of erosion of arterial vessels in the vicinity of the uterus and lesser pelvis by deciduosis lesions, especially in the 2nd and 3rd trimesters of pregnancy [4]. It is of decisive importance to recognise and resolve the bleeding complication, for just this reason a differential algorithm for more rapid diagnosis and therapy is urgently needed.

Maternal bleeding complications are principally divided into subpartum and postpartum types: the main causes of subpartum bleeding complications are placenta praevia bleeding, a premature placental abruption, vasa praevia bleeding, and bleeding due to velamentous cord insertion as well as uterine rupture. Nowadays these entities are very simple to diagnose clinically and by sonography and thus therapy can be initiated in good time. With a proportion of 80%, uterine atony plays a major role in postpartum bleeding that can usually also be quickly recognised and handled by a targeted and structured management programme [16].

The difficulty for the obstetrician in cases of extrauterine, intra-abdominal bleeding is the lack of direct vision of this complication so that under certain circumstances much time is lost before the – possibly life-saving – surgical intervention can be initiated. For this reason it is recommended to include bleeding due to deciduosis not only in the prepartum but also in postpartum period in the diagnostic considerations.

Operative management by means of laparotomy – or in selected cases by laparoscopy – to staunch the bleeding is the therapy of choice in emergency situations, whereby it must also be men-

tioned that as yet no clinical cases of surgical management by laparoscopy have been described in the literature. Because of the urgent need for action in such cases of extrauterine bleeding, a close cooperation, especially with the surgical and anaesthesiological colleagues, is highly necessary. Of course, the prevention of foetal complications is also of essential importance so that in the case of a surgical intervention during the pregnancy, appropriate neonatal care options, adequate for the week of pregnancy, must also be available.

In most cases the intraoperative tentative diagnosis is made under emergency conditions and must then later be confirmed by histology or immunohistochemistry.

A topic for further discussion is whether or not the complete removal and restructuring of all deciduosis lesions after postpartum regression is a reasonable and recommendable therapy option after haemorrhagic deciduosis for the reduction of renewed complications in subsequent pregnancies. This has not yet been clarified. However, it can be assumed that especially those patients who have suffered from deciduosis complications due to extragenital endometrial lesions during a pregnancy should be advised to undergo surgical removal of the endometriosis.

Accordingly, a subsequent detailed pathological work-up should be performed on all removed tissue samples relevant for the diagnosis in order to provide possible conclusions for postpartum therapy in subsequent pregnancies.

Until now the recurrence risk in a subsequent pregnancy is not known because as yet no systematic investigations on subsequent pregnancies of the affected women have been published. An appropriate registry could help to answer open questions.

Conclusion and Perspectives

Life-threatening complications that arise through massive intra-abdominal bleeding in pregnancy must be treated immediately after recognition by an interdisciplinary team according to the generally valid clinical recommendations. Massive haemorrhagic deciduosis must always be considered in the differential diagnosis. Therapy of choice is the complete removal of the bleeding lesions. It is still questionable if the postpartum remediation of endometriosis offers any benefits for subsequent pregnancies.

Conflict of Interest

None.

References

1 *Crombach G.* Operative Behandlung schwergradiger postpartualer Blutungen. Gynäkologe 2000; 33: 286–297

2 *Crombach G, Mosny D, Peisker U et al.* Erfahrungen mit der B-Lynch-Nahttechnik bei schwergradiger Blutung infolge postpartualer Uterusatonie. Geburtsh Frauenheilk 2001; 61: 15–19

3 *Sroka M, Franke M.* Späte atone Uterusnachblutung – Stärkste vaginale Blutung drei Wochen postpartum – junge Frau droht zu verbluten! Notfallmedizin 2003; 29: 419–421

4 *Schulze G, Chuvashkin D, Riedel H.* Schwere antepartuale Blutung in der 26 + 1. Schwangerschaftswoche infolge der Ruptur der A. ovarica sinistra bei dezidualer Transformation. Geburtsh Frauenheilk 2005; 65: 881–884

5 *Büttner A, Bassler R, Theele C.* Pregnancy associated ectopic decidua (deciduosis) of the greater omentum. Pathol Res Pract 1993; 189: 352–359

6 *Malpica A, Deavers MT, Shahab I.* Gross deciduosis peritonei obstructing labor: a case report and review of the literature. Int J Gynecol Pathol 2002; 21: 273–275

7 *Kommos F, Pfisterer J, Peters F et al.* Ektope Dezidualreaktion – möglicher Anlass zur kolposkopischen, histologischen und intraoperativen Fehldiagnose. Geburtsh Frauenheilk 1998; 58: 446–450

8 *DeClerck BK, Post MD, Wisell JA.* Cutaneous decidualized endometriosis in a nonpregnant female: a potential pseudomalignancy. Am J Dermatopathol 2012; 34: 541–543

9 *Bohlmann MK, Brueggmann D, Schief W et al.* Deziduose und Endometriose der Appendix als Ursache einer akuten abakteriellen Appendizitis. Geburtsh Frauenheilk 2007; 67: 61–65

10 *Massi D, Susini T, Paglierani M et al.* Pregnancy-associated ectopic decidua. Acta Obstet Gynecol Scand 1995; 74: 568–571

11 *Georges B, Piltz S, Ochsenkühn T et al.* Extrauterine Deziduose mit postpartaler Blutung und fulminanter Gerinnungsstörung. Z Geburtshilfe Neonatol 2003; 207 – PO_14_10

12 *Urbanczyk K, Hajduk A, Stachura J.* Pregnancy associated diffuse malignant fibrous mesothelioma of peritoneum. Pol J Pathol 1996; 47: 233–237

13 *Janssen P, Herrmanns B, Schelling M et al.* Die Deziduose – eine seltene lebensbedrohliche Komplikation in der Schwangerschaft. Geburtsh Frauenheilk 2006; 66: 774–777

14 *Heidegger H, Hümpfner A, Hugo R et al.* Peritoneal deciduosis: cause for mechanical ileus in pregnancy. Geburtsh Frauenheilk 1991; 51: 307–309

15 *Kondoh E, Shimizu M, Kakui K et al.* Deciduosis can cause remarkable leukocytosis and obscure abdominal pain. J Obstet Gynaecol Res 2012; 38: 1376–1378

16 *PPH-Konsensus-Gruppe (D-A-CH).* Postpartale Blutung – Handlungsalgorithmus nach vaginaler Geburt oder in der postoperativen Überwachungsphase nach Sectio caesarea. 2011. Online: http://www.sgar-ssar.ch/fileadmin/user_upload/user_saoa/PPH_Alg2g.pdf; last access: 29.03.2015