

# Robotic-Assisted Thymectomy: Surgical Procedure and Results

Jens Rueckert<sup>1</sup> Marc Swierzy<sup>1</sup> Harun Badakhshi<sup>2</sup> Andreas Meisel<sup>3</sup> Mahmoud Ismail<sup>1</sup>

<sup>1</sup>Competence Centre of Thoracic Surgery, Department of General, Visceral, Vascular and Thoracic Surgery, Charité - Universitätsmedizin Berlin, Berlin Germany

<sup>2</sup>Department of Radiooncology, University Medicine Berlin (Charité), Berlin, Germany

<sup>3</sup>Department of Neurology, University Medicine Berlin (Charité), Berlin, Germany

**Address for correspondence** Jens Rueckert, MD, PhD, Competence Centre of Thoracic Surgery, Department of General, Visceral, Vascular and Thoracic Surgery, Charité - Universitätsmedizin Berlin, Chariteplatz 1 10117, Berlin 10117, Germany (e-mail: jens-c.rueckert@charite.de).

Thorac Cardiovasc Surg 2015;63:194–200.

## Abstract

**Background** Thymectomy is an essential component in the treatment of myasthenia gravis (MG) and the best treatment for localized thymoma. Minimally invasive thymectomy has advanced to include robotic-assisted techniques. The acceptance of this approach is growing rapidly, while the debate on the adequate technique for thymectomy remains open.

**Methods** We describe the technique of robotic-assisted thymectomy and its modifications. The worldwide registries and the literature are reviewed. The experience from the largest single-center database is analyzed.

**Results** The unilateral three-trocar approach for robotic thymectomy from either left or right side has been standardized. More than 100 centers worldwide perform robotic thymectomy. The annual number of this procedure increased steadily and reached 1,000 in 2012, while the largest single-center experiences comprise almost 500 cases. The end points improvement of MG and recurrence of thymoma are comparable to open procedures. There are special advantages of robotic assistance for complete mediastinal dissection. The perioperative complication rate is below 2%.

**Conclusion** Robotic thymectomy combines minimal incisional discomfort with extensive mediastinal dissection. As its use expands, robotic thymectomy may become the standard for all indications of thymectomy.

## Keywords

- ▶ thymus
- ▶ mediastinum
- ▶ chest
- ▶ robotics
- ▶ thymectomy
- ▶ myasthenia gravis

## Introduction

For the autoimmune, muscle-debilitating disease of myasthenia gravis (MG), thymectomy has been accepted by many centres.<sup>1,2</sup> Thymectomy must strive to impart minimal procedural impact as the operation may exacerbate MG during recovery.<sup>3</sup> Thymectomy, however, should be complete, because postoperative improvement seems to depend on the radicality of mediastinal dissection.<sup>4–7</sup> Thymic gland anatomy reveals a highly variable shape of the main lobes with potential distribution of ectopic thymic islets in the peri-

thymic mediastinal tissue.<sup>8–10</sup> The evaluation of surgical results for MG has resisted comparison due to variable intervals of up to 7 years until clinical response occurs and the rate of improvement may be assessed.<sup>11</sup> The thymic tumors, thymoma or thymic carcinoma, may arise from any part of the thymic gland.<sup>12,13</sup> Thymoma, whether or not associated with MG, represents an absolute indication for thymectomy, while its role in MG without thymoma is relative.<sup>2,14</sup> Traditionally, thymectomy has been achieved via sternotomy, though the very first approach has been transcervical.<sup>8,15,16</sup>

received

February 4, 2015

accepted

February 6, 2015

published online

March 25, 2015

© 2015 Georg Thieme Verlag KG  
Stuttgart · New York

DOI <http://dx.doi.org/10.1055/s-0035-1549007>.  
ISSN 0171-6425.

Over decades, a debate has continued between the proponents of transcervical and transsternal thymectomy.<sup>3,8,11,17-19</sup> More recent technological advances have altered this dichotomy. Thoracoscopy in various modifications has enabled detailed mediastinal dissection, thus threatening the position of both prior approaches.<sup>2</sup> In total, 14 different operation techniques for thymectomy have been reported.<sup>2</sup> For thymoma, the dogma of sternotomy was proclaimed even longer and precluded consideration of minimally invasive thymectomy.<sup>20-22</sup> The introduction of robotic-assisted surgery continues to profoundly influence thoracic, and especially mediastinal, surgery.<sup>20,23,24</sup> The dual aim of complete resection (R0) in thymoma and radical removal of thymic and perithymic tissue in any and all challenging anatomical variations in MG can be satisfactorily addressed by robotic thymectomy.<sup>20,23-26</sup> Within robotic thymectomy, questions of technical variations and the importance of laterality in accessing the gland require further study.

## Materials and Methods

The historical development of robotic thymectomy was reviewed within the published literature using the key words robotic thymectomy. The operation technique was described and the technical advantages of robotic assistance were evaluated. Variations and refinements of the operation technique have been analyzed. Distribution, dissemination, and influence of robotic thymectomy are described by the registered cases since 2001. The clinical results of all series of more than 20 cases have been analyzed from the literature. Some lessons learned from our own experience over more than 10 years with the largest series of robotic thymectomy have been included.

## Results

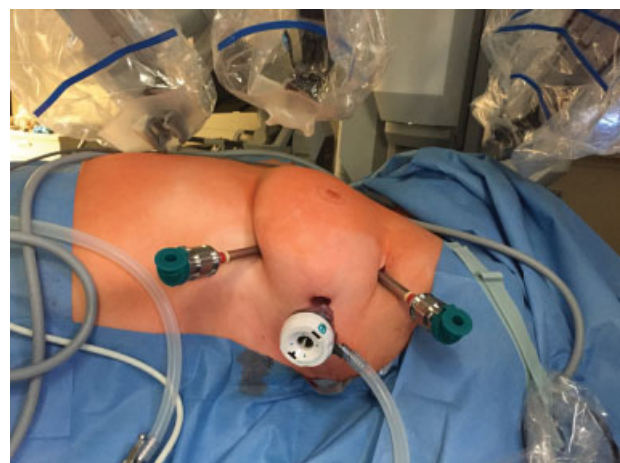
### History of Robotic Thymectomy

Robotic thymectomy evolved from thoracoscopic nonrobotic thymectomy. In the early 1990s, three sources led to the development of thoracoscopic thymectomy: the intent to minimize the deleterious effects of general anesthesia and thoracotomy pain for patients with MG, the availability of thoracoscopic equipment, and the acceptance of the requirement for radical complete thymectomy.<sup>27</sup> The first reported thoracoscopic thymic intervention was the excision of a small thymoma without complete removal of the gland in 1992.<sup>28</sup> Shortly thereafter, several teams started to perform thoracoscopic thymectomy.<sup>27,29,30</sup> At the Charité in Berlin, this technique was introduced in 1994.<sup>31,32</sup> A human anatomical study confirmed feasibility and the selection of laterality.<sup>33</sup> The technique was then standardized as a unilateral three-trocar approach. The first robotic operation on the thymic gland, of note, was again an excision of a thymoma in 2001.<sup>34</sup> Case reports and small series clarified its feasibility.<sup>22,35,36</sup> Based on 80 thoracoscopic thymectomies, preceded by an *in vitro* training phase, we introduced a three-trocar unilateral robot-assisted thymectomy using the da Vinci (Intuitive Surgical, Sunnyvale, California, United States) robotic system

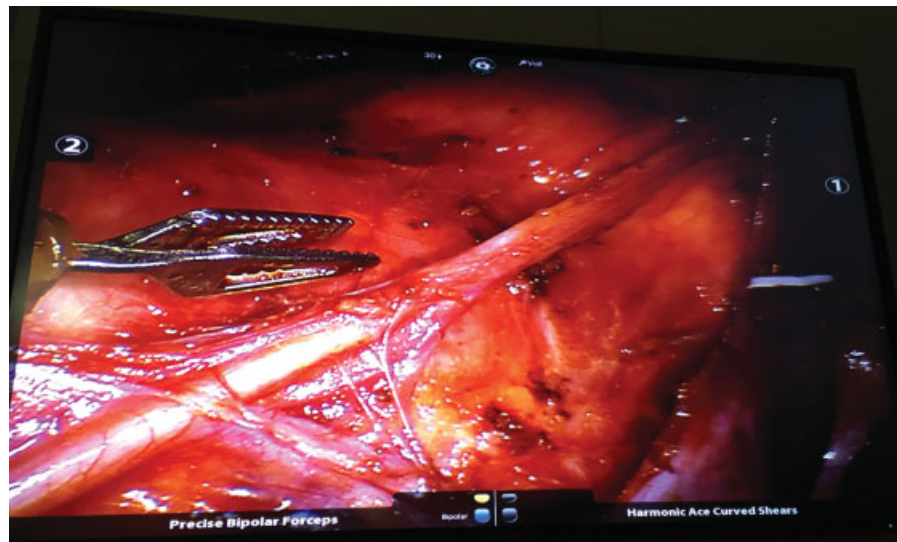into our clinical practice in 2002. A rapid and uniform adoption of this technique has taken place over the last decade.

### Surgical Technique

The preferred patient position is a supine position with downward rotation of the right patient side at 30 degrees (→Fig. 1). The left arm must be positioned posterior to the chest wall to ensure robotic dissection in both cardiophrenic angle and anterior neck, without colliding with the da Vinci arm. The positions of the surgeon and his assistant are to the left side of the patient and the nurse works to the left of the surgeon. The operative field should always be prepared and draped for a conversion to median sternotomy or additional cervical approach or right-sided thoracoscopy. Using single right lung ventilation, the 12-mm trocar is placed in the fourth intercostal space at the anterior axillary line. A 10-mm, 30-degree endoscope is then introduced through the middle trocar. The operative field is evaluated, and the position of the remaining two 8-mm trocars is determined. The cranial trocar is placed in the third intercostal space anterior to the middle axillary line and the caudal trocar is placed in the fifth intercostal space at the medioclavicular line. Thus, all three trocars are placed exactly along the submammary fold (→Fig. 1). No accessory trocars are needed; however, a right-sided trocar can be placed if necessary. The special da Vinci trocars are then connected with the three robotic arms of the table cart. The point of reference at the beginning of the resection in the anterior mediastinum is the left phrenic nerve (→Fig. 2). The thymic gland may be partially visible, depending on the various amounts of pericardial fatty tissue and the thymic histology. In cases of large amounts of fatty tissue, we initially apply CO<sub>2</sub>. Pleural adhesions, if present, may easily be dissected using the da Vinci instruments. The 12-fold optical enlargement with three-dimensional view will then allow for subtle tissue dissection. Further preparation begins low in the midsection of the pericardium where there is always a low-fat area. In very tall, usually young patients, this area is often completely free of fatty tissue. En bloc resection is continued until the right subxiphoid pleural



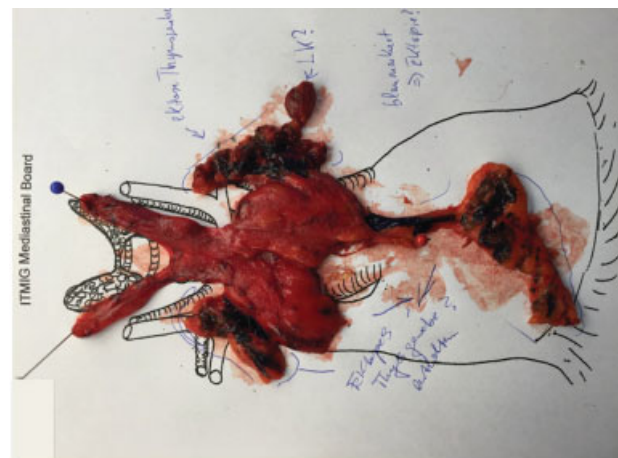**Fig. 1** Patient and trocar position for left-sided thymectomy.



**Fig. 2** Left-sided approach after robotic dissection for ectopic thymic tissue in the aortopulmonary window.

fold is reached. The retrosternal pleura incision is then continued up to the jugular fold of the mediastinal pleura. Beginning at the caudal pericardium, the tissue bloc is further mobilized on the pericardium. According to the patient's age, constitution, histology, and immune suppression before surgery, the variable local findings require an almost complete blunt dissection or a very delicate ultrasonic dissection of small vessels from the pericardium. The entire median retrosternal tissue portion is then mobilized. Often, the right main thymic lobe is clearly recognized from the surrounding fatty tissue. The aortocaval groove is then dissected free and the right lung, which is only covered by the mediastinal pleura, is exposed. To continue the preparation into the neck from behind the manubrium, the mediastinal fold is incised. At this point, the anterior wall of the innominate vein is discovered left to the phrenic nerve. Depending on the amount of fat in the anterior mediastinum, the vein may be located directly underneath the pleura or at a distance of more than 5 mm. Occasionally, a single central vessel, the vein of Keynes, collects all venous blood from the thymic gland for drainage into the innominate vein. In the majority of cases, however, there are two to four thymic veins. These veins must be dissected without causing injury to the innominate vein. The veins are then divided between clip ligatures or by using the ultrasonic scalpel. Atypical locations, although rare, of the thymic veins must also be noticed. Once the thymic veins are divided, mobilization of both upper poles continues above the innominate vein. The shape of the upper poles is recognized from the surrounding fatty tissue and can serve as a point of orientation. Special attention is needed for any part of the upper poles located between aortic arch and the innominate vein. This anatomical variation can easily be handled using the EndoWrist da Vinci instruments. In most patients, the left lobe of the thymic gland is larger and stronger, which is usually true for the upper poles as well. Additionally, the left thymic lobe is more intimately related to the phrenic nerve.<sup>37</sup> The upper poles, mobilized following careful dissection of the

capsule, are gently grasped and then pulled down. Patience is important during complete mobilization of each upper pole. At the cranial end, the thyrothymic ligament becomes clearly visible, and under tension of the completely exposed upper thymic pole, this ligament is severed by ultrasonic dissection or between clips. In most cases, the right phrenic nerve is now identified. Thymectomy concludes with preparation of the right thymic pole under CO<sub>2</sub> insufflation. The en bloc specimen of the thymus, including all surrounding fatty tissue, is placed in an endobag and removed through the middle trocar incisions. The specimen is measured by size and weight. Histological work-up is prepared by positioning the specimen as shown in **Fig. 3**. A photodocumentation is added. The operative field, including the venous confluence, the supra-aortic arteries, and parts of the anterior tracheal wall, is examined for the presence of residual tissue and hemostasis. If the right pleural cavity is opened, an enlargement of this opening prevents a right postoperative pneumothorax. A



**Fig. 3** Specimen prepared for histological work-up and for analysis of ectopic thymic tissue.

chest tube is placed in the left pleural cavity. Re-inflation of both lungs is followed by closure of the trocar incisions. Once the operation is complete, the patient is extubated immediately and placed on patient-controlled analgesia. The chest drain is removed if the postoperative chest X-ray shows normal findings and the amount of secretion is below 100 mL during the first 12 hours postoperatively.<sup>38</sup>

**Refinements and Modifications of the Technique**

The typical position of the three trocars between third and fifth intercostal space and between midclavicular and mid-axillary line is modified by some due to the use of 0 degree optic and additional trocars<sup>20,22,39</sup>. The need for bilateral access in more difficult cases, however, is lower with robotic assistance. Robotic thymectomy may be performed with 5-mm instruments. New instruments with mobile tip for suction or dissection (vessel sealer) allow for further precision of mediastinal dissection. For anatomical variations such as encasement of the left phrenic nerve by thymic tissue, cardiac scissors are most precise and enable complete en bloc thymectomy (►Fig. 3). The proponents of the left-sided approach emphasize the superior visualization of a larger left-sided thymus particularly in cases of complex overgrowth of the phrenic nerve (this occasionally on the left side and virtually never on the right side) as the main reasons to obtain complete thymectomy.<sup>23,26,40,41</sup> The right-sided technique is preferred by surgeons who favor easier conditions proclaimed by larger space and the landmark of the superior vena cava.<sup>25,39,42</sup> They believe that trocar injuries could be better avoided coming from the right side.<sup>20</sup> The use of monopolar hook, no–or continuous CO<sub>2</sub>–insufflation belong to the variations of the robotic thymectomy.<sup>22</sup>

**Advantages and Limitations of Robotic Thymectomy**

The number of registered procedures worldwide between 2001 and 2012 has been recently estimated at approximately 3,500.<sup>23</sup> All published literature on robotic thymectomy, the Intuitive Surgical registry, and personal communications were used to analyze for geographical dispersion of this approach in its first decade. The assumption of an annual caseload of 28 for each clinic resulted in at least 100 centers performing robotic thymectomy at the end of 2012.<sup>23</sup> The largest series at the Charité in Berlin comprises 449 robotic thymectomies until December 2014. The distribution is shown in ►Table 1. Robotic thymectomy has been performed in children as young as 4 years old and in patients up to 86 years old. Particular advantages of the robotic technology regarding visualization, range of motion, and dexterity for mediastinal dissection as well as comfort for the surgical team helped to include more difficult cases for minimally invasive thymectomy (►Table 2).<sup>23</sup> We included patients after previous sternotomy, those with BMI above 35, and those with pectus excavatum in our series. Particular attention was paid to the anatomical distribution of thymic tissue. Apart from small islets invisible to the eye, visible ectopic thymic tissue was encountered in 5% of patients. All cases were effectively addressed by the robotic technique. The morbidity of this series is below 2% with only three thoracoscopic reinterven-

**Table 1** Indications for robotic thymectomy at Charité University Berlin (n = 449, January 2003 to December 2014)

Indication	n
Myasthenia gravis	397
Thymoma	64
Thymoma + Myasthenia gravis	53
Parathyroid gland	7
Others	29

tions: two for bleeding from the chest wall at the entrance of the upper working trocar and one for chylothorax due to unusual thoracic duct anatomy with persistent left vena cava. Two patients had a paralyzed phrenic nerve. In two patients, thymoma with Masaoka-Koga stage III and IV was diagnosed during robotic exploration; both underwent intentional sternotomy. When thymoma of preoperative Masaoka-Koga stage I or II was confirmed during operation, we performed robotic-assisted total thymectomy from the beginning of our series. The visual accuracy and technical quality allowed us to realize a no-touch mediastinal dissection (►Table 2). Other large series of robotic thymectomy have been published.<sup>43</sup> The evaluation of the literature and meeting abstracts did not disclose major complications during or after robotic thymectomy. Centers established in open surgical approaches reported their change of operation technique with start of the new robotic approach.<sup>24,44</sup> The outcome analyses after robotic thymectomy revealed improvement of 29 to 46% for MG in mixed patient populations.<sup>22,38,45</sup> A higher complete stable remission rate of MG was found in a comparative cohort study for robotic versus nonrobotic thoracoscopic thymectomy.<sup>46</sup>

**Discussion**

The sources of robotic thymectomy were the surgical and neurological development (what do you mean?). At the

**Table 2** Technical advantages of robotic surgery with the da Vinci system

Technical parameter	Advantage
Real 3D HD	Improved visualization
MIMIC software, steeper learning curve	Stratified education
Wristed instrument tips	Increased range of motion
No workspace limitations	Fixed entry points
Highest dexterity and tremor filtration	Stable operation field
ICG for nerve visualization	New technical quality
New instruments	Single-port surgery
Avoidance of surgeon fatigue	Camera stability
Fulcrum effect	Avoided by robotic surgery

Abbreviations: HD, high definition; ICG, indocyanine green; 3D, three-dimensional.

This document was downloaded for personal use only. Unauthorized distribution is strictly prohibited.



University Clinic in Berlin (Charité), early investigations defined nature and name of MG.<sup>47</sup> Moreover, the relation between MG and the thymic gland was first postulated in Berlin.<sup>48</sup> Sauerbruch, who performed the first thymectomy for MG, had been chief of surgery at the Charité when M. Walker discovered the symptomatic therapy for MG.<sup>15,49</sup> The long tradition was continued later by Wolff, who mainly performed anterolateral approaches and sternotomy for thymectomy.<sup>50</sup> In the year 1990, the new technological development of minimally invasive abdominal surgery allowed to renew and extend the long surgical experience at our hospital with thoracoscopic surgery. The basis underlying thoracoscopic thymectomy was to conclude the debate between transsternal and transcervical operation technique.<sup>31,32,51</sup> An effective combination of minimal invasion and better mediastinal dissection was also studied and performed at the Charité in a series of 80 cases between 1994 and 2002. Imperfection characterized the beginnings of thoracoscopic and robotic-assisted thymectomy as thymomas were first resected with partial gland extirpation.<sup>34,52</sup> Soon, robotic assistance turned out to ideally meet the requirements of mediastinal surgery. We switched to robotic thymectomy in January 2003 after a preparation phase. Using a prospective database, we described the clinical course of MG, the oncological parameters of thymoma, basic clinical data, specific data of all other rare cases, and the morbidity parameters. A survey of our actual experience illustrates the largest series worldwide (►Table 3). After preliminary analysis, adequate results for improvement of MG and outcome of thymoma without recurrence were obtained (data not published yet). The technique was developed and standardized by other teams.<sup>22,26</sup> Robotic thymectomy is performed almost exclusively with the da Vinci system.<sup>53</sup> The procedure can and should be taught and learned to achieve complete thymectomy. Therefore, we and others helped to start the program

in numerous other centers worldwide.<sup>23,38</sup> At the beginning, similar to the introduction of thoracoscopic thymectomy a decade before, robotic thymectomy was accompanied by criticism and enthusiasm.<sup>1</sup> The estimation of wide adoption throughout the world in more than 100 centers also reflects the correlation with the interest of most neurologists and the wishes of the patients with MG and/or thymoma.<sup>20,38</sup> The technical advantages of robotic mediastinal dissection may not have been exhausted and further potential for surgical refinement exists (►Table 2) Approval of the clinical advantage of this enhanced technique was provided by the adoption process of robotic thymectomy: teams started minimally invasive thoracic surgery only at the level of robotic surgery,<sup>25</sup> other teams switched to robotic thymectomy after large experience with thoracoscopic thymectomy.<sup>43,54</sup> Furthermore, strong opponents of minimally invasive thymectomy turned their policy toward adoption of the robotic approach<sup>55</sup> (Meacci and Shrager, personal communication). Even at most conservative institutions, a change to thoracoscopic thymectomy was made and followed by robotic thymectomy.<sup>56</sup> The general sharp increase of numbers of robotic thymectomy illustrates the need for meticulous stratified learning facilities of the procedure.

Although there are very promising results of robotic thymectomy, difficult questions remain to be answered. Not only the evaluation of this approach depends on different surgical “schools” and “habits”, but also the availability of the da Vinci system is limited due to the tremendous, and often prohibitive, costs. Conversely, the average caseload of mediastinal surgery per institution raises the question as to how many of the 14 different operation techniques for thymectomy may realistically be part of the thoracic curriculum. Of all current techniques, robotic surgery appears to us as the singular operation most likely to replace all available alternatives.<sup>57</sup>

**Table 3** Literature summary of robotic thymectomy series including more than 20 cases

Author	Country	Year	Study interval	Total	MG	Thymoma	Approach	Ports	Complete remission rate (%)	Thymoma recurrence rate (%)
Rückert	Germany	2008	2003–2007	106	95	12	Left	3	42	0
Marulli	Italy	2013	2002–2010	100	100	8	Left	3	28.5	0
Freeman	USA	2011	6 years	75	75	excluded	Left	3	28	n.a.
Schneider	Switzerland	2012	2004–2011	58	25	20	Left	3	n.a.	11.1
Melfi	Italy	2012	2001–2010	39	19	13	Left	3	n.a.	0
Augustin	Austria	2008	2001–2007	32	32	9	Right	3	n.a.	0
Cerfolio	USA	2011	2009–2010	30	30	n.a.	Right	3	n.a.	n.a.
Castle	USA	2008	2002–2008	26	18	1	Right	4–5	n.a.	n.a.
Goldstein	USA	2010	2003–2008	26	26	5	Right	4	n.a.	n.a.
Tomulesco	Romania	2009	2008–2009	22	22	excluded	Left	3	n.a.	n.a.
Keijzers	Netherlands	2014	2004–2012	138	125	37	Right	3	28.8	2.7
Jun	China	2014	2010–2012	55	n.a.	21	Left/right	4	n.a.	n.a.

As compared with transcervical and thoracoscopic non-robotic as well as subxiphoid approaches, robotic thymectomy more perfectly adapts to different anatomical variations. Apart from difficult cases of thymoma, challenges include thymic overgrowth or complete encasement of the left phrenic nerve. The cervical thymus may be partially or completely located between anonymous vein and aortic arch. As these constellations almost never interfere with the right phrenic nerve,<sup>23,37</sup> we favor the left-sided approach with 30 degrees optic. In mixed series, all these configurations were included with favorable results.<sup>38,45</sup> For thymoma, robotic thymectomy allows to realize all the principles and guidelines of the ITMIG (International Thymic Malignancy Interest Group).<sup>58</sup> The robotic surgeon should keep in mind that the approach could be easily modified or extended by an additional cervical incision, a bilateral procedure, or a hybrid approach with simple contralateral thoracoscopy before conversion to median sternotomy.<sup>23</sup>

**Conclusion**

The large increase of institutions performing robotic thymectomy reflects the increased acceptance of this approach by neurologists, surgeons, and their patients with MG and/or thymoma. The necessity of suitable credentialing for robotic surgery is combined with the question of the place for robotic surgery in the curriculum of thoracic surgery. Although there have been modifications of almost all conventional approaches and further inventions of new approaches for thymectomy, the strongest influence and the greatest future potential has come from robotic thymectomy.

**References**

- 1 Jaretzki A, Steinglass KM, Sonett JR. Thymectomy in the management of myasthenia gravis. *Semin Neurol* 2004;24(1):49–62
- 2 Rückert JC, Ismail M, Badakhshi H, Meisel A, Swierzy M. Thymectomy in myasthenia and/or thymoma. *Zentralbl Chir* 2014;139(1):121–132, quiz 133–134
- 3 Cooper JD, Al-Jilaihawa AN, Pearson FG, Humphrey JG, Humphrey HE. An improved technique to facilitate transcervical thymectomy for myasthenia gravis. *Ann Thorac Surg* 1988;45(3):242–247
- 4 Jaretzki A III, Penn AS, Younger DS, et al. “Maximal” thymectomy for myasthenia gravis. *Results. J Thorac Cardiovasc Surg* 1988;95(5):747–757
- 5 Masaoka A, Maeda M, Mori T, Kadota Y, Nakahara K. Follow-up study of the result of thymectomy in myasthenia gravis [in Japanese]. *Nippon Kyobu Geka Gakkai Zasshi* 1975;23(10):1210–1217
- 6 Budde JM, Morris CD, Gal AA, Mansour KA, Miller JJ Jr. Predictors of outcome in thymectomy for myasthenia gravis. *Ann Thorac Surg* 2001;72(1):197–202
- 7 Essa M, El-Medany Y, Hajjar W, et al. Maximal thymectomy in children with myasthenia gravis. *Eur J Cardiothorac Surg* 2003;24(2):187–189, discussion 190–191
- 8 Jaretzki A III, Wolff M. “Maximal” thymectomy for myasthenia gravis. *Surgical anatomy and operative technique. J Thorac Cardiovasc Surg* 1988;96(5):711–716
- 9 Masaoka A, Maeda M, Monden Y, Nakahara K, Tani Y. Distribution of the thymic tissue in the anterior mediastinum—studies on the

- methods of thymectomy [in Japanese]. *Nippon Kyobu Geka Gakkai Zasshi* 1975;23(8):1016–1021
- 10 Zielinski M, Kuzdzal J, Nabialek T. Transcervical-subxiphoid-VATS “maximal” thymectomy for myasthenia gravis. *Multimed Man Cardiothorac Surg* 2005;2005(425):000836
- 11 Papatestas AE, Genkins G, Kornfeld P. Comparison of the results of the transcervical and transsternal thymectomy in myasthenia gravis. *Ann N Y Acad Sci* 1981;377:766–778
- 12 Marx A, Müller-Hermelink HK. Thymoma and thymic carcinoma. *Am J Surg Pathol* 1999;23(6):739–742
- 13 Okumura M, Ohta M, Tomiyama N, Minami M, Hirabayashi H, Matsuda H. WHO classification in thymoma [in Japanese]. *Kyobu Geka* 2002;55(11):916–920
- 14 Gronseth GS, Barohn RJ. Thymectomy for Myasthenia Gravis. *Curr Treat Options Neurol* 2002;4(3):203–209
- 15 Schumacher ER. O. Thymektomie bei einem Fall von Morbus Basedowi mit. *Myasthenie: G. Fischer*; 1912
- 16 Masaoka A, Nagaoka Y, Kotake Y. Distribution of thymic tissue at the anterior mediastinum. *Current procedures in thymectomy. J Thorac Cardiovasc Surg* 1975;70(4):747–754
- 17 Masaoka A, Monden Y. Comparison of the results of transsternal simple, transcervical simple, and extended thymectomy. *Ann N Y Acad Sci* 1981;377:755–765
- 18 Shrager JB. Extended transcervical thymectomy: the ultimate minimally invasive approach. *Ann Thorac Surg* 2010;89(6):S2128–S2134
- 19 Kirschner PA, Osserman KE, Kark AE. Studies in myasthenia gravis. *Transcervical total thymectomy. JAMA* 1969;209(6):906–910
- 20 Marulli G, Rea F, Melfi F, et al. Robot-aided thoracoscopic thymectomy for early-stage thymoma: a multicenter European study. *J Thorac Cardiovasc Surg* 2012;144(5):1125–1130
- 21 Shrager JB, Deeb ME, Mick R, et al. Transcervical thymectomy for myasthenia gravis achieves results comparable to thymectomy by sternotomy. *Ann Thorac Surg* 2002;74(2):320–326, discussion 326–327
- 22 Rea F, Marulli G, Bortolotti L, Feltracco P, Zuin A, Sartori F. Experience with the “da Vinci” robotic system for thymectomy in patients with myasthenia gravis: report of 33 cases. *Ann Thorac Surg* 2006;81(2):455–459
- 23 Ismail M, Swierzy M, Rückert JC. State of the art of robotic thymectomy. *World J Surg* 2013;37(12):2740–2746
- 24 Freeman RK, Ascoti AJ, Van Woerkom JM, Vyverberg A, Robison RJ. Long-term follow-up after robotic thymectomy for nonthymomatous myasthenia gravis. *Ann Thorac Surg* 2011;92(3):1018–1022, discussion 1022–1023
- 25 Cerfolio RJ, Bryant AS, Minnich DJ. Starting a robotic program in general thoracic surgery: why, how, and lessons learned. *Ann Thorac Surg* 2011;91(6):1729–1736, discussion 1736–1737
- 26 Schneider D, Tomaszek S, Kestenholz P, et al. Minimally invasive resection of thymomas with the da Vinci® Surgical System. *Eur J Cardiothorac Surg* 2013;43(2):288–292
- 27 Yim AP, Kay RL, Ho JK. Video-assisted thoracoscopic thymectomy for myasthenia gravis. *Chest* 1995;108(5):1440–1443
- 28 Landreneau RJ, Dowling RD, Castillo WM, Ferson PF. Thoracoscopic resection of an anterior mediastinal tumor. *Ann Thorac Surg* 1992;54(1):142–144
- 29 Mack M, Landreneau R. Thoracoscopy for the Diseases of the Mediastinum Including Thymectomy for Myasthenia Gravis. *Semin Laparosc Surg* 1996;3(4):245–252
- 30 Sabbagh MN, Garza JS, Patten B. Thoracoscopic thymectomy in patients with myasthenia gravis. *Muscle Nerve* 1995;18(12):1475–1477
- 31 Rückert JC, Gellert K, Müller JM. Operative technique for thoracoscopic thymectomy. *Surg Endosc* 1999;13(9):943–946
- 32 Rückert JC, Gellert K, Einhäupl K, Müller JM. Thoracoscopic thymectomy for treatment of myasthenia gravis [in German]. *Zentralbl Chir* 1998;123(5):506–511

- 33 Rückert JC, Czyzewski D, Pest S, Müller JM. Radicality of thoracoscopic thymectomy—an anatomical study. *Eur J Cardiothorac Surg* 2000;18(6):735–736
- 34 Yoshino I, Hashizume M, Shimada M, et al. Thoracoscopic thymectomy with the da Vinci computer-enhanced surgical system. *J Thorac Cardiovasc Surg* 2001;122(4):783–785
- 35 Ashton RC Jr, McGinnis KM, Connery CP, Swistel DG, Ewing DR, DeRose JJ Jr. Totally endoscopic robotic thymectomy for myasthenia gravis. *Ann Thorac Surg* 2003;75(2):569–571
- 36 Augustin F, Schmid T, Sieb M, Lucciarini P, Bodner J. Video-assisted thoracoscopic surgery versus robotic-assisted thoracoscopic surgery thymectomy. *Ann Thorac Surg* 2008;85(2):S768–S771
- 37 Mulder DG. Extended transsternal thymectomy. *Chest Surg Clin N Am* 1996;6(1):95–105
- 38 Rückert JC, Ismail M, Swierzy M, et al. Thoracoscopic thymectomy with the da Vinci robotic system for myasthenia gravis. *Ann N Y Acad Sci* 2008;1132:329–335
- 39 Goldstein SD, Yang SC. Assessment of robotic thymectomy using the Myasthenia Gravis Foundation of America Guidelines. *Ann Thorac Surg* 2010;89(4):1080–1085, discussion 1085–1086
- 40 Marulli G, Rea F. Myasthenia gravis and thymectomy: many doubts and few certainties. *Eur J Cardiothorac Surg* 2014
- 41 Mussi A, Fanucchi O, Davini F, et al. Robotic extended thymectomy for early-stage thymomas. *Eur J Cardiothorac Surg* 2012;41(4):e43–e46, discussion e47
- 42 Castle SL, Kernstine KH. Robotic-assisted thymectomy. *Semin Thorac Cardiovasc Surg* 2008;20(4):326–331
- 43 Jun Y, Hao L, Demin L, Guohua D, Hua J, Yi S. Da Vinci robot-assisted system for thymectomy: experience of 55 patients in China. *Int J Med Robot* 2014;10(3):294–299
- 44 Tomulescu V, Sgarbura O, Stanescu C, et al. Ten-year results of thoracoscopic unilateral extended thymectomy performed in nonthymomatous myasthenia gravis. *Ann Surg* 2011;254(5):761–765, discussion 765–766
- 45 Marulli G, Schiavon M, Perissinotto E, et al. Surgical and neurologic outcomes after robotic thymectomy in 100 consecutive patients with myasthenia gravis. *J Thorac Cardiovasc Surg* 2013;145(3):730–735, discussion 735–736
- 46 Rückert JC, Swierzy M, Ismail M. Comparison of robotic and nonrobotic thoracoscopic thymectomy: a cohort study. *J Thorac Cardiovasc Surg* 2011;141(3):673–677
- 47 Jolly F. Ueber Myasthenia gravis pseudoparalytica. *Berliner Klinische Wochenschrift*, Nr.1. 01. Januar. 1895
- 48 Walker MB. Treatment of myasthenia gravis with physostigmine. *Lancet* 1934;1:1200–1201
- 49 Weigert C. Pathologisch-anatomischer Beitrag zur Erb'schen Krankheit (Myasthenia Gravis). *Neurol Centralbl* 1901;20:597–601
- 50 Wolff H, Baumann I. Myasthenia gravis: surgical treatment with thymectomy [in German; author's translation]. *Z Erkr Atmungsorgane* 1975;142(3):290–293
- 51 Mineo TC, Pompeo E, Ambrogi V. Video-assisted thoracoscopic thymectomy: from the right or from the left? *J Thorac Cardiovasc Surg* 1997;114(3):516–517
- 52 Landreneau RJ, Mack MJ, Hazelrigg SR, et al. Video-assisted thoracic surgery: basic technical concepts and intercostal approach strategies. *Ann Thorac Surg* 1992;54(4):800–807
- 53 Moorthy K, Munz Y, Dosis A, et al. Dexterity enhancement with robotic surgery. *Surg Endosc* 2004;18(5):790–795
- 54 Tomulescu V, Ion V, Kosa A, Sgarbura O, Popescu I. Thoracoscopic thymectomy mid-term results. *Ann Thorac Surg* 2006;82(3):1003–1007
- 55 Lococo F, Cesario A, Meacci E, Margaritora S, Granone P. Surgical treatment of myasthenia gravis: evident benefits and insidious pitfalls of mini-invasive techniques. *Ann Thorac Surg* 2013;96(4):1525
- 56 Jurado J, Javidfar J, Newmark A, et al. Minimally invasive thymectomy and open thymectomy: outcome analysis of 263 patients. *Ann Thorac Surg* 2012;94(3):974–981, discussion 981–982
- 57 Murthy SC. Niche for a technology or technology for a niche? *J Thorac Cardiovasc Surg* 2013;145(3):737
- 58 Detterbeck FC. The international thymic malignancy interest group. *J Natl Compr Canc Netw* 2013;11(5):589–593