

Step-Ladder Expansive Cranioplasty after Decompressive Craniotomy and Expansive Duraplasty: Discussing Possibilities on a Mathematical Model

S. K. Sengupta¹

¹Department of Neurosurgery (Surgical Ward III), Base Hospital Delhi Cantonment, New Delhi, India

Indian J Neurosurg 2015;4:15–21.

Address for correspondence Col (Dr.) S. K. Sengupta, MS, MCh, Department of Neurosurgery (Surgical Ward III), Base Hospital Delhi Cantonment, New Delhi 110010, India (e-mail: sudipkumarsengupta14@rediffmail.com).

Abstract

Background Role of decompressive craniectomy in reducing intracranial pressure is well established. However, it comes with a cost of requiring a second surgery in the form of cranioplasty without which unacceptable hemodynamic consequences occur. It is generally felt that a credible alternative is required.

Objective The aim of the study is to devise a mathematical model, which closely represents the cranium and intracranial contents, on which various alternatives can be evaluated with reproducible results, and to work out the effects of a novel technique of expansive cranioplasty on that model.

Methods A mathematical model was designed based on the presumption that dura forms a watertight bag-containing brain, floating in cerebrospinal fluid (CSF). A model for an expansive cranioplasty was designed, and its ability to provide the space required to allow volume expansion and to achieve adequate reduction in intracranial pressure (ICP) was evaluated on this model.

Results The mathematical model could closely reproduce the surface area–volume relationships in the published literature. Based on the calculations on the model, it was found that a projection of dural outpouching of 0.83 cm beyond the craniectomy margin on either side of a bilateral 12 × 15 cm elliptical craniectomy defect is required to achieve and accommodate a volume expansion of 157 cm³, which was recorded to be the maximum volume expansion in the reviewed literature. A two-step step-ladder cranioplasty can be constructed to achieve an increase in cranial width by 1.1 to 1.3 cm on each side.

Conclusion Calculations based on the present model indicate that a two-step expansive cranioplasty can accommodate adequate volume expansion while alleviating the ill effects of a craniectomy and necessity of a second surgery. However, these are discussions on mathematical model, based on multitude of assumptions and approximations, and hence these discussions require clinical trials to validate the findings.

Keywords

- ▶ decompressive craniotomy
- ▶ step-ladder expansive cranioplasty
- ▶ mathematical model



Introduction

Raised intracranial pressure (ICP) and the resultant decrease in cerebral perfusion pressure is the root cause of deterioration in various clinical settings of brain injury, which include those inflicted by traumatic and ischemic insults. Role of decompressive craniectomy in reducing ICP is well established.¹⁻³ However, it often requires a second surgery in the form of cranioplasty. Bone removal is known to give rise to complications in the form hydrocephalus and "syndrome of trephined."⁴ There is a felt necessity to look for other alternatives.

A mathematical model was designed, based on the laws of physics and solid geometry, to simulate the intracranial compartment and discuss the various effects of volume and pressure changes occurring in the event of craniectomy performed in the face of a raised ICP. Some of the observations of existing studies, which have been accepted universally and incorporated in neurosurgical practice, were studied on this model to derive certain relevant data, which are not available at present but are required to formulate new treatment strategies.

The volume expansion required to achieve adequate pressure reduction was noted from the existing widely accepted studies^{5,6} and a novel design of expansive craniectomy was assessed for its ability to accommodate the volume, thereby allowing a possibility of doing away with the second surgery for replacing the bone flap and avoiding the complications of sunken flap syndrome.

Methods

The Mathematical Model to Represent the Intracranial Compartment

A mathematical model was designed, based on the presumption that dura forms a watertight bag-containing brain floating in CSF, which is again reconstituted once a dural closure has been achieved. For this study, the dural bag has been presumed to be hemispherical in shape, with the flat circular surface of the hemisphere lying over the base of the skull (→Fig. 1A). Volume of a hemisphere is $\frac{2}{3}\pi R^3$, where R is the radius of the sphere, of which the hemisphere has been carved out. Considering the intracranial volume to be approximately of 1,500 mL,^{7,8} R would work out to be 8.945 cm (a value of 9 cm has been used for the subsequent calculations).

On the basis of Pascal law, it can be stated that the ICP is exerted equally on the dural bag tangentially all over its wall, always trying to expand it outward (→Fig. 1A). Any expansion in the size of the dural bag is, however, prevented by the intact rigid cranium around it. A craniectomy defect can be circular, rectangular, or oval in shape. The defect with a given surface area, of any shape, has been represented in the model by a circular area of equal surface area, having a radius r_1 (→Fig. 1B). The maximum distance of the imaginary horizontal line drawn at the level of the craniectomy defect to the normal location of the dura in unoperated skull, obtained by drawing a perpendicular from the center of the imaginary sphere representing the

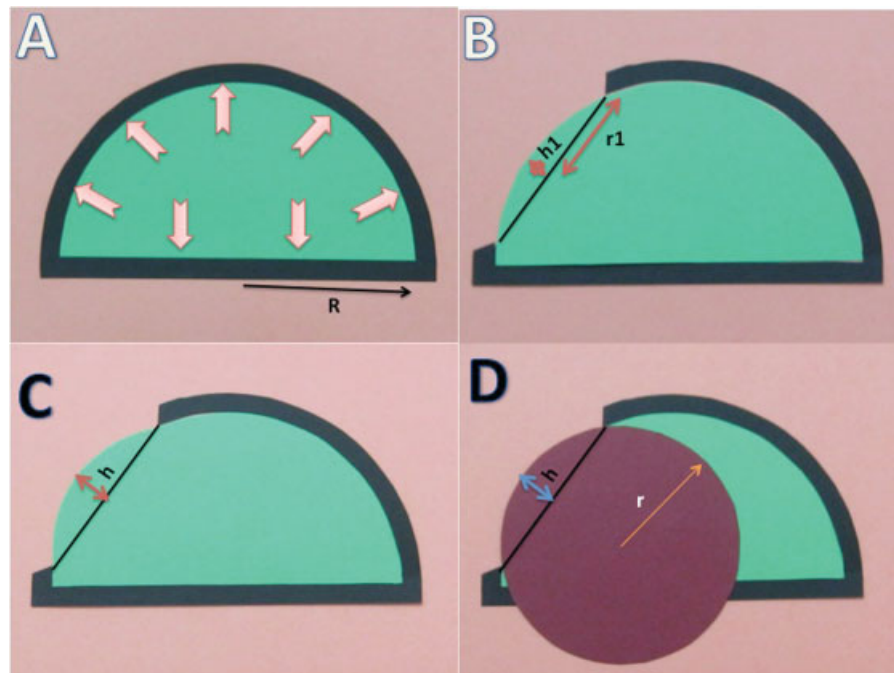


Fig. 1 (A) Black border represents the skull and green area represents the hemispherical intracranial dural bag with radius R . Pink arrows indicate the direction of forces acting outward on the dural bag. (B) Craniectomy defect of radius r_1 , maximum distance of the inner table from an imaginary line drawn at the level of the craniectomy defect being h_1 . (C) After volume augmentation of the dural sac at the craniectomy site the maximum projection of the dural sac beyond the craniectomy margin h . (D) The hemispheric projection of the dural sac beyond the craniectomy margin can be considered be a section of another imaginary sphere of diameter r .

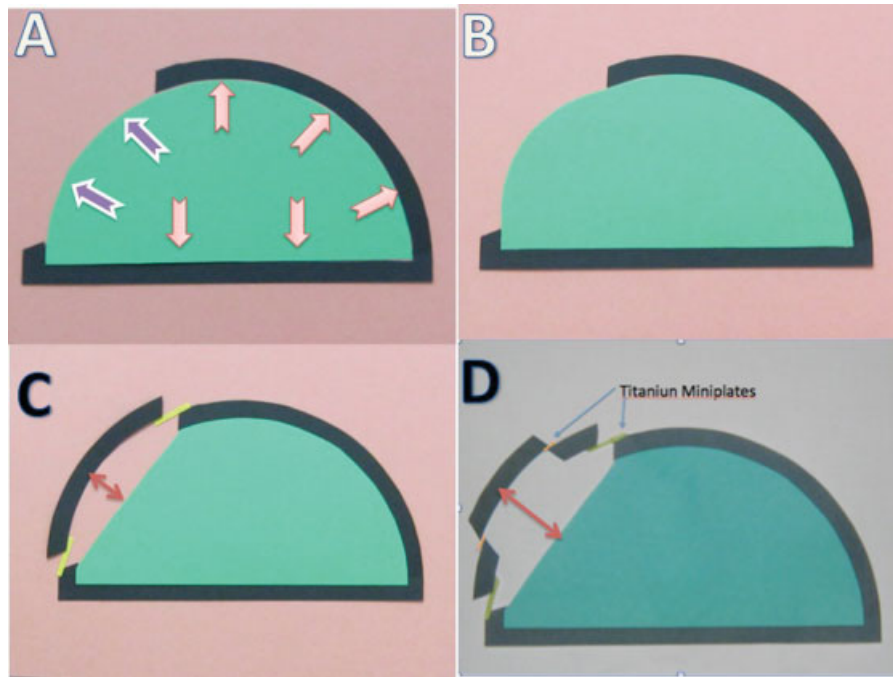


Fig. 2 (A) Black border represents the skull and green area represents the hemispherical intracranial dural bag. At the craniectomy site, the dura is exposed to the intracranial pressure, purple arrows indicating the vector of forces that can work on the dura effectively stretching it. (B) Volume expansion of the dural bag at the craniectomy site. (C) A single-step step-ladder expansive cranioplasty constructed by fixing the free bone flap and the cranium on the two opposite surfaces of a titanium miniplate. The double-headed arrow indicates the distance from the center of the craniectomy defect to the pole of the inner table of the cranioplasty construct. (D) A double-step step-ladder expansive cranioplasty.

craniectomy defect to the pole, is represented in the model by h_1 .

$$h_1 = R - \sqrt{R^2 - r_1^2} \quad (1)$$

The volume of the part of the dural sac (E), without any stretching, calculated from the edge of the defect is

$$2/3 \pi r_1^2 h_1 \quad (2)$$

The outpouching of the dural bag, after a dural closure has been achieved (►Fig. 1C), has been considered to be represented by a section of an imaginary sphere with a radius r (►Fig. 1D). The maximum distance of the dural outpouching from the craniectomy margin is represented by h .

Whenever a craniectomy is done, the vector of forces become free to stretch the dural bag over the portion of the craniectomy defect (►Fig. 2). Because the pressure exerted at each point is equal, this is expected to cause a spherical outpouching. It is the volume of this outpouching that will determine the volume expansion achieved and will require to be accommodated by an expansive craniectomy technique.

For a circular craniectomy defect (►Fig. 1) of known size (r_1) and volume (V), maximum distance of the sac from the craniectomy margin (h) can be calculated by the formula

$$h = 3V/2\pi r_1^2 \quad (3)$$

The projection of the dural bag beyond the preoperative dural limit

$$(H) = h - h_1 \quad (4)$$

The relationship of r_1 to the r (the radius of the sphere of which this outpouching is a part) is given by the formula

$$r = (r_1^2 + h_1^2)/2h_1 \quad (5)$$

Designing Expansive Cranioplasty

A craniectomy procedure aims to increase the available intracranial volume, thereby reducing the ICP. Literature review was done to find out the median volume expansion achieved after craniectomy in series with satisfactory ICP reduction and maximum volume expansion achieved among all the studies in which volume expansion has been documented after craniectomy procedures. To accommodate this additional volume, the projection of the dural bag required to take place, beyond the preoperative state, was calculated for different craniotomy size. A step-ladder pattern cranioplasty technique, in which the free bone flap and the craniectomy edge are fixed on two opposite surfaces of titanium miniplates (►Fig. 3), was evaluated for its applicability.

Results

Considering the volume of the cranial contents to be 1,500 cm^3 , it can be represented by a hemisphere of 9 cm radius.

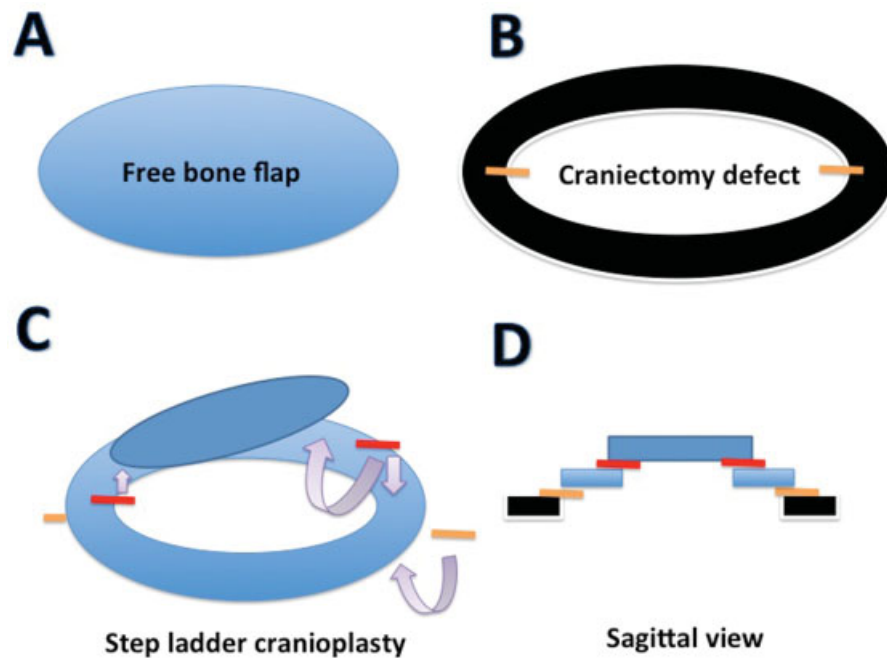


Fig. 3 Step-ladder expansive cranioplasty. (A) Free bone flap. (B) Black line representing the craniectomy margin with the white central portion representing the craniectomy defect. Titanium miniplates, represented by the yellow lines, are fixed on the outer surface of the cranium with screws. (C) A central portion of the free bone flap has been removed leaving a ring of 1.5 cm width. Miniplates fixed to the outer surface of the cranium are fixed to the inner surface of the bony ring. A second set of titanium miniplates, represented by red lines, are fixed to the outer surface of the bony ring on one end and to the inner surface of the bony inner disc on the other end. Arrows indicating the directions to fix the miniplates. (D) Sagittal section of the construct.

The results have been summarized in ►Table 1.

1. Conversion of elliptical craniectomy defects of different surface area in the published studies to equivalent circular defects in the present model.
 - (a) An elliptical craniectomy defect of 12×15 cm has a surface area of 141.42 cm^2 ; an equivalent circular defect of equal surface area will have a diameter of 13.4 cm.
 - (b) An elliptical craniectomy defect of 12×08 cm has a surface area of 75.42 cm^2 ; an equivalent circular defect of equal surface area will have a diameter of 9.79 cm.
 - (c) A craniectomy defect of 67.9 cm^2 will be represented by a circular defect of 9.29 cm diameter.
2. Measurements of dural sac at the craniectomy site.
 - (a) Maximum distance from the line joining the craniectomy margins to the outer margin of unexpanded dura (h_1):
 - For a 13.4-cm diameter circular (equivalent to 12×15 cm elliptical) craniectomy defect: 3.00 cm.
 - For a 9.79-cm diameter circular (equivalent to 12×08 cm elliptical) craniectomy defect: 1.45 cm.
 - For a 67.9-cm^2 (9.29-cm diameter circular) craniectomy defect: 1.3 cm.
 - (b) For an additional volume of 124 cm^3 , to be accommodated, the required increase in the height of the dural pouch projecting from craniectomy defects ($h - h_1$):

- For a 13.4-cm diameter circular (equivalent to 12×15 cm elliptical) craniectomy defect: 1.32 cm.
 - For a 9.79-cm diameter circular (equivalent to 12×08 cm elliptical) craniectomy defect: 2.47 cm.
 - For a 67.9-cm^2 (9.29 cm diameter circular) craniectomy defect: 2.74 cm
- (c) For an additional volume of 157.6 cm^3 , to be accommodated, the required increase in the height of the dural pouch projecting from craniectomy defects ($h - h_1$):
 - For a 13.4-cm diameter circular (equivalent to 12×15 cm elliptical) craniectomy defect: 1.67 cm.
 - (d) For an additional volume of 157.6 cm^3 , to be accommodated in a bilateral hemicraniectomy, in which each side has to accommodate a volume expansion of 78.8 cm^3 , the required increase in the height of the dural pouch projecting from craniectomy defects ($h - h_1$):
 - For a 13.4-cm diameter circular (equivalent to 12×15 cm elliptical) craniectomy defect: 0.83 cm.
 - (e) For an additional volume of 124 cm^3 , to be accommodated in a bilateral hemicraniectomy, in which each side has to accommodate a volume expansion of 62 cm^3 , the required increase in the height of the dural pouch projecting from craniectomy defects ($h - h_1$):
 - For a 9.79-cm diameter circular (equivalent to 12×8 cm elliptical) craniectomy defect: 1.23 cm

Table 1 Comparative analysis of relationship of craniectomy surface area and height of the dural outpouching with the volume expansion achieved on the mathematical model and existing literature

Sl. no.	Ref.	No. of cases in the study	Surgery performed	Size of craniectomy		Volume expansion (cm ³)	Height of the dural outpouching (cm)		
				Surface area recorded in the study (cm ²)	Corresponding diameter in our model (2 × r ₁) (cm)		Recorded in the study	Calculated in the model based on vol expansion (h)	Depth till inner table as on the model (h ₁)
1	Munch et al	49	Unilateral FTP D/C with Exp duraplasty	67.9 ± 15.5 Mean 67.9 Maximum 83.4	9.296 10.302	92.6 ± 65 92.6 157.6 ^a	0.790 2.045 2.834	1.29 1.62	2.045 2.834
2	Cavuşoğlu et al	33	FTP D/C with Exp duraplasty	Median 67.9 Maximum 113	9.295 11.992	67.5 107.2	2.78 3.70	1.29 2.28	1.492 1.423
3	Olivecrona et al	93 21 underwent D/C	Unilateral D/C 88 ± 7 Bilateral D/C 116 ± 11	Median 88 Maximum 95 Median 116 Maximum 127	10.582 10.994 12.15 12.71	98 109 124 ^b 138		1.720 1.874 2.360 2.629	1.670 1.721 1.603 1.630
Calculations on the mathematical model									
			Surface area		Diameter of equivalent circular defect		Desired volume expansion		
1	Unilateral FTP D/C 12 × 15 cm oval craniectomy		141.42 cm ²		13.4 cm		157.6 cm ³ 124 cm ³	3.0	1.67 1.31
2	Unilateral FTP D/C 12 × 8 cm oval craniectomy		75.42 cm ²		9.79 cm		124 cm ³	1.45	1.37

Abbreviations: D/C, decompressive hemicraniectomy; Exp, expansive; FTP, frontotemporoparietal.

Notes: All entries in red represent calculations made over the mathematical model. Entries in black represent findings in various published studies.

^aMaximum volume expansion for unilateral D/C in reviewed literature.

^bMedian volume expansion in a study with positive outcome.

- For a 67.9-cm² (9.29 cm diameter circular) craniectomy defect: 1.37 cm.
- (f) If an expansive cranioplasty is constructed, widening the craniectomy site by 1 cm, it can allow a volume expansion of:
- For a 13.4-cm diameter circular (equivalent to 12 × 15 cm elliptical) craniectomy defect: 94 cm³.
 - For a 9.79-cm diameter circular (equivalent to 12 × 8 cm elliptical) craniectomy defect: 50 cm³.

Discussion

Raised ICP and the resultant decrease in cerebral perfusion pressure is the root cause of deterioration in various clinical settings of brain injury. The fact that decompressive craniectomy effectively reduces ICP is well established.^{1-3,9}

Some of the problems that crop up after craniectomy, which offset the obvious advantages of the procedure, thereby annulling the benefits accrued by opening the cranium and reduction in ICP, are postcraniectomy cerebral edema,^{10,11} derangements of cerebral autoregulation, infarct of the prolapsed brain parenchyma, intracerebral hemorrhages,¹² and sunken flap syndrome.

Efforts have been made to alleviate some of these problems by resorting to various alternative, novel surgical techniques,¹³⁻¹⁵ and modifications^{16,17} with varied amount of success; however, neither have they gained universal acceptance nor have they been able to take care of all the drawbacks. A wide durotomy and expansive duraplasty have been advocated to accommodate the surplus brain volume caused by the postoperative edema¹⁸ in view of the perceived inevitability of the postcraniectomy cerebral edema.

The postcraniectomy complications can be broadly divided into two groups. First set of complications are due to bone flap removal, namely, sunken flap syndrome and postcraniectomy hydrocephalus. The second set of complications are secondary to the hemodynamic changes brought about by dural opening, namely, postoperative cerebral edema, kinking of cerebral veins, and infarct. First set of complications could be avoided if it was possible to develop a technique of expansive cranioplasty, creating required additional space to accommodate desired volume expansion, while replacing the bone flap on completion of surgery.

Experimenting on these concepts in clinical settings, while established alternatives exist, is unethical at the best. Therefore, a mathematical model was created to juggle with the available information and finally a cranioplasty design was created on this model that would allow adequate volume expansion.

Three studies were found in the literature that compared the craniectomy size with the volume expansion achieved.^{5,6,18} Although 82 cases of unilateral decompressive craniectomy were reported by Munch et al and Cavuşoğlu et al, 22 operated cases reported by Olivecrona et al underwent either unilateral or bilateral

craniectomy based on their computed tomography (CT) findings. The maximum craniectomy size reported for an unilateral surgery was 113 cm². Largest among the three studies was by Munch et al with 49 cases with a mean craniectomy size of 67.9 cm² and a mean volume expansion of 92.6 cm³. In their study, the maximum craniectomy size was recorded to be 83.4 cm² and the maximum volume expansion achieved was 157.6 cm³. The study by Olivecrona et al showed encouraging results with decompressive hemicraniectomy for cases of severe traumatic head injury with resistant raised ICP, a maximum volume expansion of 127 cm³, and an ICP reduction by 41%.

Calculations on the mathematical model showed that a volume expansion of 46.1, 67.5, and 107.2 cm³ achieved over craniectomy defects of 51.5, 67.9, and 113 cm², respectively, will require the dural outpouchings to project 2.3, 2.78, and 3.70 cm beyond the craniectomy margin. These measurements were similar to the findings recorded in the study by Cavuşoğlu et al.⁵

Mathematical calculations on the model showed that a projection of dural outpouching of 1.32 cm beyond the craniectomy margin of a unilateral 12 × 15 cm elliptical craniectomy defect is required to achieve and accommodate a volume expansion of 124 cm³, which was recorded to be the mean volume expansion in the study published by Olivecrona et al, reporting a positive outcome of the study. A projection of dural outpouching of 0.83 cm beyond the craniectomy margin on either side of a bilateral 12 × 15 cm elliptical craniectomy defect is required to achieve and accommodate a volume expansion of 157 cm³, which was recorded to be the maximum volume expansion in the study published by Munch et al and is by far the maximum volume expansion recorded in any study after a unilateral decompressive hemicraniectomy performed by the standard technique. Considering the thickness of the bones at the anterior and posterior margins of a craniectomy defect to be 5 to 6 mm and the width of the miniplates 0.5 mm, a step-ladder cranioplasty can be constructed to achieve an increase in cranial width by 1.1 to 1.3 cm on each side. The width can be increased further by drilling out a circular area of inner table and dipole from the center of the bone flap by 2 to 3 mm. Performing a three-step step-ladder cranioplasty or leaving a craniectomy defect of 3 cm diameter at the center of the bone flap can also be considered as alternatives. A two-step step-ladder cranioplasty with a gain of 1.0 cm width can, in a bilateral 12 cm × 15 cm elliptical craniotomy and expansive cranioplasty, accommodate 184 cm³ of additional volume, and can effectively allow more ICP reduction by taking the inward pressure of the tensile strength of the scalp flap off the dural pouch.

Conclusion

Calculations based on the present model indicate that a two-step step-ladder expansive cranioplasty can provide ample space to accommodate the extra volume created by an expansive duraplasty, if the craniectomy is large (12 × 15 cm) and performed bilaterally.

However, it is just a mathematical model, based on multitude of assumptions and approximations, and hence cannot be taken on the face value. If the logics forwarded, after critical review by the neuroscientists, gain some acceptance, various components of the study can be tested in animal models and in suitable, very selective clinical settings.

Disclosure

None to declare.

References

- 1 Jiang JY, Xu W, Li WP, et al. Efficacy of standard trauma craniectomy for refractory intracranial hypertension with severe traumatic brain injury: a multicenter, prospective, randomized controlled study. *J Neurotrauma* 2005;22(6): 623–628
- 2 Bao YH, Liang YM, Gao GY, Pan YH, Luo QZ, Jiang JY. Bilateral decompressive craniectomy for patients with malignant diffuse brain swelling after severe traumatic brain injury: a 37-case study. *J Neurotrauma* 2010;27(2):341–347
- 3 Yoo DS, Kim DS, Cho KS, Huh PW, Park CK, Kang JK. Ventricular pressure monitoring during bilateral decompression with dural expansion. *J Neurosurg* 1999;91(6):953–959
- 4 Yamaura A, Makino H. Neurological deficits in the presence of the sinking skin flap following decompressive craniectomy. *Neurol Med Chir (Tokyo)* 1977;17(1, Pt 1):43–53
- 5 Cavaşoğlu H, Kaya RA, Türkmenoğlu ON, Aydin Y. Value of early unilateral decompressive craniectomy in patients with severe traumatic brain injury. *Ulus Travma Acil Cerrahi Derg* 2010; 16(2):119–124
- 6 Münch E, Horn P, Schürer L, Piepgras A, Paul T, Schmiedek P. Management of severe traumatic brain injury by decompressive craniectomy. *Neurosurgery* 2000;47(2):315–322, discussion 322–323
- 7 Strik HM, Borchert H, Fels C, et al. Three-dimensional reconstruction and volumetry of intracranial haemorrhage and its mass effect. *Neuroradiology* 2005;47(6):417–424
- 8 Blatter DD, Bigler ED, Gale SD, et al. Quantitative volumetric analysis of brain MR: normative database spanning 5 decades of life. *AJNR Am J Neuroradiol* 1995;16(2):241–251
- 9 Whitfield PC, Patel H, Hutchinson PJ, et al. Bifrontal decompressive craniectomy in the management of posttraumatic intracranial hypertension. *Br J Neurosurg* 2001; 15(6):500–507
- 10 Cooper PR, Hagler H, Clark WK, Barnett P. Enhancement of experimental cerebral edema after decompressive craniectomy: implications for the management of severe head injuries. *Neurosurgery* 1979;4(4):296–300
- 11 Lobato RD, Sarabia R, Cordobes F, et al. Posttraumatic cerebral hemispheric swelling. Analysis of 55 cases studied with computerized tomography. *J Neurosurg* 1988;68(3):417–423
- 12 Stiver SI. Complications of decompressive craniectomy for traumatic brain injury. *Neurosurg Focus* 2009;26(6):E7
- 13 Schmidt JH III, Reyes BJ, Fischer R, Flaherty SK. Use of hinge craniotomy for cerebral decompression. Technical note. *J Neurosurg* 2007;107(3):678–682
- 14 Mitchell P, Tseng M, Mendelow AD. Decompressive craniectomy with lattice duraplasty. *Acta Neurochir (Wien)* 2004;146(2): 159–160
- 15 Csókay A, Pataki G, Nagy L, Belán K. Vascular tunnel construction in the treatment of severe brain swelling caused by trauma and SAH. (evidence based on intra-operative blood flow measure). *Neurol Res* 2002;24(2):157–160
- 16 Alves OL, Bullock R. “Basal durotomy” to prevent massive intra-operative traumatic brain swelling. *Acta Neurochir (Wien)* 2003; 145(7):583–586, discussion 586
- 17 Wang Y, Wang C, Yang L, et al. Controlled decompression for the treatment of severe head injury: a preliminary study. *Turk Neurosurg* 2014;24(2):214–220
- 18 Olivecrona M, Rodling-Wahlström M, Naredi S, Koskinen LO. Effective ICP reduction by decompressive craniectomy in patients with severe traumatic brain injury treated by an ICP-targeted therapy. *J Neurotrauma* 2007;24(6):927–935