

Management of the Eye in Facial Paralysis

Mahsa Sohrab, MD¹ Usiwoma Abugo, MD² Michael Grant, MD, PhD¹ Shannath Merbs, MD, PhD¹

¹Wilmer Eye Institute, Johns Hopkins University School of Medicine, Baltimore, Maryland

²Department of Ophthalmology, Howard University Hospital, Washington, District of Columbia

Address for correspondence Shannath Merbs, MD, PhD, Wilmer Eye Institute, Johns Hopkins University School of Medicine, Baltimore, MD 21205 (e-mail: smerbs@jhmi.edu).

Facial Plast Surg 2015;31:140–144.

Abstract

Facial nerve palsy, whether the cause is idiopathic, or following such insults as surgery, trauma, or malignancy, places the health of the ocular surface at risk. Reduced or absent orbicularis oculi function results in lagophthalmos and exposure of the cornea, which is exacerbated by eyelid malposition. Management of the exposure keratopathy is paramount to prevent corneal breakdown, scarring, and permanent vision loss. Significant exposure keratopathy can be complicated by loss of corneal sensation, leading to a neurotrophic corneal ulcer. Initial management consists of artificial tear drops and ointment for corneal lubrication and strategies to address the lagophthalmos. Once the condition of the ocular surface has been stabilized, a variety of surgical treatment options are available depending on the severity and persistence of eyelid and ocular findings. The most common surgical options include temporary or permanent tarsorrhaphy for lagophthalmos, upper eyelid weight placement for retraction, and lateral canthoplasty with or without a middle lamellar spacer for lower eyelid retraction. External eyelid loading is a good option in patients who are poor surgical candidates or who have a known temporary palsy of short duration. The goal of all such procedures must be protection of the ocular surface through optimization of eyelid position.

Keywords

- ▶ facial paralysis
- ▶ exposure keratopathy
- ▶ lagophthalmos
- ▶ eyelid retraction
- ▶ paralytic ectropion

Proper evaluation and management of eyelid-related abnormalities in patients with facial nerve palsy and ocular surface disease are essential to preserve the structure and function of the eye. Decreased blink reflex and partial eyelid closure due to weakening or complete paresis of the orbicularis oculi muscle can lead to progressive exposure keratopathy, which can ultimately cause loss of vision due to corneal scarring or perforation. Secondary problems can include epiphora, eyelid retraction, paralytic ectropion, and cosmetic deformity. Decision making regarding the need for and timing of surgical intervention varies depending on the cause of the palsy, the degree of neural injury, the location of the injury, the patient age, and the clinical setting. Furthermore, the severity of any ocular findings mediates the urgency of medical or surgical interventions. The primary management goal must always be centered on protection of the corneal surface and maintenance visual acuity.^{1–6}

Clinical Evaluation

The assessment of a patient with facial nerve palsy begins with a thorough history. When possible, the cause of the palsy must be elicited for targeted therapy. The most common infectious causes include history of herpes zoster or Lyme disease. Postsurgical or iatrogenic changes are often the sequelae of tumor resection, including parotid tumors and acoustic neuromas and can even occur after blepharoplasty or rhytidectomy. Other causes include traumatic injuries such as temporal bone fractures and congenital anomalies.^{1,5} Reported symptoms such as burning, redness, tearing, or foreign body sensation of the eye should be noted. The anticipated duration of the paralysis must be ascertained. The current medication regimen, including ocular history and use of topical medications, should be documented.

A complete ophthalmic evaluation of all patients with facial nerve palsy is essential, beginning with baseline visual

acuity. External examination should include assessment and grading of orbicularis strength, the amount of lagophthalmos, as well as the presence or absence of an intact Bell phenomenon. The eyelid position in relation to the globe should be noted, including any evidence of lower eyelid retraction and/or ectropion (►Fig. 1A), as well as upper eyelid retraction from the unopposed action of the levator muscle, which can be masked by severe brow ptosis. The height of the tear lake and position of the lower eyelid punctum should be evaluated. Documenting the presence of conjunctival hyperemia/chemosis and corneal sensation is especially important, followed by a conjunctival and corneal examination with fluorescein staining to identify any evidence of epithelial erosions, scarring, or ulceration (►Fig. 1B).

Management

One of the most important determinants of appropriate medical or surgical intervention in patients with orbicularis oculi paresis due to facial nerve palsy is whether the paralysis is expected to be temporary or permanent. Temporary paresis can often be managed with more conservative measures such as topical lubrication of the eye, whereas permanent paresis more often than not necessitate surgical treatment of upper and lower eyelid malposition.

Medical Therapies

Temporary treatments focus on supportive therapy to protect the ocular surface as facial nerve function is gradually regained.²⁻⁶ Lubricating drops consisting of preservative-free methylcellulose can be initiated three to four times daily to prevent or treat superficial keratopathy. The frequency can be increased as needed or thicker gel formulations can be used. Several approaches can help manage lagophthalmos at night. A petroleum-based artificial tear ointment, typically a combination of mineral oil and petroleum jelly, is best for overnight use. Taping the upper eyelid shut can be helpful to protect the eye overnight, preventing exposure and trauma. However, careful taping instructions must be provided so as to minimize the risk of abrasive corneal trauma, and patients must understand that simply putting some sort of patch over the eye will not necessarily result in eyelid closure and may do

more harm. Patients in whom taping is unsuccessful or in whom dermatitis develops from the tape may benefit from a moisture chamber created with a cellophane patch sealed to the skin with a ring of petroleum jelly.

In patients with upper eyelid retraction from the unopposed action of the levator muscle, daytime lagophthalmos can be managed temporarily with external eyelid weights,^{7,8} which are produced in various colors to match different patient skin tones (Blinkeze External Lid Weights, MedDev Corporation, Sunnyvale, CA). These weights are made of pure tantalum, a dense, inert material with high biocompatibility. Weights are available in 0.2 g increments ranging from 0.6 to 2.8 g and are attached to the pretarsal eyelid skin using adhesive strips. Complications can include contact dermatitis from the adhesive, induced astigmatism, or ocular irritation from inadequate weight size.^{7,8} Patients in whom facial nerve recovery is anticipated can also benefit from a protective ptosis induced by an injection of botulinum toxin type A into the levator muscle.^{5,9} After eversion of the upper eyelid, 5 U of botulinum toxin A in 0.1 mL can be injected transconjunctivally several millimeters above the top of the tarsus. The ptosis resolves in approximately 6 weeks. Paralytic ectropion of the lower eyelid can often be temporarily supported by a thin strip of tape (►Fig. 2A).

Surgical Therapies

Tarsorrhaphy

Classically, the surgical management of keratopathy resulting from lagophthalmos after facial nerve palsy has been a temporary or permanent tarsorrhaphy (►Fig. 2B), which can be performed by several techniques.^{1-6,10} A temporary tarsorrhaphy needed for 1 to 2 weeks can be created using a 6-0 nylon suture passed in a mattress fashion partial thickness superiorly and inferiorly through skin and orbicularis oculi muscle, entering and exiting the eyelid margin at the gray line. The suture can be tied over bolsters if the tarsorrhaphy is needed for more than 2 weeks. For long-term management, a permanent but reversible tarsorrhaphy can be created by de-epithelializing the eyelid margin and joining the upper and lower eyelid margins with interrupted 6-0 polyglactin 910 sutures partial thickness through the tarsus supported with 6-0 nylon sutures partial thickness

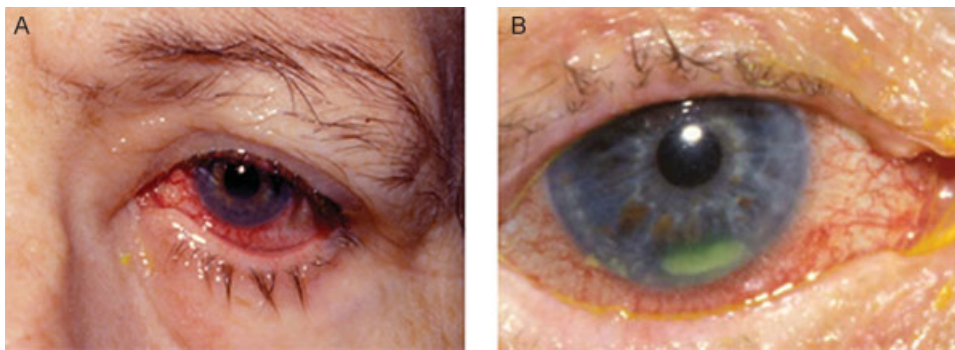


Fig. 1 Ophthalmic manifestations of facial nerve palsy. (A) Brow ptosis, lower eyelid retraction and ectropion and severe conjunctival injection. The absence of upper eyelid retraction in this patient precludes the need for or usefulness of an upper eyelid weight. (B) Lagophthalmos and lower eyelid retraction has resulted in exposure keratopathy and a corneal epithelial defect highlighted by fluorescein staining.

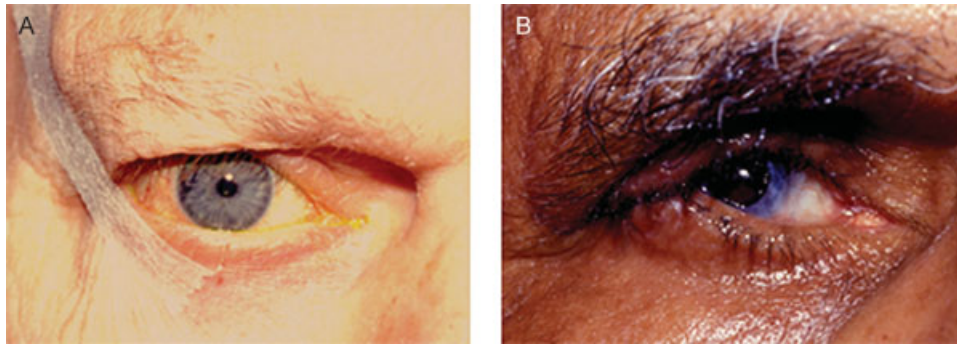


Fig. 2 Treatment of lagophthalmos in the setting of facial nerve palsy. (A) Tape is used to temporarily support the paralytic ectropion of the lower eyelid until a more permanent solution can be achieved. (B) Permanent and reversible tarsorrhaphy by intramarginal adhesions.

superiorly and inferiorly through skin and orbicularis oculi muscle left in for 1 to 2 weeks. Care should be taken not to incorporate any lashes into the tarsorrhaphy, which could lead to a mechanical keratopathy requiring an unintended reversal of the tarsorrhaphy. Although tarsorrhaphies are useful for patients with significant corneal thinning or in whom the risk of perforation is great, and in those patients who are not candidates for more aggressive or staged therapies, they have limitations and disadvantages. These include poor cosmesis and reduction of the temporal visual field, making them less popular in the long-term management of lagophthalmos from facial nerve palsy.

Upper Eyelid

Retraction of the upper eyelid occurs as the result of unopposed levator palpebrae superioris action. Surgical treatment of upper eyelid retraction in the setting of facial palsy involves upper eyelid loading by adding weights to the upper eyelid and using gravitational forces to move the eyelid downward. For many years, rigid gold weights were the recommended eyelid loading material.^{11,12} Many studies have reported improvement in lagophthalmos, keratopathy, visual acuity, and cosmesis after the placement of upper eyelid gold weights, with good patient satisfaction. Recently, the use of platinum has been advocated as an alternative to gold.^{13,14} Platinum has a reduced allergic response and is denser than gold, which allows for the use of smaller implants of the same weight and a lower risk of extrusion. Although low-profile rigid weights are available,¹⁴ a flexible platinum/iridium chain implant is now available (Spiggle & Theis GmbH, Dieburg, Germany), which is thought to adapt better to the shape of the upper eyelid tarsus.^{13,15}

Weights are most commonly attached to the tarsal plate for greater stability¹⁶ and are curved to conform to the natural contour to the eyelid. Though the weight amount must be individualized, it generally varies from 0.8 to 1.4 g, with most patients achieving sufficient results using less than 1.2 g. The appropriate weight is determined during a preoperative evaluation. A trial weight or sizing weight is attached to the upper eyelid using adhesive tape and eyelid closure is observed. The minimum weight allowing for downward movement of the upper eyelid to within 2 to 4 mm of the lower eyelid should be selected, while avoiding excessive ptosis (►Fig. 3).^{3,17} The implant can be placed under local

anesthesia or with sedation. An incision is made in the skin along the upper eyelid crease. An implant pocket is made deep to the orbicularis oculi muscle but superficial to the tarsal plate. Correct implant placement is crucial, with the implant centered over the pupil and placed over the superior half of the tarsal plate to avoid visibility after the operation.¹⁸ When placed optimally, the implant should not be visible when the eye is open (►Fig. 4).

Complications of upper eyelid weight placement include ptosis, irregular eyelid contour, extrusion, and gold allergy.¹⁸ The efficacy of upper eyelid weights is dependent on head position as well as the globe size and position. They tend to be most effective when the head is in the upright position and gravitational forces are optimal. As the head reclines, the vector changes and the degree of eyelid closure decreases, with loss of efficacy beginning approximately at a 45-degree incline.² It is important to recognize that the upper eyelid weight does not initiate an involuntary blink and only serves to load the upper eyelid; thus, it is best used for those patients with upper eyelid retraction, in whom the induced ptosis returns the upper eyelid to a normal position or in those patients with a partial involuntary blink in which the weight helps complete the blink.

Lower Eyelid

Orbicularis weakness or paralysis in a facial palsy patient gives rise to an atonic lower eyelid and the accompanying problems that occur with a static lower eyelid position. Tension on the anterior lamella of the lower eyelid from the facial droop causes lower eyelid retraction, and in older patients with a greater horizontal laxity, causes a paralytic ectropion (►Fig. 1A). Several surgical approaches are used to correct lower eyelid malposition. Excessive horizontal laxity of the eyelid, particularly common in older patients, can be treated with lateral canthoplasty; however, lateral canthoplasty alone is often insufficient to treat lower eyelid retraction. A common mistake is elevating the lateral canthal position higher than normal in an attempt to elevate the central and nasal aspects of the retracted lower eyelid. This can lead to further retraction in the case of a relatively proptotic eye or to a compromised upper eyelid position and an abnormal appearance (►Fig. 5). Either a midface resuspension or sub-orbicularis oculi fat (SOOF) lift, or the addition of a middle lamellar spacer, particularly in patients with relatively proptotic eyes, is required to provide eyelid support.

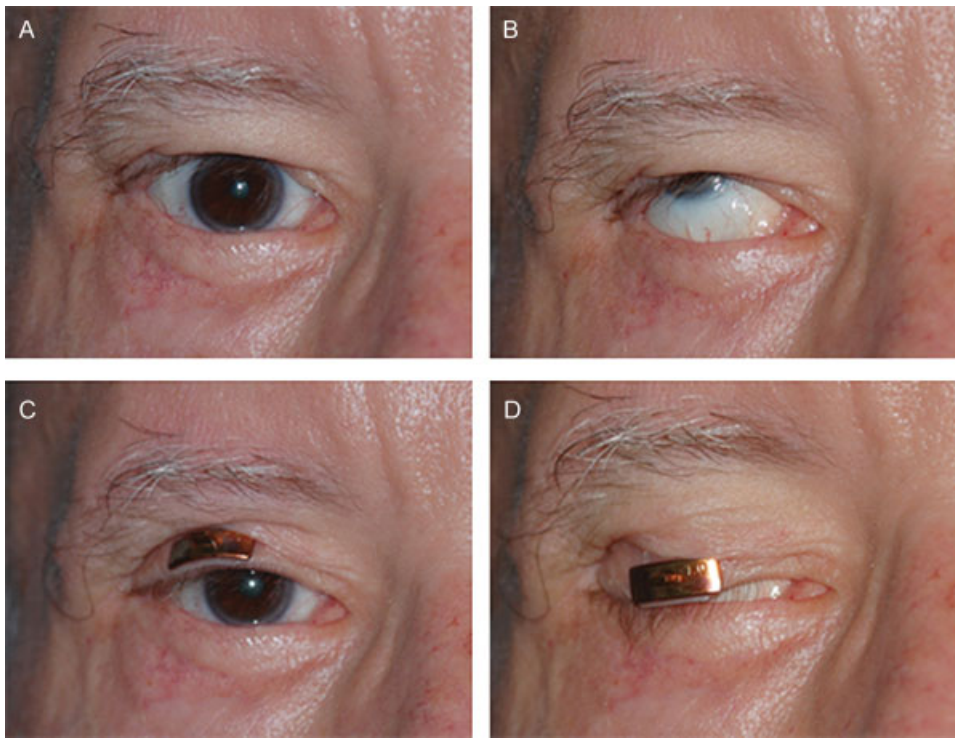


Fig. 3 Management of upper eyelid retraction secondary to facial nerve palsy. (A) Baseline upper eyelid retraction partially obscured by significant brow ptosis. (B) Lagophthalmos from no upper eyelid movement with forced closure; however, a good Bell phenomenon is present. (C) Temporary adhesion of a 1.0 g weight to the upper eyelid eliminates the upper eyelid retraction and (D) reduces the degree of lagophthalmos on forced closure.

Lateral tarsal strip surgery is the mainstay of horizontal eyelid shortening.¹⁹ After lateral canthotomy and inferior cantholysis are performed, the extent of lateral movement of the lower eyelid is determined to estimate adequate horizontal tightening. A subciliary incision is used to dissect skin and orbicularis off of the intended lateral strip. The tarsal strip is de-epithelialized, including removal of the eyelash follicles, and the conjunctiva is ablated using light bipolar cautery. The tarsal strip is then secured to the periosteum of the inner aspect of the lateral orbital rim at the height of the uninjured lateral canthus using a double-armed, braided, nonabsorbable suture such as polyester. Many patients with lower eyelid retraction also benefit from a middle lamellar spacer placed between the orbicularis and lower eyelid

retractors and secured to the inferior border of the lower tarsus. Many materials have been used, including autologous cartilage and acellular porcine dermis. Raising and tightening the lower eyelid leads to improved eyelid closure and better punctal positioning, which help optimize tear outflow and function of the lacrimal pump system.

Tear Drainage

Epiphora is a common symptom in facial palsy patients. The cause of tearing is multifactorial and can include a combination of increased tear production and compromised tear outflow. Normal hypersecretion associated with ocular surface abnormalities results in reflex tearing. Orbicularis oculi weakness or paralysis results in a static lower eyelid position

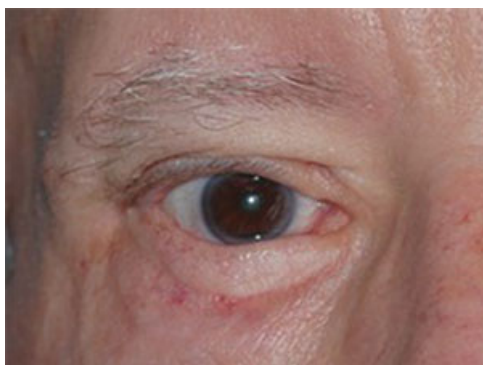


Fig. 4 Resolution of upper eyelid retraction. The same patient in ►Fig. 3 after a 1-g platinum/iridium chain weight has been placed.

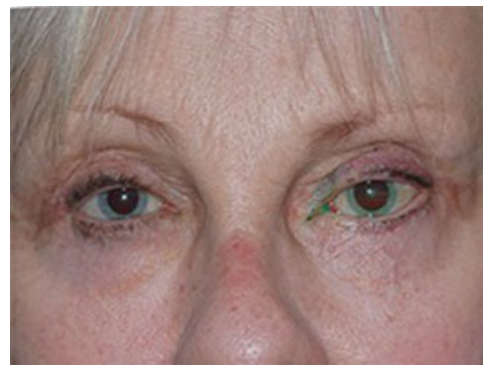

Fig. 5 Widening and elevation of left lateral canthus after canthopexy positioned abnormally high in attempt to treat left lower eyelid retraction. Note that the left lower eyelid is still lower than the normal right side.

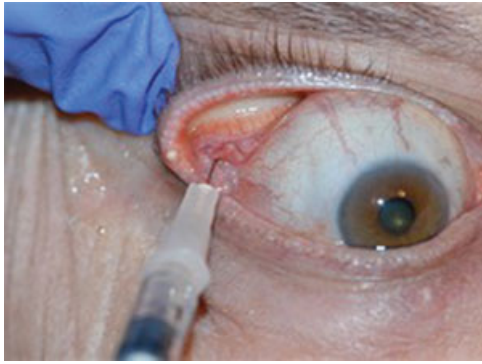

Fig. 6 Transconjunctival injection of botulinum toxin A into the palpebral lobe of the lacrimal gland for the treatment of gustatory lacrimation.

and a defective tear pump mechanism, which impairs proper tear outflow. Tear outflow can be further compromised by punctal ectropion in the setting of paralytic lower eyelid ectropion seen most commonly in older patients with underlying horizontal laxity. Management of reflex tearing is best accomplished by appropriate lubrication and treatment of eyelid malposition. Poor pump function and punctal ectropion can be improved by lower eyelid surgery, and intubation of the lacrimal system with a silicone stent can also be helpful in cases of accompanying punctal stenosis. In some cases, refractory tearing can be treated by a conjunctivorhinostomy with Jones tube placement.²⁰ Abnormal tearing while eating, known as gustatory lacrimation, is an uncommon consequence of facial nerve regeneration in which the efferent fibers from the superior salivary nucleus improperly innervate the lacrimal gland.²¹ Gustatory lacrimation responds well to 5 U of botulinum toxin A in 0.05 mL injected transconjunctivally into the palpebral lobe of the lacrimal gland (→ Fig. 6).²²

Conclusion

Early consultation of an ophthalmologist for a thorough evaluation of the ocular surface and eyelids of a patient with facial nerve palsy and subsequent comanagement of these patients is crucial to an optimal outcome. Although the greatest risk of improperly treated ocular manifestations of facial nerve palsy is the development of permanent loss of vision due to corneal scarring or perforation, symptoms from exposure keratopathy and constant epiphora can significantly impact the quality of life of facial palsy patients. The foundation of medical management is lubrication with preservative-free drops and ointment and nonsurgical management of lagophthalmos. Surgical management is focused on protecting the ocular surface by normalization of upper and lower eyelid positions.

References

- Boerner M, Seiff S. Etiology and management of facial palsy. *Curr Opin Ophthalmol* 1994;5(5):61–66
- Catalano PJ, Bergstein MJ, Biller HF. Comprehensive management of the eye in facial paralysis. *Arch Otolaryngol Head Neck Surg* 1995;121(1):81–86
- Custer PL. Ophthalmic management of the facial palsy patient. *Semin Plast Surg* 2004;18(1):31–38
- Lee V, Currie Z, Collin JR. Ophthalmic management of facial nerve palsy. *Eye (Lond)* 2004;18(12):1225–1234
- Rahman I, Sadiq SA. Ophthalmic management of facial nerve palsy: a review. *Surv Ophthalmol* 2007;52(2):121–144
- Seiff SR, Chang JS Jr. The staged management of ophthalmic complications of facial nerve palsy. *Ophthalm Plast Reconstr Surg* 1993;9(4):241–249
- Seiff SR, Boerner M, Carter SR. Treatment of facial palsies with external eyelid weights. *Am J Ophthalmol* 1995;120(5):652–657
- Zwick OM, Seiff SR. Supportive care of facial nerve palsy with temporary external eyelid weights. *Optometry* 2006;77(7):340–342
- Ellis MF, Daniell M. An evaluation of the safety and efficacy of botulinum toxin type A (BOTOX) when used to produce a protective ptosis. *Clin Experiment Ophthalmol* 2001;29(6):394–399
- Leatherbarrow B, Collin JR. Eyelid surgery in facial palsy. *Eye (Lond)* 1991;5(Pt 5):585–590
- Barclay TL, Roberts AC. Restoration of movement to the upper eyelid in facial palsy. *Br J Plast Surg* 1969;22(3):257–261
- Smellie GD. Restoration of the blinking reflex in facial palsy by a simple lid-load operation. *Br J Plast Surg* 1966;19(3):279–283
- Berghaus A, Neumann K, Schrom T. The platinum chain: a new upper-lid implant for facial palsy. *Arch Facial Plast Surg* 2003;5(2):166–170
- Silver AL, Lindsay RW, Cheney ML, Hadlock TA. Thin-profile platinum eyelid weighting: a superior option in the paralyzed eye. *Plast Reconstr Surg* 2009;123(6):1697–1703
- Bladen JC, Norris JH, Malhotra R. Cosmetic comparison of gold weight and platinum chain insertion in primary upper eyelid loading for lagophthalmos. *Ophthalm Plast Reconstr Surg* 2012;28(3):171–175
- Seiff SR, Sullivan JH, Freeman LN, Ahn J. Pretarsal fixation of gold weights in facial nerve palsy. *Ophthalm Plast Reconstr Surg* 1989;5(2):104–109
- Hontanilla B. Weight measurement of upper eyelid gold implants for lagophthalmos in facial paralysis. *Plast Reconstr Surg* 2001;108(6):1539–1543
- Bladen JC, Norris JH, Malhotra R. Indications and outcomes for revision of gold weight implants in upper eyelid loading. *Br J Ophthalmol* 2012;96(4):485–489
- Anderson RL, Gordy DD. The tarsal strip procedure. *Arch Ophthalmol* 1979;97(11):2192–2196
- Madge SN, Malhotra R, Desousa J, et al. The lacrimal bypass tube for lacrimal pump failure attributable to facial palsy. *Am J Ophthalmol* 2010;149(1):155–159
- McCoy FJ, Goodman RC. The crocodile tear syndrome. *Plast Reconstr Surg* 1979;63(1):58–62
- Falzon K, Galea M, Cunniffe G, Logan P. Transconjunctival botulinum toxin offers an effective, safe and repeatable method to treat gustatory lacrimation. *Br J Ophthalmol* 2010;94(3):379–380