

“Sensory Switching” in Elbow Reconstruction

Shunsuke Sakakibara¹ Kazunobu Hashikawa¹ Hiroto Terashi¹

¹Department of Plastic Surgery, Kobe University Graduate School of Medicine, Kobe, Japan

Address for correspondence Shunsuke Sakakibara, MD, PhD, Department of Plastic Surgery, Kobe University Graduate School of Medicine, 7-5-2 Kusunoki-cho, Chuo-ku, Kobe 650-0017, Japan (e-mail: shunsuke@med.kobe-u.ac.jp).

J Brachial Plex Peripher Nerve Inj 2015;10:e30–e33.

Abstract

In the treatment of the soft tissue defect of the elbow, flap reconstruction is necessitated in many cases because of thinness of soft tissue at this region. In addition, reacquirement of tactile sensation is desirable because of the anatomical and specific functions of the elbow. Of three cases treated for elbow defects, one was reconstructed with a pedicled island forearm flap containing the lateral cutaneous nerve of the forearm, another was reconstructed with a venoneuro-accompanying artery fasciocutaneous flap (VNAF flap) containing the basilic vein, and the third with the VNAF flap containing the cephalic vein. The three cases demonstrated a sudden change of sensory territory 4 to 6 months after surgery, which was confirmed by touching the reconstructed region with patients' eye-closed: from its original territory to the elbow in a “switching”-like action. Here we describe and discuss the concept of “sensory switching.”

Keywords

- ▶ sensory switching
- ▶ sensory reconstruction
- ▶ elbow reconstruction
- ▶ sensory nerve
- ▶ sensory territory

Introduction

There are some functionally important elements for hand and arm movements in the elbow such as muscles, tendons, and nerves; therefore, damage to soft tissue of the elbow may cause crucial disruption of hand and arm functions. Although some options are available for the reconstruction of general soft tissue defects, a specific strategy for elbow reconstruction is needed in addition to the reacquirement of tactile sensation because of its anatomy and specific functions, as this region is a weight-bearing site and necessitated to avoid injury such as pressure sore.

With the use of free flaps, the sensory nerve can be reconstructed by suturing the cut end of the recipient sensory nerve to the nerve in the free flap. With the use of a pedicle flap, however, because reconstruction of the sensory nerve at the defect is usually not possible by suturing, the sensory territory of the flap at the donor site can be often conserved. Interestingly, some cases show a sudden transfer of sensory territory preserved in the flap to the reconstructed site, in a “switching”-like manner. Previous reports have described sensory relearning and reeducation after damage to sensory nerves, phenomena that are

related to the plasticity of the sensory cortex and that may be similar to the mechanism of plasticity of the brain. Here we describe the new concept of “sensory switching” that may be related to the plasticity of the sensory cortex.

We describe three cases of elbow injury reconstructed with pedicle flaps containing the sensory nerves, and discuss the concept of “sensory switching.”

Case Presentation

Case 1

A 75-year-old woman presenting with arrhythmia and undergoing catheter ablation had her right elbow exposed to X-rays. She had angina and uterine fibroid but no metabolic diseases including diabetes on her past history. After the catheter therapy, radiation skin ulcer on the right elbow occurred. Although the dermatologist treated for over 1½ years, the ulcer has still remained and the patient was introduced to our department. The left elbow was debrided (▶Fig. 1A) and reconstructed with a pedicled island forearm flap (6 × 4.5 cm) containing the lateral cutaneous nerve of the forearm (▶Fig. 1B, C).

received
August 14, 2014
accepted after revision
February 19, 2015
published online
April 29, 2015

DOI <http://dx.doi.org/10.1055/s-0035-1549369>.
ISSN 1749-7221.

Copyright © 2015 Georg Thieme Verlag
KG Stuttgart · New York

License terms



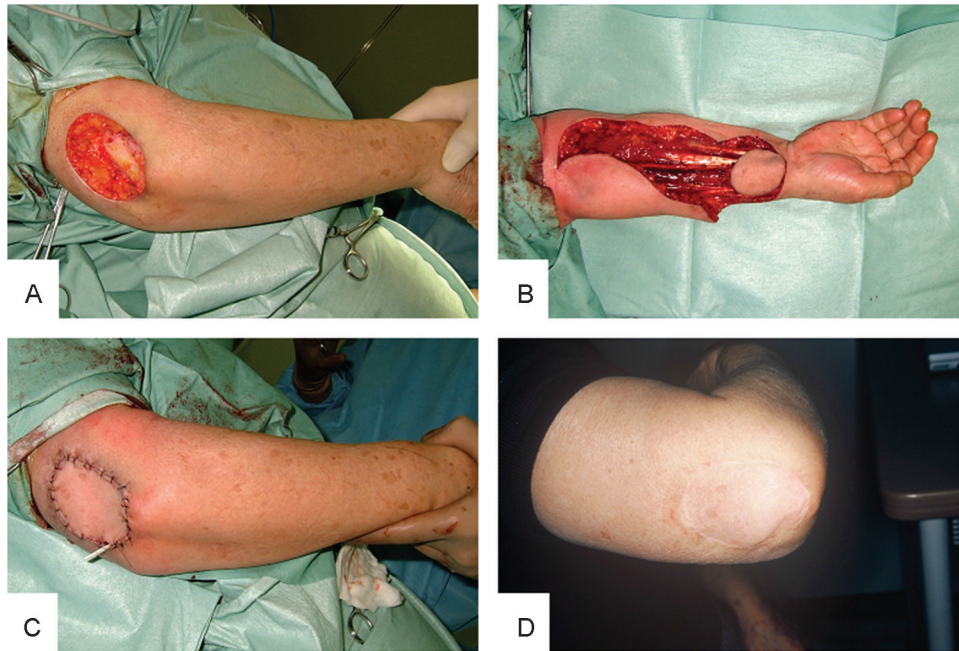


Fig. 1 (A–C) A radiation skin ulcer on the elbow was reconstructed with a pedicled island forearm flap containing the lateral cutaneous nerve of the forearm. (D) Sensory switching was observed after 6 months.

Case 2

A 49-year-old man presented with skin and the underlying soft tissue defect caused by traffic injury to his right elbow (► Fig. 2A). He had no past history including any metabolic diseases. During 2 weeks of conservative therapy, the wound was infected and radical debridement was necessitated. After the debridement of infected tissue, because cortex of ulnar head was appeared, the defect was reconstructed with a

venoneuro-accompanying artery fasciocutaneous flap (VNAF) containing the basilic vein (► Fig. 2A–C).

Case 3

A 75-year-old woman recognized small nodule on her right elbow. Biopsy was performed and sarcoma was suspected. After the tumor resection, the elbow was reconstructed with a VNAF flap containing the cephalic vein (► Fig. 3A–C). The

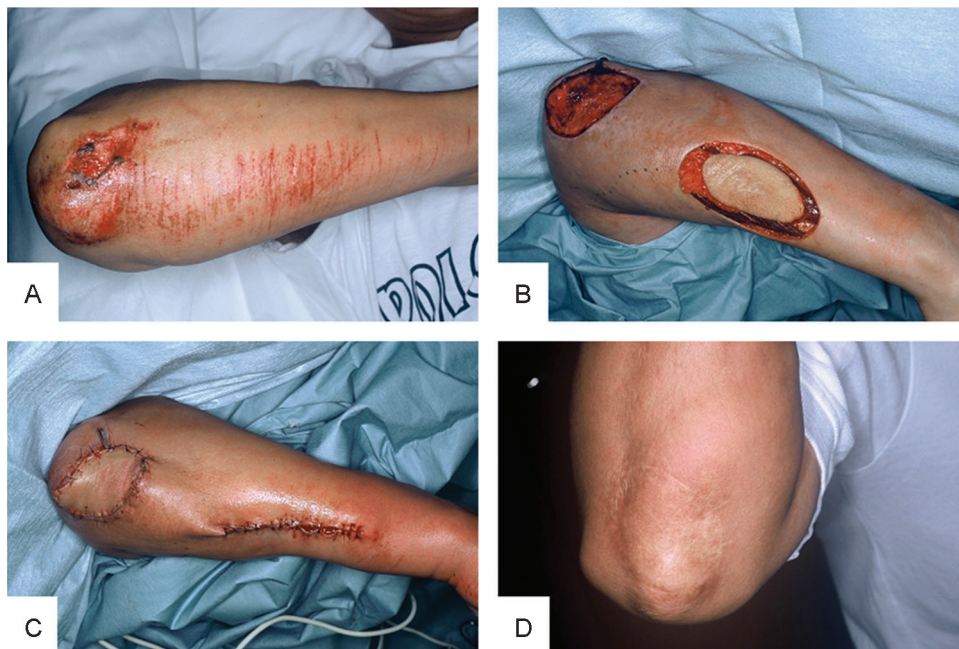

Fig. 2 (A–C) A skin and subskin soft tissue defect caused by injury was reconstructed with a venoneuro-accompanying artery fasciocutaneous flap (VNAF) containing the basilic vein. (D) Sensory switching was observed after 4 months.

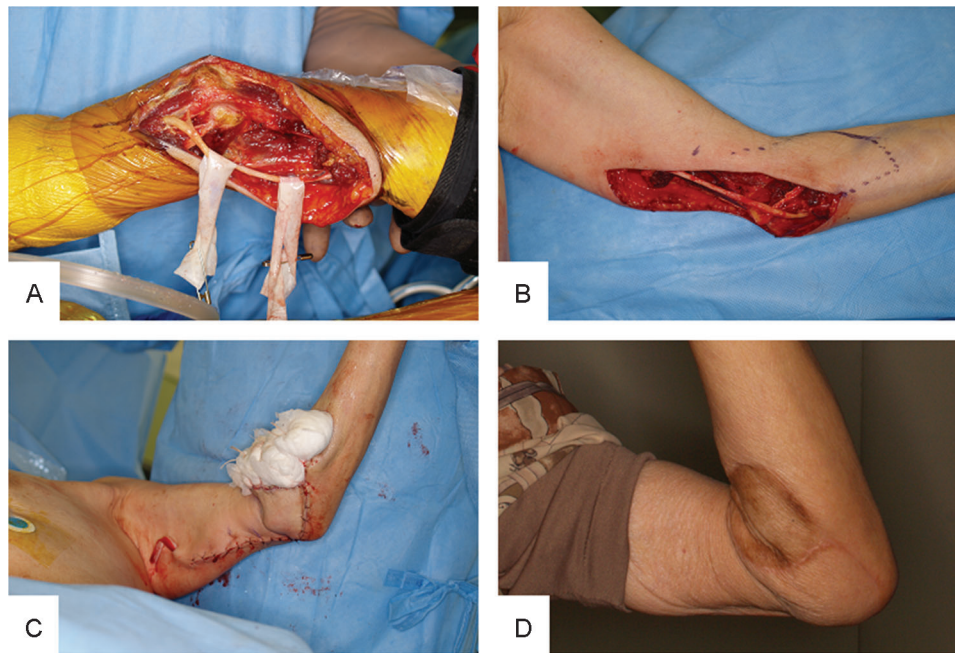


Fig. 3 (A–C) Myxofibrosarcoma on right elbow underwent tumor resection. The elbow was reconstructed with a venoneuro-accompanying artery fasciocutaneous flap containing the cephalic vein. (D) Sensory switching was observed after 5 months.

tumor was diagnosed as a low-grade myxofibrosarcoma and no adjuvant radiotherapy or chemotherapy was performed.

The three cases showed good graft take without any adverse effects such as partial skin necrosis and skin contracture. After the hospital discharge, patients were followed up at the outpatient department every 1 to 2 months. Tactile sensation was checked by touching the reconstructed region with patients' eye-closed. "Sensory switching" was observed after 6 months in case 1 (►Fig. 1D), 4 months in case 2 (►Fig. 2D), and 5 months in case 3 (►Fig. 3D).

Discussion

There are three options for the reconstruction of elbow soft tissue defects: skin grafts, free flaps, and pedicle flaps. With skin grafts, sensory reacquirement relies on the invasion of sensory nerves surrounding the graft; however, tactile sensation is hardly restored. With the free flap, the end of the transected cutaneous sensory nerve contained in the flap is sutured to the original nerve end located in the skin defect, resulting in better axonal regeneration and sensory recovery than with a skin graft. With a pedicle flap such as an island forearm flap, NAF or VNAF, the pedicled sensory nerve is used. Especially with NAF or VNAF, the flap blood supply relies on vessels accompanying and inevitably containing the sensory nerve.^{1,2}

With the pedicle flap, remaining sensation resembling phantom pain is often observed; also the sensation on the flap sometimes appears suddenly at the reconstructed site, in a "switching" manner, which we describe as "sensory switching." Magnetoencephalography of syndactyly patients before and after surgical separation shows cortical reorganization attributed to plasticity of the sensory cortex.³ Moreover, the

reorganization of the somatosensory cortex occurs after injury to the median nerve. These phenomena are summarized in superb sentences by hand surgeons "the hand speaks a new language to the brain."⁴

Analogous to this mechanism, sensory switching on the pedicle flap may also occur because of the plasticity of the sensory cortex. Sensory relearning and reeducation is closely related to age after nerve transection and repair.^{5–7} Our cases tend to be age-related "sensory switching"; however, the number is too small to discuss about this tendency. Further study is needed in this respect.

Rehabilitation might be effective in promoting sensory switching on the basis of sensory reeducation after nerve injury. Conventionally, training for tactile sensation by visual stimulation is effective.⁸ Other forms of stimulation, such as olfactory and auditory, also help tactile reeducation of fingers.⁹ The elbow often makes contact with other objects, for example, the chin resting on the hands, which may stimulate sensory receptors and constitute unconscious rehabilitation.

To summarize, tactile sensation is desirable in the reconstruction of elbow injury because of its specific functions. An especially good option in the reconstruction of the elbow is the innervated pedicle flap. Sensory switching may rely on the plasticity of the somatosensory cortex; however, the mechanism is unknown, and rehabilitation is potentially necessary for promoting sensory switching. Further study is needed for additional data.

References

- 1 Nakajima H, Fujino T, Adachi S. A new concept of vascular supply to the skin and classification of skin flaps according to their vascularization. *Ann Plast Surg* 1986;16(1):1–19

- 2 Herter F, Ninkovic M, Ninkovic M. Rational flap selection and timing for coverage of complex upper extremity trauma. *J Plast Reconstr Aesthet Surg* 2007;60(7):760-768
- 3 Mogilner A, Grossman JA, Ribary U, et al. Somatosensory cortical plasticity in adult humans revealed by magnetoencephalography. *Proc Natl Acad Sci U S A* 1993;90(8):3593-3597
- 4 Lundborg G. *Nerve Injury and Repair*. 2nd ed. Elsevier; 2004
- 5 Almqvist EE, Smith OA, Fry L. Nerve conduction velocity, microscopic, and electron microscopy studies comparing repaired adult and baby monkey median nerves. *J Hand Surg Am* 1983;8(4):406-410
- 6 Polatkan S, Orhun E, Polatkan O, Nuzumlali E, Bayri O. Evaluation of the improvement of sensibility after primary median nerve repair at the wrist. *Microsurgery* 1998;18(3):192-196
- 7 Lundborg G, Rosén B. Sensory relearning after nerve repair. *Lancet* 2001;358(9284):809-810
- 8 Parry CB, Salter M. Sensory re-education after median nerve lesions. *Hand* 1976;8(3):250-257
- 9 Rosén B, Lundborg G. Early use of artificial sensibility to improve sensory recovery after repair of the median and ulnar nerve. *Scand J Plast Reconstr Surg Hand Surg* 2003;37(1):54-57