

The Beginning of Diagnostic Ultrasound Real-Time Imaging 50 Years Ago

In 1940 Gohr and Wedekind were the first to attempt to use ultrasound for clinical diagnostics – admittedly without relevant results. 2 years later Dussik published a scanning technique through the skull, which he called “hyperphonography”. This procedure proved to be erroneous, however, as the displayed figures showed no equivalent to anatomical structures.

Today’s impulse-echo technique was “copied” by listening to the sounds of nature. Bats picture their surroundings in the darkness by listening to the echoes of their brief ultrasonic cries, thereby locating insects or obstacles in their flight path.

The echo principle was first put into practical use for “sound navigation and ranging” (sonar), especially for measuring distances to icebergs and submarines or to shoals (of fish). In the metal working industry the echo-impulse principle is used for detecting flaws in work pieces.

Sonar laid the groundwork for applying the echo-impulse principle to diagnostic

fields in neurology (echo-encephalography), ophthalmology (echo-ophthalmography) and cardiology (echo-cardiography). At that time these methods only used the 1-dimensional A-mode, which displayed the echoes as spikes of a curve. The Scottish physician Ian Donald, father of ultrasound in gynecology and obstetrics, at first also used 1-dimensional A-mode devices for metal flaw detection in his explorations of gynecological tumors. At the end of the 1950s and the beginning of the 1960s, devices for 2-dimensional ultrasound examination were developed at several locations and on several continents, in part with and in part without water standoff. These compound scanning devices used a storage tube on which a sectional image of the investigated body region appeared within 1 to 2 minutes, while the ultrasound probe was guided by hand over the body surface. This was a time-consuming procedure and the images displayed on the storage tube were

harshly black and white without gray shades. Furthermore, because of the slow image formation, artifacts appeared whenever the body or the hand-held probe moved.

During the 1960s ultrasound examinations of the female breast were already being performed, especially in Japan and the USA. However, at that time this procedure was not competitive with radiological mammography because of its poor resolution, lack of gray shades and its duration.

The young engineer Richard Soldner of Siemens AG in Erlangen, Germany, couldn’t stop thinking about this unsolved problem. In the years 1962 to 1964 he constructed an ingenious new ultrasonic device with automatic scanning and a frame rate of 10 and later up to 16 images per second.

• **Fig. 1** shows Soldner’s scanning concept: Revolving ultrasonic transducers in the focal plane of a parabolic mirror within a water-filled scanning head. The acoustic impulses are beamed to the parabolic mirror and then reflected in a parallel way towards the membrane closing the aperture of the transducer and then enter the examined body. This works in both direc-

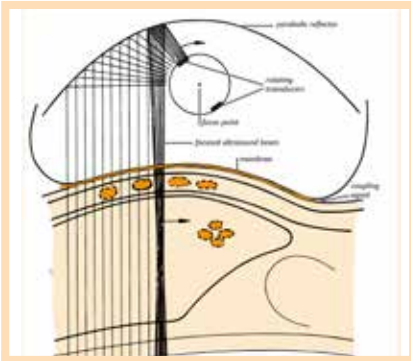


Fig. 1 Illustration of the 'Vidoson' scanning principle (according to Soldner und Krause).

tions. The returning echo signals reach the transducer, which now works as a receiver in gaps between the emitted pulses, and are displayed as dots on a video screen. Numerous dots make up a picture of the scanned organs.

Because of the revolutionary high frame rate of initially 10 and later up to 16 frames per second, the examiner was able to look directly at the emerging moving pictures in real time. This was not possible with the previously used storage tubes. Furthermore, the new method also displayed gray shades. The scanning procedure was so fast that the mammary gland could be scanned in many planes within a few minutes. In this respect the Vidoson fulfilled the requirements for breast cancer screening, which was Soldner's original intention. As it was designed for mammary inspections in a supine position, an imaging depth of 12 cm was deemed good enough. In 1962 the 1st trials at a university gynecological hospital were, however, not successful. After re-engineering, in 1965, the innovative ultrasound equipment was tested at the university gynecological hospital in Göttingen, where studies of pelvic bone structures with a 1-dimensional A-scan had been done for some time. However, Soldner's device was again not suited for these studies. Should Siemens AG halt all further developments?

In the search for another field of application, the device was sent to the university gynecological hospital of Münster, where Dr. P. Weiser, an experienced intern, had asked Siemens AG for a means of performing abdominal ultrasound diagnostics. Moreover, consultant Prof. Dr. D. Hofmann had familiar ties to Siemens.

On July 29, 1965, the device was brought to Münster and assembled by Mr. Soldner and his laboratory manager, the engineer Walter Krause. At that time I was just beginning my internship there and was accidentally passing by. Given my interest in

this new device and the fact that I did not yet have an area of specialization, I was assigned to test the new equipment.

These instruments which were later called 'Vidoson' consisted of 3 parts attached to a mobile X-ray stand (Fig. 2): a display console (to the left), originating from a metal-flaw testing device by Krautkrämer Co. Cologne, with photo-attachment, a 3-dimensional mounting suspen-

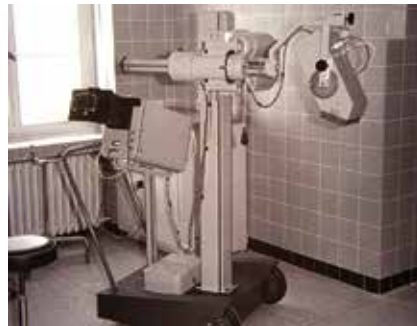

Fig. 2 Prototype of the 'Vidoson', Siemens Co., 1966.

sion (middle), and Soldner's ultrasound scanner (to the right at the long arm of this suspension system).

The scanner field was about 13-14 cm long with an average of 1 line per mm. The imaging depth of the prototype we tested had a maximum of 12 cm (later this depth was increased to 16 and finally even to 20 cm). The frequency used was 2.5 MHz, and the impulse duration was nearly 1 µsec. The median ultrasonic intensity was specified by Siemens AG as approx. 3 mW/cm², and the intensity of a single impulse as ca. 10 Watt/cm². Furthermore, the transducer could be shifted within the scanning head by a servo motor, thus enabling movement of the section plane of up to 3.5 cm parallel to the original plane in order to find the optimal section without moving the heavy scan head (Fig. 3). The continuous signal display could not be stopped, as memory screens were not yet available.

Together with this ultrasound machine, a significant publication by the Swedish gynecologist B. Sundén was handed over to us. He had been working with I. Donald for a while and later in Lund, in his dissertation, he compiled a detailed report about his experiences with the ultrasound compound scanner which had been developed by Donald and his staff.

Left alone with the new device, we tried to reproduce Sundén's publications at first.

Our foremost aim was the discovery and display of gynecological tumors, e.g. my-

omas and ovarian tumors, and we were soon successful (Fig. 3). Using low amplifier thresholds, we visualized not only the tumor contours but also the interior structures, and we found our results to be much better than those of Sundén, who had worked with a compound scanner and a storage tube. In the beginning some of our colleagues viewed our new equipment with skepticism or even derision, but this attitude changed when I was able to clearly demonstrate an ovarian tumor, which was not palpable before, not even under anesthetic, in an obese 81-year-old patient.

Our secondary aim was diagnostics in the 2nd half of gestation. In 1965 nearly 10%

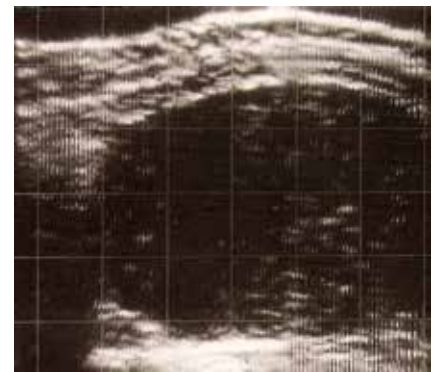

Fig. 3 Sonogram of a solid malignant ovarian tumor. Clearly visible internal structures of the tumor at a low amplifier threshold. The distance between the grid lines on this and on the following figures correspond to 2 cm within the body.

of all women admitted to our department for delivery underwent an X-ray examination to answer questions regarding twins, intrauterine death, hydrocephalus, anencephalus, fetal position, narrow pelvis. We gradually realized that most of these questions can also be answered by ultrasonic testing. Therefore, ultrasound imaging techniques soon replaced X-ray procedures, and in the years to follow the number of radiographic examinations for obstetric patients was reduced by 90%, with the exception of pelvic measurements, which we could not perform by ultrasound at that time.

Our 1st test trial came to an end as scheduled after 8 weeks and the equipment was returned to Erlangen. We presented our (predominantly positive) experiences at a meeting of the Medical Society in Münster on Nov. 10, 1965. This gave Siemens AG the necessary encouragement to continue the development of this scanner, and we got the opportunity for another 3-month trial period on March 1, 1966.

This opened up completely new diagnostic potential. In those days we had to take care of many pregnant women with rhesus incompatibility. One day we were asked to localize the placenta before amniocentesis in one of these women, in order to minimize the risk. We had no problem visualizing the placenta and we wondered why we had not seen it before. In retrospect we did see the placenta on previous ultrasonic pictures, but we did not think about it before we were asked to do so. We were enthusiastic about this discovery and from that point on we did an ultrasound scan prior to every amniocentesis and every intrauterine blood transfusion so that the puncture could be carried out at a placenta-free location. While doing so, we observed for the 1st time signs of a severe Rh-related hemolytic fetal disease: polyhydramnia, hydroptic thickening of the placenta and also signs of fetal hydrops (ascites and double outlines of the head caused by edematous thickening of the skin, **Fig. 4**). Intrauterine fetal death resulted in deformation of the fetal skull, as could previously only be seen on radiographic images. Furthermore, we suddenly discovered an exciting new possibility for real-time scanning: We realized that we saw fetal movement and even heartbeats. Therefore, it was now possible to diagnose cardiac arrest and thus intrauterine fetal death immediately. Previously, several days had to pass before signs of maceration were present. The ability to observe movement in real time had not even been on Richard Soldner's mind when he developed this ultrasonic equipment.

Having achieved breath-taking results like this, we increasingly used the machine in the 1st half of gestation, as Sundén's literature research, experience and animal experiments had shown that diagnostic

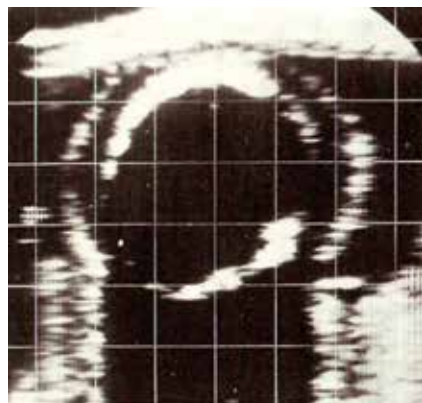


Fig. 4 Fetal skull with double outlines ("halo") due to hydrops as a result of severe hemolytic fetal disease. 28th week of gestation.

ultrasound harmed neither the fetus nor the ovaries. Until that time diagnostically speaking, the pregnant uterus was a black hole before the 20th week of gestation, since neither would the fetus be seen radiographically nor would there be evidence of the fetal heartbeat. Moreover, fetal movements would only be detected by the mother during about the 20th week. In 1966, during the 2nd trial period, we were able to visualize the embryo and its movements during the 12th week and cardiac action during the 13th week (later, when we were more experienced, as early as the 7th week in individual cases). Also in 1966 we diagnosed a twin pregnancy in week 17 (**Fig. 5**) and distinguished it from the differential diagnosis of a hydatidiform mole.

We also conducted measurements of the fetal skull beginning with gestation week 13. This facilitated the identification of the age of gestation better than the previously published measurements after the 30th week of gestation.

Because of our new findings on the importance of ultrasonic diagnostics in obstetrics, Siemens AG decided to assemble a small series of this new device now named the 'Vidoson'. In 1967 we were able

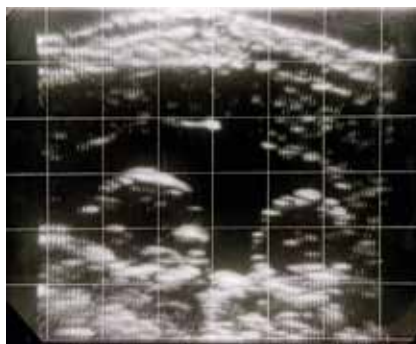


Fig. 5 Skulls of twins, 17th week of gestation.

to put Vidoson no. 1 into service. It now had an imaging depth of 15-16 cm instead of the previous 12 cm, and this was important for diagnostics during the 2nd half of gestation, especially for determining fetal abdominal girth, which proved to be an important parameter for fetal weight. After just 120 examinations, the Vidoson was accepted in our department as an outstanding diagnostic tool. The frequency of ultrasonic examinations increased from year to year.

As colleagues from the neighboring internal medicine department learned of the availability of this new diagnostic option, they came to us more and more often with patients having an enlarged liver and/or

spleen, ascites or pericardial effusion. Therefore, our diagnostic activities were not restricted to gynecological or obstetric cases (**Fig. 6**).

Starting in 1967 the Vidoson was also employed in various other German gynecological departments, e.g. in Aachen, Berlin, Essen, Frankfurt, Munich and Tübingen.

The 1st World Congress on Ultrasonic Diagnostics in Medicine took place in Vienna in 1969. 13 study groups in the fields of gynecology and obstetrics presented their imaging results. Only 3 of them worked with the Vidoson, while all others used compound devices.

On that occasion I got to know Gerhard Rettenmaier, the pioneer of the use of the

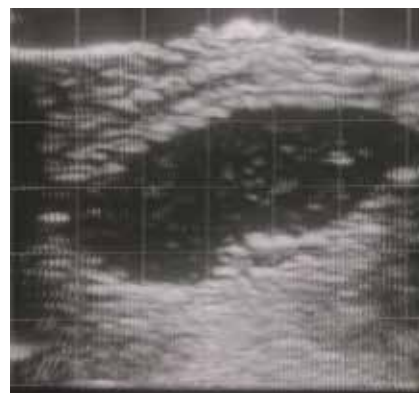


Fig. 6 Enlarged spleen due to liver cirrhosis.

Vidoson in internal medicine. He presented his results on normal and pathological ultrasonic echoes of the liver. Subsequently he got into arguments with the users of the compound technique with storage tubes, as they found the normal liver unechogenic inside, while Rettenmaier, using the Vidoson, found echogenic structures within the liver. Rettenmaier later (1977) called the missing display of gray shades the "congenital deficit" of the storage tube technique, and in 1977 the grayscale technique was finally added to compound scanning ("scan converter"). In the gynecological field, too, there were intense discussions on the advantages or disadvantages of both compound and real-time scanning in the years of 1968 to 1975. Undoubtedly the advantage of compound scanning was the potential to display the entire abdomen, whereas the (faster) Vidoson was only able to display sections with a width of 14 cm and a depth of 16 cm. Alfred Kratochwil, Vienna, combined the compound scan with the 1-dimensional A-mode in order to de-

monstrate fetal heart action or tissue structures.

After 1969 the Vidoson was widely distributed in Europe, in departments of obstetrics and gynecology as well as in those of internal medicine. More than 3000 machines were produced. In particular, many German gynecologists acquired competence in ultrasound scanning during their specialist training and they would buy a Vidoson when going into private practice. The end of the Vidoson age was on the horizon in 1975.

At the 1st European Congress on Ultrasonic Diagnostics in Munich, ADR introduced the 1st serially produced device with a linear-array transducer. Siemens AG reacted by further improving the Vidoson. The new Vidoson 735, however, was not able to sustain its position much longer, as the competitor devices with electronic scanners were cheaper and easier to manage. In approximately 1980, production of the Vidoson was discontinued. At the same time, production of compound scanners was also stopped.

First and foremost, Richard Soldner deserves the credit for being the first to realize the advantages of real-time scan diagnostics and for having transferred his ideas into practice. I am grateful that I had the opportunity to assist with the birth of real-time sonography in the fields of obstetrics and gynecology.

*Prof. Dr. med. Hans-Jürgen Holländer,
Dinslaken, Germany*

References

- 1 Donald I, MacVicar J, Brown TG. Investigation of abdominal masses by pulsed ultrasound. *Lancet* 1958; 1: 1188
- 2 Dussik K. Über die Möglichkeit hochfrequente mechanische Schwingungen als diagnostisches Hilfsmittel zu verwenden. *Zschr. Neurol.* 1942; 174: 153
- 3 Gohr H, Wedekind T. Der Ultraschall in der Medizin. *Klin. Wschr.* 1940; 19: 25
- 4 Hofmann D, Holländer HJ, Weiser P. Neue Möglichkeiten der Ultraschalldiagnostik in der Gynäkologie und Geburtshilfe. *Fortschr. Med.* 1966; 84: 689 (Vortrag auf der Sitzung der Medizin. Gesellschaft Münster am 10.11.1965)
- 5 Hofmann D, Holländer HJ, Weiser P. Über die geburtshilfliche Bedeutung der Ultraschalldiagnostik. *Gynaecologia (Basel)* 1967; 164: 24
- 6 Hofmann D, Holländer HJ. Über den Nachweis fetalen Lebens und die Messung des kindlichen Schädels mittels des zweidimensionalen Ultraschallechoverfahrens. – Bemerkungen zu: A. Kratochwil: *Gynaecologia* 1967; 164: 37–42. *Gynaecologia (Basel)* 1968; 165: 60
- 7 Holländer HJ. Nachweis und Differentialdiagnostik intraabdominaler Tumoren mittels Ultraschall. *Med. Kli.* 1968; 63: 1175
- 8 Holländer HJ. Die Ultraschalluntersuchung im Rahmen der pränatalen Diagnostik der Rh-Erythroblastose. 1. Weltkongreß über Ultraschalldiagnostik in der Medizin, Wien 1969
- 9 Holländer HJ. Die Ultraschalluntersuchung in der Schwangerschaft. 3. Auflage, München – Berlin – Wien: Urban und Schwarzenberg, 1984
- 10 Kratochwil A. Ultraschalldiagnostik in Geburtshilfe und Gynäkologie. Stuttgart: Georg Thieme Verlag, 1968
- 11 Krause W, Soldner R. Ultraschallschnittbildverfahren (B-scan) mit hoher Bildfrequenz für medizinische Diagnostik. *Electromedica* 1967; 4: 8
- 12 Rettenmaier G. Unterscheidung von normalen und krankhaften Ultraschallreflexionen in der Leber. 1. Weltkongreß über Ultraschalldiagnostik in der Medizin, Wien 1969
- 13 Rettenmaier G. Ultraschalldiagnostik durch Grauwertdarstellung. *Dtsch. Med. Wschr.* 1977; 102: 1104
- 14 Soldner R, Krause W. Ultraschall-Scanner mit hoher Bildfolge für die medizinische Diagnostik. *Biomed. Technik* 1971; 16: 87–89
- 15 Sundén B. On the diagnostic value of ultrasound in obstetrics and gynaecology. *Acta Obstet. Gynec. Scand.* 1964; 43 (Suppl 6): 1–191