

# Localized Thyroid Tissue Ablation by High Intensity Focused Ultrasound: Volume Reduction, Effects on Thyroid Function and Immune Response

## Lokale Ablation von Schilddrüsengewebe durch hochintensiven fokussierten Ultraschall: Volumenreduktion, Auswirkungen auf die thyroideale Funktion und Immunreaktion

### Authors

H. Korkusuz<sup>1,2</sup>, M. Sennert<sup>2</sup>, N. Fehre<sup>2</sup>, C. Happel<sup>1,2</sup>, F. Grünwald<sup>1,2</sup>

### Affiliations

<sup>1</sup> German Center for Thermoablation of Thyroid Nodules, University Hospital, Frankfurt am Main, Germany

<sup>2</sup> Department of Nuclear Medicine, University Hospital, Frankfurt am Main, Germany

### Key words

- high intensity focused ultrasound
- thyroid nodule
- thermal ablation
- thyroid hormones
- thyroid function
- thyroglobulin

### Zusammenfassung



**Ziel:** Das Ziel dieser Studie war, die Effektivität von hochintensivem fokussiertem Ultraschall (HIFU) zu beurteilen. Es wurden die Volumenreduktion der Knoten, die Funktion der Schilddrüse und eventuell auftretende Immunreaktionen evaluiert.

**Material und Methoden:** Zwölf Patienten (neun weiblich, Durchschnittsalter 56,9 Jahre) wurden ambulant mit HIFU an der Schilddrüse behandelt. Alle Patienten hatten einen einzelnen benignen Schilddrüsenknoten, der in jeweils einer Therapie-sitzung behandelt wurde. Das mittlere Knotenvolumen (nodular outline volume) betrug 3,4 ml (Bereich 0,6–5,0 ml). Die therapeutische Ultraschallsonde (Echopulse® THC900 888-H), die in dieser Studie verwendet wurde, arbeitet mit einer Frequenz von 3 MHz, erreicht eine mittlere Temperatur von 80–90°C und sendet eine mittlere akustische Leistung von 87,6 bis 192,8 Watt aus. Die Serumspiegel von Trijodthyronin (T3), Thyroxin (T4), Thyreotropin (TSH), Thyreoglobulin (hTg) und zusätzlich Antikörper gegen Thyreoglobulin (TAK), Thyreotropin-Rezeptoren (TRAK) und Thyreoperoxidase (TPO) wurden bei der Aufnahme, 24 Stunden nach der Therapie und drei Monate nach der Therapie gemessen. Die prä-post Thyreoglobulin-Reduktion wurde gemessen, um den Erfolg der Ablation einzuschätzen. Außerdem wurde das Knotenvolumen mit der Variable Nodular Outline Volume (NOV) untersucht, um die Effektivität zu bestimmen.

**Ergebnisse:** Die Hormonspiegel sind stabil geblieben ( $p < 0,05$ ). Es wurde keine Autoimmunerkrankung, wie etwa eine Autoimmunthyreoiditis hervorgerufen ( $p > 0,05$ ). Die Serumthyreoglobulinspiegel sind 24 Stunden nach der Ablation signifikant angestiegen ( $p > 0,05$ ). 3 Monate nach der Ablation wiederum sind sie signifikant abgefallen ( $p < 0,05$ ) und erreichten das prä-ablative Niveau.

### Abstract



**Purpose:** The aim of this study was to assess the effectiveness of high intensity focused ultrasound (HIFU) in reducing thyroid nodule volume while preserving thyroid function as measured by immunological response.

**Materials and Methods:** 12 patients (9 females) whose average age was 56.9 years (37–81) were treated with HIFU in an ambulatory setting. All patients had a single benign thyroid nodule treated in one HIFU session. The median nodular outline volume (NOV) was 3.4 ml (range 0.6–5.0 ml). The therapeutic ultrasound probe (Echopulse® THC900 888-H) used works with a frequency of 3 MHz, reaching temperatures of 80–90°C and a mean output between 87.6 and 192.8 W. To assess possible effects of HIFU on thyroid function, serum levels of triiodothyronine (T3), thyroxine (T4), thyrotropin (TSH), thyroglobulin (hTg) and antibodies against thyroglobulin (TAb), thyrotropin receptors (TRAb) and thyroid peroxidase (TPOAb) were measured at enrollment, 24-hours post-HIFU treatment and at 3-month follow-up. Pre- post thyroglobulin reduction was measured to evaluate the success of ablation and the nodular outline volume (NOV) was evaluated at baseline and the 3-month follow-up to assess effectiveness.

**Results:** All measured hormone levels were within normal ranges and remained stable ( $p > 0,05$ ). No clinically meaningful immune reaction was induced ( $p > 0,05$ ). Thyroglobulin serum levels increased significantly at 24 hours after ablation ( $p < 0,05$ ) and decreased significantly at the 3-month follow-up ( $p < 0,05$ ), returning to pre-ablative levels. The median reduction in nodular outline volume (NOV) was 55% ( $p < 0,05$ ).

**Conclusion:** HIFU is a safe and effective alternative for treating benign thyroid nodules, while preserving thyroid function. Further investigations with multiple treatments should be conducted to eval-

received 22.2.2015  
accepted 30.5.2015

### Bibliography

DOI <http://dx.doi.org/10.1055/s-0035-1553348>  
Published online: 22.7.2015  
Fortschr Röntgenstr 2015; 187: 1011–1015 © Georg Thieme Verlag KG Stuttgart · New York · ISSN 1438-9029

### Correspondence

Dr. Huedayi Korkusuz

German Center for Thermoablation of Thyroid Nodules, University Hospital, Frankfurt am Main, Germany, [www.dzta.de](http://www.dzta.de)  
Theodor-Stern-Kai 7  
60590 Frankfurt  
Germany  
Tel.: ++49/69/63 01 67 83  
Fax: ++49/69/63 01 71 43  
[huedayi.korkusuz@kgu.de](mailto:huedayi.korkusuz@kgu.de)

Das mittlere Knotenvolumen (NOV) konnte um 55 % reduziert werden ( $p < 0,05$ ).

**Schlussfolgerung:** HIFU ist eine sichere und effektive Methode, um benigne Schilddrüsenknoten zu behandeln. Die Funktion der Schilddrüse wird nicht beeinträchtigt. Um eine noch größere Volumenreduktion zu erreichen, könnten mehrfache Sitzungen Erfolg versprechen.

#### Kernaussagen:

- ▶ HIFU ist eine sichere und effektive Methode, um benigne Schilddrüsenknoten zu behandeln.
- ▶ HIFU beeinträchtigt die Funktion der Schilddrüse nicht.
- ▶ HIFU induziert keine ernste Immunreaktion, wie etwa Morbus Basedow.

## Introduction

Thyroid nodules are relatively common in industrial nations [1–6] with most being benign and requiring treatment for associated symptoms such as compression, discomfort and cosmetic concerns [7–9]. The relatively mild clinical consequences of most benign nodules suggest that standard therapies, like surgery and radioiodine therapy (RIT), may be associated with more harm than benefit [10, 11]. As a result, there has been a search for alternatives to these standard treatments. This has yielded a variety of new techniques including radiofrequency ablation [8], ethanol sclerotherapy [12], microwave ablation [7, 9, 13] and high intensity focused ultrasound (HIFU) ablation. While some of these alternative techniques have already been established in clinical practice [14], a majority have drawbacks that include induction of serious immune reactions such as Graves' disease, scar formation, hypothyroidism and hyperthyroidism, thyrotoxicosis and inflammation [10–18].

Of existing alternatives to standard therapies, HIFU appears to be one of the most promising in that its advantages include: (a) non-invasiveness, (b) patient wellbeing due to avoidance of scar formation (c) low risk of immune responses as will be discussed below, (d) accuracy and (e) ease of use, the latter two based on our own clinical experience. HIFU is already widely applied in clinical practice and is used to treat, among other diseases, breast lesions [19], uterine fibroids [20] and prostate cancer [21]. It is also further being developed to treat kidney and liver tumors [22]. However, to our knowledge there have been only few published studies except our own recent publications [23–25] investigating the ablation of human thyroid tissue with HIFU [26–28] and few other publications describing preclinical work in the area [28–30].

The objective of the current study was to assess HIFU's effectiveness in reducing nodule volume while preserving thyroid function, as measured by thyroid hormone and relevant antibodies, and so to provide much needed additional data on procedure outcome in the indication. A successful treatment in this study was achieved if the following criteria were achieved: (a) volume reduction  $> 30\%$ , (b) symptom score improvement, (c) euthyroid hormone status.

## Materials and Methods

### Patients

Patients were enrolled at the nuclear medicine department of the University Hospital Frankfurt. Eligible patients had a symptomatic thyroid nodule and cosmetic concerns and had either refused sur-

rogate whether additional treatments can achieve greater volume reduction.

#### Key points:

- ▶ HIFU is a safe and effective method to treat thyroid nodules.
- ▶ HIFU does not interfere with thyroid gland function.
- ▶ HIFU does not induce any immune response like Graves' disease.

#### Citation Format:

- ▶ Korkusuz H, Sennert M, Fehre N et al. Localized Thyroid Tissue Ablation by High Intensity Focused Ultrasound: Volume Reduction, Effects on Thyroid Function and Immune Response. *Fortschr Röntgenstr* 2015; 187: 1011–1015

gery or were contraindicated for it. Patients were excluded for having asymptomatic nodules, nodule volume exceeding 10 ml, histological evidence for malignancy or positive Tc-99m MIBI uptake in cold nodules or conspicuous calcitonin measurement.

12 patients (9 females) whose average age was 56.9 years (37–81) were treated with HIFU in an ambulatory setting. All patients had a single benign thyroid nodule treated in one HIFU session. The median nodular outline volume (NOV) was 3.4 ml (range 0.6–5.0 ml).

### Study Design

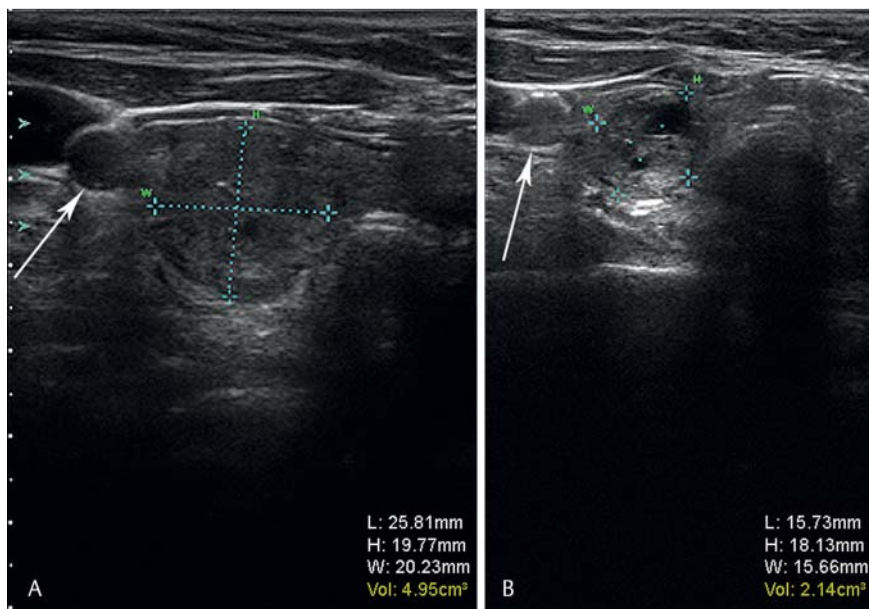
This was a single-arm, open-label, baseline control study. The study complied with institutional review board ethics committees, informed consent regulations, International Committee on Harmonization Good Clinical Practice Guidelines, the Declaration of Helsinki, and local regulations.

### Treatment Procedure and Equipment

The system used in this study (Echopulse® THC900 888-H, THERACLION SA, Malakoff – France) has two separate ultrasound systems. The imaging system works between frequencies of 7.5 and 12 MHz and the therapeutic system with frequencies of 3 MHz, reaching temperatures approximately 80–90 °C. Heat is produced by absorption of acoustic energy and its conversion into thermal energy.

A probe with a maximal penetration depth of 1.5 cm and an exchangeable cooling kit was used. The system automatically selected the following safety margins: (a) 0.5 cm from the skin, (b) at least 0.3 cm from the trachea and (c) 0.2 cm from the carotid. The mean output per treated voxel varied between 87.6 and 192.8 W. Before each treatment, a cooling kit was installed and the system underwent a general test of function. The nodular volume was measured using US (Fig. 1). Local anesthesia (Mecain 1%) was given, followed by positioning of the ultrasound probe on the hyperextended neck and primary marking of relevant structures. The system automatically generated a voxel map of the intended nodule and the marked structures around it. Following the computed voxel map in a screw pattern while adjusting the energy level, the system executed ablation by automatically alternating a four-second treatment beam with a cooling pause and positioning. Throughout the procedure the voxel map and sonographic images, showing the actual and planned images of the current voxel, were visible to enable control of the ultrasound probe location.

Throughout the treatment it was possible to manually pause, reposition, select or remove particular voxels and terminate the treatment. If patient movement occurred during a beam, a laser-



**Fig. 1** Example of ultrasound imaging of a thyroid nodule. Part **A** shows the nodule pre-ablation and part **B** three months post-ablation. Light blue crosses mark the nodules. White arrows mark the carotid artery. In this example a successful volume reduction of 2.8 ml was achieved.

**Abb. 1** Ein Beispielbild für die Ultraschallkontrolle eines Schilddrüsenknotens. Die linke Bildhälfte (mit **A** markiert) stellt den Knoten vor der Behandlung durch HIFU dar, die rechte Bildhälfte (mit **B** markiert) zeigt die Ultraschallkontrolle 3 Monate nach der Ablation. Die hellblauen Kreuze markieren den Knoten. Die weißen Pfeile zeigen auf die Arteria Carotis. In diesem Beispiel konnte eine Volumenreduktion von 2,8 ml erreicht werden.

controlled movement detector directed at the laryngeal prominence automatically stopped the treatment and lead to manual repositioning or recalibration of the measured laser distance.

### Baseline Assessment and Endpoints

All patients underwent a pre-ablation assessment, including laboratory blood tests, ultrasound imaging and fine-needle aspiration biopsy of the targeted nodule.

B-mode ultrasound (Sonix Touch Ultrasound system, Ultrasonix Medical Corporation, Richmond, Canada) was used to evaluate the volume, size, number and composition of the nodules.

Serum levels were determined with commercially available immunoradiometric assay and radioimmunoassay kits. Laboratory blood tests included a complete thyroid hormone status with triiodothyronine (T3, normal range: 1.0 – 3.3 nmol/L) determined by RIA (T3<sup>[125I]</sup> RIA Kit, Izotop, Budapest, Hungary), thyroxine (T4, normal range: 55 – 170 nmol/L) determined by RIA (T4<sup>[125I]</sup> RIA Kit, Izotop, Budapest, Hungary), thyrotropin (TSH, normal range: 0.3 – 4.0 mE/L) determined by IRMA (SELco<sup>®</sup> TSH rapid, Medipan GmbH, Dahlewitz, Germany) and thyroglobulin (Tg, normal range: 2 – 70 ng/mL) determined by IRMA (Riason<sup>®</sup> Tg c. t., Iason GmbH, Graz-Seiersberg, Austria).

Calcitonin level, blood count and coagulation diagnostic were measured.

The presence of antibodies was also examined, specifically those against thyroid peroxidase (TPOAbs, positive: >50 U/mL) determined by RIA (anti-TPO magnum, Medipan GmbH, Dahlewitz, Germany), thyroglobulin (TgAbs, positive: >50 U/mL) determined by RIA (anti-Tg magnum, Medipan GmbH, Dahlewitz, Germany) and thyrotropin receptor (TRAbs, positive: >1.5 IU/L) determined by RIA (TRAK Human RIA, Brahms GmbH, Henningsdorf, Germany). Patients with “cold” nodules were evaluated with a Tc-99m methoxy-isobutyl-isonitrile (MIBI) scan to exclude malignancy. Images were taken 10 and 60 minutes after injection of 500 MBq (13.5 mCi) Tc-99m MIBI. Further a fine-needle aspiration biopsy was performed. No evidence of malignant transformation was found in any of the subjects.

The patients had follow-up laboratory blood tests at 24 hours and 3 months after ablation treatment.

### Statistical Analysis

Statistical analyses were done with the R statistical software [29]. Because of the small sample size and the fact that normality could not be assumed, all statistical testing was non-parametric. Differences between time points were compared by the Wilcoxon sign-rank test and correlation using Kendall's tau.

### Results



#### Safety and Tolerability

HIFU treatment sessions were completed successfully for all twelve patients. All patients tolerated the treatment and interruption was not necessary.

#### Laboratory Tests

With the exception of thyroglobulin (hTg), no laboratory parameter, antibody measurement or blood count changed significantly at all follow-ups.

Thyroglobulin levels increased significantly ( $p < 0.05$ ) 24 hours after ablation and decreased significantly at the 3-month follow-up relative to the 24-hour time point ( $p < 0.05$ ). Comparison of 3-month hTg values to the baseline was not significant (● Fig. 2). Descriptive statistics for serum levels are provided in ● Table 1.

#### Efficacy

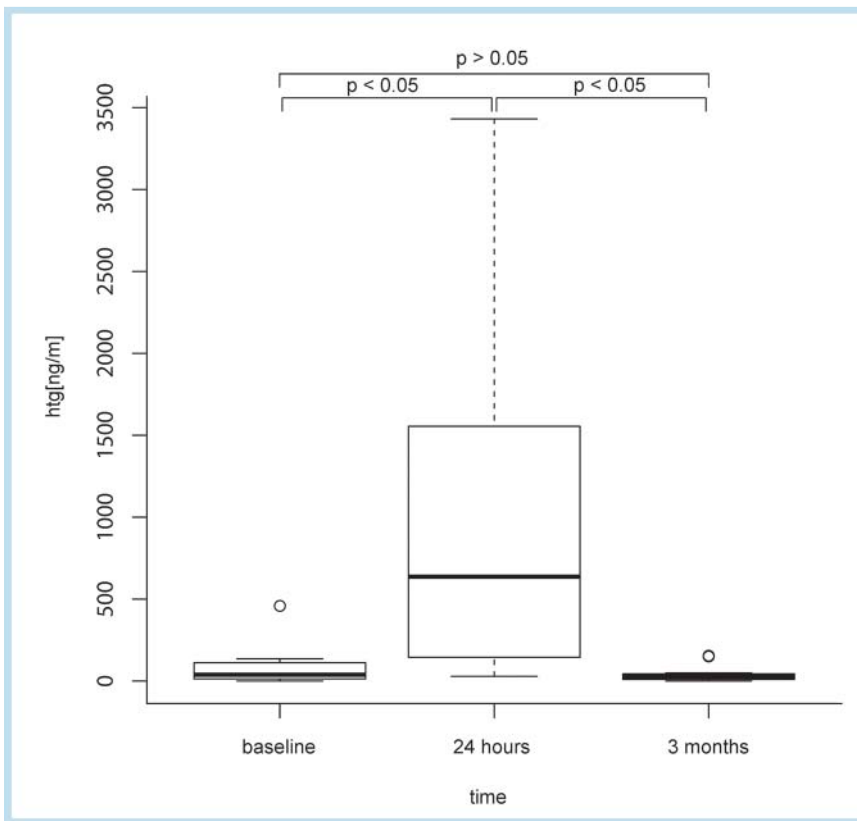
The median reduction of the NOV at the three-month follow-up was 55% ( $p < 0.05$ ). In three patients the therapy was not successful, because a volume reduction of more than 30% was not achieved.

#### Antibody Measurement

No patient showed signs of Hashimoto's thyroiditis or Grave's disease. Yet one patient had elevated levels of anti-TPO before HIFU. After HIFU the levels remained stable. Antibody measurement is summarized in ● Table 1.

#### Discussion

HIFU is currently the least invasive method for the treatment of thyroid nodules, with the most favorable safety profile, posing low risk for infection and other side effects [27]. The study present-



**Fig. 2** Boxplots of hTg serum levels. The increase of hTg levels 24 hours after ablation and the following decrease three months after ablation are significant ( $p < 0.05$ ).

**Abb. 2** Diese Grafik zeigt einen Boxplot der hTg-Blutserum-Werte. Sowohl der Anstieg der Werte 24 Stunden nach der Ablation, als auch der darauf folgende Rückgang drei Monate nach der Ablation sind signifikant ( $p < 0.05$ ).

parameter	baseline	24 hours after HIFU	3 months after HIFU
T3 [nmol/L]	1.7 (1.4–2.3)	1.7 (0.9–2.7)	1.5 (1–2.2)
T4 [nmol/L]	84 (69–144)	92 (74–146)	87 (60–164)
TSH [mE/L]	0.9 (0.5–5.6)	0.7 (0.1–3.0)	1.2 (0.1–1.8)
hTg [ng/mL]	29.6 (0.1–459)	702.0 <sup>1</sup> (28.9–3431.0)	15.3 <sup>1</sup> (0.09–155)
TPOAbs [U/mL]	10 (6–1119)	12 (6–986)	7 (3–791)
TABs [U/mL]	9 (5–110)	7 (5–63)	9 (3–108)
TRABs [IU/L]	0.02 (0–0.92)	0.30 (0–0.74)	0.3 (0–0.74)

**Table 1** Thyroid function parameter medians at baseline and follow-ups.

Median laboratory parameters at baseline and follow-ups. Normal ranges of hormones and antibodies are: T3: 1.0–3.3 nmol/L, T4: 55–170 nmol/L, TSH: 0.3–4.0 mE/L, hTg: < 1 after thyroidectomy, TRABs: positive > 1.5 IU/L, TABs: positive > 50 U/mL, TPO > 50 U/mL. The increase of hTg levels 24 hours after ablation and the following decrease 3 months after ablation are significant ( $p < 0.05$ ). Data are presented as median and range. Blood count, coagulation diagnostics and calcitonin were within normal limits in all patients at all dates of measurement. Die Tabelle zeigt die Mittel der Laborparameter zum Zeitpunkt vor der HIFU-Therapie und bei den Kontrollen. Der normale Bereich der Hormone und Antikörper sind: T3: 1,0–3,3 nmol/L, T4: 55–170 nmol/L, TSH: 0,3–4,0 mE/L, hTg: < 1 nach Thyreoidektomie, TRABs: positiv > 1,5 IU/L, TABs: positiv > 50 U/mL, TPO > 50 U/mL. Die einzigen signifikanten Veränderungen waren im hTg-Wert zu beobachten ( $p < 0,05$ ). Die Daten sind als Median und Bereich präsentiert. Das Blutbild, die Gerinnungsdiagnostik und die Calcitoninwerte waren bei allen Patienten an allen Messungen im Referenzbereich.

<sup>1</sup>  $p < 0.05$

ed in this article found no indication that HIFU either interferes with thyroid gland function or induces thyrotoxicosis. Furthermore, no indications for serious thyroid diseases like Graves' disease or Hashimoto's thyroiditis were found. The hormone status of all patients remained stable and substitution was not necessary. HIFU ablates with temperatures of about 80 to 85 °C. Irreversible tissue damage by heat occurs at temperatures higher than 60 °C [30, 31] while high temperatures under 60 °C induce reversible damage, with a high risk of leaking functional thyroid hormones inducing transient thyrotoxicosis [16]. Other thermal ablative treatments use rather large ablation areas and a long ablation time and thus leak significant energy into the surrounding tissue. In comparison to other thermal ablative treatments, HIFU works with small focal points, great accuracy, short ablation times and a

constant cooling system whereby very little energy is spread to the surrounding not targeted tissue [26–28]. This is likely the reason that there have yet to be reports of HIFU inducing thyrotoxicosis, which may in fact not occur at all when using this procedure. Adding to the safety of the procedure is that structures like blood vessels or the trachea are protected by automatic safety margins and planning accuracy.

A successful volume reduction of more than 30% of the pre-ablative volume was achieved in 9 of the 12 patients in this study. However, it is possible that a further volume reduction will be observed at later follow-ups, since not all damaged tissue might be biologically degraded 3 months after ablation.

Thyroglobulin serum levels were measured to evaluate the success of ablation. In clinical diagnosis thyroglobulin constitutes a

tumor marker, but it can also be measured to assess thyroid mass or damage to thyroid tissue [27, 32]. Thyroglobulin levels increased significantly from baseline to 24 hours and subsequently stabilized at the 3-month follow-up. Since all other laboratory parameters remained stable and no post-ablative increases in antibodies were found, it is possible that HIFU preserves thyroid gland function and does not induce antibodies against thyroid tissue. It should be noted that while non-significance in a small sample such as ours does not prove a lack of change, the similarity of pre and post values on these parameters supports this conclusion.

At the same time, as it currently stands, HIFU treatment for this indication has some drawbacks. Most importantly, HIFU treatment is currently limited to nodules that are smaller than 10 ml. Such was the case in this study and worse results are obtained with bigger nodules. One possible solution for achieving sufficient volume reduction with bigger nodules may be multiple HIFU sessions given at appropriately spaced intervals. Unfortunately there has, to our knowledge, been no study investigating the effects of multiple HIFU sessions. However, the automatic safety margins and anatomical proximity to sensitive structures still represents a limiting factor to treatment success, especially in smaller nodules close to the trachea or the carotid artery, but a possible solution for this problem could lie in the variation of the treatment angle, or liquid infiltration, e.g. local anesthesia in the space between the nodule and the sensitive structure.

## Conclusion

HIFU treatment in benign thyroid nodules is safe, effective and easy to use. The procedure preserves thyroid gland function and there is no indication of it causing autoimmune diseases or thyrotoxicosis. Volume reduction is significant and in most cases sufficient.

Due to small sample size and missing long-term outcome, findings of this study need to be verified by larger studies.

## References

- 1 Etzel M, Happel C, von Müller F et al. Palpation and elastography of thyroid nodules in comparison. *Nuklearmedizin* 2013; 52: 97–100
- 2 Reiners C, Schumm-Draeger PM, Geling M et al. Schilddrüsenultraschallscreening (Initiative Papillon). *Internist* 2003; 44: 412–419
- 3 Schicha H, Hellmich M, Lehrmacher W et al. Should all patients with thyroid nodules  $\geq 1$  cm undergo fine-needle aspiration biopsy? *Nuklearmedizin* 2009; 48: 79–83
- 4 Schmid KW, Sheu SY, Görges R et al. Tumoren der Schilddrüse. *Pathologie* 2003; 24: 357–372
- 5 Völzke H, Lüdemann J, Robinsn DM et al. The prevalence of undiagnosed thyroid disorders in a previously iodine-deficient area. *Thyroid* 2003; 13: 803–810
- 6 Happel C, Truong PN, Bockisch B et al. Colour-coded duplex-sonography versus scintigraphy. Can scintigraphy be replaced by sonography for diagnosis of functional thyroid autonomy? *Nuklearmedizin* 2013; 52: 157–203
- 7 Korkusuz H, Happel C, Heck K et al. Percutaneous thermal microwave ablation of thyroid nodules. *Nuklearmedizin* 2014; DOI: 10.3413/Nukmed-0631-13-10
- 8 Jeong WK, Baek JH, Rhim H et al. Radiofrequency ablation of benign thyroid nodules: safety and imaging follow-up in 236 patients. *Eur Radiol* 2008; 18: 1244–1250
- 9 Yue W, Wang S, Wang B et al. Ultrasound guided percutaneous microwave ablation of benign thyroid nodules: Safety and imaging follow-up in 222 patients. *Eur J Radiol* 2013; 82: e11–e16
- 10 Dietlein M, Dressler J, Grünwald F et al. Leitlinie zur Radioiodtherapie (RIT) bei benignen Schilddrüsenenerkrankungen (Version 4). *Nuklearmedizin* 2007; 46: 220–223
- 11 Lin CM, Doyle P, Tsan YT et al. 131I treatment for thyroid cancer and risk of developing primary hyperparathyroidism: a cohort study. *Eur J Nucl Med Mol Imaging* 2014; 41: 253–259
- 12 Martino E, Murtas ML, Loviselli A et al. Percutaneous intranodular ethanol injection for treatment of autonomously functioning thyroid nodules. *Surgery* 1992; 112: 1161–1165
- 13 Korkusuz H, Happel C, Grünwald F. Ultrasound guided percutaneous microwave ablation of hypofunctional thyroid nodules: evaluation by scintigraphic  $^{99m}\text{Tc}$ -MIBI imaging. *Nuklearmedizin* 2013; 52: 205–257
- 14 Na DG, Lee JH, Jung SL. Korean Society of Thyroid Radiology (KSThR); Korean Society of Radiology. et al. Ablation of Benign Thyroid Nodules and Recurrent Thyroid Cancers: Consensus Statement and Recommendations. *Korean J Radiol* 2012; 13: 117–125
- 15 Christou N, Mathonnet M. Complications after total thyroidectomy. *J Visc Surg* 2013; 150: 249–256
- 16 Ha EJ, Baek JH, Lee JH. The efficacy and complications of radiofrequency ablation of thyroid nodules. *Current Opinion in Endocrinology, Diabetes & Obesity* 2011; 18: 310–314
- 17 Tarantino L, Francica G, Sordelli I et al. Percutaneous Ethanol Injection of Hyperfunctioning Thyroid Nodules: Long-Term Follow-Up in 125 Patients. *Am J Roentgenol* 2008; 190: 800–808
- 18 Feng B, Liang P, Cheng Z et al. Ultrasound-guided percutaneous microwave ablation of benign thyroid nodules: experimental and clinical studies. *Eur J Endocrinol* 2012; 166: 1031–1037
- 19 Kaiser WA, Pfeleiderer SO, Baltzer PA. MRI-guided interventions of the breast. *J Magn Reson Imaging* 2008; 27: 347–355
- 20 Pérez-López FR, Ornat L, Ceausu I et al. EMAS position statement: Management of uterine fibroids. *Maturitas* 2014, pii: S0378-5122(14)00198-4
- 21 Rewcastle JC. High intensity focused ultrasound for prostate cancer: A review of the scientific foundation, technology and clinical outcomes. *Technol Cancer Res Treat* 2006; 5: 619–625
- 22 Illing RO, Kennedy JE, Wu F et al. The safety and feasibility of extracorporeal high-intensity focused ultrasound (HIFU) for the treatment of liver and kidney tumors in a Western population. *Br J Cancer* 2005; 93: 890–895
- 23 Korkusuz H, Sennert M, Fehre N et al. Local thyroid tissue ablation by high-intensity focused ultrasound: effects on thyroid function and first human feasibility study with hot and cold thyroid nodules. *Int J Hyperthermia* 2014; 30: 480–485
- 24 Korkusuz H, Fehre N, Sennert M et al. Early assessment of high-intensity focused ultrasound treatment of benign thyroid nodules by scintigraphic means. *J Ther Ultrasound* 2014; 2: 18
- 25 Korkusuz H, Fehre N, Sennert M et al. Volume reduction of benign thyroid nodules 3 months after a single treatment with high-intensity focused ultrasound (HIFU). *J Ther Ultrasound* 2015; 3: 4
- 26 Esnault O, Rouxel A, Le Nestour E et al. Minimally invasive ablation of a toxic thyroid nodule by High-Intensity Focused Ultrasound. *Am J Neuroradiol* 2010; 31: 1967–1968
- 27 Esnault O, Franc B, Ménégau F et al. High-intensity focused ultrasound ablation of thyroid nodules: first human feasibility study. *Thyroid* 2011; 21: 965–973
- 28 Esnault O, Franc B et al. Localized ablation of thyroid tissue by high-intensity focused ultrasound: improvement of noninvasive tissue necrosis methods. *Thyroid* 2009; 19: 1085–1091
- 29 R Core Team. R: A language and environment for statistical computing. R Foundation for Statistical Computing: Vienna, Austria; 2013, ISBN 3-900051-07 http://www.R-project.org/
- 30 Bhuyan BK. Kinetics of cell kill by Hyperthermia. *Cancer Res* 1979; 39: 2277–2284
- 31 Vogl TJ et al. Interventionelle Thermoablation von malignen Lebertumoren und Lebermetastasen: Vergleich von Radiofrequenzablation (RFA), laserinduzierter Thermotherapie (LITT) und Mikrowellenablation (MWA). *Hessisches Ärzteblatt* 2011; 72: 606–615
- 32 Valcavi R, Riganti F, Bertani A et al. Percutaneous Laser Ablation of Cold Benign Thyroid Nodules: A 3-Year Follow-Up Study in 122 Patients. *Thyroid* 2010, [cited 2014 Feb 4] 20: 1253–1261