

Medical Treatment of Graves' Orbitopathy

Authors

M. Salvi, I. Campi

Affiliation

Graves' Orbitopathy Center, Endocrinology, Department of Clinical Sciences and Community Health, Fondazione Cà Granda, IRCCS and University of Milan, Milan, Italy

Key words

- Graves' orbitopathy
- cytokines
- TSH receptor
- IGF-1 receptor
- rituximab
- B cells

Abstract

The medical treatment of Graves' orbitopathy (GO) is usually reserved to moderate to severe disease. Steroids have been widely employed and possess anti-inflammatory activity, but about 20–30% of patients are not responsive and about 20% present with disease recurrence. Immunosuppressive therapy alternative to corticosteroids may target the different antigens involved in pathogenic mechanisms of GO. Some have already been employed in clinical studies and showed interesting results, although the lack of randomized and controlled trials suggests caution for their use in clinical practice. Potential targets for therapy in GO are the TSH receptor and the IGF-1 receptor on the fibroblasts, inflammatory cytokines, B and T cells. Most promising results are obtained by interacting with the PIK3/

mTORC1 signaling cascades for adipogenesis and the anti-IGF-1R with the monoclonal antibody teprotumumab. A recent open study has shown that tocilizumab, an anti-sIL-6R antibody, inactivates GO. Consistent reports on the efficacy of rituximab have recently been challenged by randomized controlled trials. Clinical practice will greatly benefit from the use of disease modifying agents in GO, as compared to steroids, currently standard treatment for GO. Among these, rituximab may be useful, especially in patients resistant to steroid or with contraindications to steroids. However, larger randomized controlled trials are needed for definitive data on the potential disease-modifying role of rituximab in GO. Direct targeting of the orbital fibroblast via immunosuppression or nonimmunosuppressive drugs is emerging as a promising alternative.

received 15.02.2015

accepted 01.06.2015

Bibliography

DOI <http://dx.doi.org/10.1055/s-0035-1554721>
Horm Metab Res 2015;
47: 779–788
© Georg Thieme Verlag KG
Stuttgart · New York
ISSN 0018-5043

Correspondence

Dr. M. Salvi, MD

Graves' Orbitopathy Center
Fondazione Cà Granda IRCCS
Department of Clinical Sciences
and Community Health
University of Milan
via Sforza 35
Milan
20122 Italy
Tel.: +39/02/50320 609
Fax: +39/02/50320 605
mario@mariosalvinet.it

Introduction

Graves' orbitopathy (GO) is a complex disorder associated with thyroid autoimmunity (AITD) and characterized by expansion and remodeling of the orbital content as a consequence of inflammation of retrobulbar tissues, increased adipogenesis, and accumulation of glycosaminoglycans (GAGs) within the extra-ocular muscles. GO is the most frequent extrathyroidal manifestation of Graves' disease (GD), but is also diagnosed in patients with Hashimoto's thyroiditis or without apparent thyroid abnormalities (Euthyroid Graves' Orbitopathy) [1].

The clinical presentation of GO is highly variable in severity, encompassing conditions of mild orbital involvement, which may be susceptible of spontaneous improvement, and potentially sight-threatening complications, requiring prompt therapeutic intervention.

In a survey among 9 large EUGOGO referral centers in 2002, newly diagnosed GO patients pre-

sented with mild, moderate or severe eye disease in 40, 33, and 28% of cases, respectively. Very recently [2] a change in the presentation of GO to the same centers has been observed, with a significant decrease of most severe cases, probably due to earlier referral to specialized centers and prompt therapeutic care. Conversely, a sight-threatening GO was a very rare event (3–5% of patients) [1].

The natural course of GO is typically characterized by an active phase followed by disease stabilization, as described by the "Rundle curve" [3–8]. An early diagnosis of the active disease phase is important since immunosuppressive and disease-modifying therapies exert their effects only on active GO, while subjects with burn-out GO may only benefit from rehabilitative surgery.

Another important issue in the management of GO is the interaction between thyroid function and the eye disease, since the aim is a rapid restoration of euthyroidism. The choice among different therapeutic approaches for hyperthyroidism depends

on several factors such as the patient's age, the thyroid volume, and the degree of activity and severity of the associated GO [9]. An early diagnosis of GO allows appropriate evaluation and potentially may avoid the onset of severe complications. Therefore, a late referral of the more complex cases to a specialist center, may have a negative impact on the final outcome of these patients. This review will describe the available therapies for GO, both well-established therapies, such as glucocorticoids (GC), or more innovative treatments targeting either the immune system, or the specific antigens involved in GO pathogenesis (IGF-1 receptor and TSH-R) or players of tissue remodeling such as GAGs deposition and adipocytes function.

Although the management of GO is improved over the decades, an effective therapeutic strategy, capable to restore the patients to their pre-GO physical and psychosocial functioning, remains still elusive, as most patients experience deterioration of their quality of life, even years after the initial disease diagnosis [10, 11].

Treatment of Thyroid Dysfunction

The therapy of Graves' disease (GD), when associated to orbitopathy (GO), aims at achieving restoration of euthyroidism as rapidly as possible. Stable euthyroidism may induce spontaneous amelioration of milder degrees of GO [3–7] and may contribute to the optimization of the potential responsiveness to immunosuppressive treatments, when indicated. Euthyroidism also represents the essential condition in which patients may undergo rehabilitative surgical procedures in the burnt out phase of GO. Available treatments for Graves' hyperthyroidism include antithyroid drugs (ATD) as the initial approach, and subsequent definitive ablation of thyroid tissue by surgery or radioiodine therapy (RAI), since a causative treatment in GD is not available, due to the unknown pathogenic mechanisms at the basis of disease. The choice among the different therapeutic approaches for GD is based on several considerations such as the patient's age, the thyroid volume, the presence of GO and its degree of activity and severity. Restoration of permanent euthyroidism is frequently obtained only after definitive treatment with radioiodine or surgery. In general, ATD are not known to influence the natural course of GO [9]. On the other hand, RAI has been shown to cause *de novo* occurrence or progression of GO, which is preventable with the administration of oral steroid prophylaxis. Based on the recent evidence, low dose steroid (0.2 mg/kg bw of prednisone for 6 weeks) prophylaxis should be encouraged when treating with RAI patients with GD, with or without pre-

existing GO, as long as risk factors for developing GO are identified [4, 12, 13], while higher doses may be necessary in patients with moderate GO [14]. Few data are available in the literature on the possible risk of newly occurring GO or reactivation of previous GO after thyroidectomy. Since it is possible that total and near total thyroidectomy may be associated with a certain degree of antigenic release during the surgical procedures, the effect of total thyroidectomy alone or followed by RAI ablation of thyroid remnants in patients with moderate to severe orbitopathy treated with IVGC has been the object of investigation [15–17]. In these studies, total thyroid ablation seems associated with a better outcome of GO, compared with thyroidectomy alone, whereas, in one report, 5 patients submitted to thyroidectomy without RAI had deterioration of GO 6 and 12 months after the end of IVGC pulses [17]. In a retrospective cohort of 50 GD patients submitted to total thyroidectomy, 4 patients developed GO after surgery [18]. To date, the modality of treatment for hyperthyroidism in the presence of GO, ATD, RAI, or surgery, is based more on expert opinion than on evidence [9, 19].

In general, the presence of mild GO influences to a lesser extent, compared to moderate to severe disease, the decision on the type of therapy for GD [9].

Treatment of Mild Orbitopathy

Wait and see strategy and local measures

According to the EUGOGO classification (► **Table 1**) mild GO is defined as "minor lid retraction (<2 mm), mild soft tissue involvement, exophthalmos <3 mm above normal for race and gender, transient or no diplopia, corneal exposure responsive to lubricants" [20].

Kendall-Taylor and collaborators [21] analyzed the first 100 consecutive patients, referred to the same joint thyroid-eye unit in 1960 and 1990 and observed a reduction in the proportion of GD patients with clinically relevant GO from 57–32%. This result was more recently confirmed by Piantanida et al. who described a trend towards a reduction in the prevalence of moderate to severe GO, possibly due to a better control of thyroid dysfunctions and other risk factors such as cigarette smoking [22]. Data from the literature suggest that most patients with GD have mild or no GO at presentation, and that the progression of mild GO to severe forms is infrequent, while partial or complete remission is frequent. Thus, in mild GO, the need of more aggressive treatments instead of a wait and see strategy is questionable [4, 20, 23, 24].

Table 1 Severity classifications in GO, according with EUGOGO classification of patients with GO.^a

Grade	Findings	Therapy
Sight-threatening GO	Dysthyroid optic neuropathy (DON) and/or corneal breakdown	Immediate intervention (steroids or urgent orbital decompression)
Moderate to severe GO	One or more of the following signs: – lid retraction ≥ 2 mm – moderate or severe soft tissue involvement – exophthalmos ≥ 3 mm above normal for race and gender – inconstant or constant diplopia	Eye disease has sufficient impact on daily life to justify the risks of immunosuppressive therapy (if active) or surgical intervention (if inactive)
Mild GO	One or more of the following signs: – minor lid retraction (<2 mm) – mild soft tissue involvement – exophthalmos <3 mm above normal for race and gender – transient or no diplopia – corneal exposure responsive to lubricants	GO has a minor impact on daily life which is insufficient to justify immunosuppressive therapy Supportive therapy (lubricants during daytime and ointments at night, sunglasses, elevation of the head at night, selenium administration) is the most appropriate

^aModified from Bartalena et al. 2008, reference [20]

Although the natural history of the disease is not fully understood, different longitudinal studies confirm that spontaneous improvement or stabilization of eye symptoms and signs in mild GO may occur [3–7]. In particular, improvement of GO has been reported in 35–65% of patients, disease stabilization in 20–45% and worsening in 4–25%. It is therefore important to inform and reassure the patients that their disease is unlikely to progress to more severe forms, and may even improve spontaneously.

In the majority of the cases, the quality of life of patients with mild GO is not severely impaired and supportive therapy is definitely the most appropriate. Different local measures may be chosen: lubricants during daytime and ointments at night are recommended when symptoms of dryness and corneal exposure, such as redness, itching, light sensitivity, excessive tearing, feeling of foreign-body are present. The presence of lagophthalmos may require the need of taping the eyelids during the night. No clear advantages have been obtained by adding 0.05% cyclosporine A as a local immunosuppressive agent to the artificial tear drops [25,26]. Photophobia can be controlled with sunglasses and morning periorbital congestive swelling can be reduced by increasing the elevation of the head at night. Immunosuppressive therapy or orbital radiotherapy (OR) are not recommended, because the risks of side effects generally prevail over the advantages [10,23], except for selected patients with mild active GO, who suffer for a significant deterioration of their quality of life or do not improve over time [11]. Prisms can be used effectively to correct symptomatic diplopia. Botulinum toxin type A injections may be considered to reduce upper lid retraction [27].

Smoking cessation

Smoking cessation is an essential therapeutic step because it has been associated to a decreased chance of developing proptosis and diplopia [28] and probability to progress toward a more severe GO [29]. Behavioral therapies, pharmacological treatment and professional stop-smoking clinics may be helpful in patients who want to stop smoking. In EU-27 Countries, a mean reduction of the number of active smokers of 16% (range –5 to –41%) has been reported from 2000 to 2012 [30]. This might contribute to the observed reduction of the prevalence of severe forms of GO.

Antioxidants supplementation

Selenium has antioxidant, anti-inflammatory, and immunomodulatory actions [31]. Recently, a multicenter randomized, placebo-controlled trial has shown that a 6-month course with selenium (sodium selenite 100 µg twice daily) can be effective in ameliorating the quality of life and of the clinical signs of GO, without causing significant adverse events [32]. However, since most of these patients were living in mild selenium-deficient areas, it remains still to establish if selenium supplementation will also be beneficial for patients living in selenium-sufficient areas.

Treatment of Moderate to Severe Orbitopathy

The self-limiting natural course of GO is characterized by a phase of active inflammation of the orbital tissues, in which disease severity generally progresses, followed by a phase of stabilization and improvement of inflammation and only partial remission of disease signs, as described by the “Rundle curve” [33,34]. Immunosuppressive therapies exert their effects only in the

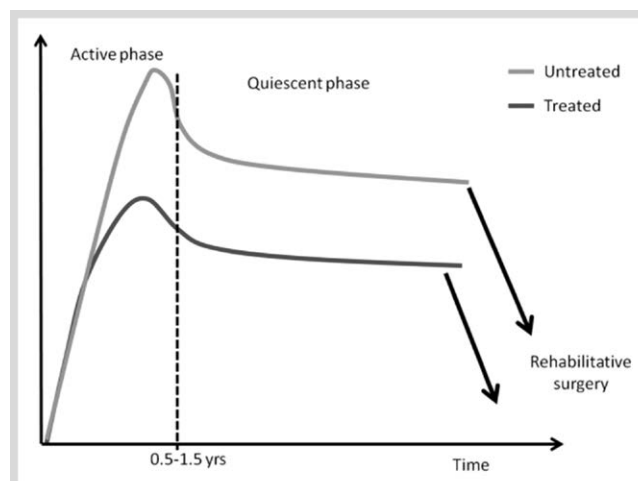


Fig. 1 The natural course of Graves' orbitopathy (GO) and the rationale for treatment. The self-limiting natural course of GO is here represented by the “Rundle curve”, characterized by an active inflammatory phase followed by a stabilization of disease. Immunosuppressive therapies may exert their effects only in the active phase of GO, while patients with inactive diseases will only benefit from rehabilitative surgery (Modified from [34]).

active phase of GO, while burn-out disease can only benefit from rehabilitative surgery (◉ Fig. 1). In patients with active disease medical treatment (immunosuppressive/anti-inflammatory) has the objective to reduce inflammatory signs and the degree of compression around the optic nerve by eye muscles and consequently reduce the need of subsequent rehabilitative surgery [3]. According to a EUGOGO consensus paper (◉ Table 1), patients classified with moderate to severe GO usually have one or more of the following clinical signs: lid retraction ≥ 2 mm, moderate or severe soft tissue involvement, exophthalmos ≥ 3 mm above normal for race and gender, inconstant or constant diplopia [20].

Glucocorticoids

To date, glucocorticoids (GCs) represent the mainstay of immunosuppression for active moderate-severe GO since they exert an anti-inflammatory and, at high doses, also an immunosuppressive effect. In vitro studies have shown that GCs decrease the synthesis and secretion of glycosaminoglycans by orbital fibroblasts, downregulate some adhesion molecules, inhibit cytokines and antibodies secretion, interfere with T and B lymphocytes functions, and decrease the recruitment of neutrophils and macrophages at the inflammation sites [20,35]. Treatment effectiveness much relies on great inter-individual variability that may lead to either treatment failure or drug induced toxicity. In the past GCs have been administered even locally (subconjunctival or peribulbar), but this procedure is not extensively employed, because of concerns about either safety or efficacy. In particular, local triamcinolone injections have been associated with complications such as intractable intraocular hypertension, globe perforation, conjunctival or corneoscleral melting, vascular occlusion or pressure induced optic nerve compression, fat atrophy, depigmentation, and granulomas due to the vehicle of the depot injections [36]. Consequently, although there are few anecdotal experience suggesting a certain degree of efficacy of injected steroids, this method of delivery, is not recommended.

Conversely, a significant response to therapy has been demonstrated for oral GCs (prednisone) [37,38]. High doses of oral GC (daily administration of 50–100 mg of prednisone tapered down in 4–5 months) are effective on inflammatory signs of active GO in about 50–60% of cases but the relapse of symptoms, after discontinuation or dose tapering, is not uncommon [39–44]. Oral therapy is however more often associated to long term side effects, including hepatotoxicity, Cushing's syndrome, osteoporosis, glaucoma, and diabetes mellitus.

Subsequent studies have shown that pulsed intravenous methylprednisolone (ivMP) is more effective (70–80% responders) [16,20,39,45–47] and has a better safety profile compared with oral prednisone [38,48–52]. A wide range of ivMP treatment schedules have been used, with different cumulative doses administered (from 4.5 to 12 g) and occasionally associated with oral GC in the pause between each infusion or at the end of the protocol [16,20,39,45–47,53]. A recent multicenter double-blind randomized study has shown that a cumulative dose of 7.5 g of methylprednisolone has a higher response rate in patients with moderate-severe GO, when compared with intermediate or lower doses (5 g or 2.25 g, respectively), although it is associated with more frequent adverse events [52]. It has therefore been suggested that a high dose regimen may be used in more severe cases of GO while an intermediate dose (5 g) regimen may be used in most patients with moderate disease and that anyhow a cycle of treatment with ivMP should never exceed a total cumulative dose of 8 g. The limitation of ivMP treatment is that 20–30% of patients are poorly responsive or unresponsive at all and that approximately 10–20% of patients present with disease relapse after drug withdrawal [52]. More recently, a study on a retrospective series of patients has shown that responsive patients have inactivation of GO as early as 6–8 weeks from the beginning of ivMP, or may be otherwise switched to other treatments, alone or in combination with steroids [53].

The morbidity and mortality of GC therapy in GO patients have been estimated to 6.5 and 0.6%, respectively [50]. Acute liver failure and cardiovascular events associated with GC administration are potentially fatal [54–59], consequently a careful follow-up during the therapy is crucial. Marked increase of liver enzymes, often asymptomatic, is the most common adverse event associated with ivMP. Acute liver failure seems caused by a direct toxic effect of GC on hepatocytes and appears to be dose-related. The onset of this damage is often not predictable since

only preexistent viral hepatitis is probably associated with increased risk of liver damage, while data about pretreatment liver steatosis or diabetes are conflicting [55,60]. In patients with elevation of liver enzymes the possibility of an autoimmune hepatitis should be ruled out [61,62].

In order to reduce complications, careful screening of risk factors is mandatory. Before ivMP administration, patients should be screened for hepatotropic virus markers and autoantibodies related to autoimmune hepatitis, and clinical monitoring should be regularly performed in order to promptly identify and treat complications [24,50].

Targeted Treatments

Over the past decade, a series of studies have partly uncovered the mechanisms involved in GO pathogenesis [63], in particular those leading to increased retro-orbital adipogenesis. Based on these findings, some authors have proposed to treat progressive GO by directly targeting the specific players involved in the orbital tissue remodeling that results in orbital tissue expansion and in the immune and inflammatory processes occurring in GO. Novel immunomodulating agents, now available, may target several antigens with the purpose of modifying the natural course of disease and not just to control inflammation [64]. In particular, the TSH receptor (TSH-R) [65], the IGF-1 receptor (IGF-1R) and platelet-derived growth factor (PDGF)-receptor, which are expressed on the fibroblasts in the active phase of the disease, several cytokines which have been found to be increased in the various stages of disease progression, molecules regulating the function of antigen presenting cells such as B and T cells, and finally enzymes involved in the synthesis of GAGs (● Fig. 2).

Targeting the TSH receptor

During the last years some low molecular weight TSHR ligands, have been synthesized. These compounds may act as: 1) TSHR agonists (ligands that activate receptors), 2) neutral antagonists (ligands that inhibit receptor activation by agonists), and 3) inverse agonists (ligands that inhibit receptor activation by agonists and also basal or constitutive signaling). These molecules are potential treatment for the treatment of both GD and GO, as they have been tested for their effects on both thyrocytes and orbital fibroblasts [66]. The molecular proprieties of these

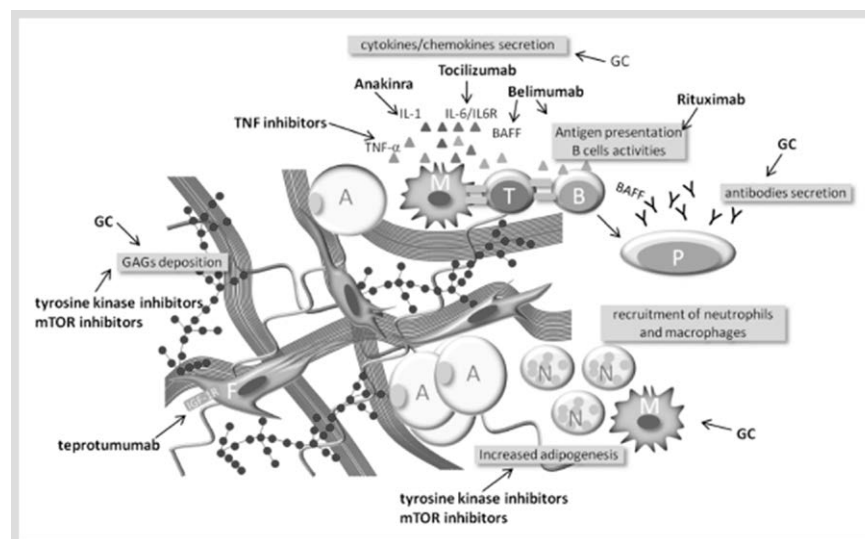


Fig. 2 Potential therapeutic targets for treatment of Graves' orbitopathy (GO). Beside steroids, direct targeting of the orbital fibroblast via immunosuppressive or non immunosuppressive agents is shown. Other immunosuppressants may target tissue antigens, cytokines involved in GO inflammation and immune cells.

A: Adipocyte; B: B-lymphocyte; F: Fibroblast; M: Macrophage; N: Neutrophils; T: T-lymphocyte; GC: Glucocorticoids; GAGs: Glycosaminoglycans; IL1/6: Interleukin 1/6; TNF: Tumor necrosis factor; BAFF: B-cell activating factor; IGF1R: Insulin-like growth factor-1 receptor. (Color figure available online only).

molecules as well as their *in vitro* and *in vivo* actions are extensively described below.

Targeting the IGF-1 receptor

The potential therapeutic use of low molecular weight TSHR analogues is discussed below in this review. The IGF-1R is co-expressed on orbital fibroblasts along with the TSH-R and *in vitro* blocking of the IGF-1R attenuates TSH-dependent signaling. Teprotumumab (RV 001, R1507) is a specific fully human monoclonal antibody that binds to the extracellular-subunit domain of IGF-1 receptor (IGF-1R) and is currently under investigation in patients with moderate-severe GO in an in-phase 2 multicenter placebo-controlled randomized clinical trial conducted in the U.S. and in Europe [67]. Teprotumumab is able either to decrease the expression of TSHR and IGF-1R on fibrocytes or to attenuate TSH-dependent IL-6 and IL-8 expression and Akt phosphorylation [67].

Targeting other modifiers of orbital tissue remodeling

Recently, Zhang et al. reported the efficacy of inhibitors of PI3K/mTORC1 cascades in an *in vitro* model of GO in reducing hyaluronan accumulation and adipogenesis [68]. The PI3K/mTOR signaling pathway is involved in basic biological processes such as cell proliferation, survival, migration, glucose metabolism, and nutrient sensors. However, first-generation inhibitors, such as wortmannin, LY294002, or rapamycin and its derivatives have shown undesirable side effects including stomatitis, noninfectious pneumonitis, secondary infections, hyperglycemia, and dyslipidemia. At present second-generation inhibitors are currently used in clinical trials on patients with refractory cancers [69].

Another possible player in GO pathogenesis is the platelet-derived growth factor (PDGF)-receptor and a PDGF-BB isoform has recently been found expressed and increased in the orbital tissue of GO patients [70–73]. PDGF-R signaling on orbital fibroblast can be blocked by tyrosine kinase inhibitors, such as imatinib mesylate and nilotinib.

Another structurally different tyrosine kinase inhibitor, dasatinib, has recently been approved as second-line therapy for chronic myeloid leukemia. Dasatinib has been found to reduce the production of the extracellular matrix components fibronectin and collagen by skin fibroblasts in systemic sclerosis [73] and very recently it has been found to decrease *in vitro* the mRNA expression of hyaluronan synthetase 2 (HAS-2), CCL2, IL-6, and IL-8 in orbital tissue from active GO, thus confirming that this or similar compounds may represent a promising therapeutic approach for GO [72].

Unfortunately, these 2 compounds are associated to serious side effects. In addition, Li et al. recently established a 3D *in vitro* model of GO, which allows measurement of contractile and adipogenic properties of orbital fibroblast. The authors used this model to study the potential effects of several drug in the treatment of GO: in particular, imatinib treatment resulted in an exaggerated adipogenic response in GO fibroblasts. This effects might limit the use of imatinib as a treatment for GO. On the contrary, an anti-IGF1R antibody IGF-1R had no effects on adipogenesis, but significant attenuated the contractile phenotype, suggesting that IGF-1R antagonists might target the proliferative/fibrotic component of GO and a Src family kinase (SFK) inhibitor PP2, which exerted an inhibitory effect on both the contractile and the adipogenic potential of GO fibroblasts [74].

Targeting cytokines/chemokines with monoclonal antibodies

In the active phase of GO there is a predominant production of pro-inflammatory and Th1-derived cytokines such as IL-6 and IL-1, and IFN-gamma-induced chemokines, such as CXCL10. Th2-derived cytokines, including IL-4, IL-5, and IL-10 are more likely associated to the inactive phase of GO [75].

There is evidences that immunoglobulins binding the TSH receptor binding may increase the expression of IL-1 receptor on orbital fibroblasts [76]. Therefore, it has been hypothesized that Anakinra, an interleukin-1 (IL-1) receptor antagonist, may play a therapeutic role in GO, although its low *in vivo* stability may compromise the therapeutic efficacy [77], but this hypothesis has not been challenged in a therapeutic trial.

The class of biological compounds known as TNF inhibitors (etanercept, infliximab, adalimumab) have also been widely used in autoimmune rheumatic diseases. Etanercept is a recombinant dimeric fusion protein consisting of 2 molecules of the soluble, extracellular ligand-binding portion of the human TNF receptor linked to the Fc portion of human immunoglobulin G1. It binds TNF, blocking the interaction with its receptors, thus preventing TNF-mediated inflammatory responses. In 2005 Paridaens et al. [78] have treated 10 patients with active moderate-severe GO and noted clinical improvement of the soft tissue signs in 6. The authors could not show an advantage over therapy with ivMP, in terms of efficacy and side effects.

Another important pathway in active GO is represented by the IL-6/sIL-6 receptor system. Elevated serum sIL-6R concentrations were in fact measured in patients with active GO [79]. Tocilizumab is a recombinant, humanized monoclonal antibody that acts as an interleukin IL-6 receptor antagonist. Several studies demonstrated the efficacy of intravenous tocilizumab in patients with rheumatoid arthritis by improving disease activity, even when refractory to standard therapy. Promising results have been recently obtained in a study of 18 patients with GO refractory to ivMP treatment [80]. After tocilizumab infusion, CAS improved in 100% patients, proptosis decreased in 72%, and ocular motility improved in 83%. In this cohort, one patient with compressive optic neuropathy improved, avoiding orbital decompression. These results are to be considered preliminary and this modality of treatment warrants further clinical trials. Increased serum BAFF concentrations have been detected in patients with Hashimoto' thyroiditis [81] and more recently in those with Graves' disease with and without orbitopathy [82], suggesting that anti-BAFF therapy may be an option in the management of Graves' disease. Belimumab, a mAb against BAFF, has been tried in patients with RA and SLE and has shown clear biologic effects on B cells and Ig levels with moderate clinical benefits mainly in SLE.

Targeting B Cells with Rituximab

▼
Rituximab (RTX) has been used off-label in several autoimmune disease but is approved for clinical use only in rheumatoid arthritis and antineutrophil cytoplasmic antibody-associated (ANCA) vasculitis. RTX is a chimeric mouse-human monoclonal antibody that targets CD20, a human B lymphocyte-specific antigen expressed on more than 95% of B cells from the stages of immature to mature B cells, but not on antibody-producing plasma cells [83]. As a consequence, therapy with RTX does not remove long-lived plasma cells from the peripheral blood and

antibody production is maintained, despite peripheral B cell depletion [84]. The rationale for using RTX in GO is the potential blockade of pathogenic autoantibody generation and production of inflammatory cytokines or the depletion of B cells as antigen-presenting cells. RTX may affect specific B cell clones arising from the germinal centers or even extrafollicular lymphoid structures without interfering with B and T cell interaction, therefore having little therapeutic impact on pathogenic specific autoantibodies [85]. Unexpected depletion of T cells, mainly CD4⁺ cells, has been recently observed in patients with rheumatoid arthritis treated with RTX [86]. The implications of this data is that RTX may be indirectly responsible also for the depletion of autoreactive T cells, as a consequence of the decrease of T cell promoting cytokines and chemokines released by B cells, depleted by RTX.

Preliminary studies have suggested that RTX can be effective either as first line treatment for moderate to severe GO or as additional therapy in patients resistant to ivMP [87–93].

Side Effects of Rituximab

In rheumatoid arthritis, the half life of RTX has been recorded to be 20 days after 2 doses of 1000 mg, the dose suggested for most autoimmune diseases [94]. Studies addressing dose/response relationship of RTX are lacking. A recent meta-analysis of randomized trials in RA has shown no significant differences in the primary clinical outcomes when 1000 mg twice were compared to 500 mg twice, 2 weeks apart [95]. The use of lower RTX doses may ultimately lead to significant reduction of treatment costs in chronic disease and the incidence of first infusion reactions. These reactions may be present in 10–30% of patients at first infusion and can be severe, but reversible [96]. Release of pro-inflammatory cytokines from macrophages, monocytes, lymphocytes and NK cells is the underlying mechanism. Activation of complement cascade may be responsible of fever, chill and skin rashes [97]. Infections have been reported as major side effects attributed to the decrease of immunoglobulin levels after RTX repeated doses. Recent large retrospective studies on patients affected with multisystem autoimmune disease have shown that severe infections observed in patients treated with RTX were associated to higher exposure to steroids and other immunosuppressants but not to hypogammaglobulinemia [98]. Progressive multifocal leukoencephalopathy (PML) has rarely been reported in patients receiving RTX, especially those with systemic lupus erythematosus (SLE). It is again important to point out that all these patients had previously been treated with other immunosuppressive therapies including cyclophosphamide, azathioprine and even steroids, oral prednisone or intravenous steroids [99].

Rituximab in GO: Dosage and Efficacy

Since the first report on successful treatment of one patient with moderate-severe GO [87], several noncontrolled studies on the effects of RTX in GO have appeared in the literature, reviewed by Salvi et al. [100]. In addition, one randomized controlled trial comparing RTX to placebo [101] and one comparing RTX to steroids [102] in moderate-severe GO have just been published. In earlier reports [87, 103] RTX was employed in patients with active GO who were unresponsive to standard ivMP therapy.

Subsequently, RTX therapy has been used as a first line treatment in patients not treated previously with steroids in an open study [89], with disease inactivation at the end of follow-up and improvement also of proptosis, eye muscle motility and signs of soft tissue inflammation. Reactivation of GO was never observed after RTX, but it is known to occur in 10–20% of patients treated with steroids [58].

The results of 2 randomized clinical trials employing RTX in GO have just been published. Salvi et al. [104] have studied 32 patients with active moderate-severe GO, treated with RTX or ivMP, and studied the decrease of the CAS as a primary end point. The CAS decreased more significantly after RTX, whether patients had received 1000 mg twice or a single dose of 500 mg and, at 24 weeks, 100% of patients after RTX improved compared to 69% after ivMP ($p < 0.001$). Disease reactivation was never observed in patients treated with RTX, but in 5 after ivMP. Data on disease severity parameters have shown that either treatment was not effective on proptosis, palpebral aperture and the total eye score, but RTX proved to be more effective than ivMP on motility and quality of life, thus suggesting that RTX acts as a disease modifying therapy, compared to steroids. Stan and colleagues [101] did not find RTX effective in treating active GO, when compared to placebo. The study was conducted on 21 patients, of whom 2, after RTX, developed optic neuropathy. Major differences that may have influenced the outcome of their study are a much longer disease duration (11.2 vs. 4.5 months), a greater number of patients previously treated with steroids (40 vs. 19%), and a lesser degree of motility involvement (mean diplopia score 2 vs. 3.5). Failure of RTX was previously reported in one patient whose GO did not respond to therapy and subsequently progressed to acute DON [105], similarly to the 2 patients herein described [101]. It is possible that in these patients subclinical DON was already present at the time of therapy and that the orbital edema caused by cytokine release after the administration of RTX may have increased intraorbital tissue congestion and optic nerve compression. On the other hand, RTX has also been employed successfully in another 10 patients with DON [91, 93, 106], resulting in improvement of visual sight. This data need to be confirmed in larger studies and until then we suggest caution in administering RTX in severe disease, particularly when patients have GO of long duration or subclinical DON. We envisage that further and larger randomized controlled trials will be needed for definitive data on the potential disease modifying role of RTX in GO and its superiority over standard treatment with steroids.

Dosage schedules of RTX in GO have been quite different due to the lack of randomized trials. The infusion of 1000 mg twice, with a 2 week interval, standardized for the treatment of RA and other autoimmune diseases has been reported to be effective in most open studies [91, 93] and in case reports [87, 107]. Successful peripheral B cell depletion following very low dose RTX was shown in a study by Salvi et al. [108] in 2 patients in whom RTX was discontinued because of the development of a transient cytokine release reaction, after receiving only 100 mg of the drug. Interestingly, after spontaneous resolution of the side effect, clinical improvement with GO inactivation occurred within a few weeks, despite the administration of a dose about 20 times less than the standard dose used in systemic autoimmune disease. More recently, a dose finding analysis in the randomized clinical trial of Salvi et al. has shown that a single dose of 500 mg RTX is as effective as 2 doses of 1000 mg, 2 weeks apart, in inactivating GO [104].

Other Treatment Options

The rationale for the use of octreotide and lanreotide in GO was supported by the observation that somatostatin receptors are expressed on the surface of both orbital fibroblasts [109] or orbital lymphocytes [110]; in addition, orbital octreoscan may be positive in active GO and it has been suggested that it can be used as an index to predict GO response to immunosuppressive therapy [111]. Four randomized controlled trials have shown that both octreotide and lanreotide have only minor effects on GO [112–115]; accordingly, their use is presently not justified [116, 117]. Novel somatostatin analogues are now available, such as pasireotide, which has in vitro a stronger inhibitory effect on orbital adipogenesis than octreotide [118], suggesting that it may be more effective in GO.

Only 2 randomized controlled studies have addressed the efficacy of cyclosporine [41, 119] in the treatment of moderate to severe GO. Cyclosporine (3–5 mg/kg/day) seems less effective compared to glucocorticoids if given as monotherapy. The combination of both drugs might be more effective than either treatment alone. However, cyclosporine administration is associated with significant side effects. Data on the use of intravenous immunoglobulins (IVIg) are conflicting [120]; considering their high cost and the risks deriving from the use of plasma-derived products, this treatment is currently not recommended.

Second line treatment

A significant proportion (20–30%) of patients with GO fail to respond to medical treatment. There is no definitive agreement on how to treat these patients and the decision about a second line treatment of active moderate-severe GO is based more on experts' opinion than on clinical evidence. Such patients should be better referred to a specialized center, since they are more prone to develop complications. If oral steroids were initially used, then ivMP might be beneficial, as long as the therapy does not exceed a safe total cumulative dose of steroids. RTX is actually a good alternative to steroids in nonresponders, as its mechanism of action is different, but the administration of this and other biological agents should be limited only to experienced centers, until the results of multicenter RCT trials on a greater number of patients will be available [39]. Combination therapy is at the moment a good option with orbital radiotherapy associated with either oral steroids or ivMP, or alternatively, with cyclosporin.

Treatment of sight-threatening ophthalmopathy

Sight threatening GO accounts for about 3–5% of patients and is due to either compressive optic neuropathy, known as dysthyroid optic neuropathy (DON), or severe corneal damage resulting from severe corneal exposure. In general, the golden standard of therapy for DON is urgent orbital decompression, although up to 40% of patients may respond to a course of high dose ivMP within 1–2 weeks [121, 122]. While cigarette smoking, the male gender, restrictive strabismus, and rapidly progressive GO are considered factor risk for the development of DON [123, 124], the diagnosis of DON is sometimes challenging and distinction from subclinical and overt forms is not always straightforward. A survey among EUGOGO members in 2007 found that optic disc swelling, impaired color vision, and radiological evidence of apical optic nerve crowding are the most useful clinical features. Optic disc swelling, if present, is a very specific for DON, although in few patients a normal appearance of optic nerve may be

caused by the combination of edema and optic nerve atrophy. Also the impairment of color vision and radiological evidence of apical optic nerve compression further support the diagnosis of DON [124].

The results of 2 small studies suggest that the first line treatment should be high dose ivMP, either 500 mg or 1 000 mg of methylprednisolone daily for 3 consecutive days, repeated one week later. If the patient responds and recovers normal vision, this therapy may be followed by oral prednisone tapered down in a few weeks or by weekly pulses of ivMP, up to a cumulative dose of 8 g [121, 122]. Urgent orbital decompression should be performed if patients do not respond to ivMP or when such treatment is contraindicated [121, 122].

Acknowledgements

This work is supported in part by MIUR, Roma and by Fondazione Ca' Granda, IRCCS, Milano, Italy.

Conflict of Interest

The authors declare no conflict of interest.

References

- 1 Prummel MF 1, Bakker A, Wiersinga WM, Baldeschi L, Mourits MP, Kendall-Taylor P, Perros P, Neoh C, Dickinson AJ, Lazarus JH, Lane CM, Heufelder AE, Kahaly GJ, Pitz S, Orgiazzi J, Hullo A, Pinchera A, Marcocci C, Sartini MS, Rocchi R, Nardi M, Krassas GE, Halkias A. Multi-center study on the characteristics and treatment strategies of patients with Graves' orbitopathy: the first European Group on Graves' Orbitopathy experience. *Eur J Endocrinol* 2003; 148: 491–495
- 2 Perros P, Žarković M, Azzolini C, Ayvaz G, Baldeschi L, Bartalena L, Boschi A, Bournaud C, Brix TH, Covelli D, Čirić S, Daumerie C, Eckstein A, Fichter N, Führer D, Hegedüs L, Kahaly GJ, Konuk O, Lareida J, Lazarus J, Leo M, Mathiopoulos L, Menconi F, Morris D, Okosieme O, Orgiazzi J, Pitz S, Salvi M, Vardanian-Vartin C, Wiersinga W, Bernard M, Clarke L, Currò N, Dayan C, Dickinson J, Knežević M, Lane C, Marcocci C, Marinò M, Möller L, Nardi M, Neoh C, Pearce S, von Arx G, Törüner FB. PREGO (presentation of Graves' orbitopathy) study: changes in referral patterns to European Group On Graves' Orbitopathy (EUGOGO) centres over the period from 2000 to 2012. *Br J Ophthalmol* 2015; May 7. pii: bjophthalmol-2015-306733. doi: 10.1136/bjophthalmol-2015-306733. [Epub ahead of print]
- 3 Menconi F, Profilo MA, Leo M, Sisti E, Altea MA, Rocchi R, Latrofa F, Nardi M, Vitti P, Marcocci C, Marinò M. Spontaneous improvement of untreated mild Graves' ophthalmopathy: Rundle's curve revisited. *Thyroid* 2014; 24: 60–66
- 4 Marcocci C, Marinò M. Treatment of mild, moderate-to-severe and very severe Graves' orbitopathy. *Best Pract Res Clin Endocrinol Metab* 2012; 26: 325–337
- 5 Perros P, Crombie AL, Kendall-Taylor P. Natural history of thyroid associated ophthalmopathy. *Clin Endocrinol* 1995; 42: 45–50
- 6 Streeten DH, Anderson GH Jr., Reed GF, Woo P. Prevalence, natural history and surgical treatment of exophthalmos. *Clin Endocrinol* 1987; 27: 125–133
- 7 Noth D, Gebauer M, Muller B, Burgi U, Diem P. Graves' ophthalmopathy: natural history and treatment outcomes. *Swiss Med Wkly* 2001; 131: 603–609
- 8 Tanda ML, Piantanida E, Liparulo L, Veronesi G, Lai A, Sassi L, Pariani N, Gallo D, Azzolini C, Ferrario M, Bartalena L. Prevalence and natural history of Graves' orbitopathy in a large series of patients with newly diagnosed Graves' hyperthyroidism seen at a single center. *J Clin Endocrinol Metab* 2013; 98: 1443–1449
- 9 Hegedüs L, Bonnema SJ, Smith TJ, Brix TH. Treating the thyroid in the presence of Graves' ophthalmopathy. *Best Pract Res Clin Endocrinol Metab* 2012; 26: 313–324
- 10 Terwee C, Wakelkamp I, Tan S, Dekker F, Prummel MF, Wiersinga W. Long-term effects of Graves' ophthalmopathy on health-related quality of life. *Eur J Endocrinol* 2002; 146: 751–717

- 11 Wiersinga WM, Prummel MF, Terwee CB. Effects of Graves' ophthalmopathy on quality of life. *J Endocrinol Invest* 2004; 27: 259–264
- 12 Lai A, Sassi L, Compri E, Marino F, Sivelli P, Piantanida E, Tanda ML, Bartalena L. Lower dose prednisone prevents radioiodine-associated exacerbation of initially mild or absent Graves' orbitopathy: a retrospective cohort study. *J Clin Endocrinol Metab* 2010; 95: 1333–1337
- 13 Dederichs B, Dietlein M, Jenniches-Kloth B, Schmidt M, Theissen P, Moka D, Schicha H. Radioiodine therapy of Graves' hyperthyroidism in patients without pre-existing ophthalmopathy: can glucocorticoids prevent the development of new ophthalmopathy? *Exp Clin Endocrinol Diabetes* 2006; 114: 366–370
- 14 Shiber S, Stiebel-Kalish H, Shimon I, Grossman A, Robenshtok E. Glucocorticoid regimens for prevention of Graves' ophthalmopathy progression following radioiodine treatment: systematic review and meta-analysis. *Thyroid* 2014; 24: 1515–1523
- 15 Leo M, Marcocci C, Pinchera A, Nardi M, Megna L, Rocchi R, Latrofa F, Altea MA, Mazzi B, Sisti E, Profilo MA, Marinò M. Outcome of Graves' orbitopathy after total thyroid ablation and glucocorticoid treatment: follow-up of a randomized clinical trial. *J Clin Endocrinol Metab* 2012; 97: E44–E48
- 16 Menconi F, Marinò M, Pinchera A, Rocchi R, Mazzi B, Nardi M, Bartalena L, Marcocci C. Effects of total thyroid ablation vs. near-total thyroidectomy alone on mild to moderate Graves' orbitopathy treated with intravenous glucocorticoids. *J Clin Endocrinol Metab* 2007; 92: 1653–1658
- 17 Moleti M, Violi MA, Montanini D, Trombetta C, Di Bella B, Sturniolo G, Presti S, Alibrandi A, Campenni A, Baldari S, Trimarchi F, Vermiglio F. Radioiodine ablation of postsurgical thyroid remnants after treatment with recombinant human TSH (rhTSH) in patients with moderate-to-severe Graves' orbitopathy (GO): a prospective, randomized, single-blind clinical trial. *J Clin Endocrinol Metab* 2014; 99: 1783–1789
- 18 Catania A, Gaiatoli E, Carbotta G, Bianchini M, Di Matteo FM, Carbotta S, Nardi M, Fabiani E, Grani G, D'Andrea V, Fumarola A. Total thyroidectomy for Graves' disease treatment. *Clin Ter* 2013; 164: 193–196
- 19 Bartalena L. The dilemma of how to manage Graves' hyperthyroidism in patients with associated orbitopathy. *J Clin Endocrinol Metab* 2011; 96: 592–599
- 20 Bartalena L, Baldeschi L, Dickinson A, Eckstein A, Kendall-Taylor P, Marcocci C, Mourits M, Perros P, Boboridis K, Boschi A, Currò N, Daumerie C, Kahaly GJ, Krassas GE, Lane CM, Lazarus JH, Marinò M, Nardi M, Neoh C, Orgiazzi J, Pearce S, Pinchera A, Pitz S, Salvi M, Sivelli P, Stahl M, von Arx G, Wiersinga WM. Consensus statement of the European Group on Graves' Orbitopathy (EUGOGO) on management of GO. *Eur J Endocrinol* 2008; 158: 273–285
- 21 Kendall-Taylor P, Perros P. Clinical presentation of thyroid associated orbitopathy. *Thyroid* 1998; 8: 427–428
- 22 Piantanida E, Tanda ML, Lai A, Sassi L, Bartalena L. Prevalence and natural history of Graves' orbitopathy in the XXI century. *J Endocrinol Invest* 2013; 36: 444–449
- 23 Salvi M, Currò N. Management of mild Graves' orbitopathy. In Wiersinga WM, Kahaly GJ (eds.). *Graves' orbitopathy. A multidisciplinary approach – questions and answers. 2nd, revised version.* Basel: Karger; 2010: 111–119
- 24 Bartalena L. Graves' Disease Complications. In: De Groot LJ. *Thyroid Disease Manager*. Chapter 12 <http://www.thyroidmanager.org/>
- 25 Altıparmak UE, Acar DE, Ozer PA, Emec SD, Kasim R, Ustun H, Duman S. Topical cyclosporine A for the dry eye findings of thyroid orbitopathy patients. *Eye* 2010; 24: 1044–1050
- 26 Gürdal C, Genç I, Saraç O, Gönül I, Takmaz T, Can I. Topical cyclosporine in thyroid orbitopathy-related dry eye: clinical findings, conjunctival epithelial apoptosis, and MMP-9 expression. *Curr Eye Res* 2010; 35: 771–777
- 27 Uddin JM, Davies PD. Treatment of upper eyelid retraction associated with thyroid eye disease with subconjunctival botulinum toxin injection. *Ophthalmology* 2002; 109: 1183–1187
- 28 Pfeilschifter J, Ziegler R. Smoking and endocrine ophthalmopathy: impact of smoking severity and current vs lifetime cigarette consumption. *Clin Endocrinol* 1996; 45: 477–481
- 29 Bartalena L, Bogazzi F, Tanda ML, Manetti L, Dell'Unto E, Martino E. Cigarette smoking and the thyroid. *Eur J Endocrinol* 1995; 133: 507–512
- 30 OECD Health Data 2012. Eurostat Statistics Database; WHO Global Infobase
- 31 Marcocci C, Bartalena L. Role of oxidative stress and selenium in Graves' hyperthyroidism and orbitopathy. *J Endocrinol Invest* 2013; 36: 15–20
- 32 Marcocci C, Kahaly GJ, Krassas GE, Bartalena L, Prummel M, Stahl M, Altea MA, Nardi M, Pitz S, Boboridis K, Sivelli P, von Arx G, Mourits MP, Baldeschi L, Bencivelli W, Wiersinga W. *European Group on Graves' Orbitopathy*. Selenium and the course of mild Graves' orbitopathy. *N Engl J Med* 2011; 364: 1920–1931
- 33 Bahn RS, Heufelder AE. Pathogenesis of Graves ophthalmopathy. *Engl J Med* 1993; 329: 1468–1475
- 34 Dolman PJ. Evaluating Graves' orbitopathy. *Best Pract Res Clin Endocrinol Metab* 2012; 26: 229–248
- 35 Heufelder AE, Wenzel BE, Bahn RS. Glucocorticoids modulate the synthesis and expression of a 72 kDa heat shock protein in cultured Graves' retroocular fibroblasts. *Acta Endocrinol* 1993; 128: 41–50
- 36 Goldberg RA. Orbital steroid injections. *Br J Ophthalmol* 2004; 88: 1359–1360
- 37 Marcocci C, Bartalena L, Tanda ML, Manetti L, Dell'Unto E, Rocchi R, Barbesino G, Mazzi B, Bartolomei MP, Lepri P, Cartei F, Nardi M, Pinchera A. Comparison of the effectiveness and tolerability of intravenous or oral glucocorticoids associated with orbital radiotherapy in the management of severe Graves' ophthalmopathy: results of a prospective, single-blind, randomized study. *J Clin Endocrinol Metab* 2001; 86: 3562–3567
- 38 Kahaly GJ, Pitz S, Hommel G, Dittmar M. Randomized, single blind trial of intravenous versus oral steroid monotherapy in Graves' orbitopathy. *J Clin Endocrinol Metab* 2005; 90: 5234–5240
- 39 Kahaly GJ. Management of moderately severe Graves' orbitopathy. In: Wiersinga WM, Kahaly GJ (eds.). *Graves' orbitopathy. A multidisciplinary approach – Questions and answers. 2nd, revised version.* Basel: Karger; 2010: 120–158
- 40 Bartalena L, Marcocci C, Chiovato L, Laddaga M, Lepri G, Andreani D, Cavallacci G, Baschieri L, Pinchera A. Orbital cobalt irradiation combined with systemic corticosteroids for Graves' ophthalmopathy: comparison with systemic corticosteroids alone. *J Clin Endocrinol Metab* 1983; 56: 1139–1144
- 41 Kahaly G, Schrezenmeier J, Krause U, Schweikert B, Meuer S, Muller W, Dennebaum R, Beyer J. Cyclosporine and prednisone v. prednisone in treatment of Graves' ophthalmopathy: a controlled, randomized and prospective study. *Eur J Clin Invest* 1986; 16: 415–422
- 42 Kung AW, Michon J, Tai KS, Chan FL. The effect of somatostatin versus corticosteroid in the treatment of Graves' ophthalmopathy. *Thyroid* 1996; 6: 381–384
- 43 Kahaly G, Pitz S, Müller-Forell W, Hommel G. Randomized trial of intravenous immunoglobulins versus prednisolone in Graves' ophthalmopathy. *Clin Exp Immunol* 1996; 106: 197–202
- 44 van Geest RJ, Sasim IV, Koppeschaar HP, Kalmann R, Stravers SN, Bijlsma WR, Mourits MP. Methylprednisolone pulse therapy for patients with moderately severe Graves' orbitopathy: a prospective, randomized, placebo-controlled study. *Eur J Endocrinol* 2008; 158: 229–237
- 45 Matejka G, Vergès B, Vaillant G, Petit JM, Brun-Pacaud A, Rudoni S, Brun JM. Intravenous methylprednisolone pulse therapy in the treatment of Graves' ophthalmopathy. *Horm Metab Res* 1998; 30: 93–98
- 46 Kendall-Taylor P, Crombie AL, Stephenson AM, Hardwick M, Hall K. Intravenous methylprednisolone in the treatment of Graves' ophthalmopathy. *BMJ* 1988; 297: 1574–1578
- 47 Aktaran S, Akarsu E, Erbağcı I, Araz M, Okumuş S, Kartal M. Comparison of intravenous methylprednisolone therapy vs. oral methylprednisolone therapy in patients with Graves' ophthalmopathy. *Int J Clin Pract* 2007; 61: 45–51
- 48 Kauppinen-Mäkelin R, Karma A, Leinonen E, Löytyniemi E, Salonen O, Sane T, Setälä K, Viikari J, Heufelder A, Välimäki M. High dose intravenous methylprednisolone pulse therapy versus oral prednisone for thyroid-associated ophthalmopathy. *Acta Ophthalmol Scand* 2002; 80: 316–321
- 49 Macchia PE, Bagattini M, Lupoli G, Vitale M, Vitale G, Fenzi G. High-dose intravenous corticosteroid therapy for Graves' ophthalmopathy. *J Endocrinol Invest* 2001; 24: 152–158
- 50 Zang S, Ponto KA, Kahaly GJ. Intravenous glucocorticoids for Graves' orbitopathy: efficacy and morbidity. *J Clin Endocrinol Metab* 2011; 96: 320–332
- 51 Gao G, Dai J, Qian Y, Ma F. Meta-analysis of methylprednisolone pulse therapy for Graves' ophthalmopathy. *Clin Experiment Ophthalmol* 2014; 42: 769–777
- 52 Bartalena L, Krassas GE, Wiersinga W, Marcocci C, Salvi M, Daumerie C, Bornaoud C, Stahl M, Sassi L, Veronesi G, Azzolini C, Boboridis KG, Mourits MP, Soeters MR, Baldeschi L, Nardi M, Currò N, Boschi A, Bernard M, von Arx G and the European Group on Graves' Orbitopathy. Efficacy and safety of three different cumulative doses of intravenous methylprednisolone for moderate to severe and active Graves' orbitopathy. *J Clin Endocrinol Metab* 2012; 97: 4454–4463

- 53 Vannucchi G, Covelli D, Campi I, Origo D, Currò N, Cirello V, Dazzi D, Beck-Peccoz P, Salvi M. The therapeutic outcome to intravenous steroid therapy for active Graves' orbitopathy is influenced by the time of response but not polymorphisms of the glucocorticoid receptor. *Eur J Endocrinol* 2013; 22: 170: 55–61
- 54 Weissel M, Hauff W. Fatal liver failure after high-dose glucocorticoid pulse therapy in a patient with severe thyroid eye disease. *Thyroid* 2000; 10: 521
- 55 Marinò M, Morabito E, Brunetto MR, Bartalena L, Pinchera A, Marcocci C. Acute and severe liver damage associated with intravenous glucocorticoid pulse therapy in patients with Graves' ophthalmopathy. *Thyroid* 2004; 14: 403–406
- 56 Lendorf ME, Rasmussen AK, Fledelius HC, Feldt-Rasmussen U. Cardiovascular and cerebrovascular events in temporal relationship to intravenous glucocorticoid pulse therapy in patients with severe endocrine ophthalmopathy. *Thyroid* 2009; 19: 1431–1432
- 57 Gursoy A, Cesur M, Erdogan MF, Corapcioglu D, Kamel N. New-onset acute heart failure after intravenous glucocorticoid pulse therapy in a patient with Graves' ophthalmopathy. *Endocrine* 2006; 29: 513–516
- 58 Owecki M, Sowinski J. Acute myocardial infarction during high-dose methylprednisolone therapy for Graves' ophthalmopathy. *Pharm World Sci* 2006; 28: 73–75
- 59 Marcocci C, Watt T, Altea MA, Rasmussen AK, Feldt-Rasmussen U, Orgiazzi J, Bartalena L, European Group of Graves' Orbitopathy. Fatal and non-fatal adverse events of glucocorticoid therapy for Graves' orbitopathy: a questionnaire survey among members of the European Thyroid Association. *Eur J Endocrinol* 2011; 166: 247–253
- 60 Le Moli R, Baldeschi L, Saeed P, Regenburg N, Mourits MP, Wiersinga WM. Determinants of liver damage associated with intravenous methylprednisolone pulse therapy in Graves' ophthalmopathy. *Thyroid* 2007; 17: 357–362
- 61 Marinò M, Morabito E, Altea MA, Ambrogini E, Oliveri F, Brunetto MR, Pollina LE, Campani D, Vitti P, Bartalena L, Pinchera A, Marcocci C. Autoimmune hepatitis during intravenous glucocorticoid pulse therapy for Graves' ophthalmopathy treated successfully with glucocorticoids themselves. *J Endocrinol Invest* 2005; 28: 280–284
- 62 Salvi M, Vannucchi G, Sbrozzi F, Del Castello AB, Carnevali A, Fargion S, Beck-Peccoz P. Onset of autoimmune hepatitis during intravenous steroid therapy for thyroid associated ophthalmopathy in a patient with Hashimoto's thyroiditis: case report. *Thyroid* 2004; 14: 631–634
- 63 Bahn RS. Current insights into the pathogenesis of Graves' ophthalmopathy. *Horm Metab Res* 2015; 47: in press
- 64 Salvi M. Immunotherapy for Graves' ophthalmopathy. *Curr Opin Endocrinol Diabetes Obes* 2014; 21: 409–414
- 65 Neumann S, Place RF, Krieger CC, Gershengorn MC. Future prospects for the treatment of Graves' hyperthyroidism and eye disease. *Horm Metab Res* 2015; 47: in press
- 66 Gershengorn MC, Neumann S. Update in TSH receptor agonists and antagonists. *J Clin Endocrinol Metab* 2012; 97: 4287–4292
- 67 Chen H, Mester T, Raychaudhuri N, Kauh CY, Gupta S, Smith TJ, Douglas RS. Teprotumumab, an IGF-1R blocking monoclonal antibody inhibits TSH and IGF-1 action in fibrocytes. *J Clin Endocrinol Metab* 2014; 99: E1635–E1640
- 68 Zhang L, Grennan-Jones F, Draman MS, Lane C, Morris D, Dayan CM, Tee AR, Ludgate M. Author information Possible targets for nonimmunosuppressive therapy of Graves' orbitopathy. *J Clin Endocrinol Metab* 2014; 99: E1183–E1190
- 69 Jerusalem G, Rorive A, Collignon J. Use of mTOR inhibitors in the treatment of breast cancer: an evaluation of factors that influence patient outcomes. *Breast Cancer* 2014; 17 6: 43–57
- 70 van Steensel L, Paridaens D, van Meurs M, van Hagen PM, van den Bosch WA, Kuipers RW, Drexhage HA, Hooijkaas H, Dik WA. Orbit-infiltrating mast cells, monocytes, and macrophages produce PDGF isoforms that orchestrate orbital fibroblast activation in Graves' ophthalmopathy. *J Clin Endocrinol Metab* 2012; 97: E400–E408
- 71 van Steensel L, van Hagen PM, Paridaens D, Kuipers RW, van den Bosch WA, Drexhage HA, Hooijkaas H, Dik WA. Whole orbital tissue culture identifies imatinib mesylate and adalimumab as potential therapeutics for Graves' ophthalmopathy. *Br J Ophthalmol* 2011; 95: 735–738
- 72 Virakul S, Dalm VA, Paridaens D, van den Bosch WA, Hirankarn N, van Hagen PM, Dik WA. The tyrosine kinase inhibitor dasatinib effectively blocks PDGF-induced orbital fibroblast activation. *Graefes Arch Clin Exp Ophthalmol* 2014; 252: 1101–1109
- 73 Distler JH, Distler O. Intracellular tyrosine kinases as novel targets for anti-fibrotic therapy in systemic sclerosis. *Rheumatology* 2008; 47 (Suppl 5): v10–v11
- 74 Li H, Fitchett C, Kozdon K, Jayaram H, Rose GE, Bailly M, Ezra DG. Independent adipogenic and contractile properties of fibroblasts in Graves' orbitopathy: an in vitro model for the evaluation of treatments. *PLoS One* 2014; 21; 9: e95586
- 75 Wakelkamp IM, Bakker O, Baldeschi L, Wiersinga WM, Prummel MF. TSH-R expression and cytokine profile in orbital tissue of active vs. inactive Graves' ophthalmopathy patients. *Clin Endocrinol* 2003; 58: 280–287
- 76 Li B, Smith TJ. Regulation of IL-1 receptor antagonist by TSH in fibrocytes and orbital fibroblasts. *J Clin Endocrinol Metab* 2014; 99: E625–E633
- 77 Pasi S, Kant R, Gupta S, Suroli A. Novel multimeric IL-1 receptor antagonist for the treatment of rheumatoid arthritis. *Biomaterials* 2015; 42: 121–133
- 78 Paridaens D, van den Bosch WA, van der Loos TL, Krenning EP, van Hagen PM. The effect of etanercept on Graves' ophthalmopathy: a pilot study. *Eye* 2005; 19: 1286–1289
- 79 Slowik M, Urbaniak-Kujda D, Bohdanowicz-Pawlak A, Kapelko-Slowik K, Dybko J, Wolowiec D, Jazwiec B, Daroszewski J. CD8+CD28-lymphocytes in peripheral blood and serum concentrations of soluble interleukin 6 receptor are increased in patients with Graves' orbitopathy and correlate with disease activity. *Endocr Res* 2012; 37: 89–95
- 80 Pérez-Moreiras JV, Alvarez-López A, Gómez EC. Treatment of active corticosteroid-resistant Graves' orbitopathy. *Ophthalm Plast Reconstr Surg* 2014; 30: 162–167
- 81 Fabris M, Grimaldi F, Villalta D, Picierno A, Fabro C, Bolzan M, De Vita S, Tonutti E. BlyS and April serum levels in patients with autoimmune thyroid diseases. *Autoimmun Rev* 2010; 9: 165–169
- 82 Vannucchi G, Covelli D, Currò N, Dazzi D, Maffini A, Campi I, Bonara P, Guastella C, Pignataro L, Ratiglia R, Beck-Peccoz P, Salvi M. Serum BAFF concentrations in patients with Graves' disease and orbitopathy before and after immunosuppressive therapy. *J Clin Endocrinol Metab* 2012; 97: E755–E759
- 83 Fan QW, Knight ZA, Goldenberg DD, Yu W, Mostov KE, Stokoe D, Shokat KM, Weiss WA. A dual PI3 kinase/mTOR inhibitor reveals emergent efficacy in glioma. *Cancer Cell* 2006; 9: 341–349
- 84 Kurtz J-E, Ray-Coquard I. PI3 kinase inhibitors in the clinic: an update. *Anticancer Res* 2012; 32: 2463–2470
- 85 Gong Q, Ou Q, Ye S, Lee WP, Cornelius J, Diehl L, Lin WY, Hu Z, Lu Y, Chen Y, Wu Y, Meng YG, Gribbling P, Lin Z, Nguyen K, Tran T, Zhang Y, Rosen H, Martin F, Chan AC. Importance of cellular microenvironment and circulatory dynamics in B cell immunotherapy. *J Immunol* 2005; 174: 817–826
- 86 Mélet J, Mulleman D, Goupille P, Ribourtout B, Watier H, Thibault G. Rituximab-induced T cell depletion in patients with rheumatoid arthritis: association with clinical response. *Arthritis Rheum* 2013; 65: 2783–2790
- 87 Salvi M, Vannucchi G, Campi I, Rossi S, Bonara P, Sbrozzi F, Guastella C, Avignone S, Pirola G, Ratiglia R, Beck-Peccoz P. Efficacy of rituximab treatment for thyroid-associated ophthalmopathy as a result of intraorbital B-cell depletion in one patient unresponsive to steroid immunosuppression. *Eur J Endocrinol* 2006; 154: 511–517
- 88 El Fassi D, Nielsen CH, Hasselbalch HC, Hegedüs L. Treatment-resistant severe, active Graves' ophthalmopathy successfully treated with B lymphocyte depletion. *Thyroid* 2006; 16: 709–710
- 89 Salvi M, Vannucchi G, Campi I, Currò N, Dazzi D, Simonetta S, Bonara P, Rossi S, Sina C, Guastella C, Ratiglia R, Beck-Peccoz P. Treatment of Graves' disease and associated ophthalmopathy with the anti-CD20 monoclonal antibody rituximab: an open study. *Eur J Endocrinol* 2007; 156: 33–40
- 90 Erdei A, Paragh G, Kovacs P, Karanyi Z, Berenyi E, Galuska L, Lenkey A, Szabados L, Gyory F, Ujhelyi B, Berta A, Boda J, Berta E, Bodor M, Gazdag A, Nagy EV. Rapid response to and long-term effectiveness of anti-CD20 antibody in conventional therapy resistant Graves' orbitopathy: A five-year follow-up study. *Autoimmunity* 2014; 47: 548–555
- 91 Mitchell AL, Gan EH, Morris M, Johnson K, Neoh C, Dickinson AJ, Perros P, Pearce SH. The effect of B cell depletion therapy on anti-TSH receptor antibodies and clinical outcome in glucocorticoid-refractory Graves' orbitopathy. *Clin Endocrinol* 2013; 79: 437–442
- 92 Salvi M, Vannucchi G, Currò N, Introna M, Rossi S, Bonara P, Covelli D, Dazzi D, Guastella C, Pignataro L, Ratiglia R, Golay J, Beck-Peccoz P. Small dose of rituximab for Graves' orbitopathy: new insights into the mechanism of action. *Arch Ophthalmol* 2012; 130: 122–124
- 93 Khanna D, Chong KK, Afifyan NF, Hwang CJ, Lee DK, Garneau HC, Goldberg RA, Darwin CH, Smith TJ, Douglas RS. Rituximab treatment of patients with severe, corticosteroid-resistant thyroid-associated ophthalmopathy. *Ophthalmology* 2010; 117: 133–139

- 94 Edwards JC, Leandro MJ, Cambridge G. B lymphocyte depletion therapy with rituximab in rheumatoid arthritis. *Rheum Dis Clin North Am* 2004; 30: 393–403
- 95 Bredemeier M, de Oliveira FK, Rocha CM. Low- versus high dose rituximab for rheumatoid arthritis: a systematic review and meta-analysis. *Arthritis Care Res* 2014; 66: 228–235
- 96 Descotes J. Immunotoxicity of monoclonal antibodies. *MAbs* 2009; 1: 104–111
- 97 van der Kolk LE, Grillo-López AJ, Baars JW, Hack CE, van Oers MH. Complement activation plays a key role in the side-effects of rituximab treatment. *Br J Haematol* 2001; 115: 807–811
- 98 van Vollenhoven RF, Emery P, Bingham CO 3rd, Keystone EC, Fleischmann RM, Furst DE, Tyson N, Collinson N, Lehane PB. Long-term safety of rituximab in rheumatoid arthritis: 9.5-year follow-up of the global clinical trial programme with a focus on adverse events of interest in RA patients. *Ann Rheum Dis* 2013; 72: 1496–502
- 99 Food and Drug Administration. FDA Public Health Advisory: life-threatening brain infection in patients with systemic lupus erythematosus after Rituxan (rituximab) treatment. <http://www.fda.gov/cder/drug/> 2006
- 100 Salvi M, Vannucchi G, Beck-Peccoz P. Potential utility of rituximab for Graves' orbitopathy. *J Clin Endocrinol Metab* 2013; 98: 4291–4299
- 101 Stan MN, Garrity JA, Carranza Leon BG, Prabin T, Bradley EA, Bahn RS. Randomized Controlled Trial of Rituximab in Patients With Graves' Orbitopathy. *J Clin Endocrinol Metab* 2014; 24: jc20142572
- 102 Salvi M, Vannucchi G, Currò N, Campi I, Covelli D, Dazzi D, Simonetta S, Guastella C, Pignataro L, Avignone S, Beck-Peccoz P. Efficacy of B-cell targeted therapy with rituximab in patients with active moderate to severe Graves' orbitopathy: a randomized controlled study. *J Clin Endocrinol Metab* 2015; 100: 422–431
- 103 El Fassi D, Banga JP, Gilbert JA, Padoa C, Hegedüs L, Nielsen CH. Treatment of Graves' disease with rituximab specifically reduces the production of thyroid stimulating autoantibodies. *Clin Immunol* 2009; 130: 252–258
- 104 Salvi M, Vannucchi G, Currò N, Campi I, Covelli D, Dazzi D, Simonetta S, Guastella C, Pignataro L, Avignone S, Beck-Peccoz P. Efficacy of b-cell targeted therapy with rituximab in patients with active moderate-severe Graves' orbitopathy: a randomized controlled study. *J Clin Endocrinol Metab* 2015; 100: 422–431
- 105 Krassas GE, Stafiliadou A, Boboridis KG. Failure of rituximab treatment in a case of severe thyroid ophthalmopathy unresponsive to steroids. *Clin Endocrinol* 2010; 72: 853–855
- 106 Salvi M, Vannucchi G, Campi I, Currò N, Simonetta S, Covelli D, Pignataro L, Guastella C, Rossi S, Bonara P, Dazzi D, Ratiglia R, Beck-Peccoz P. Rituximab treatment in a patient with severe thyroid-associated ophthalmopathy: effects on orbital lymphocytic infiltrates. *Clin Immunol* 2009; 131: 360–365
- 107 Madaschi S, Rossini A, Formenti I, Lampasona V, Bianchi Marzoli S, Cammarata G, Politi L, Martinelli V, Bazzigaluppi E, Scavini M, Bosi E, Lanzi R. *Endocr Pract* 2010; 16: 677–685
- 108 Salvi M, Vannucchi G, Currò N, Introna M, Rossi S, Bonara P, Covelli D, Dazzi D, Guastella C, Pignataro L, Ratiglia R, Golay J, Beck-Peccoz P. A small dose of rituximab may be sufficient to treat Graves' orbitopathy: new insights into the mechanism of action. *Arch Ophthalmol* 2012; 130: 122–124
- 109 Pasquali D, Vassallo P, Esposito D, Bonavolontà G, Bellastella A, Sinisi AA. Somatostatin receptor gene expression and inhibitory effects of octreotide on primary cultures of orbital fibroblasts from Graves' ophthalmopathy. *J Mol Endocrinol* 2000; 25: 63–71
- 110 Pasquali D, Notaro A, Bonavolontà G, Vassallo P, Bellastella A, Sinisi AA. Somatostatin receptor genes are expressed in lymphocytes from retroorbital tissues in Graves' disease. *J Clin Endocrinol Metab* 2002; 87: 5125–5129
- 111 Kahaly GJ. Recent developments in Graves' ophthalmopathy imaging. *J Endocrinol Invest* 2004; 27: 254–258
- 112 Dickinson AJ, Vaidya B, Miller M, Coulthard A, Perros P, Baister E, Andrews CD, Hesse L, Heverhagen JT, Heufelder AE, Kendall-Taylor P. Double-blind placebo-controlled trial of octreotide long-acting repeatable (LAR) in thyroid-associated ophthalmopathy. *J Clin Endocrinol Metab* 2004; 89: 5910–5915
- 113 Wemeau JL, Caron P, Beckers A, Rohmer V, Orgiazzi J, Borson-Chazot F, Nocudie M, Perimenis P, Bisot-Locard S, Bourdeix I, Dejager S. Octreotide (long-acting release formulation) treatment in patients with Graves' orbitopathy: clinical results of a four-month, randomized, placebo-controlled, double-blind study. *J Clin Endocrinol Metab* 2005; 90: 841–848
- 114 Chang T-C, Liao S-L. Slow-release lanreotide in Graves' ophthalmopathy: a double-blind randomized, placebo-controlled clinical trial. *J Endocrinol Invest* 2006; 29: 413–422
- 115 Stan MN, Garrity JA, Bradley EA, Woog JJ, Bahn MM, Brennan MD, Bryant SC, Achenbach SJ, Bahn RS. Randomized, placebo-controlled, double-blind trial of long-acting release octreotide for treatment of Graves' ophthalmopathy. *J Clin Endocrinol Metab* 2006; 91: 4817–4824
- 116 Bartalena L, Marcocci C, Pinchera A. Somatostatin analogs for Graves' ophthalmopathy: do they bounce off like a rubber bullet? *J Clin Endocrinol Metab* 2004; 89: 5908–5909
- 117 Tanda ML, Bartalena L. Currently available somatostatin analogs are not good for Graves' orbitopathy. *J Endocrinol Invest* 2006; 29: 389–390
- 118 Cozma I, Zhang L, Uddin J, Lane C, Rees A, Ludgate M. Modulation of expression of somatostatin receptor subtypes in Graves' ophthalmopathy orbits: Relevance to novel analogs. *Am J Physiol Endocrinol Metab* 2007; 293: E1630–E1635
- 119 Prummel MF, Mourits MP, Berghout A, Krenning EP, van der Gaag R, Koornneef L, Wiersinga WM. Prednisone and cyclosporine in the treatment of severe Graves' ophthalmopathy. *N Engl J Med* 1989; 321: 1353–1359
- 120 Bartalena L, Pinchera A, Marcocci C. Management of Graves' ophthalmopathy: reality and perspectives. *Endocr Rev* 2000; 21: 168–199
- 121 Wakelkamp IM, Baldeschi L, Saeed P, Mourits MP, Prummel MF, Wiersinga WM. Surgical or medical decompression as a first-line treatment of optic neuropathy in Graves' ophthalmopathy? A randomized controlled trial. *Clin Endocrinol* 2005; 63: 323–328
- 122 Currò N, Covelli D, Vannucchi G, Campi I, Pirola G, Simonetta S, Dazzi D, Guastella C, Pignataro L, Beck-Peccoz P, Ratiglia R, Salvi M. Therapeutic outcomes of high-dose intravenous steroids in the treatment of dysthyroid optic neuropathy. *Thyroid* 2014; 24: 897–905
- 123 Al-Bakri M, Rasmussen AK 2, Thomsen C 3, Toft PB. Orbital Volumetry in Graves' Orbitopathy: Muscle and Fat Involvement in relation to Dysthyroid Optic Neuropathy. *ISRN Ophthalmol* 2014; 435276
- 124 McKeag D, Lane C, Lazarus JH, Baldeschi L, Boboridis K, Dickinson AJ, Hullo AI, Kahaly G, Krassas G, Marcocci C, Marinò M, Mourits MP, Nardi M, Neoh C, Orgiazzi J, Perros P, Pinchera A, Pitz S, Prummel MF, Sartini MS, Wiersinga WM. European Group on Graves' Orbitopathy (EUGOGO) Clinical features of dysthyroid optic neuropathy: a European Group on Graves' Orbitopathy (EUGOGO) survey. *Br J Ophthalmol* 2007; 91: 455–458