

An Algorithm for the Initial Management of Nasal Trauma

John F. Hoffmann, MD, FACS¹

¹Department of Otolaryngology, University of Washington, Spokane, Washington

Address for correspondence John F. Hoffmann, MD, FACS, 217 W. Cataldo, Spokane, Washington 99201
(e-mail: jhoffmann@spokaneent.com).

Facial Plast Surg 2015;31:183–193.

Abstract

Nasal fractures are the most common of all facial skeletal injuries. Untreated, these fractures frequently lead to functional and aesthetic problems. Careful history and physical assessment are critical to determine the extent of injury and to determine proper management. Critical aspects of assessment are discussed, as is the role of imaging in management. The unique aspects of pediatric nasal fractures and their management are reviewed. Fractures are classified based on the degree of injury and the involvement of the septum. A simple treatment algorithm is provided to help guide the selection of optimal treatment techniques. A review of instrumentation and treatment techniques is provided. The goal of treatment is to restore the nose to its preinjury shape and function and to minimize the need for secondary septorhinoplasty.

Keywords

- ▶ nasal fractures
- ▶ septal trauma
- ▶ closed reduction

Nasal fractures represent some of the most prevalent clinical problems seen in a facial plastic surgery or otolaryngology practice. Fractures of the nose are the most frequent of all facial fractures and are reported to be the third most common fracture of the human skeleton.¹ Nasal trauma may lead to obvious or subtle changes in the nasal appearance and can lead to functional nasal airway obstruction as well. Almost 40% of all facial fractures involve the nasal bones.² These fractures run the gamut from simple, unilateral displaced fractures to severely comminuted bony trauma with associated septal deviation, dislocation, or fracture. It has been reported that up to 90% of all nasal fractures may also have some degree of septal injury.³

The overall goal of treatment is to restore the nose to its premorbid shape and function and to minimize the need for subsequent surgery. Management of nasal fractures has remained controversial and challenging through the centuries. Even Hippocrates expressed his frustration with the treatment of nasal fractures more than 2,000 years ago.¹ In response to this challenge, several surgeons have advocated various treatment strategies and treatment algorithms to guide clinicians through the evaluation and treatment of a variety of nasal fractures from simple to complex. This article details the assessment of nasal trauma and provides a simple treatment algorithm based on clinical evaluation and other published guidelines for the management of the most commonly seen types of nasal fractures.

Evaluation

Unlike many facial fractures that rely on sophisticated radiographic imaging for accurate diagnosis, isolated nasal fractures are principally diagnosed through history and especially through careful clinical examination. The history will provide clues as to the severity and location of the fractures. A lateral blow to the nose, as might occur when one is elbowed in a basketball game or perhaps punched in an altercation, is likely to result in lateral displacement of the nasal pyramid. A low-energy lateral strike might result in isolated unilateral or bilateral fractures with mild displacement of the dorsum (▶ **Fig. 1**). A higher-energy blow might result in comminuted bilateral fractures such that the side that was struck is medialized—or depressed—while the contralateral bone is lateralized and made more prominent (▶ **Fig. 2**). The end result is significant movement of the nasal dorsum off the midline. In these instances, displacement of the nasal dorsum is highly suggestive of significant nasal septal dislocation and fracture.⁴ Many of these patients will typically complain of significant nasal airway obstruction as well. This is another important clinical clue that suggests significant septal injury.

In contrast, a frontal blow in a fall will commonly fracture the anterior aspect of the nasal bones, nasal tip, and septum (▶ **Fig. 3**). This may result in frontal depression of the nasal bones without lateral deviation. A more intense frontal blow may lead to impaction of the nasal bones with loss of some

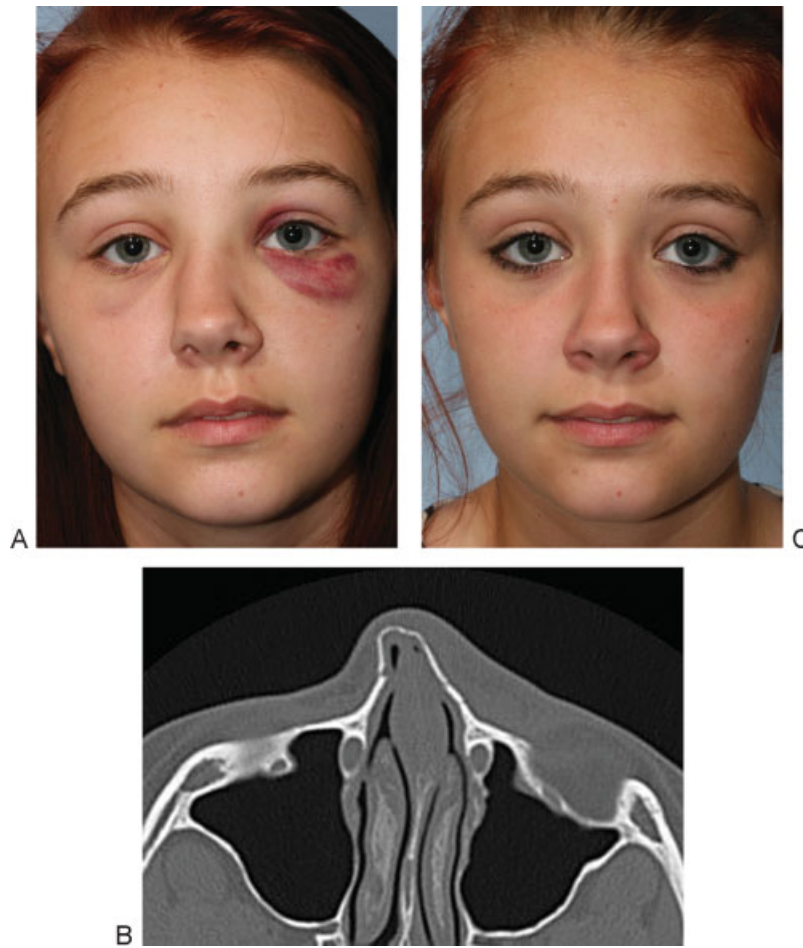

Fig. 1 (A) A 15-year-old girl who sustained trauma while playing basketball. Nasal pyramid displaced to the right but patent nasal airway. (B) CT scan demonstrating displaced but minimal comminution and well-aligned septum. (C) Post closed reduction only.

nasal height and splaying of the nasal bones laterally. Anterior trauma also frequently will cause fracture of the caudal septum and perhaps the anterior nasal spine (► **Fig. 4**).

It is important to inquire whether the patient has undergone septorhinoplasty surgery prior to the trauma. As septorhinoplasty may weaken nasal structures, this may lead to greater instability and posttrauma deformities and airway compromise.² These patients are much more likely to need secondary reconstruction after the initial management of their fracture and they should be counseled accordingly.

Plain radiographic imaging offers little clinical benefit in isolated nasal trauma. In fact, sometimes plain film X-rays can be confusing as they may suggest there is no fracture even when the nose is obviously displaced (► **Fig. 5**). Conversely, plain X-rays may be read as significant fractures even when there is no significant change in the nasal appearance or airway. Plain films also are unable to distinguish between acute and old fractures. Even though there is little clinical utility with plain radiographs, there may be a need for objective documentation of nasal fractures for legal purposes especially in cases of assault or liability claims.⁵ However, the author never obtains plain films in cases of isolated nasal

trauma for clinical purposes alone. Surprisingly, more often than not, new patients referred with isolated nasal fractures still present after they have had plain films taken elsewhere. The indications for surgical intervention following nasal trauma are *solely* based on changes in the appearance or function of the nose after injury, and plain film imaging will rarely impact these decisions and may in fact be confusing.

The only time that imaging is definitely indicated following nasal trauma is when one suspects the presence of associated facial injuries. A few clinical questions will quickly identify most of those patients that may have additional facial fractures. Is there any facial numbness? If yes, that could suggest the presence of maxillary or orbital injury involving the infraorbital nerve. Is there any double vision or change in vision? If so, this would suggest orbital trauma. Has there been any change in dental occlusion? If yes, then there may be associated fractures of the maxilla or mandible. Is there significant rhinorrhea? This might suggest a skull base or frontal sinus injury with cerebrospinal fluid (CSF) leakage. A positive response to any of these inquiries would dictate the need for a high-resolution computed tomographic (CT) scan of the face bones with axial, coronal, and sagittal views (► **Fig. 6**).

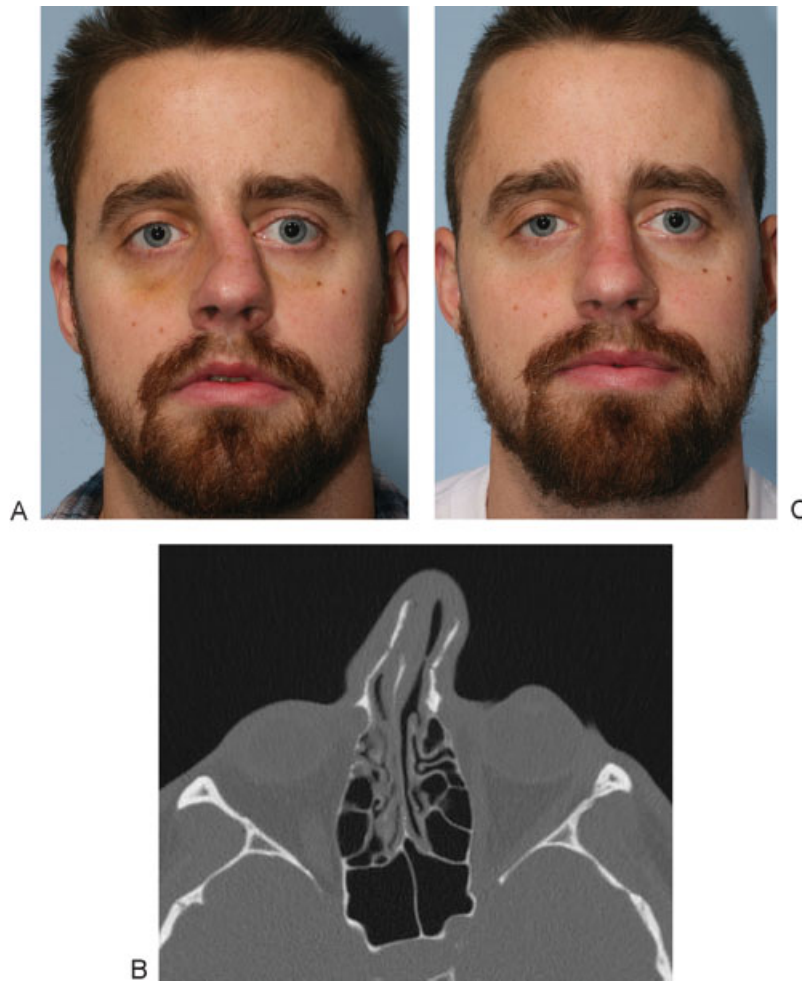


Fig. 2 (A) A 24-year-old man involved in altercation. Significant displacement of the dorsum to the left with associated septal dislocation and nasal airway restriction. (B) CT scan demonstrating significant comminution and septal displacement. (C) Post-op following closed reduction of nasal bone and septal fractures.

Physical Examination

The goal of the physical examination in patients with nasal trauma is to assess the extent and severity of the injury so that one can determine the most appropriate management and counsel the patient accordingly. Nasal trauma commonly results in perinasal edema, ecchymosis, and deformity. The physical examination includes gentle palpation of the dorsum and tip. One should assess the degree of displacement of the bony pyramid and the extent of depression or lateralization of the nasal bones. Palpation of the nasal tip should assess potential loss of caudal septal support. A saddle deformity may indicate significant dislocation or fracture of the septal cartilage (► **Fig. 7**). One should also gently palpate the nasal bone and upper lateral cartilage junction. On occasion, trauma may result in separation of these structures, resulting in depression and collapse of the middle vault even when the bony pyramid is not displaced (► **Fig. 8**). As it is difficult to reduce such an injury acutely, many of these patients may benefit from secondary reconstruction with cartilage only grafting or other techniques done on an elective basis.

Careful anterior rhinoscopy—and endoscopy as needed—should be performed to assess the septum and intranasal structures. One should carefully look for the presence of a septal hematoma. A septal hematoma must be drained and managed as quickly as possible to avoid the development of a septal abscess, which could lead to significant septal cartilage loss and subsequent nasal collapse. One should assess the alignment of the septum and the degree of septal dislocation and fracture. Significant septal deviation has been shown in multiple studies to be a critical predictor of failure of closed nasal fracture reduction and the need for revision surgery after closed reduction.^{6–8} The intranasal examination should assess soft tissue damage to the septal mucosa and look for evidence of watery rhinorrhea, which may suggest a CSF leak. The rest of the facial skeleton should be carefully palpated to identify any associated fractures. An examination of the eyes should at a minimum assess visual acuity, pupillary symmetry, and responses as well as globe position and extraocular movement. Additional imaging or consultation is obtained as indicated by a high suspicion of associated injuries.

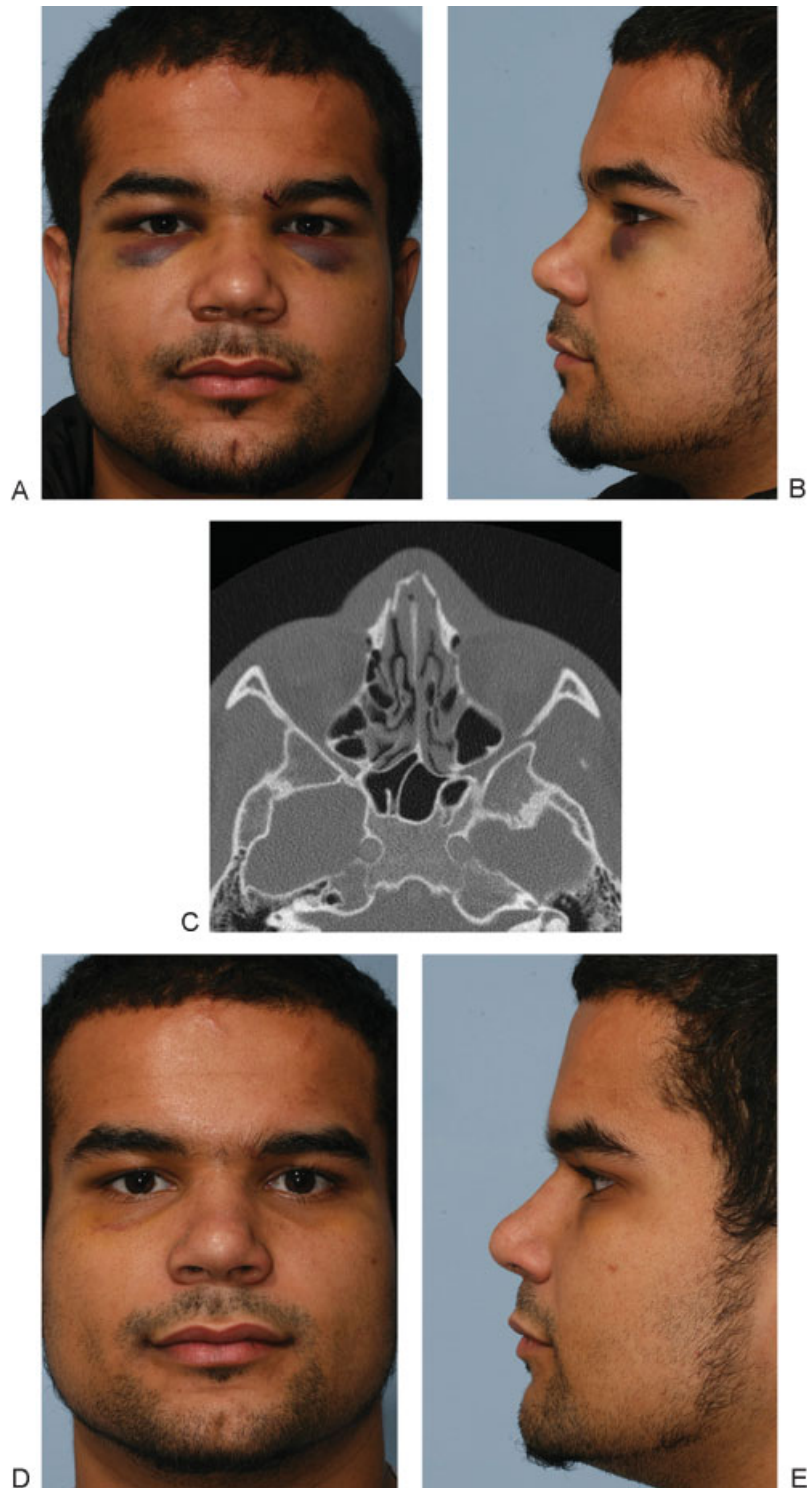


Fig. 3 (A, B) A 19-year-old man involved in altercation with predominately frontal trauma with impaction of nasal bones with some loss of dorsal height and airway obstruction. (C) CT scan showing severe comminution and impaction of nasal bones. (D, E) Post-op following disimpaction and limited septal reconstruction with restoration of dorsal height and improvement of airway.

Pediatric Nasal Trauma

Overall the pediatric nose is relatively protected from fractures. This is partly because the nasal dorsum projects less than the adult nose and thus is given protection by the more prominent forehead and supraorbital rim. Furthermore, the pediatric nasal skeleton is more cartilaginous and hence more

flexible and less prone to comminution. The pediatric nasal septum is vulnerable to dislocation or distortion, however, and septal hematomas are proportionately more common in children than in adults.⁹ Thus, the clinician must be on the lookout for septal hematomas in all cases of pediatric nasal and facial trauma. When present, hematomas must be drained urgently to avoid the possibility of septal abscess,

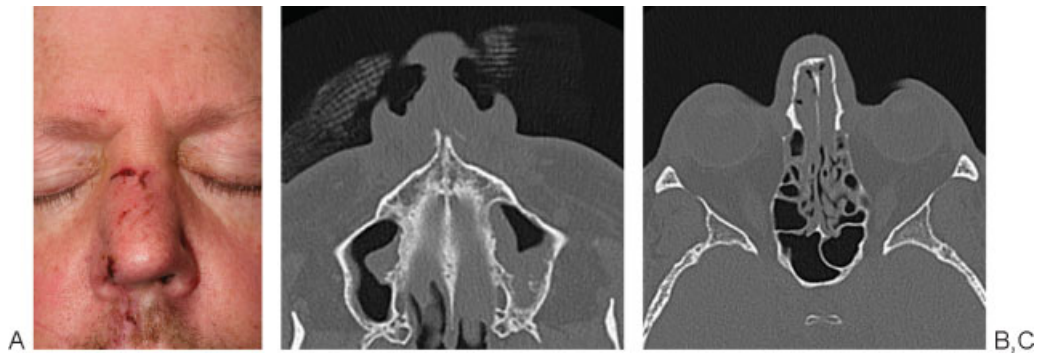


Fig. 4 (A) 53-year-old man who sustained frontal trauma in a fall off a ladder with widening of the dorsum and airway restriction. (B) CT scan showing fracture of anterior nasal spine. (C) CT scan demonstrating severe comminution, impaction and lateral splaying of nasal bones.

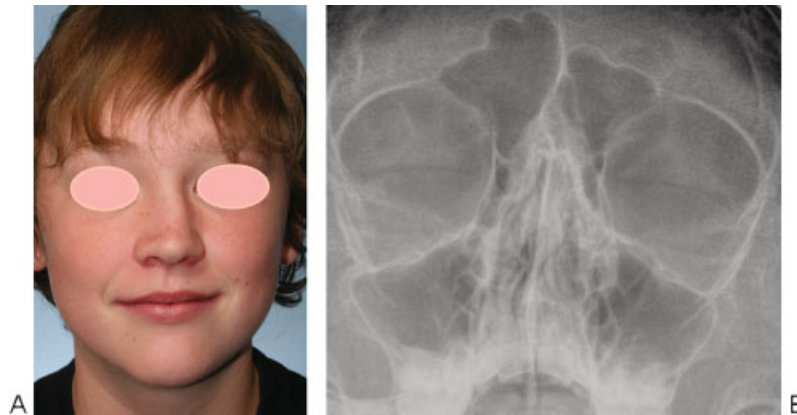


Fig. 5 (A) A 13-year-old man who sustained sports-related nasal trauma with obvious displacement of nasal bridge to the left. (B) Plain film radiograph read as “no fractures.”

which could lead to substantial septal cartilage loss. As soon as feasible, the hematoma should be evacuated through a limited mucoperichondrial incision. The dead space is then obliterated by placing through and through gut sutures as this might eliminate the need for placement of packing. Antibiotics are typically administered as well.

It is well recognized that prior to adolescence, the nasal septum plays a crucial role as a growth center for the nose and midface.⁶ To minimize the impact of trauma on eventual nasofacial development, it is prudent to be conservative in the treatment of nasal fractures in the pediatric population.¹⁰

Thus, the mainstay of treatment is closed reduction of bony fractures and closed reduction of septal dislocation. Open treatment of bony injuries with osteotomies or open septal reconstruction, although advocated by some authors, is rarely indicated except in those cases of severe trauma, which typically would also involve the orbit or midface.¹¹ As children tend to heal rapidly, closed reduction should ideally be performed within a week of the injury or else adequate reduction may become difficult. It is prudent to advise the parents that trauma at an early age, in spite of timely treatment, may result in nasal airway or appearance problems later in life.

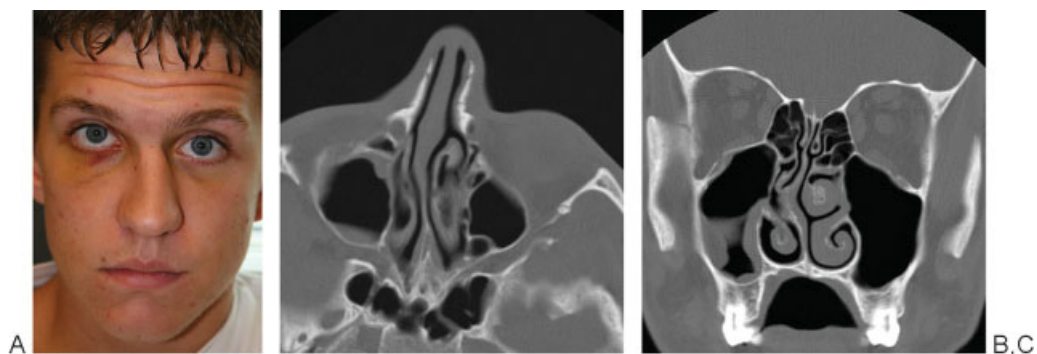


Fig. 6 (A) A 17-year-old man who sustained nasofacial trauma in an altercation. Obvious nasal displacement and diplopia with up gaze. (B, C) CT scan demonstrating displaced nasal fractures as well as mildly displaced right orbital floor fractures.

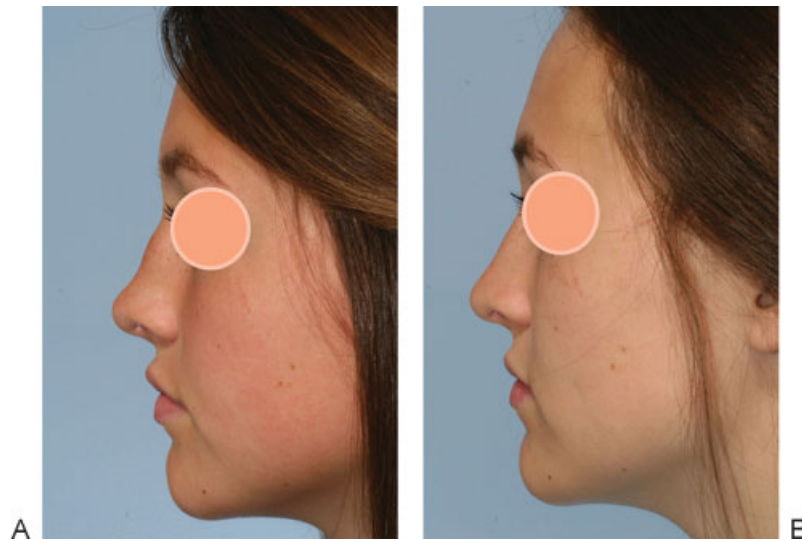

Fig. 7 (A) A 18-year-old girl who sustained sports-related nasal septal trauma 3 years before with cartilaginous saddle deformity. (B) Post-op following septoplasty alone.

Classification of Nasal Fractures and Management Algorithm

Not all nasal fractures require treatment. If the fractured nasal bones remain well aligned and the nasal airway is not significantly changed, observation alone is adequate. If the patient is seen shortly after the injury and the edema is still significant, they should be advised that any external deformity may only become apparent once the edema improves. In these cases, the patient should be reevaluated as soon as the

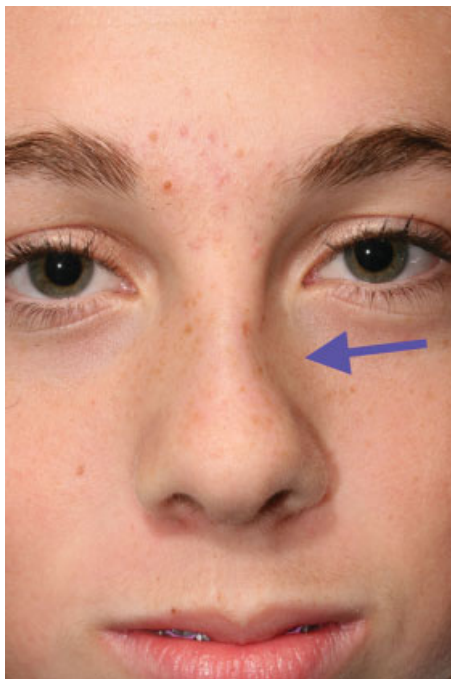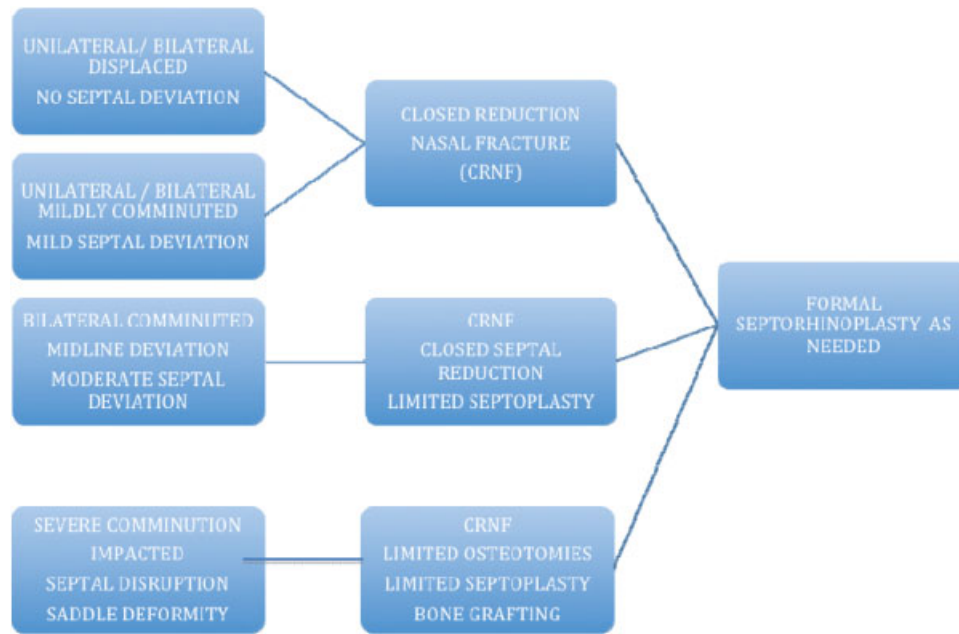


Fig. 8 A 19-year-old woman sustained left-sided nasal trauma several years before. She exhibits hollowing of the left middle vault from upper lateral cartilage separation without nasal bone displacement.

swelling has receded but soon enough to reduce the fractures prior to consolidation of the fracture site.

Several different classification schemes for nasal fractures have been proposed through the years. Typically these have attempted to categorize the trauma based on the degree of injury to the nasal bones and septum. The intent is to then guide management based on the severity of injury. Rohrich and Adams⁷ in 2000 proposed a classification scheme and treatment algorithm in an effort to reduce subsequent revision rates. They proposed initial closed reduction of nasal and septal fractures with advancing to limited septal reconstruction as needed. Staffel¹² also proposed a graduated approach as well progressing from simple closed reduction to septal reconstruction, osteotomies, and grafting as indicated. More recently, Ondik et al⁸ devised a new classification scheme dividing nasal trauma into five groups. Class I fractures were simple mildly displaced fractures progressing in severity up to class V fractures that were complex injuries with severe, comminuted fractures of the nose and septum including significant soft tissue injury. They then proposed a comprehensive treatment algorithm designed to recommend treatment based on the fracture classification. This was all done in an effort to improve treatment outcome and to reduce the need for secondary surgery, and in their study the overall need for revision surgery was an admirable 6%. Riley and Davison² also reviewed their experience in closed and open treatment of nasoseptal fractures. They concluded that those injuries that needed septal reconstruction also greatly benefitted from open treatment of the nasal bone component as closed treatment alone in these cases led to high rates of revision.

In this article, a somewhat simplified classification scheme similar to Ondik et al⁸ is presented as well as a basic treatment algorithm (► **Table 1**). The first group includes those who have displaced but noncomminuted fractures with minimal septal deviation and only minor displacement of the midline (► **Fig. 1**). The second would include those with more

Table 1 Treatment algorithm

comminution and mild, but nonobstructive septal deviation and moderate dorsal displacement greater than $\frac{1}{2}$ the width of the dorsum (\rightarrow Fig. 2). Both groups can typically be managed with simple closed reduction of the nasal bones with external splint stabilization.

A third group would include those with bony comminution and obstructive septal deviation or dislocation along with significant displacement of the midline dorsum (\rightarrow Fig. 9). In addition to closed reduction of the nasal bones, these patients will also need either closed septal reduction or perhaps limited septoplasty and perhaps limited osteotomies of the nasal bones. Included in this group would be those with comminuted and depressed fractures with associated septal fractures and loss of dorsal support (\rightarrow Figs. 3 and 9). In most of these cases, intranasal septal splints can be helpful to provide additional support to the weakened septal cartilage and protection of the septal mucosa. Intranasal septal splints may also reduce the incidence of synechia between the septum and the mucosa of the turbinates and nasal sidewall, which is commonly lacerated in this group. Adequate repair of the septum is often cited as the key to a successful outcome and for reduction in the need for secondary surgery. That said, it remains prudent to only use the minimal intervention necessary to allow adequate septal reduction.

The final group includes those with severe comminution and impaction of the nasal bones as well as collapse of the septal support and damage to or loss of external soft tissues (\rightarrow Fig. 10). Naso-orbital-ethmoid fractures would fall into this category. These cases may require open reduction and internal fixation of the nasal bones with limited osteotomies, septal reconstruction, soft tissue repair, and perhaps bone or cartilage grafting to restore dorsal support and contour.

Any of these groups may ultimately need secondary formal septorhinoplasty at some point in the future. This may be indicated for persistent nasal airway restriction or external deformity. Typically this is performed after 3 to 6 months of healing, which allows for stabilization of the nasal bones and septum as well as time for the external edema to resolve. This allows for more accurate secondary septorhinoplasty at a convenient time. A discussion of secondary surgery for traumatic nasal deformity is beyond the purview of this chapter.

Techniques

The timing of nasal fracture repair is dependent on the degree of injury and amount of soft tissue edema. Commonly, fracture reduction is done within 1 to 2 weeks following the injury. Pediatric patients should be managed within 7 to 10 days given their tendency to heal more rapidly. Ideally, one should allow enough time for a substantial amount of the swelling to resolve but not so much time that the bones have become stable and difficult to disimpact and reduce. If the reduction is done while there is still significant edema, the reduction of the nasal bones may be inaccurate as the bony contours and position are hidden under the thickened soft tissues. Additionally, if an external stabilizing splint or cast is applied too early, it will prematurely become loose and ineffective as the edema resolves. Thus one should attempt to schedule the reduction during the 1 to 2 weeks window of time for maximum accuracy and stability. In cases where there is severe comminution, closed reduction may still be successful up to 3 weeks after the initial trauma as these bony fragments tend to remain mobile longer. Beyond 2 weeks, however, the surgeon should be prepared to perform open

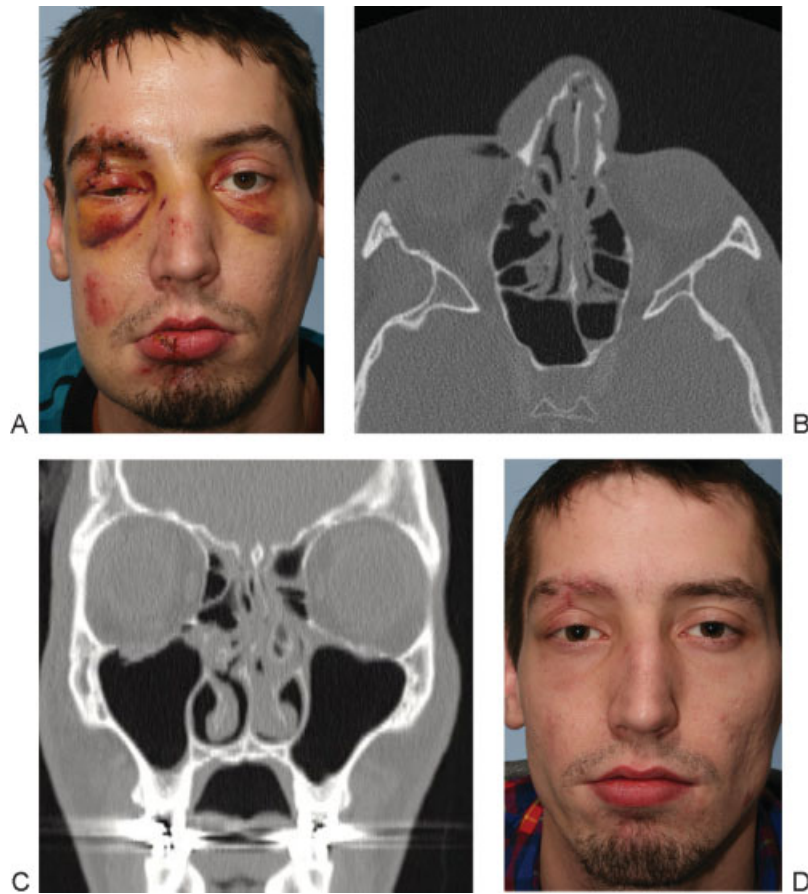

Fig. 9 (A) A 26-year-old man who sustained substantial facial trauma in an autopedestrian incident. No vision changes. (B, C) CT scan demonstrating severe impaction and comminution of the nasal bones and septum. Minimally displaced right orbital fracture without entrapment. (D) Post-op following septal reconstruction and limited osteotomies needed to mobilize and reduce fractures.

techniques on the septum and nasal bones, and the patient should be prepared for that eventuality.

Simple closed reduction is typically performed as an outpatient procedure. It is the author's preference to perform this in an ambulatory surgical center under brief general anesthesia. Although this can be done under local and topical anesthesia,¹³ it has been our routine to perform these quickly and in a very humane fashion under a brief general anesthesia. Not only does this approach result in little postoperative pain, but it is believed that more complete and accurate reduction can be performed effectively without any limitation or restriction caused by patient discomfort during the procedure. When performed in an efficient ambulatory surgery center, it is also very cost-effective and well received by the patient. A further advantage of general anesthesia is that it is easy to perform more invasive maneuvers such as osteotomies or septoplasty in the same setting if that proves necessary. Osteotomies or more invasive septal procedures may prove difficult under local or topical anesthesia alone.

After the induction of general anesthesia, a topical intranasal anesthetic—typically a 1:1 mixture of 4% topical lidocaine and oxymetazoline—is applied intranasally to provide mucosal decongestion, diminished risk of bleeding and postoperative comfort. If more extensive intervention is anticipated, such as osteotomies or septal repair, then regional

infiltration with a 1:1 mixture of 1% lidocaine and 0.25% bupivacaine with epinephrine is also done. Perioperative antibiotics are used at the surgeon's discretion. Antibiotics are indicated in all cases of septal hematoma, however. Intranasal packing is avoided except when needed to manage epistaxis. Most patients will require only minimal postoperative analgesics.

We have assembled a limited instrument set specifically for closed fracture reduction (→Fig. 11). This includes a nasal speculum, bayonet forceps, suction tips, Asch forceps, Walsham forceps, and a Boies elevator. Cottonoids are used for the application of topical anesthetic and to tamponade the occasional bleeding. These are often placed into the posterior nasal airway at the start of the procedure to provide a temporary barrier in order to minimize the migration of any blood down into the pharynx. Cottonoids are also useful to provide some cushioning between the elevator and the delicate mucosa under the nasal bones (→Fig. 12). This simple addition protects the mucosa and limits bleeding while the bones are manipulated back into place.

A typical closed reduction is begun by elevating the bone on the side that is depressed with a Boies elevator using a bimanual technique to stabilize the bones and to feel when they are accurately reduced (→Fig. 13). Occasionally, a Walsham forceps may be helpful to disimpact and elevate

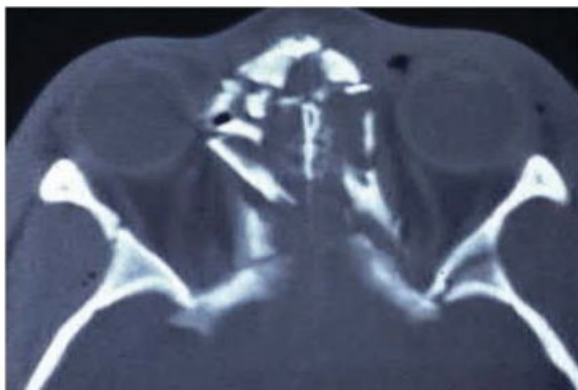
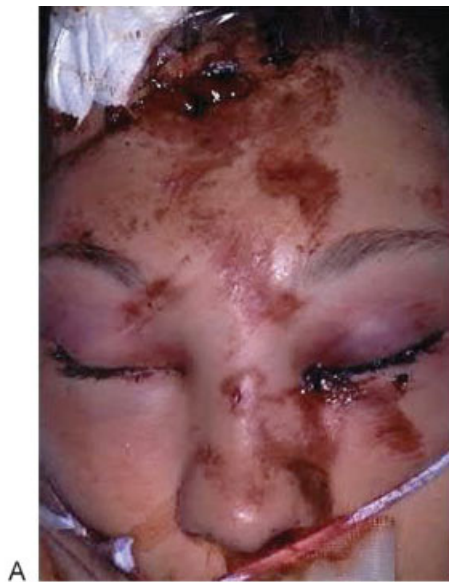

Fig. 10 (A, B) A 25-year-old woman involved in motor vehicle accident with severe naso-orbital-ethmoid fractures.

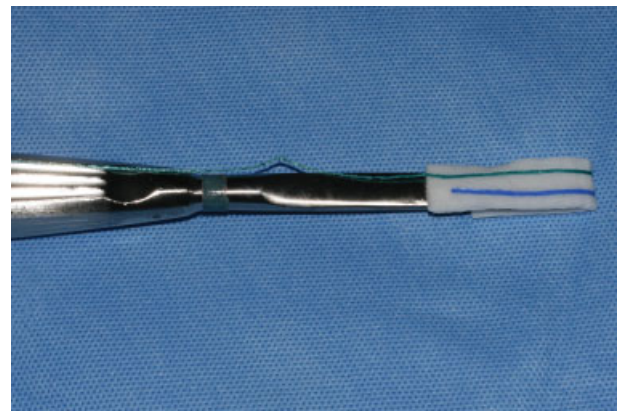


Fig. 12 Boies elevator cushioned with cottonoid to minimize trauma to nasal mucosa during bony manipulation.

depressed nasal bones (►Fig. 14). If the bony dorsum is impacted, an Ashe or similar forceps are used to disimpact the bones (►Fig. 15). The Ashe may also be helpful in reducing a dislocated septum back toward the midline over the maxillary crest. After adequate mobilization, the dorsum is then manipulated back into alignment with external digital pressure. Frequently an audible and palpable “pop” will occur during this process and may signify that the bones are disimpacted and the bony spicules of the fracture sites have become interdigitated.

If there is significant septal deviation from cartilage fracture or dislocation off the maxillary crest, septal realignment is indicated. In general, this author has tried to limit extensive septal reconstruction at the time of initial fracture repair because of concerns regarding unpredictable healing, increased risk of septal perforation when the mucosa is already traumatized and increased difficulty and risks when

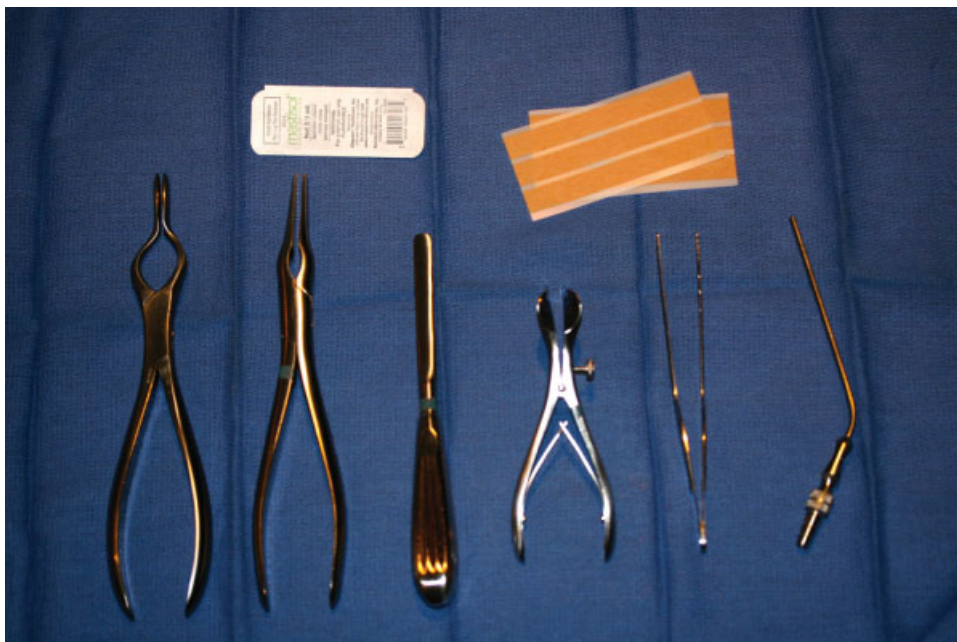

Fig. 11 Instrument set for acute nasal fracture management. From left: Walsham forceps, Ashe forceps, Boies elevator, nasal speculum, Bayonet forceps, Frasier suction. Also skin adhesive and elastic adhesive strips for casting.

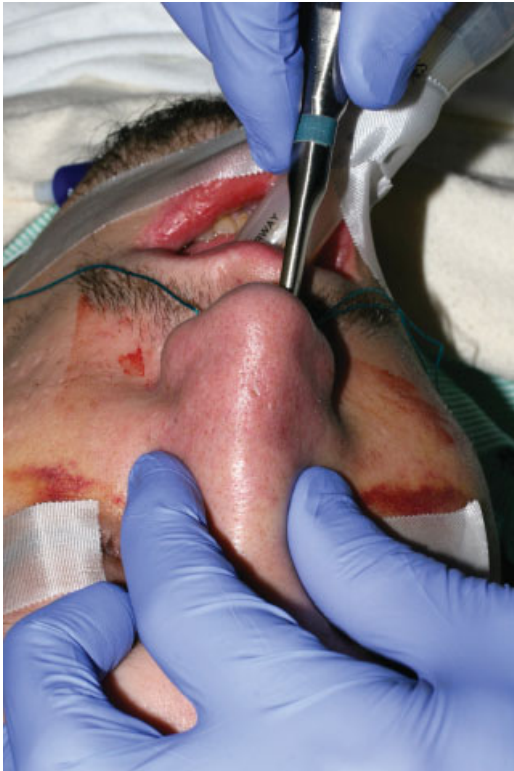

Fig. 13 Bimanual technique using Boies elevator to manipulate nasal bones into position.

secondary septoplasty is needed. Nonetheless, closed septal relocation and limited septal dissection are used as needed. The exposure along the maxillary crest and bony cartilaginous junction is done keeping mucoperiosteal dissection to a minimum. As a rule, the surgeon should strive to preserve as much septal cartilage as possible as there is a significant possibility that the patient may need definitive reconstructive rhinoplasty in the future and the septum is a critical source of graft material. In most instances, extensive septal reconstruction probably should be delayed for a few months when a formal septorhinoplasty procedure can be done in a setting where the cartilage is stable and the external edema is minimal.

On occasion, limited osteotomies may be needed to reduce and acute fracture. Typically this is in cases of displaced but impacted fractures or perhaps those fractures, which are displaced but incomplete. In general, osteotomies should be as limited as possible and only enough to allow mobilization of the displaced bones. Nasal trauma typically disrupts the periosteum of the nasal bones. Thus, one should limit soft tissue and periosteal elevation over the dorsum in the acute trauma situation as this may further destabilize the bones during healing. One should rarely perform complete osteotomies as are commonly performed in elective rhinoplasty as this might lead to additional postoperative instability and unpredictable healing. Instead, one should use small, sharp osteotomes and only complete the fracture lines enough to allow mobilization and reduction of the fracture segments. Percutaneous lateral osteotomies may also be a good option, as

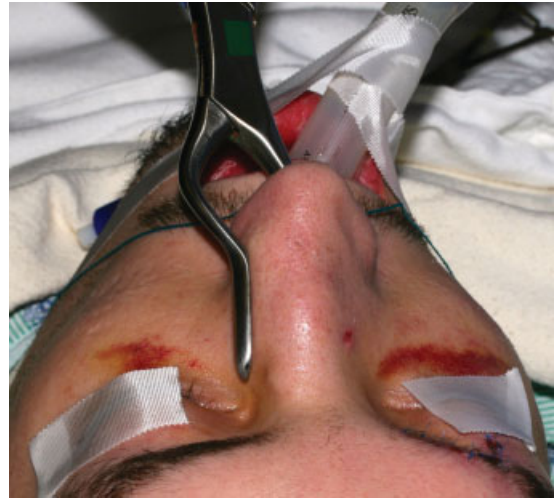

Fig. 14 Walsham forceps used to disimpact and mobilize nasal bones.

these tend to preserve more periosteum and hence provide more postoperative stability.

In general, it is ill advised to incorporate other esthetic rhinoplasty maneuvers, such as tip modification, at the time of acute fracture repair given the potentially unpredictable healing following trauma.

In the most severe cases of nasal trauma bone or cartilage grafting might be indicated to maintain dorsal stability. This is most often indicated in those cases where there are associated fractures of the naso-orbito-ethmoid or other midface

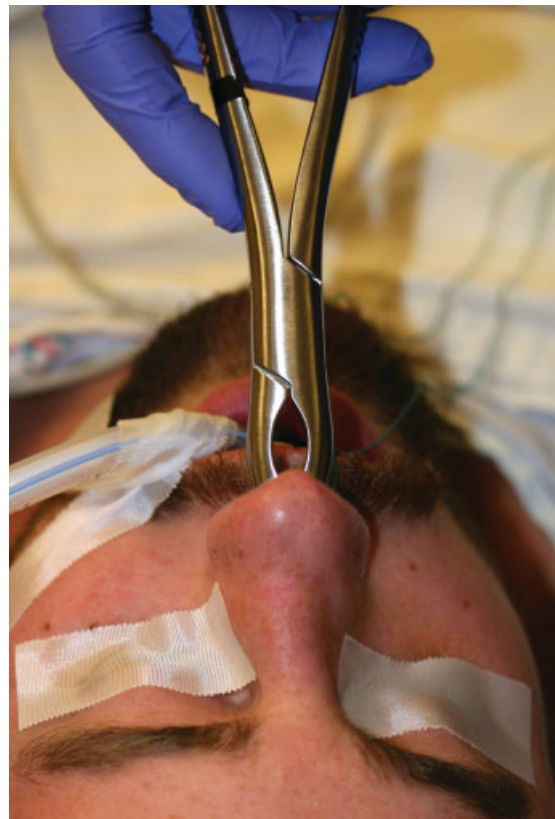


Fig. 15 Asch forceps used to disimpact nasal dorsum and nasal septum.

fractures (► **Fig. 10**). Management of those types of injuries is beyond the scope of this article.

In all cases, an external splint of adhesive strips and perforated thermoplastic material is applied. The application of skin adhesive is usually helpful to secure the splint. If any septal manipulation or repair is done, an internal septal splint is also used. Internal and external splints are typically left in place for up to 1 week. The patient is advised to carefully avoid further trauma for at least 1 month after reduction. If they are involved in athletic activities, a protective face shield is advised. Definitive septorhinoplasty, if needed, is usually delayed at least 3 months to allow for complete bone healing and resolution of edema.

Summary

Nasoseptal trauma is one of the most common injuries in all of facial trauma. Careful history and physical assessment are key to diagnosis and the determination of appropriate treatment techniques. The goal of treatment is to restore the nose to its premorbid shape and function. A graduated approach from simple closed reduction to limited septal repair to osteotomies is presented with the intent of restoring the nose to its premorbid shape and function and to minimize the need for secondary septorhinoplasty.

References

- 1 Gilman GS, Rivera-Serrano CM. Nasal fractures. In: Johnson JT, Rosen CA eds. *Bailey's Head and Neck Surgery—Otolaryngology*. Philadelphia, PA: Wolters Kluwer; 2014:1241–1254
- 2 Reilly MJ, Davison SP. Open vs closed approach to the nasal pyramid for fracture reduction. *Arch Facial Plast Surg* 2007;9(2): 82–86
- 3 Rhee SC, Kim YK, Cha JH, Kang SR, Park HS. Septal fracture in simple nasal bone fracture. *Plast Reconstr Surg* 2004;113(1): 45–52
- 4 Murray JA, Maran AG, Mackenzie IJ, Raab G. Open v closed reduction of the fractured nose. *Arch Otolaryngol* 1984;110(12): 797–802
- 5 Jaberoo MC, Joseph J, Korgaonkar G, Mylvaganam K, Adams B, Keene M. Medico-legal and ethical aspects of nasal fractures secondary to assault: do we owe a duty of care to advise patients to have a facial x-ray? *J Med Ethics* 2013;39(2):125–126
- 6 Higuera S, Lee EI, Cole P, Hollier LH Jr, Stal S. Nasal trauma and the deviated nose. *Plast Reconstr Surg* 2007;120(7, Suppl 2): 64S–75S
- 7 Rohrich RJ, Adams WP Jr. Nasal fracture management: minimizing secondary nasal deformities. *Plast Reconstr Surg* 2000;106(2): 266–273
- 8 Ondik MP, Lipinski L, Dezfoli S, Fedok FG. The treatment of nasal fractures: a changing paradigm. *Arch Facial Plast Surg* 2009;11(5): 296–302
- 9 Alcaraz N, Lawson W. Trauma of the nose and nasoethmoid complex in children and adolescents. *Facial Plast Surg Clin North Am* 1999;7:175–183
- 10 Wright RJ, Murakami CS, Ambro BT. Pediatric nasal injuries and management. *Facial Plast Surg* 2011;27(5):483–490
- 11 Ferreira P, Marques M, Pinho C, Rodrigues J, Reis J, Amarante J. Midfacial fractures in children and adolescents: a review of 492 cases. *Br J Oral Maxillofac Surg* 2004;42(6):501–505
- 12 Staffel JG. Optimizing treatment of nasal fractures. *Laryngoscope* 2002;112(10):1709–1719
- 13 Atighechi S, Baradaranfar MH, Akbari SA. Reduction of nasal bone fractures: a comparative study of general, local, and topical anesthesia techniques. *J Craniofac Surg* 2009;20(2):382–384