

Chronic Bilateral Subdural Hematoma Complicating Decompressive Craniectomy

Sureswar Mohanty¹ Gouri S. Sarangi¹ Pradipta Tripathy¹

¹Department of Neurosurgery, Institute of Medical Sciences and Sum Hospital, Siksha 'O' Anusandhan University, Bhubaneswar, Odisha, India

Address for correspondence Sureswar Mohanty, MCh (Neuro), Department of Neurosurgery, Institute of Medical Sciences and Sum Hospital, Siksha 'O' Anusandhan University, Bhubaneswar, Odisha, India (e-mail: sureswar.mohanty@gmail.com).

Indian J Neurotrauma 2015;12:68–70.

Abstract

Keywords

- ▶ severe head injury
- ▶ brain contusion
- ▶ brain edema
- ▶ chronic subdural hematoma
- ▶ decompressive craniectomy

Problems Considered A case of road side accident developed acute subdural hematoma and cerebral contusion with progressive edema and rise intracranial pressure as revealed on serial computed tomographic scan of the head.

Methods Decompressive craniectomy performed for progressive hemorrhagic contusion producing mass effect.

Results Patient improved unconsciousness and remained stationary because of the development of subdural hematoma further improvement occurred after drainage of subdural hematoma.

Conclusion Development of chronic subdural hematoma is extremely uncommon following decompressive craniectomy and could be responsible for arrest of neurological recovery.

Introduction

Decompressive craniectomy is often indicated in cases of severe head injury with acute subdural hematoma and cerebral edema leading to increased intracranial pressure. Chronic subdural hematoma following such decompressive procedure is extremely uncommon and may be responsible for persistent-raised pressure and arrest of neurologic recovery.

Case History

A 32-year-old male patient (IP-130311629), met with road traffic accident and was brought unconscious (GSC 8) on February 5, 2013, and did not show any significant contusion, edema or mass effect (▶**Fig. 1**).

As the patient showed clinical deterioration computed tomographic (CT) scan was done on February 7, 2013. It showed extensive primary contusion and brain edema of right frontal temporal lobe with mass effect (▶**Fig. 2**). Cranial decompression performed on February 8, 2013, in

which right frontotemporal large bone flap was raised. Dura was left open and bone flap was preserved in the abdominal wall. Neurologically, patient continued in GCS 7 tracheostomy was done. CT scan done on February 9, 2013, (postoperative) (▶**Fig. 3**) revealed brain herniation in the cranial defect with recovery of midline shift. Patient clinically had left hemiparesis and normal vital signs. Edema showed some resolution. Patient's recovery remained stationary.

CT scan on February 13, 2013, shows brain herniation with ipsilateral dilatation and migration of lateral ventricle toward herniation. Neurological status was stationary for nearly 1 month.

CT scan on March 12, 2014, (▶**Fig. 4**) showed interhemispheric and bilateral subdural collection. On March 14, 2013, subdural fluid drained by left frontal, left parietal, and right parietal burr hole. The subdural fluid was under pressure. The bulging brain herniation regressed back. After 1 week, recurrence of swelling occurred and CT revealed subdural recollection on both side and also interhemispheric. Then, left subduroperitoneal shunt done

received

November 10, 2014

accepted after revision

May 29, 2015

published online

June 17, 2015

© 2015 Neurotrauma Society of India

DOI <http://dx.doi.org/>

10.1055/s-0035-1556045.

ISSN 0973-0508.

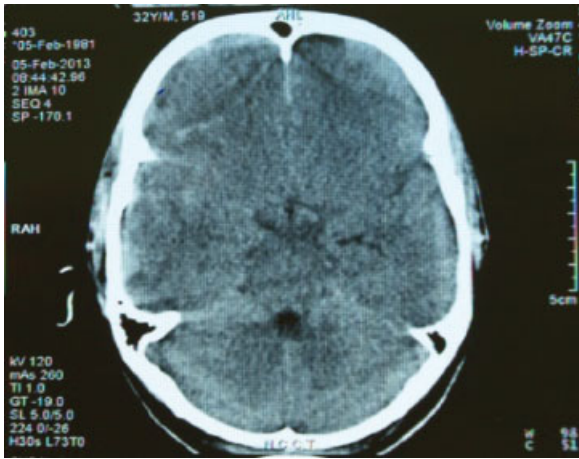


Fig. 1 Mild acute subdural with surface contusion at right cerebral hemisphere.

(►**Fig. 5**). Cranioplasty was done with preserved bone flap. Subdural hematoma disappeared. Herniated brain returned back on last CT. Tracheostomy was closed. Patient improved neurologically and discharged walking with a mild left hemiparesis. Follow-up revealed personality changes and suicidal tendencies.

Discussion

Severe brain injury could reveal dynamic pathology, that is, progressive contusion, edema, mass effect which is correlated with repeat CT scan as in this case.¹ One of the standard palliative surgery is to provide bony decompression (decompressive craniectomy) to permit expansion of brain volume and prevent herniation.² Under such circumstances when intracranial pressure (ICP) is raised, development of chronic subdural hematoma is a rare possibility. When such lesion occurs, neurologic recovery could be arrested as in this case. Drainage of subdural fluid leads to rapid recovery of neurologic status. Surgical treatment consists of drainage of subdural hematoma by drill hole, burr hole, craniectomy and

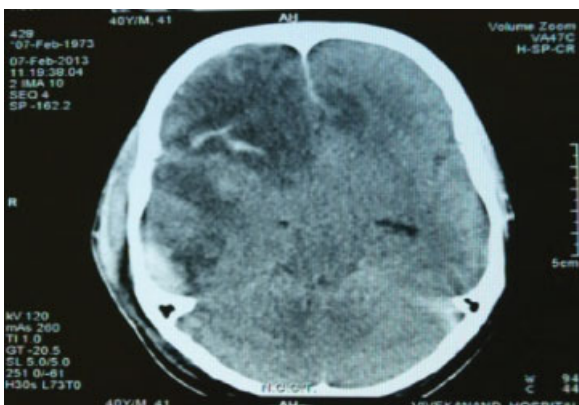


Fig. 2 Increased subdural hematoma with increased contusion edema with mass effect.

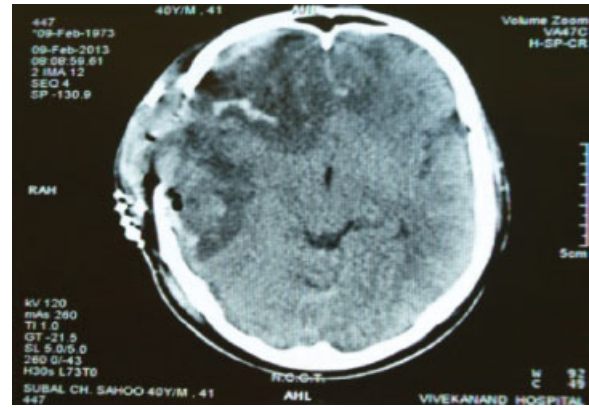


Fig. 3 Postdecompressive craniectomy.

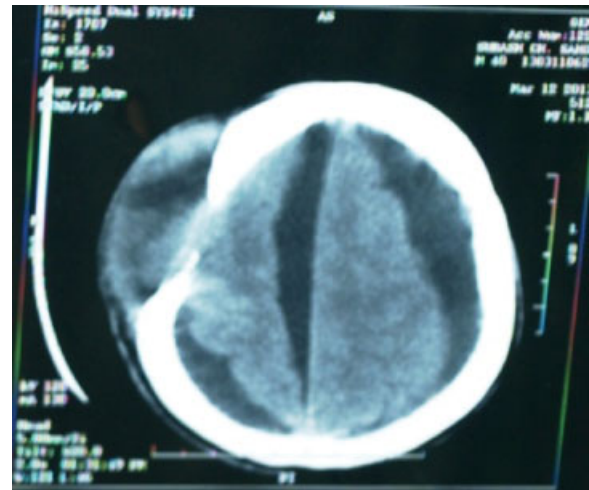


Fig. 4 Bilateral and interhemispheric subdural with brain herniation at the craniectomy site.

membranectomy, and shunt procedures. Decompressive craniectomy indication has been brain swelling because of edema or extensive contusion to provide space for expanding intracranial volume. However, chronic subdural

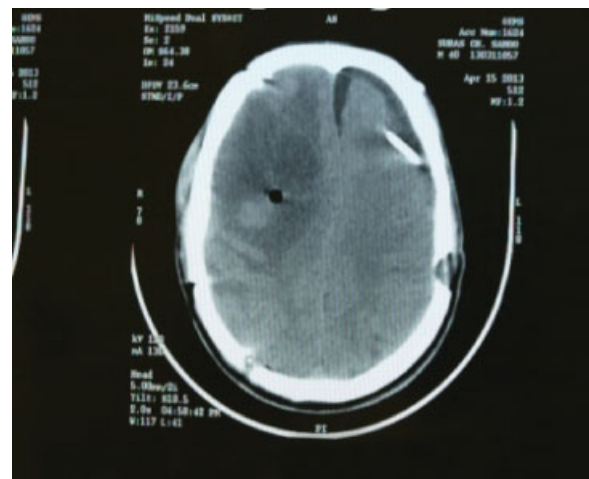

Fig. 5 Postoperative subduroperitoneal shunt and cranioplasty with total resolution of hematoma.

This document was downloaded for personal use only. Unauthorized distribution is strictly prohibited.

hematoma (SDH) as a complication of decompressive craniectomy with duraplasty is extremely rare after craniectomy and duraplasty being done, permitting temporary seepage of subdural fluid through dura and craniectomy into the subgaleal space, where it is absorbed. Only when the subdural hematoma is recurrent or not resolving and the fluid is noninfected and contains low protein, subduro-peritoneal shunt has been effective in continuous drainage and cure.

Initially burr hole drainage was undertaken. However, the recurrence occurred and the patient neurologic states did not show any improvement. Craniectomy flap was bulging. Following subduroperitoneal shunt, craniectomy flap settled down and cranioplasty performed. Patient showed slow but steady improvement. Thus, cranioplasty, which could not be done earlier because of the brain herniation at the cranioplasty site, was done after subdural peritoneal shunt, when the intracranial pressure subsided.

Medical and surgical treatments for chronic subdural hematoma are available. Medical treatment consists of osmolar diuretic, that is, mannitol and hypertonic saline. However, the results are not predictable.

To provide space within cranial cavity, severe head injury with raised ICP, bony decompression has been a recognized procedure.³ Ipsilateral or contralateral subdural hematoma is seen rarely in postoperative period. However, the development of a bilateral chronic subdural hematoma appearing after 5 weeks of trauma and 4 weeks of decompression, when ICP is elevated, is extremely uncommon. Thus, decompression may not be quite effective if complications such as subdural hematoma occurs.⁴

Chronic SDH is not reported after decompressive cranioplasty when intracranial pressure is raised with brain herniating through the cranioplasty site as in this case. A few cases of acute SDH may in due course become chronic SDH in head injury cases, which is likely in this case. Thus, in a case of acute head injury with brain contusion and edema, when decompressive cranioplasty has been performed, if the progressive improvement of neurologic status is arrested often a period of time, complication such as chronic subdural hematoma may be a possibility requiring treatment.

Acknowledgment

The authors thank Dr. P. K. Mohanty, MS, Institute of Medical Sciences and Sum Hospital, Bhubaneswar, for his cooperation.

References

- 1 Kurland D, Hong C, Aarabi B, Gerzanich V, Simard JM. Hemorrhagic progression of a contusion after traumatic brain injury: a review. *J Neurotrauma* 2012;29(1):19-31
- 2 Kitagawa RS, Bullock MR. Lessons from the DECRA study. *World Neurosurg* 2013;79(1):82-84
- 3 Flint AC, Manleg GT, Gean AD, Hambil JC 3rd, Rosenthal G. Post-operative expansion of hemorrhagic contusions after unilateral decompressive hemicraniectomy in severe traumatic brain injury. *J Neurotrauma* 2008;25(5):503-512
- 4 Walcott BP, Kahle KT, Simard JM. The DECRA trial and decompressive craniectomy in diffuse traumatic brain injury: is decompression really ineffective? *World Neurosurg* 2013;79(1):80-81