Clavicular Autograft for C7–T1 Anterior Spinal Fusions

Enxerto clavicular autólogo para artrodese cervical anterior de C7–T1

Edmundo Luis Rodrigues Pereira[1,2] Daniella Brito Rodrigues[3] Mário de Nazareth Hermes Júnior[4]

[1] Hospital Metropolitano de Urgências e Emergências, Belém, PA, Brazil
[2] Deapartment of Neurology, Universidade Federal do Pará, Belém, PA, Brazil
[3] Universidade do Estado do Pará, Belém, PA, Brazil
[4] Hospital Metropolitano de Urgências e Emergências, Belém, PA, Brazil

Address for correspondence Edmundo Luís Rodrigues Pereira, MD, Universidade do Estado do Pará, Rua dos Pariquis, 1838, ap. 802, Jurunas, Belém, PA, Brazil CEP: 66033-590 (e-mail: eluis@ufpa.br).

Arq Bras Neurocir 2015;34:200–202.

Abstract

Background Arthrodesis to anterior cervical spine fusion (ACSF) following trauma remains an effective method to accomplish both vertebrae link and neural decompression using combined materials such as metal screws and plates, along a section of bone inserted between the two adjacent involved vertebrae plates, conferring reliable spinal stability. Present study shows an alternative technique using autologous ipsilateral clavicle bone graft to fracture disruptions localized at most inferior aspect of cervical spine.

Methods Five adult patients with C7–T1 fracture dislocations were treated by means of clavicular autograft to promote neural decompression and vertebral fusion. An anterior cervical supramanubrial approach was performed in all patients to perform a standard surgical approach and dissection to the anterior cervical spine.

Results No gross injury was found to adjacent structures, the middle one-third of the clavicle offered sufficient bone for the one to two segments fused with the remaining bone for at least two additional segments, and a convenient bone healing fusion was observed 3 to 6 months after the procedure, without local or regional complications from the technique.

Conclusion Autologous clavicle may be a suitable alternative to the iliac crest for use in anterior cervical fusion procedures with a convenient bone healing fusion.

Keywords
- cervical vertebrae
- column
- arthrodesis
- spinal fractures

Resumo

Introdução A artrodese de coluna cervical é um método eficaz para fixação vertebral e para descompressão neural, utilizando materiais como parafusos, placas de metal e um enxerto ósseo inserido entre as duas placas fixadas nas vértebras adjacentes, conferindo estabilidade para a coluna vertebral. O presente estudo mostra uma técnica alternativa que utiliza enxerto ósseo autólogo da clavícula ipsilateral a fraturas localizadas no segmento mais inferior da coluna cervical.

Métodos Cinco pacientes adultos com fraturas e luxações de C7-T1 foram tratados por meio de enxerto clavicular autólogo, com o intuito de promover a descompressão

Palavras-chave
- vértebras cervicais
- coluna
- artrodese da coluna vertebral
- fraturas

received
April 22, 2014
accepted
June 12, 2015

DOI http://dx.doi.org/10.1055/s-0035-1560028.
ISSN 0103-5355.

Copyright © 2015 by Thieme Publicações Ltda, Rio de Janeiro, Brazil

License terms

neural e fusão vertebral. Uma abordagem supramanubrial cervical anterior foi realizada em todos os pacientes, objetivando uma abordagem cirúrgica padrão e dissecção para a coluna cervical anterior.

Resultados Não houve lesão de estruturas adjacentes, o terço médio da clavícula utilizado foi suficiente para a fixação óssea do segmento inferior da coluna cervical, adequada fusão óssea foi observada 3-6 meses após o procedimento. Não houve complicações locais decorrentes da técnica.

Conclusões Enxerto clavicular autólogo pode ser uma alternativa à crista ilíaca em procedimentos de fusão cervical anterior, com fixação cervical adequada e poucas complicações.

Introduction

Anterior cervical fusion (ACF) with iliac bone graft is a suitable technique used to provide spinal stability and neural decompression.[1] Despite the safety of the procedure, a small group of patients suffers from undesired complications, mainly persistent pain on donor site.[2] Here we present an alternative to lower cervical spine fusion using clavicle bone graft instead, which revealed satisfactory results in the middle-term postsurgical follow-up.

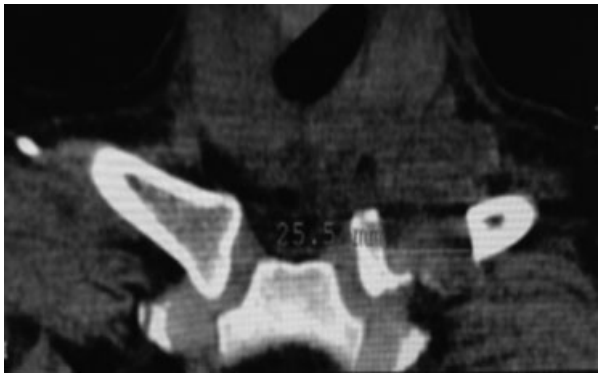

Fig. 1 Donor site of clavicular autologous bone graft.

Materials and Methods

Five adult patients (three men and two women, 23–40 years old) harboring C7–T1 fracture dislocations were treated by means of clavicular autograft to promote neural decompression and vertebral fusion. All patients were victims of traffic accidents, harboring no others injured sites, but 'ASIA A', according ASIA Impairment Scale (AIS) as the predominant preoperatively physical examination.

An anterior cervical supramanubrial approach was performed in all patients by means of a semicurved transverse skin incision above the left clavicular superior border to performer a standard surgical approach and dissection to the anterior cervical spine.

Lateral extension of incision was performed to gain further access to clavicular region, where a bone graft of approximately 2.5 cm was removed from the middle one-third of the clavicle (►**Fig. 1**), followed by a standard discectomy and corpectomy, with placement of harvested ipsilateral clavicle previously dissected (►**Fig. 2**), and an anterior cervical plating system was next placed over the segment using standard techniques.

The harvested clavicle as well as clinical and radiologic results were analyzed during the procedure, in the next day following surgery, and in postoperative follow-up of 01, 03, 06, and 12 months.

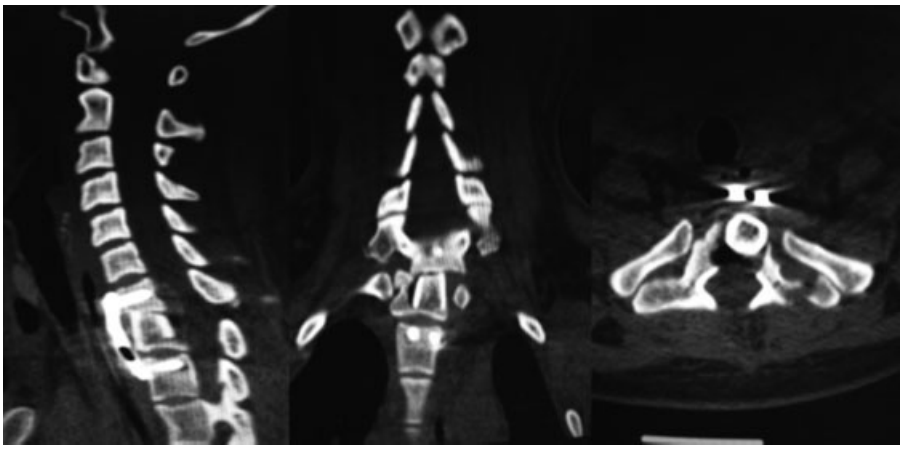

Fig. 2 Clavicular bone graft inserted between C7–T1.

Results

The results of our surgical analysis revealed that an average of 2.5 cm of the bone is easily removed from the middle one-third of the clavicle with standard techniques of bone removal. No gross injury was found to vicinal structures, the middle one-third of the clavicle offered sufficient bone for the one to two segments fused in our study with the remaining bone for at least two additional segments, and a convenient bone healing fusion was observed 3 to 6 months after the procedure, without local or regional complications from the technique.

Discussion

Anterior cervical fusion (ACF) is a safe and effective surgical treatment of cervical pathologies, including spinal instability/compression following trauma.[2,3] Inserting a structural graft is the key for successful results, to remove distraction of the resulting space following removal of the injured vertebrae, resulting in neural decompression along spinal stability.[4]

In earlier years, cervical fusion cages have been gaining acceptance as a method for ensuring cervical interbody arthrodesis. Some authors advocate that such fusion devices provide anterior structural support of the operative segments and obviate the need for harvesting tricortical bone block from the iliac crest.[5]

Autogenous cancellous bone graft alone or combined with metallic devices is preferred, once the presence of bone provides osteoconductive, osteoinductive, and osteogenic substrate for filling bone voids, augmenting efficacy of fracture healing.[1]

The iliac crest remains the most widely used site for bone-graft harvest, as it offers the advantage of easy access and a relatively large and safe supply bone. The proximal part of the tibia, distal end of the radius, and distal aspect of the tibia are also other alternative donor sites that may be useful for bone grafting in ACF procedures.[6,7]

However, these donor sites are no longer devoid of hazardous complications, such as persistent pain at the donor site, with less frequent complications, including nerve injury, hematoma, infection, and fracture at the donor site.[2,6,8,9]

Acute symptoms included also ambulation difficulty, persistent drainage, wound dehiscence, and local pain, whereas chronic symptoms included pain at the donor site, abnormal sensations at the donor site, and discomfort with clothing, ambulation, with long-term functional impairment.[6]

Such potential problems often occur when one may not be aware of regional anatomy and careful technique is no longer observed, once pain symptoms may be prevented by minimizing muscle dissections around donor sites. In such circumstances, until 30% of patients complain of local pain 6 months or even longer postoperatively. Although pain decreases with time, half of patients continue to report pain for more than 2 years.[6]

Patient should be counseled regarding these potential problems, and alternative sources of graft material should be considered in all instances. Other graft sources for cervical fusion procedures include synthetic materials and donor grafts, but considering the data that autologous bone grafts seem to generate the best results for fusion, the next logical step is to seek alternative donor sites so as to attempt to reduce the morbidity associated with these procedures.[4]

Autologous clavicle has not been properly explored as a potential source for cervical fusion, which may be reasonable considering anatomical proximity of the anterior cervical approach, mainly to treat lesions located at the inferior aspect of cervical spine, mainly the C6–C7 and C7–T1 vertebral segment.[10]

We performed autologous clavicular bone graft in five patients harboring C7–T1 lesions during anterior cervical spinal fusion procedures, with no local or systemic complications, no significant extend on surgical time, gaining a satisfactory degree of fusion on middle-term follow-up, revealing that this may be also a suitable bone graft site of utility in such types of injuries.

Conclusion

Autologous clavicle may be a suitable alternative to the iliac crest for use in anterior cervical fusion procedures, mainly those around the inferior aspect of cervical spine.

References

1 Syre P, Petrov D, Malhotra NR. Management of upper cervical spine injuries: a review. J Neurosurg Sci 2013;57(3): 219–240
2 Dimitriou R, Mataliotakis GI, Angoules AG, Kanakaris NK, Giannoudis PV. Complications following autologous bone graft harvesting from the iliac crest and using the RIA: a systematic review. Injury 2011;42(Suppl 2):S3–S15
3 Stein DM, Roddy V, Marx J, Smith WS, Weingart SD. Emergency neurological life support: traumatic spine injury. Neurocrit Care 2012;17(Suppl 1):S102–S111
4 Hsu WK. Advanced techniques in cervical spine surgery. J Bone Joint Surg Am 2011;93(8):780–788
5 Cabraja M, Kroppenstedt S. Bone grafting and substitutes in spine surgery. J Neurosurg Sci 2012;56(2):87–95
6 Hadley MN, Walters BC, Aarabi B, et al. Clinical assessment following acute cervical spinal cord injury. Neurosurgery 2013; 72(Suppl 2):40–53
7 Myeroff C, Archdeacon M. Autogenous bone graft: donor sites and techniques. J Bone Joint Surg Am 2011;93(23):2227–2236
8 Grabowski G, Cornett CA, Kang JD. Esophageal and vertebral artery injuries during complex cervical spine surgery—avoidance and management. Orthop Clin North Am 2012;43(1): 63–74, viii
9 Nassr A, Eck JC, Ponnappan RK, Zanoun RR, Donaldson WF III, Kang JD. The incidence of C5 palsy after multilevel cervical decompression procedures: a review of 750 consecutive cases. Spine 2012;37(3):174–178
10 Tubbs RS, Louis RG Jr, Wartmann CT, et al. Use of the clavicle in anterior cervical discectomy/corpectomy fusion procedures: cadaveric feasibility study. Childs Nerv Syst 2008;24(3): 337–341