

# Hemopericardium Due to Idiopathic Coronary Artery Rupture Treated with Saphenous Vein Patch Plasty

Benedikt Mayr<sup>1</sup> Stefan Buchholz<sup>1</sup> Christian Hagl<sup>1</sup> Maximilian Pichlmaier<sup>1</sup>

<sup>1</sup>Department of Cardiac Surgery, University Hospital of Munich LMU, Munich, Germany

Address for correspondence Benedikt Mayr, MD, Department of Cardiac Surgery, University Hospital Munich LMU, Marchioninstr. 15, Munich 81377, Germany (e-mail: Benedikt.Mayr@med.uni-muenchen.de).

Thorac Cardiovasc Surg Rep 2016;5:54–56.

## Abstract

### Keywords

- ▶ cardiovascular surgery
- ▶ heart disease
- ▶ artery/arteries (includes all peripheral arteries)

We report a case of an idiopathic coronary artery rupture in a 41-year-old male patient who was admitted to the hospital with cardiac tamponade. On opening the chest via a median sternotomy and establishing cardiopulmonary bypass the hemopericardium's cause could be identified as a perforation of the right posterior descending coronary artery which was treated with a saphenous vein patch plasty. With idiopathic coronary artery rupture being a rare diagnosis, one should always consider it in a young patient presenting with cardiac tamponade.

## Introduction

Primary coronary artery rupture is an uncommon disease with only a few reported cases linked to an often unfavorable prognosis.<sup>1,2</sup> Secondary coronary artery rupture can be associated with various etiologies such as trauma,<sup>3</sup> aneurysm,<sup>4</sup> infection,<sup>5,6</sup> connective tissue disorders,<sup>7</sup> and percutaneous coronary intervention.<sup>8</sup> We report a case of an idiopathic coronary artery rupture in a 41-year-old healthy man without any comorbidities or preceding events.

## Case Presentation

A 41-year-old policeman was admitted to the hospital with acute retrosternal pain (VAS 10) radiating into his neck, shortness of breath, and signs of centralization. His medical history and medication history did not reveal anything of relevance. Cardiovascular risk factors were smoking of approximately 20 cigarettes a day. During transportation to the hospital cardiopulmonary resuscitation had to be performed for 3 minutes due to bradycardia, but on arrival in the emergency department the patient was hemodynamically stable with systolic blood pressure of 130 mm Hg, heart rate of 56 beats per minute, and respiratory rate of 15 per minute.

The 12 lead electrocardiogram and cardiac enzymes did not show any pathological abnormalities. Cardiac tamponade was diagnosed in the transthoracic echocardiography. Contrast computed tomography confirmed a hemopericardium but also showed changes in the ascending aorta, suspicious of an intramural hematoma (▶ **Figs. 1 and 2**). Due to progressive hemodynamic instability and suspected aortic dissection type A the patient was urgently transferred to the operating room. The chest was opened via a median sternotomy and the hemopericardium was evacuated. The cause of the hemopericardium was eventually identified as a perforation of the right posterior descending coronary artery (RPD) and reconstruction of the vessel was performed using a venous patch of the great saphenous vein under cardiopulmonary bypass and cardioplegic cardiac arrest (▶ **Figs. 3 and 4**). To rule out aortic dissection aortotomy was conducted showing no intramural hematoma. Tissue samples of the coronary artery, epicardium, and ascending aorta were taken. In the first few postoperative hours only a low dosage of catecholamine was needed and the patient was extubated on the first day after surgery. After an uneventful postoperative course the patient was discharged on the 11th day after cardiac surgery. He was put on antiplatelet therapy with clopidogrel and aspirin for 3 months. Concerning the tissue samples only the epicardial

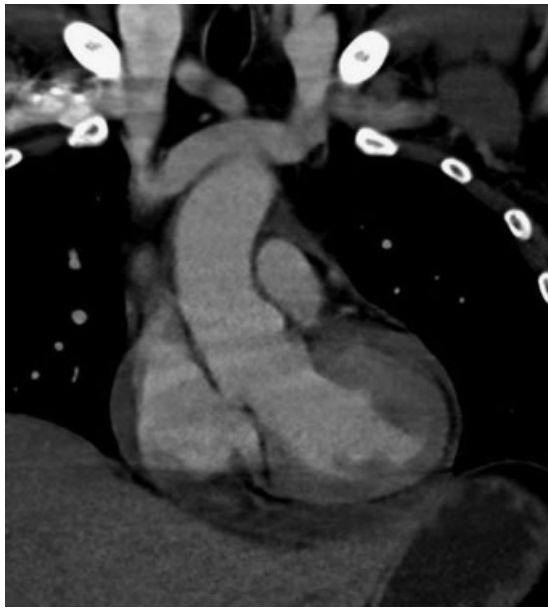
received  
May 2, 2015  
accepted after revision  
July 28, 2015  
published online  
February 18, 2016

DOI <http://dx.doi.org/10.1055/s-0035-1564586>.  
ISSN 2194-7635.

© 2016 Georg Thieme Verlag KG  
Stuttgart · New York

License terms



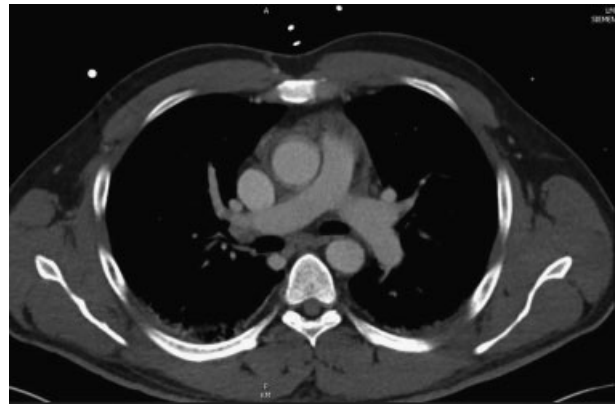


**Fig. 1** Coronal angio computed tomography of the chest showing pericardial effusion.

one showed signs of a fibrinous/hemorrhagic epicarditis. Another possible cause for carditis seemed a Lyme disease as the patient stated that he had been bitten by ticks in the summer—but the serology was negative.

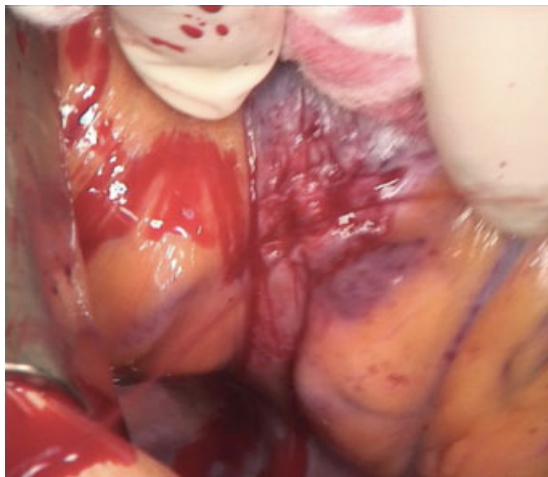## Discussion

Idiopathic coronary artery rupture is a rare disorder with only a few published cases<sup>1,2</sup> where the etiology of secondary coronary artery rupture/perforation is quite diverse with **Table 1** showing the different etiologies of secondary coronary artery rupture. Concerning our case the patient underwent cardiopulmonary resuscitation (CPR) before hospital admission so trauma might be the cause of the perforation of the right posterior descending coronary artery. Comparable to the force which is executed

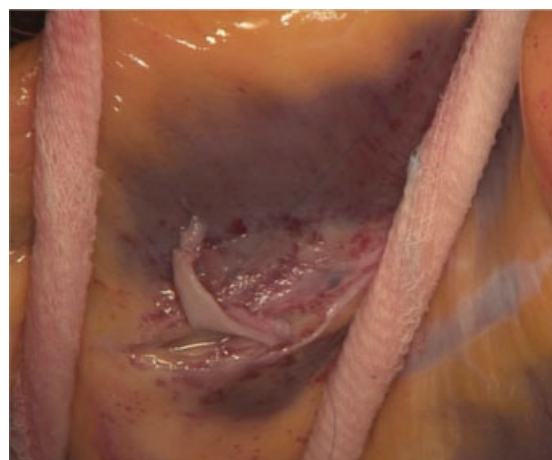


**Fig. 2** Axial angio computed tomography of the chest demonstrating alterations of the ascending aorta's wall suspicious of an intramural hematoma.

during CPR there is one published case in which the impact of an elbow to the chest during basketball resulted in the dissection of the right coronary artery.<sup>9</sup> A review of the literature by James et al reveals that most cases with blunt trauma to the chest are caused by motor vehicle accidents with the left main coronary artery (LMCA) and left anterior descending coronary artery being the primarily affected ones.<sup>5</sup> Another cause for cardiac tamponade is the coronary artery perforation during percutaneous coronary intervention which is graded by the Ellis classification with serious complications such as hemopericardium occurring with grade III perforations and mainly during the treatment of chronic total coronary occlusion.<sup>8</sup> Coronary artery perforation due to PCI can be treated interventionaly by using prolonged balloon inflation and covered stent implantation or surgically by coronary artery bypass grafting.<sup>10</sup> Another etiology for secondary coronary artery rupture is the rupture of a coronary aneurysm which is due to coronary artery fistula, congenital aneurysms, atherosclerosis, Kawasaki disease, Marfan syndrome, and infections such as mycotic emboli.<sup>4</sup> Coronary artery fistulas are the most common congenital anomaly of the



**Fig. 3** Perforation of the right posterior descending coronary artery with spurting of arterial blood.



**Fig. 4** Reconstruction of the coronary artery with vein patch plasty.

**Table 1** Causes of secondary coronary artery rupture

Causes of secondary coronary artery rupture
Trauma
Coronary aneurysm
Percutaneous coronary intervention
Autoimmune disease (Kawasaki disease)
Connective tissue disorders (Marfan syndrome)
Infection (Lyme borreliosis)

coronary arteries resulting in large aneurysms which should be treated surgically. Considering connective tissue disorders patients with Marfan syndrome are more at risk of developing spontaneous arterial aneurysms and dissections with Onoda et al reporting a case of an aneurysm of the LMCA after an original Bentall operation in a patient with Marfan syndrome.<sup>7</sup> In our case, the patient did not show any symptoms such as abnormal joint flexibility or arachnodactyly which could have indicated Marfan syndrome. Concerning Kawasaki disease the inflammation of the medium-sized blood vessels is often associated with the formation of coronary artery aneurysms, which are the late effect of inflammation in childhood, however, the medical history of the 41-year-old policeman did not show any evidence of inflammatory diseases during childhood and the tissue sample of the affected coronary artery did not show any pathological postinflammatory alterations. Another possible cause for secondary coronary artery rupture are mycotic coronary aneurysms caused by bacterial infections with *Staphylococcus aureus* which are usually accompanied with systemic infection.<sup>5</sup> As stated in our case history, the patient reported of various tick bites in summer so one could argue that the triggering factor for the hemopericardium might have been the formation of an aneurysm of the RPD with its subsequent rupture as a complication of long-standing Lyme borreliosis consistent with Gasser et al publishing a case of coronary artery aneurysm due to long-standing Lyme borreliosis.<sup>6</sup> Nevertheless the patient's serology in our case was negative for the specific Lyme antibodies. Concerning the treatment of coronary artery rupture it can be managed surgically or interventionaly. Interventionally speaking primary or secondary coronary artery rupture can be treated with a coated stent<sup>11,12</sup> or by microcoil embolic vessel occlusion.<sup>13</sup> With the different etiology of coronary artery rupture the surgical therapy might differ from patient to patient either using a saphenous vein patch plasty after aneurysmectomy<sup>14</sup> or bilateral ligation of the ruptured coronary artery and coronary artery bypass grafting.<sup>1</sup>

## Conclusion

In young patients presenting with cardiac tamponade primary or secondary coronary artery rupture is a rare diagnosis which should always be considered as a possible differential diagnosis with subsequent immediate interventional or surgical treatment.

## References

- Motoyoshi N, Komatsu T, Moizumi Y, Tabayashi K. Spontaneous rupture of coronary artery. *Eur J Cardiothorac Surg* 2002;22(3): 470–471
- Butz T, Lamp B, Figura T, et al. Images in cardiovascular medicine. Pericardial effusion with beginning cardiac tamponade caused by a spontaneous coronary artery rupture. *Circulation* 2007;116(16): e383–e384
- James MM, Verhofste M, Franklin C, Beilman G, Goldman C. Dissection of the left main coronary artery after blunt thoracic trauma: Case report and literature review. *World J Emerg Surg* 2010;5:21
- Gunduz H, Akdemir R, Binak E, Tamer A, Uyan C. Spontaneous rupture of a coronary artery aneurysm: a case report and review of the literature. *Jpn Heart J* 2004;45(2):331–336
- Osevala MA, Heleotis TL, DeJene BA. Successful treatment of a ruptured mycotic coronary artery aneurysm. *Ann Thorac Surg* 1999;67(6):1780–1782
- Gasser R, Watzinger N, Eber B, et al; Borreliosis Study Group. Coronary artery aneurysm in two patients with long-standing Lyme borreliosis. *Lancet* 1994;344(8932):1300–1301
- Onoda K, Tanaka K, Yuasa U, Shimono T, Shimpo H, Yada I. Coronary artery aneurysm in a patient with Marfan syndrome. *Ann Thorac Surg* 2001;72(4):1374–1377
- Shimony A, Zahger D, Van Straten M, et al. Incidence, risk factors, management and outcomes of coronary artery perforation during percutaneous coronary intervention. *Am J Cardiol* 2009;104(12): 1674–1677
- Hobelmann A, Pham JC, Hsu EB. Case of the month: Right coronary artery dissection following sports-related blunt trauma. *Emerg Med J* 2006;23(7):580–581
- Aykan AÇ, Güler A, Gül I, et al. Management and outcomes of coronary artery perforations during percutaneous treatment of acute coronary syndromes. *Perfusion* 2015;30(1):71–76
- Nageh T, Thomas MR. Coronary-artery rupture treated with a polytetrafluoroethylene-coated stent. *N Engl J Med* 2000;342(25): 1922–1924
- Kawano H, Matsumoto Y, Satoh O, et al. Successful treatment of a ruptured spontaneous dissecting coronary artery pseudoaneurysm with a covered stent in a patient with cardiac tamponade. *Intern Med* 2014;53(10):1067–1070
- Dorros G, Jain A, Kumar K. Management of coronary artery rupture: covered stent or microcoil embolization. *Cathet Cardiovasc Diagn* 1995;36(2):148–154, discussion 155
- Shrestha BM, Hamilton-Craig C, Platts D, Clarke A. Spontaneous coronary artery rupture in a young patient: a rare diagnosis for cardiac tamponade. *Interact Cardiovasc Thorac Surg* 2009;9(3): 537–539