Tailored PICA Revascularization for Unusual Ruptured Fusiform Vertebro-PICA Origin Aneurysms: Rationale and Case Illustrations

Andrew P. Carlson[1]

[1] Department of Neurosurgery, University of New Mexico, Albuquerque, New Mexico, United States

J Neurol Surg Rep 2015;76:e275–e278.

Address for correspondence Andrew P. Carlson, MD, MS-CR, Department of Neurosurgery, University of New Mexico, 1 UNM, Albuquerque, NM 87131, United States (e-mail: andrewcarlson@salud.unm.edu).

Abstract

Ruptured fusiform aneurysms of the vertebral artery involving posterior inferior cerebellar artery (PICA) origin are difficult to manage without sacrificing PICA. In this report, two very unusual cases are described which highlight different revascularization strategies that may be required. The first case initially appeared to be a small saccular PICA origin aneurysm, but detailed angiography showed a serpentine recanalization of a fusiform aneurysm. This was treated with PICA–PICA anastomosis and trapping of the aneurysm. The second case is a dissecting vertebral aneurysm with both PICA and the anterior spinal artery originating from the dome. PICA was found to be a bihemispheric variant, so no in situ bypass was available, and an occipital artery to PICA bypass was performed. The vertebral artery was occluded proximally only and follow-up angiography showed remodeling of the distal vertebral artery with the anterior spinal artery filling by retrograde flow from the distal vertebral artery. These cases illustrate both the anatomic variability of this region as well as the need to be familiar with multiple treatment strategies including revascularization techniques to be able to successfully treat these aneurysms.

Keywords
- aneurysm
- subarachnoid hemorrhage
- cerebral revascularization
- posterior inferior cerebellar artery
- extracranial–intracranial bypass

Introduction

Fusiform ruptured aneurysms of the vertebral artery involving posterior inferior cerebellar artery (PICA) or the vertebro-PICA (VA/PICA) origin are challenging aneurysms to treat.[1] Direct surgical clipping is usually not possible due to circumferential involvement of the vessel. Many surgical approaches have been described including clip/wrapping, segmental sacrifice, flow reversal with proximal occlusion, distal occlusion, and bypass with trapping. Of all these treatments, bypass with trapping likely offers the most durable option with less chance of infarction than trapping or sacrifice alone. Though endovascular techniques have been used,[2] cases of vessel sacrifice result in a predictably high rate of infarction and newer techniques such as flow diversion are limited in cases of subarachnoid hemorrhage due to the need for dual antiplatelet agents. Because of the extremely variable anatomy of the vertebral and PICA vasculature, the optimal treatment must be carefully determined with a full understanding of the specific angiographic anatomy and the impact of potential anatomic variations. In this report, we describe two cases of aneurysms involving the origin of PICA, both with very unusual anatomic features as well as the decision making involved in achieving a successful treatment for each.

Case Illustrations

Case 1: Fusiform Vertebral Origin Aneurysm with Serpentine Recanalization

This 52-year-old female patient presented with neck pain followed by severe headache and loss of consciousness. She

received
May 7, 2015
accepted after revision
August 10, 2015
published online
October 9, 2015

DOI http://dx.doi.org/10.1055/s-0035-1564607.
ISSN 2193-6358.

was found to have a Fischer grade 4, Hunt and Hess grade 3 subarachnoid hemorrhage. Computed tomographic angiography (CTA, ►**Fig. 1**) showed a possible left PICA origin saccular aneurysm, however, angiography revealed a small serpentine fusiform recanalization within the larger aneurysm dome. The aneurysm was not large or giant as most serpentine aneurysms are, and if it had been mistaken for a saccular aneurysm and clipped, would have resulted in occlusion of PICA at the origin and likely medullary and PICA infarction. Because of this very unusual anatomy, the decision was made to perform a bypass to the distal PICA and trap the serpentine segment at the inflow and outflow. The patient was taken for suboccipital craniotomy, partial left condylectomy, and midline PICA–PICA side-to-side anastomosis followed by trapping of the aneurysm at the origin of PICA. At the time of surgical inspection, there was found to be a separate inflow and outflow vessel into a larger dome, which could have been mistaken for a saccular or fusiform sidewall type aneurysm. Postoperatively, the patient was found to have a small asymptomatic distal left PICA stroke. She was discharged to rehab with no neurologic deficit but significant deconditioning. A 6-month follow-up angiogram showed patency of the bypass and the patient had returned to her neurologic baseline with no deficit.

Case 2: Vertebral Dissecting Aneurysm Involving the Origin of a Bihemispheric PICA and the Anterior Spinal Artery

This 42-year-old female patient presented after sudden onset worst headache of her life (►**Fig. 2**). On arrival, she was intubated, weakly following commands in the upper extremities with no significant movement in the lower extremities. Angiogram showed a fusiform dissecting aneurysm of the left vertebral artery involving the origin of PICA as well as the origin of the anterior spinal artery (ASA). The PICA was recognized to be a bihemispheric variant, crossing midline, and serving the contralateral PICA territory with aplasia of the contralateral PICA. The patient was taken for suboccipital craniotomy, partial left condylectomy, and occipital artery to PICA anastomosis (due to the lack of contralateral PICA). The vertebral artery was then clipped just proximal to the dilated segment. No distal clip was applied to allow retrograde filling of the ASA from the contralateral vertebral artery. Early follow-up angiography revealed patency of the bypass filling the bihemispheric PICA, patency of the ASA, and a small amount of slow filling of the aneurysm at the ASA level. She developed vasospasm and required balloon angioplasty to the right vertebral artery. She had a prolonged recovery with pneumonia and meningitis and required tracheostomy and

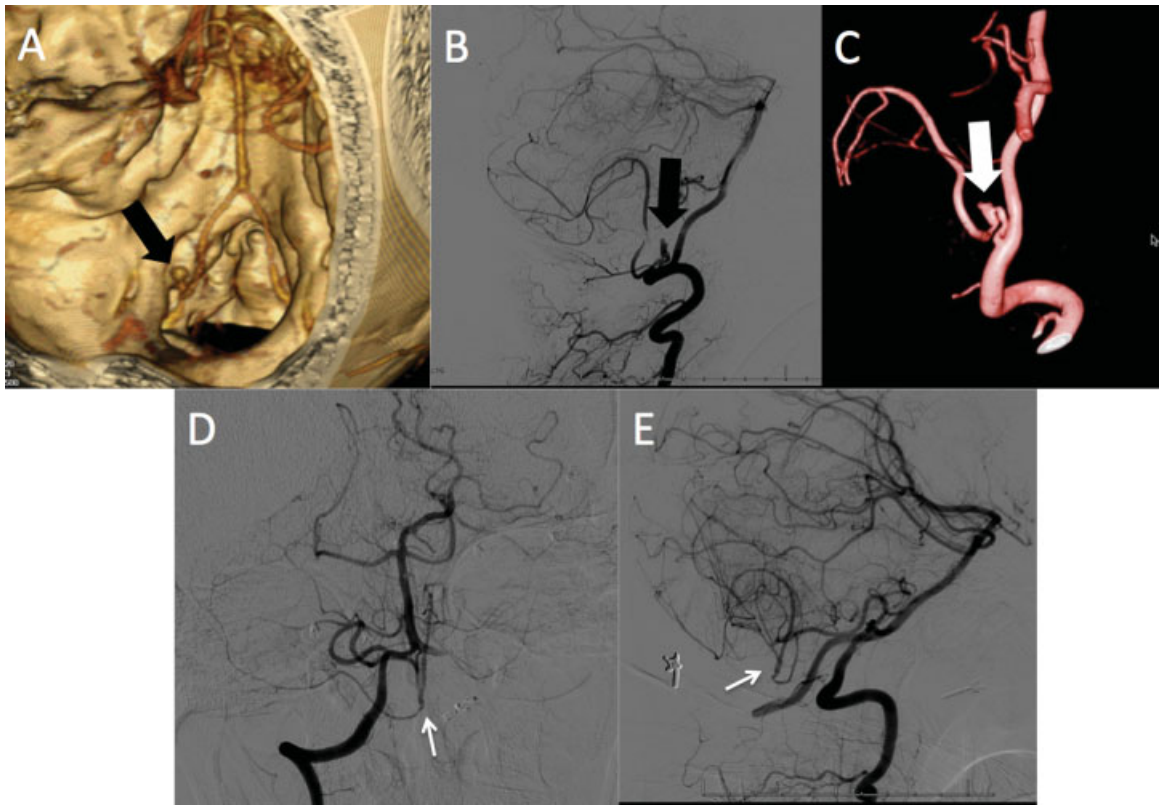

Fig. 1 Case 1: (A) Reconstructed CTA image showing the area suspicious for aneurysm (black arrow). The aneurysm appears to be saccular due to volume averaging. (B) Lateral angiogram of the left vertebral artery, showing the serpentine recanalization within the aneurysm (black arrow). This is better visualized on the 3D rotational angiogram reconstruction (C) showing the clear serpentine nature of the aneurysm (white arrow). (D, E) Follow-up angiogram at 6 months, with AP (D) and lateral (E) views demonstrating the patent bypass (white narrow arrow). 3D, three-dimensional; AP, anteroposterior; CTA, computed tomographic angiography.

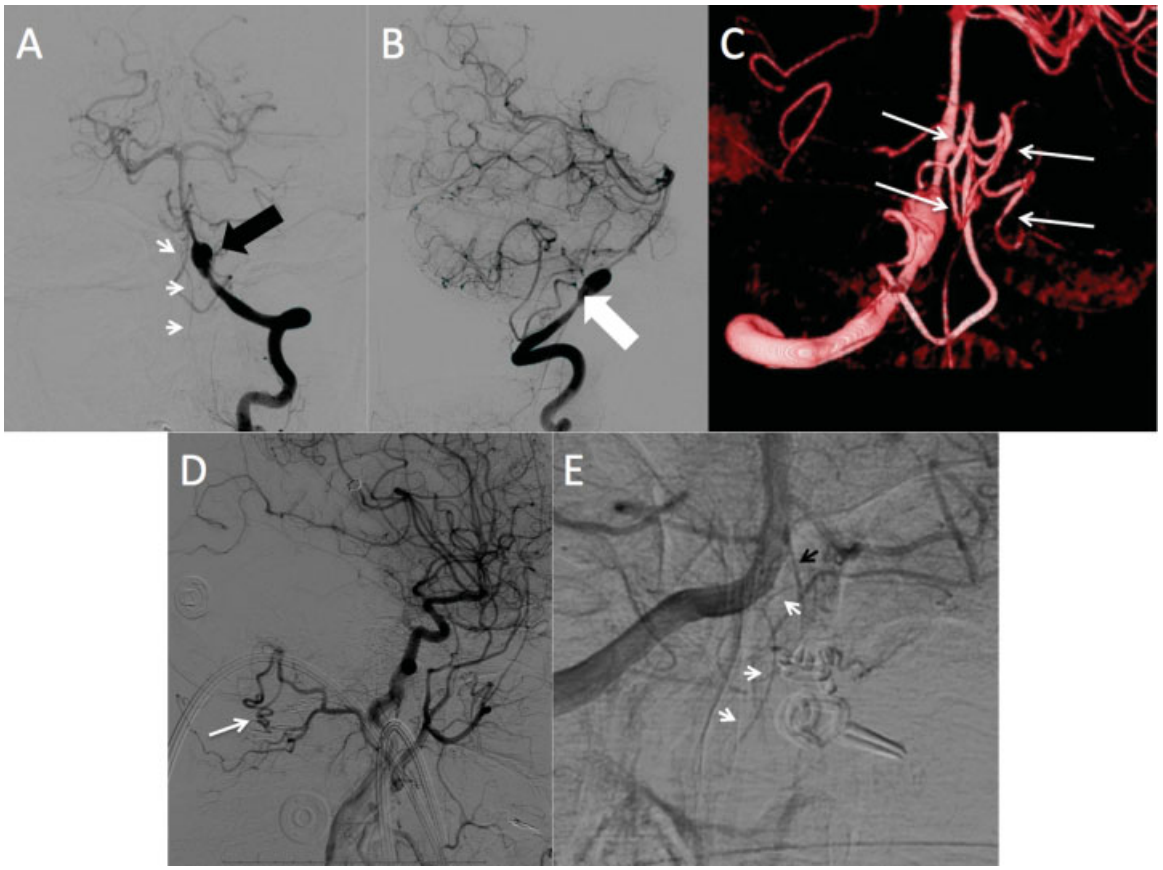

Fig. 2 Case 2: (A) Left vertebral artery AP angiogram, showing the fusiform aneurysm (black arrow) and the filling of the anterior spinal artery from the dome of the aneurysm (narrow white arrows). (B) Lateral angiogram of the left vertebral artery injection. The white arrow indicates the origin of the PICA from the dome of the aneurysm. C) Reconstruction of 3D rotational angiogram which shows bilateral filling of PICA territories (narrow white arrows) from the left PICA consistent with a bihemispheric variant. (D) Postoperative lateral projection of the left common carotid injection, showing the patent anastomosis from the occipital artery to the PICA (narrow white arrow). (E) Magnified AP projection of the postoperative injection of the right vertebral artery. Note that the distal left vertebral artery (black arrow) has remodeled to a very small channel that fills the anterior spinal artery (white arrows). There is no filling of the aneurysm itself. 3D, three-dimensional; AP, anteroposterior; PICA, posterior inferior cerebellar artery.

percutaneous endoscopic gastrostomy tube. At 6-month follow-up, the aneurysm is angiographically cured with patency of the bypass (feeding the bihemispheric PICA) as well as the ASA (from retrograde flow). Clinically she was awake and oriented, beginning to ambulate, and living at home.

Discussion

These two cases of ruptured aneurysms represent very unusual anatomic variations involving the VA/PICA origin. Each required tailored decision making and a detailed understanding of the involved anatomy as well as various bypass techniques to achieve angiographic cure. In case 1, the CTA revealed a small aneurysm at the origin of PICA, which appeared to likely be a simple saccular aneurysm. Angiography revealed instead that this was a very unusual small serpentine aneurysm with a separate inflow and outflow vessel. To our knowledge, this type of aneurysm has not been reported. Serpentine aneurysms are typically large or giant and require trapping and ensuring distal vascular supply, either with surgical revascularization or by relying on internal collaterals.[3,4] The same principle applies of trapping with restoration of distal flow was applied in this case. The technique of PICA–PICA side-to-side anastomosis was chosen due to the relative simplicity of the bypass and lack of extensive dissection time,[5] though other options such as occipital to PICA[6] and PICA reimplantation to the vertebral artery or interposition grafting could also be considered.

In case 2, the anatomic nuance was the recognition of the bihemispheric variant of the PICA as well as the origin of the ASA. Though previously thought to be rare,[7] we have recently observed a much higher incidence of bihemispheric PICA in greater than 3% of cases.[8] Sacrificing the vertebral artery in this segment would have put a much larger territory at risk for stroke than usually considered in cases of PICA sacrifice. This observation also was critical in planning of the bypass procedure in that a side-to-side anastomosis would not have been effective since the contralateral tonsillar loop of PICA was being fed by the ipsilateral PICA origin. For this reason, the occipital artery was required for revascularization of the PICA territory before proximal occlusion of the vertebral artery. The addition of distal occlusion for full trapping was considered as well and would have been a

more definitive treatment, but would have sacrificed the fairly large ASA. By occluding proximally, the ASA was able to fill retrograde and the artery remodeled on follow-up angiography, excluding the aneurysm.

Treatment of these aneurysms is complex due both to the rarity and variability in anatomic features[1] and the available literature is largely limited to very small case series and case reports. Park et al[6] recently reported a series of seven patients with VA/PICA aneurysms with occipital to PICA bypass. Six of these bypasses remained patent and the remaining patient suffered multiple infarctions in the target territory, underscoring the risk of stroke with sacrifice of the entire PICA. Wang et al[9] also reported the use of the occipital to PICA bypass in five patients with VA/PICA aneurysms with all remaining patent. Lemole et al[10] reported a series of four patients with VA/PICA aneurysms treated with trapping and PICA–PICA bypass, also showing good results in terms of patency and lack of infarction. Another report detailed the use of radial artery grafts from the V2–V3 segment and included three patients with PICA or PICA origin aneurysms.[11] Czabanka et al[12] also described two cases using a similar interposition graft technique in two cases of ruptured dissecting vertebral aneurysms. The importance of multiple treatment options for these aneurysms has also been emphasized including a variety of bypass options[13] and open and endovascular techniques.[2,14,15]

The described cases illustrate the importance of an understanding of potential anatomic variants and the need for technical proficiency with multiple treatment options depending on the specific anatomy of a specific aneurysm in this region.

Conclusions

Two very unusual cases of ruptured aneurysms involving the origin of PICA are presented. Each case illustrates a different bypass strategy for revascularization and trapping of the aneurysm. These cases underscore the importance of understanding the highly variable anatomy in treatment decision making. Familiarity with a variety of surgical, endovascular, and bypass options is critical for vascular neurosurgeons treating these complex lesions.

Disclosure
No potential conflict of interest exists for the presented article.

Financial Support
None.

Previous Presentation
Portion of this work was presented as an oral presentation at the 26th Annual Meeting of the North American Skull Base Society; February 20–22, 2015; Tampa, FL.

Acknowledgments
The author would like to thank Howard Yonas, MD, for his mentorship and advice regarding clinical management.

References

1 Yasui T, Komiyama M, Nishikawa M, Nakajima H. Subarachnoid hemorrhage from vertebral artery dissecting aneurysms involving the origin of the posteroinferior cerebellar artery: report of two cases and review of the literature. Neurosurgery 2000;46(1): 196–200, discussion 200–201
2 Chalouhi N, Jabbour P, Starke RM, et al. Endovascular treatment of proximal and distal posterior inferior cerebellar artery aneurysms. J Neurosurg 2013;118(5):991–999
3 Anson JA, Lawton MT, Spetzler RF. Characteristics and surgical treatment of dolichoectatic and fusiform aneurysms. J Neurosurg 1996;84(2):185–193
4 Aletich VA, Debrun GM, Monsein LH, Nauta HJ, Spetzler RF. Giant serpentine aneurysms: a review and presentation of five cases. AJNR Am J Neuroradiol 1995;16(5):1061–1072
5 Abla AA, Lawton MT. Revascularization for unclippable posterior inferior cerebellar artery aneurysms: extracranial-intracranial or intracranial-intracranial bypass? World Neurosurg 2014;82(5): 586–588
6 Park W, Ahn JS, Park JC, Kwun BD, Kim CJ. Occipital artery-posterior inferior cerebellar artery bypass for the treatment of aneurysms arising from the vertebral artery and its branches. World Neurosurg 2014;82(5):714–721
7 Cullen SP, Ozanne A, Alvarez H, Lasjaunias P. The bihemispheric posterior inferior cerebellar artery. Neuroradiology 2005;47(11): 809–812
8 Carlson AP, Alaraj A, Dashti R, et al. The bihemispheric posterior interior cerebellar artery: anatomic variations and clinical relevance in 11 cases. J Neurointerv Surg 2013;5(6): 601–604
9 Wang C, Shi XE, Wang J, Wang B, Tang Z. Long-term outcomes of trapping vertebral artery-posterior inferior cerebellar artery dissecting aneurysms after revascularization. Neurol India 2014; 62(1):15–18
10 Lemole GM Jr, Henn J, Javedan S, Deshmukh V, Spetzler RF. Cerebral revascularization performed using posterior inferior cerebellar artery-posterior inferior cerebellar artery bypass. Report of four cases and literature review. J Neurosurg 2002;97(1): 219–223
11 Yang T, Tariq F, Duong HT, Sekhar LN. Bypass using V2-V3 segment of the vertebral artery as donor or recipient: technical nuances and results. World Neurosurg 2014;82(6):1164–1170
12 Czabanka M, Ali M, Schmiedek P, Vajkoczy P, Lawton MT. Vertebral artery-posterior inferior cerebellar artery bypass using a radial artery graft for hemorrhagic dissecting vertebral artery aneurysms: surgical technique and report of 2 cases. J Neurosurg 2011; 114(4):1074–1079
13 Nussbaum ES, Madison MT, Myers ME, Goddard J, Janjua T. Dissecting aneurysms of the posterior inferior cerebellar artery: retrospective evaluation of management and extended follow-up review in 6 patients. J Neurosurg 2008;109(1): 23–27
14 Coert BA, Chang SD, Do HM, Marks MP, Steinberg GK. Surgical and endovascular management of symptomatic posterior circulation fusiform aneurysms. J Neurosurg 2007;106(5):855–865
15 Hamada J, Kai Y, Morioka M, Yano S, Todaka T, Ushio Y. Multimodal treatment of ruptured dissecting aneurysms of the vertebral artery during the acute stage. J Neurosurg 2003; 99(6):960–966