

# Strictly Intraventricular Craniopharyngioma: Case Report and Literature Review

## *Craniofaringioma puramente intraventricular: relato de caso e revisão da literatura*

Marcelo Lemos Vieira da Cunha<sup>1</sup> Ana Luiza Brunelli Pletz<sup>2</sup>

<sup>1</sup> Department of Neurosurgery, Hospital Regional do Oeste, Chapecó, SC, Brazil

<sup>2</sup> Course of Medicine, Universidade Federal do Paraná, Curitiba, PR, Brazil

Address for correspondence: Marcelo Lemos Vieira da Cunha, MD, Rua Lauro Muller, 224-E, Apto. 501, Centro, Chapecó, SC, Brazil CEP: 89801-600 (e-mail: marcelolvc@yahoo.com.br).

Arq Bras Neurocir 2018;37:113–118.

### Abstract

#### Keywords

- ▶ strictly intraventricular craniopharyngioma
- ▶ third ventricle
- ▶ transcallosal approach

Strictly intraventricular craniopharyngiomas are a rare topographical variety of craniopharyngiomas. The correct diagnosis is important in order to define the surgical planning, as the surgical access is different for suprasellar tumors with secondary invasion of the third ventricle. An image diagnosis may be difficult, though suggestive patterns exist. The aim of the present case report and literature review is to add to the scarce literature on strictly intraventricular craniopharyngiomas, as well as to remind the neurosurgeon of this rare diagnosis so that the proper treatment is provided.

### Resumo

#### Palavras-chave

- ▶ craniofaringioma puramente intraventricular
- ▶ terceiro ventrículo
- ▶ acesso transcaloso

Craniofaringiomas puramente intraventriculares constituem uma rara variedade topográfica dos craniofaringiomas. O diagnóstico correto é fundamental para a definição do plano cirúrgico, posto que o acesso a este tipo de tumor difere dos tumores supraselares com invasão secundária do terceiro ventrículo. A confirmação por neuroimagem pode ser difícil, embora existam características sugestivas. A presente descrição de caso, bem como a revisão de literatura, visa contribuir com a escassa literatura a respeito de craniofaringiomas puramente intraventriculares, além de remeter o neurocirurgião a este diagnóstico raro para a adoção da conduta correta de tratamento.

## Introduction

Patient LMBG, female, 38 years old, underwent a stereotactic biopsy in another service in 1997 due to an intraventricular expansive lesion. The result of the pathology examination at the time was oligodendroglioma. Radiotherapy was used as a complementary therapy. There was a loss of follow-up with the team responsible for the first treatment after the com-

pletion of the radiotherapy. The patient was admitted to our service in 2013, after the onset of a refractory headache 30 days before admission. There was an association with nausea and vomiting around 15 days after the onset of the headache, as well as evolution with paraparesis in the lower limbs. Five days before the referral to our service, the patient presented with speech difficulties and fainting. At the

received  
November 10, 2013  
accepted  
August 7, 2015  
published online  
October 28, 2015

DOI <https://doi.org/10.1055/s-0035-1564825>.  
ISSN 0103-5355.

Copyright © 2018 by Thieme Revinter Publicações Ltda, Rio de Janeiro, Brazil

License terms

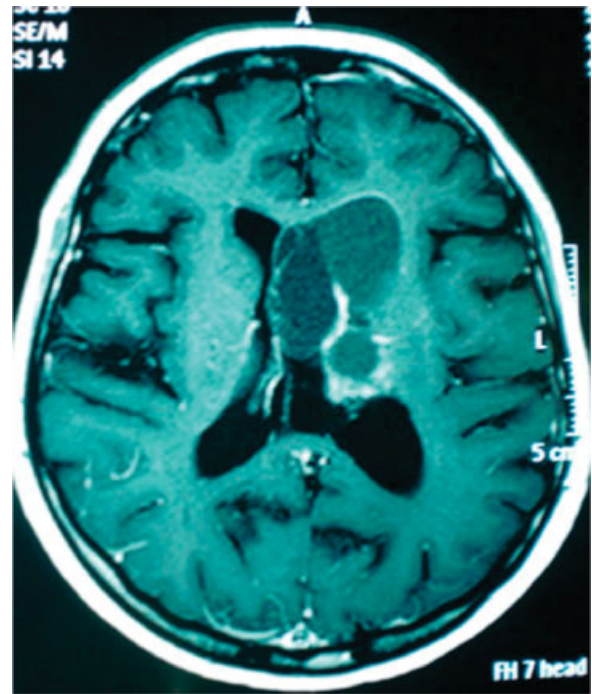


physical examination, she was wry, but with motor dysphasia. She had grade III symmetrical paraparesis in the lower limbs and grade I paresthesia in the lower limbs. There were no signs of pyramidal release and no involvement of the cranial nerves or of the cerebellar function. The deep reflexes were present and symmetrical. An imaging study was performed, showing an intraventricular solid-cystic expansive lesion (►Figs. 1, 2, 3). The patient underwent a microneurosurgical treatment with a transcallosal approach without interferences. Lesion resection was evidenced (►Fig. 4).

The postoperative period elapsed with motor aphasia without new deficits. The patient was discharged on the seventh postoperative day. After a new pathological study, a craniopharyngioma of the adamantinomatous subtype was evidenced.

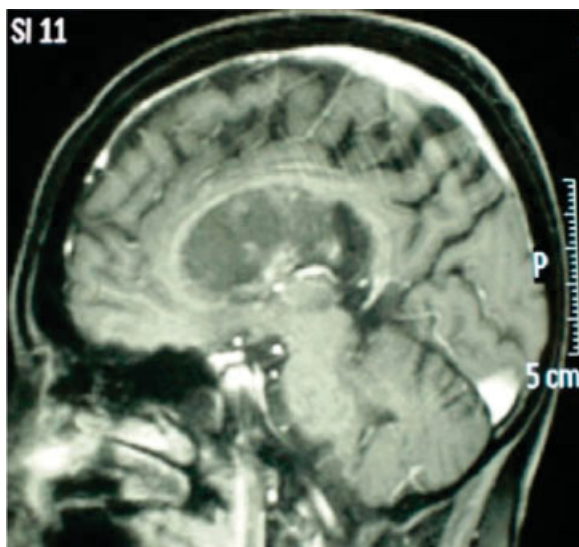
## Discussion

Purely intraventricular craniopharyngiomas are very rare. The incidence in the literature varies between 0.1 and 16.6%, with an average of 2.8% of all craniopharyngiomas. ►Table 1 defines the frequency of purely intraventricular craniopharyngiomas in several studies.<sup>1</sup> The first case was described in 1953 by Dobos,<sup>2</sup> and since then there are few cases described in the literature. Until the 1990s, only 22 cases had been described.<sup>3</sup> In some cases described prior to the use of magnetic resonance imaging (MRI) in the diagnosis of these lesions, an inaccurate topographic classification of the tumor was present, which led to an incorrect diagnosis of a primarily suprasellar tumor with secondary invasion of the third ventricle as intraventricular and vice versa. The craniopharyngiomas that affect the ventricular cavity must be differentiated in terms of their topography, and can be classified into four groups: pseudointraventricular, secondary intraventricular, not strictly intraventricular and pure intraventricular craniopharyngiomas. Pseudointraventricular craniopharyngiomas are supra-

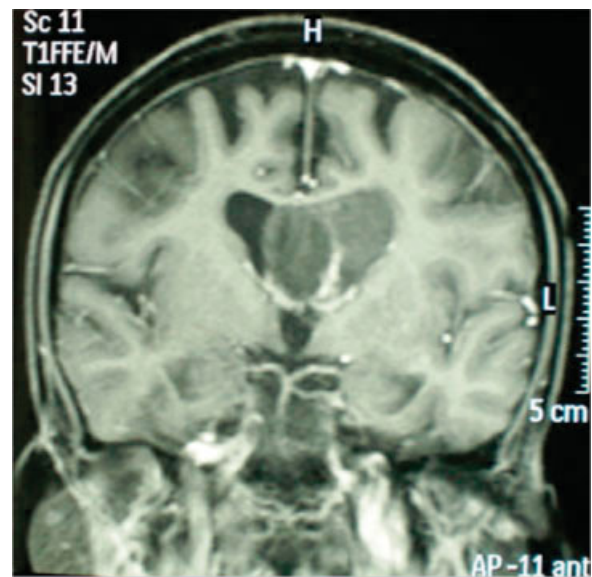

**Fig. 2** Axial cut of contrast-enhanced magnetic resonance imaging of the brain showing a solid-cystic intraventricular lesion with 5.3 cm of laterolateral length.

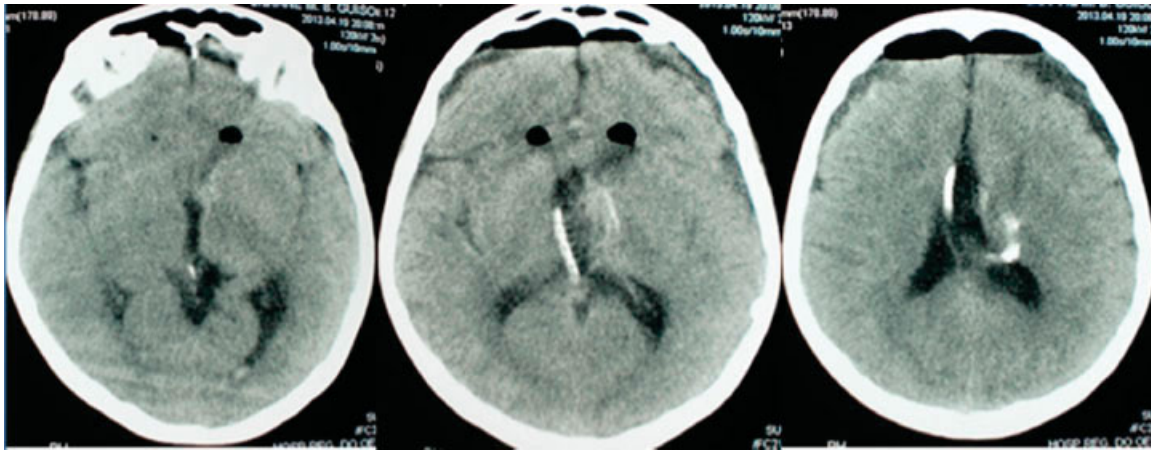
sellar tumors that push the lower wall of the third ventricle upwards, while secondary intraventricular craniopharyngiomas are suprasellar masses that invade the intraventricular cavity as they traverse the lower wall of the third ventricle. Regarding the intraventricular craniopharyngiomas, most of them invade the floor of the third ventricle, which is replaced by the tumor, with the margins of the ventricle remaining intact in only a small portion of cases, which are defined as purely



**Fig. 1** A sagittal section of contrast-enhanced T1-weighted magnetic resonance imaging showing evidence of corpus callosum and of a solid-cystic intraventricular lesion with 6.1 cm of anteroposterior length.



**Fig. 3** Coronal computed tomography corneal magnetic resonance imaging cut in contrast showing a solid-cystic intraventricular lesion with 2.8 cm of cranial caudal length.



**Fig. 4** Three axial sections, in sequence, of contrast tomography with lesional resection.

**Table 1** Percentage of purely intraventricular craniopharyngiomas in relation to all craniopharyngiomas in several studies

Series	% PIVC
Behari et al <sup>5</sup>	8.0
Steno et al <sup>10</sup>	1.3
Tomita, Bowman <sup>11</sup>	16.6
Zuccaro <sup>12</sup>	1.3
Lena et al <sup>13</sup>	2.1
Shi et al <sup>14</sup>	8.0
De Divitiis et al <sup>15</sup>	0.1
Zhang et al <sup>16</sup>	2.4
Pan et al <sup>17</sup>	4.6

Abbreviations: PIVC, purely intraventricular craniopharyngioma.

intraventricular craniopharyngiomas. Another difference between intraventricular tumors lies in the pattern of adhesion to the ventricle floor. While pure intraventricular tumors usually connect to the ventricular floor by a pedunculated, vascularized and non-reactive gliosis process (in 48% of the cases), non-purely intraventricular tumors present an extensive and firm adhesion to the floor and lateral walls of the third ventricle, without a leptomeningeal layer separating the neural tissue from the tumor wall (in up to 64% of the cases).<sup>2</sup>

Two subtypes of craniopharyngiomas were described: adamantinomatous and papillary, with histopathological and radiological differences, which are summarized in ► **Tables 2** and **3**.<sup>4</sup> The adamantinomatous subtype affects mainly children, although it can affect adults. It is heterogeneous, with solid and cystic parts, with an irregularly lobed smooth surface. In its interior, it presents a brown or yellowish liquid with cholesterol crystals, solid areas with granular consistency, keratin and calcium microcysts, and the peritumoral brain tissue presents dense gliosis, rich in Rosenthal fibers, which are small islands of tumor cells distant from the tumor mass.<sup>3</sup> In the MRI exams, precontrast T1 images frequently reveal single or multiple hyperintense cysts with peripheral enhancement; and in T2,

**Table 2** Histopathological differences between craniopharyngiomas of the adamantinomatous and squamous-papillary subtypes based on the World Health Organization classification of brain tumors

Histopathology	Adamantinomatous (solid-cystic mix)	Squamous-papillary (predominantly solid)
Displacement or adhesion to adjacent vessels or cranial nerves	+	–
Calcifications	+	Rare
Cyst with cholesterol	+	–
Keratin nodule	+	–
Cholesterol cracks	+	–
Necrotic flares and fibrosis	+	–
Keratin-positive squamous epithelium with:		
Peripheral cellular palladium	+	–
Starry reticle	+	–
Papillary formations	–	+
Inflammatory reaction	+	–
Brain invasion	+++	+

+, present; –, absent; +++, extremely common.

Source: Sartoretti-Schefer et al.<sup>4</sup>

the cysts may be hypointense or hyperintense.<sup>4</sup> These cysts contain cholesterol, triglycerides, methemoglobin, protein, and desquamative epithelium. Adamantinomatous tumors are more strongly associated with non-purely intraventricular craniopharyngiomas.<sup>2</sup>

The papillary subtype affects almost exclusively adults, with a peak between the ages of 40 and 45 years old,<sup>3</sup> and

**Table 3** Clinical and radiological (magnetic resonance) characteristics typical of adamantinomatous and squamous-papillary craniopharyngiomas

	Adamantinomatous craniopharyngioma	Scaly-papillary craniopharyngioma
Site	Suprasellar	Intrasellar/suprasellar or suprasellar
Age	Children (occasionally adults)	Adults
Tissue structure	Predominantly cystic <sup>†</sup>	Predominantly solid <sup>‡</sup>
Tumor cyst in T1 image without contrast	Hyperintense cyst (classic); <sup>‡</sup> possible hypointense cyst	Hypointense cyst, if any <sup>‡</sup>
Tumor form	Predominantly lobed <sup>†</sup>	Predominantly spherical <sup>†</sup>
Coating of subarachnoid arteries	Yes <sup>‡</sup>	No
Tumor recurrence	+++	+
Calcifications	+++	+

+++ , extremely common; + , common.

Source: Sartoretti-Schefer et al.<sup>4</sup>

Notes: These radiological features are statistically significant for differentiation between adamantinomatous and squamous-papillary craniopharyngiomas by Fisher Exact Test. <sup>†</sup>These radiological features show a trend toward statistical significance for differentiation between adamantinomatous and squamous-papillary craniopharyngiomas by Fisher Exact Test.

shows a tendency to affect the 3rd ventricle (40% of the cases).<sup>2</sup> In the macroscopy exam, it is a predominantly cystic, thin-walled tumor. Histologically, anastomotic cords of pavement epithelium are verified within a loose connective tissue stroma; in the center, keratinized cells are found; no keratoid nodules, calcifications or cholesterol crystals are found; the peritumoral brain tissue presents slight gliosis, and is devoid of tumor cells.<sup>3</sup> If there are cysts, they appear as hypointense signs on T1 images with no MRI contrast. Calcifications can occur in both subtypes, although they are more frequent in adamantinomatous craniopharyngiomas, which also have a higher recurrence rate,<sup>4</sup> partly explained by the characteristics of the peritumoral tissue.

Perhaps, this characteristic of the adamantinomatous subtype explains the latency period found in our case.

Intraventricular craniopharyngiomas affect a higher age group than the suprasellar classics. Due to their slow growth and intracavitary location, the obstruction to cerebrospinal fluid flow and the invasion of vital structures occur later, delaying the diagnosis.<sup>5,6</sup> This topographic variety presents other differences in relation to the suprasellar tumors. While visual and endocrine disorders are quite common in suprasellar tumors, with a prevalence of 70% to 90%, the frequency is significantly lower in the intraventricular (28% and 27% respectively); the opposite occurs with psychiatric symptoms, with an incidence of 40% in purely intraventricular tumors, and an incidence of < 15% in the suprasellar tumors.<sup>2,3,5,6</sup> Memory loss affects up to 33% of the patients with this rare tumor. These differences can be explained by the position of the tumor, involving the third ventricle floor, the mammillary bodies and the hypothalamus. Involvement of the third ventricle and of the hypothalamus is often associated with obesity, sexual dystrophy and diabetes insipidus.<sup>1</sup> These patients may present with headache and vomiting due to increased intracranial pressure.<sup>5,6</sup> Visual impairment is more common in suprasellar tumors; in the intraventricular space, it results from chiasmatic compres-

sion by the bulging of the terminal lamina and the chiasmatic recess of the third ventricle.<sup>5</sup>

Behari et al<sup>5</sup> reported six cases of purely intraventricular craniopharyngiomas. In all cases, the diagnosis was confirmed preoperatively by an MRI exam. A total of 4 patients presented cystic lesions, and 2 presented solid lesions. All of the patients presented with intracranial hypertension and papilledema. All of the patients were submitted to surgery, by different approaches, and two patients received radiotherapy for residual lesions. One patient died from septicemia in the perioperative period. During the follow-up, which lasted up to 36 months, the computed tomography (CT) scans did not show recurrence or lesion growth. Tayari et al<sup>6</sup> reported the case of a 22-year-old female patient complaining of chronic headache with papilledema. A preoperative MRI demonstrated a large lesion in T1 and hypointense in T2 in the third ventricle, obstructing the foramen of Monro. The patient underwent a transcallosal surgery, and the diagnosis was confirmed by anatomopathology, which revealed a mixed papillary tumor. During the follow-up, which lasted 9 months, there was no recurrence or lesion growth.

The correct topographic diagnosis of craniopharyngiomas is fundamental to establish the surgical plan, since the access is different for suprasellar and intraventricular tumors. The error in the topographic diagnosis of the tumor leads to an inadequate surgical approach.<sup>2</sup> Both subtypes of craniopharyngiomas can be accessed via the pterional or the subfrontal approaches, which may include orbitozygomatic or clinoidal osteotomy. In the case of suprasellar tumors, the opening of the terminal lamina is usually not necessary, whereas the intraventricular tumors are accessed through this structure.<sup>5</sup> Magnetic resonance imaging and tomography should demonstrate the floor of the third ventricle intact, an evident suprasellar cistern, a hypophyseal stem within normality, and no seal changes. Tumor calcification, which is common in suprasellar tumors (50–80%), is rare in the intraventricular variety.<sup>5</sup> Confirmation through neuroimaging can be



difficult, since at the time of the diagnosis the tumors are generally large and have already invaded the third ventricle, making the anatomic differentiation between the ventricular and tumor margins difficult. There are data, however, that suggest and should raise the suspicion of intraventricular craniopharyngioma: rounded, solid or cystic tumor with homogeneous signal intensity.<sup>2</sup>

Ideally, there should be a preoperative differentiation between exclusively intraventricular tumors (purely intraventricular or not), but, even with current diagnostic resources, this does not usually occur, since it is difficult to define the extra or subpolar involvement of the ventricle by the craniopharyngioma though a preoperative MRI.<sup>1</sup>

In the postoperative period, however, the MRI identifies the integrity of the floor and the situation of the third ventricle, enabling the differential diagnosis between these topographic subtypes.<sup>2</sup>

Some characteristics of non-purely intraventricular tumors are the predominantly adamantinomatous histological pattern, extensive adhesions to the floor of the third ventricle, and worse surgical outcome due to the proximity of the hypothalamus.<sup>2</sup>

The main differential diagnoses with tumors that originate primarily in the ventricle include colloid cyst, ependymoma, choroid plexus papilloma, astrocytoma, and meningioma.<sup>5,6</sup> Although imaging methods are fundamental in the diagnosis of brain pathologies, the histopathological diagnosis is only possible with a biopsy. There are reports in the literature of cases in which a diagnosis based on imaging methods alone would be incorrect in between 13% and 26% of the cases.<sup>7</sup>

There are several indications for stereotactic biopsy, including the collection of intracranial expansive lesions, drainage of cysts, abscesses and hematomas, resection of brain lesions in eloquent areas, radiosurgery, implantation of radioactive isotopes, among others.<sup>8</sup>

Although the correct diagnosis can be observed in the majority of cases, difficulties in the interpretation of the stereotactic biopsy may lead to diagnostic errors, as occurred with the patient reported in the present study. According to Pittella,<sup>8</sup> the main situations that can lead to error are: thick and hypercellular smears of normal white matter, simulating a low grade glioma; reactive gliosis with Rosenthal fibers around craniopharyngiomas, simulating astrocytoma; posterior fossa lesions containing neurons of the granular layer, mimicking medulloblastoma, lymphoma, or an inflammatory process by generating densely cellular and small cell smears; poorly differentiated primary neoplasms versus metastases; and the correctness in the classification and graduation of the neoplasia.

The treatment of choice is surgical, and the access to intraventricular craniopharyngiomas presents a greater technical difficulty in relation to the suprasellar tumors, because it is necessary to cross healthy structures to access the ventricle. The surgical difficulty is elevated by complex topographic relationships with vital neurovascular structures. An adequate exposure of the tumor to direct vision throughout the surgical procedure is important to avoid traumatic and ischemic hypothalamic lesions.<sup>1</sup> The main

techniques described are transcallosal, frontal transcortical and the terminal lamina approach. The latter has low morbidity, but is related to lower success rates in total mass resection.<sup>2</sup> Invasion of the walls of the third ventricle and the proximity of the hypothalamus increase the risk of sequelae, and the maintenance of the anatomical integrity of the ventricular walls is essential.<sup>1</sup> In cases of extensive and firm adhesion to the third ventricle, and with characteristics of non-purely intraventricular tumors, Pascual et al<sup>2</sup> advised against radical tumor excision to avoid hypothalamic lesions. There are reports in the literature of the successful use of radiotherapy after surgery with partial resection of the craniopharyngioma. Behari et al<sup>5</sup> described two cases in which tomography during the follow-up showed the total resolution of the lesions after radiotherapy. Stereotactic radiosurgery is associated with a progressive shrinkage of the tumor mass with a normalization of the ventricle format.<sup>1</sup> If possible, an MRI exam of the brain should be performed within the first 72 hours postoperatively to verify the presence of residual tumor and of complications such as hypothalamic and vascular lesions.<sup>9</sup>

## Conclusion

Purely intraventricular craniopharyngiomas are a rare topographic variety of craniopharyngiomas. The diagnostic examination of choice is MRI. The preoperative differentiation from the suprasellar tumors with secondary invasion of the ventricle walls is fundamental for the correct surgical planning. The differentiation between intraventricular subtypes – purely intraventricular or not – is difficult to achieve preoperatively through an MRI exam. The postoperative examination can make the differential diagnosis most of the time. Stereotactic biopsy is of great value in the neurosurgical practice, but it has limitations in the precise diagnosis. The treatment of choice is always the complete resection of the tumor, and adjuvant radiotherapy can be performed in cases of incomplete resection.

## References

- 1 Pascual JM, Prieto R, Carrasco R. Infundibulo-tuberal or not strictly intraventricular craniopharyngioma: evidence for a major topographical category. *Acta Neurochir (Wien)* 2011;153(12): 2403–2425, discussion 2426
- 2 Pascual JM, González-Llanos F, Barrios L, Roda JM. Intraventricular craniopharyngiomas: topographical classification and surgical approach selection based on an extensive overview. *Acta Neurochir (Wien)* 2004;146(08):785–802
- 3 Zanon-Collange N. Craniofaringioma: atualização terapêutica. Sociedade de Neurocirurgia de São Paulo; 2006
- 4 Sartoretti-Schefer S, Wichmann W, Aguzzi A, Valavanis A. MR differentiation of adamantinomatous and squamous-papillary craniopharyngiomas. *AJNR Am J Neuroradiol* 1997;18(01):77–87
- 5 Behari S, Banerji D, Mishra A, et al. Intrinsic third ventricular craniopharyngiomas: report on six cases and a review of the literature. *Surg Neurol* 2003;60(03):245–252, discussion 252–253
- 6 Tayari N, Etemadifar M, Hekmatnia A, Mahzouni P, Maghzi AH, Rouzbahani R. Intrinsic third ventricular craniopharyngioma: A case report. *Int J Prev Med* 2011;2(03):178–185

- 7 Arbit E, Galicich JH. Importance of image-guided stereotactic biopsy to confirm diagnosis in an oncological setting. *Ann Surg Oncol* 1994;1(05):368–372
- 8 Pittella JEH. Biópsia estereotáxica no diagnóstico de tumores cerebrais e lesões não neoplásicas: indicações, acurácia e dificuldades diagnósticas. *J Bras Patol Med Lab* 2008;44(05):343–354
- 9 Curran JG, O'Connor E. Imaging of craniopharyngioma. *Childs Nerv Syst* 2005;21(8-9):635–639
- 10 Steno J, Maláček M, Bízík I. Tumor-third ventricular relationships in supradiaphragmatic craniopharyngiomas: correlation of morphological, magnetic resonance imaging, and operative findings. *Neurosurgery* 2004;54(05):1051–1058, discussion 1058–1060
- 11 Tomita T, Bowman RM. Craniopharyngiomas in children: surgical experience at Children's Memorial Hospital. *Childs Nerv Syst* 2005;21(8-9):729–746
- 12 Zuccaro G. Radical resection of craniopharyngioma. *Childs Nerv Syst* 2005;21(8-9):679–690
- 13 Lena G, Paz Paredes A, Scavarda D, Giusiano B. Craniopharyngioma in children: Marseille experience. *Childs Nerv Syst* 2005;21(8-9):778–784
- 14 Shi XE, Wu B, Zhou ZQ, Fan T, Zhang YL. Microsurgical treatment of craniopharyngiomas: report of 284 patients. *Chin Med J (Engl)* 2006;119(19):1653–1663
- 15 de Divitiis E, Cappabianca P, Cavallo LM, Esposito F, de Divitiis O, Messina A. Extended endoscopic transsphenoidal approach for extrasellar craniopharyngiomas. *Neurosurgery* 2007;61(05, Suppl 2):219–227, discussion 228
- 16 Zhang YQ, Ma ZY, Wu ZB, Luo SQ, Wang ZC. Radical resection of 202 pediatric craniopharyngiomas with special reference to the surgical approaches and hypothalamic protection. *Pediatr Neurosurg* 2008;44(06):435–443
- 17 Pan J, Qi S, Lu Y, et al. Intraventricular craniopharyngioma: morphological analysis and outcome evaluation of 17 cases. *Acta Neurochir (Wien)* 2011;153(04):773–784