

Preoperative Interventional Therapy for Childhood Undifferentiated Embryonal Liver Sarcoma: Two Retrospective Cases from a Single Center

Xiaoxia Zhao¹ Qixing Xiong¹ Jinhu Wang¹ Min-Ju Li¹ Qi Qin¹ Shoujiang Huang¹ Weizhong Gu¹
Qiang Shu¹ Jinfa Tou¹

¹ Department of Pediatric Surgery, Children's Hospital, Zhejiang University School of Medicine, Hangzhou, Zhejiang, China

Eur J Pediatr Surg Rep 2015;3:90–93.

Address for correspondence Jinfa Tou, PhD, Department of Pediatric Surgery, Children's Hospital, Zhejiang University School of Medicine, 57 Zhugan Xiang, Hangzhou, Zhejiang, China 310003 (e-mail: toujinfa@zju.edu.cn).

Abstract

Background Undifferentiated embryonal liver sarcoma (UELS) accounts for only 9 to 15% of all malignant liver tumors in children. Typically, UELS occurs in older children and presents as an abdominal mass. Most UELS are unresectable because of the later diagnosis. The outcome of UELS is very poor, with a 5-year overall survival of < 37.5%. Transarterial chemoembolization (TACE) has been reported to be an effective modality for unresectable liver tumors. To investigate the effects of TACE on UELS in children, we present two cases of children with UELS who underwent TACE and surgical resection in our center within the past 10 years.

Methods In this study, two children with UELS were treated using TACE with cisplatin, doxorubicin, and iodized oil. The size of the tumors was measured before and after TACE using ultrasonography. Routine was also given before and after surgical resection. Side effects were recorded. Both patients had follow-up.

Results After interventional therapy, both patients presented with vomiting, fever, and transient liver dysfunction without cardiac or renal dysfunction. One patient had bone marrow depression. The size of the tumors was reduced by 23% to 31% after TACE. The tumors were completely removed by surgical procedures after 4 weeks of TACE in both patients. One patient survived free of disease for 1 year, and the other survived free of disease for 9 years.

Conclusion TACE yielded satisfactory results for unresectable UELS in children, with lower dosage of chemotherapy and fewer side effects. It may be applied as a preoperative therapy for children with unresectable UELS.

Keywords

- undifferentiated embryonal liver sarcoma
- transarterial chemoembolization
- child

New Insights and the Importance for the Pediatric Surgeon

Undifferentiated embryonal liver sarcoma (UELS) is an uncommon tumor. In percent years, various types of chemotherapy have been developed to increase its resection rate and survival rate, however, most cases lose the chance to remove the tumor at the initial presentation. The present study analyses the use of preoperative TACE in two cases with UELS, and would encourage all pediatric surgeons to be familiar with the new treatment.

received
November 29, 2014
accepted after revision
September 17, 2015
published online
November 19, 2015

DOI <http://dx.doi.org/10.1055/s-0035-1566219>.
ISSN 2194-7619.

© 2016 Georg Thieme Verlag KG
Stuttgart · New York

License terms



Introduction

Undifferentiated embryonal liver sarcoma (UELS) accounts for only 9 to 15% of all malignant liver tumors in children. Typically, UELS occurs in older children and presents as an abdominal mass. Most UELS are unresectable because of the later diagnosis. The outcome of UELS is very poor, with a 5-year overall survival of < 37.5%.¹ Recently, transarterial chemoembolization (TACE) has been used in an attempt to reduce the toxicity of chemotherapy and this method is accepted as effective and safe for the treatment of unresectable adult hepatocellular carcinoma (HCC).² We used this procedure for two children with UELS and observed a favorable response. Herein, we report the cases of two children with UELS who underwent TACE and surgical resection in our center within the past 10 years.

Case Report

Case1

A 7-year-old girl had been presented with an abdominal pain and abdominal mass for the last 7 days. She did not have any other associated symptoms. Family history was insignificant. The weight of the patient was 26 kg. On examination, the child was found to have a large abdominal mass in the right lobe of the liver. The laboratory investigations revealed abnormal liver tests (alanine aminotransferase [ALT] 56 U/L), serum α -fetoprotein (AFP), and inflammatory tests were normal. An

ultrasound examination identified it was a hepatic mass like hepatoblastoma. The patient was presumptively diagnosed with UELS by an ultrasound-guided needle biopsy. The tumor was evaluated with computed tomography (CT) scan and magnetic resonance imaging (MRI) to examine the size and extent of the primary tumor and the involvement of major vessels (**Fig. 1A, B**). The tumor was considered unresectable if it involved a large part of both lobes of the liver or had invaded the main hepatic vessels or inferior vena cava. Pulmonary metastasis was excluded via lung CT scan.

Under basal plus caudal anesthesia and aseptic conditions, the right femoral artery was catheterized with a radiography catheter (5F) using the Seldinger technique. Using digital subtraction angiography fluoroscopy, the celiac axis and proper hepatic artery were identified. Using an intra-arterial catheter, the right hepatic artery was identified, and diatrizoate meglumine was used to identify the location of blood vessels and the range of the blood supply range. The tumor's vessel around the mass showed a "holding ball" appearance (**Fig. 1C, D**). At the time of angiography, 80 mg/m² cisplatin (PLA), 30 mg/m² doxorubicin (DO), and 1.5 mg/m² vincristine were mixed with saline; one portion was infused slowly (90 minutes), and one portion was dispersed in lipiodol and injected into the feeding artery of the tumor. After embolization, celiac angiography confirmed the patency of major vessels and the occlusion of the feeding arteries.

TACE was successfully performed in this patient. In the first day after TACE, she presented with vomiting, fever, and

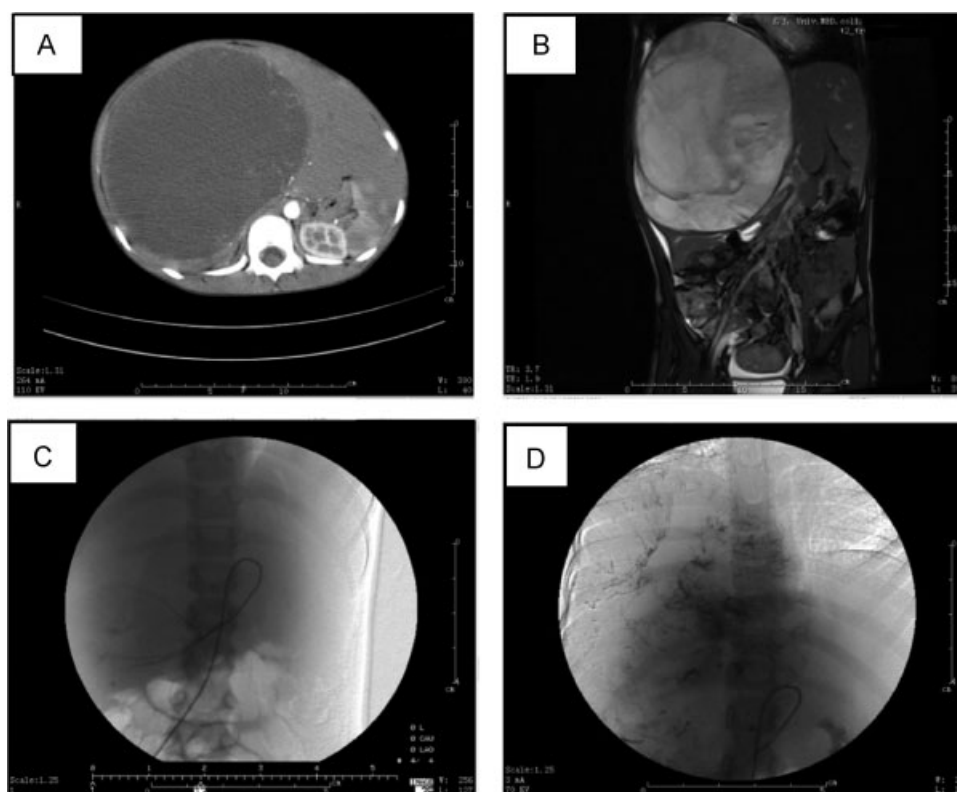


Fig. 1 (A and B) CT and MRI scans of case 1 show an unresectable mass in the liver. (C) Digital subtraction angiography displays the tumor's blood supply of "holding ball." (D) The feeding artery of the tumor was embolized. CT, computed tomography; MRI, magnetic resonance imaging.

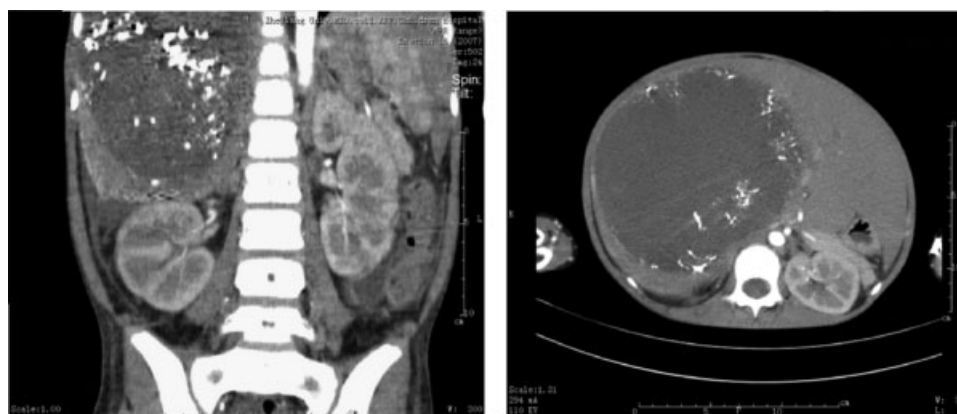

Fig. 2 The tumor shank 4 weeks after TACE of case 1. TACE, transarterial chemoembolization.

transient liver dysfunction including the rise of ALT (63 U/L) for 1 week, without cardiac, leukocytopenia, or renal dysfunction, and these symptoms showed dramatic improvement after symptomatic treatment. Four weeks after TACE, abdominal ultrasonography and CT scan showed that the tumor volume decreased by 31% and the blood flow of the tumor was clearly lower than before treatment (→Fig. 2).

Surgical resection with right hepatectomy was performed 8 weeks after TACE when the tumor volume appeared to be sufficiently reduced to allow safe resection using extended lobectomy. The gross findings showed well-demarcated nodular masses covered by an incomplete capsule well defined from the surrounding normal parenchyma. The cut surface was soft and variegated, with white gelatinous areas and foci of tumor necrosis and hemorrhage (→Fig. 3A). The cellular component was composed of medium to large spindle or stellate cells with marked nuclear pleomorphism or multinucleate forms.³ (→Fig. 3B). The cell borders were poorly defined. Pleomorphic multinucleated giant cells were relatively frequent. PAS (Periodic acid-Schiff)-positive, diastase-resistant hyaline globules, which are believed to be lysosomes or apoptotic bodies, were frequently observed within tumor cells and in the extracellular stroma.^{1,4} Tumor necrosis was evident.

Another six courses of regular venous chemotherapy (PLA + DO) were administered beginning 2 weeks after the

surgery. The patient was followed up for 1 year without any complications with CT scan.

Case 2

A 10-year-old girl presented with an abdominal mass on physical examination for the last 24 hours. There was no history of bellyache, jaundice, fever, anorexia, or weight loss. On examination, the child was found to have a large abdominal mass in the right lobe of the liver, with a weight of 34 kg. Serum AFP, liver enzymes, and inflammatory markers were normal. Likewise, abdominal ultrasonography and MRI were used to examine the size and extent of the primary tumor and the involvement of major vessels. TACE was performed after presumptively diagnosing with UELS by ultrasound guided needle biopsy. One week after TACE, the patient had vomiting, fever, and bone marrow depression with a low neutrophil count of $0.68 \times 10^9/L$. After treatment with a leukocyte increasing agent (recombinant human granulocyte colony-stimulating factor), the neutrophil count rapidly increased to normal. Three weeks after TACE, abdominal ultrasonography and MRI scan were used to evaluate the tumor response. The tumor volume decreased by 23% but was still large; one course of venous chemotherapy (PLA 80 mg/m^2 + DO $30 \text{ mg/m}^2 \times 2$) was administered. Two weeks later, right hemihepatectomy was performed. Two weeks after the

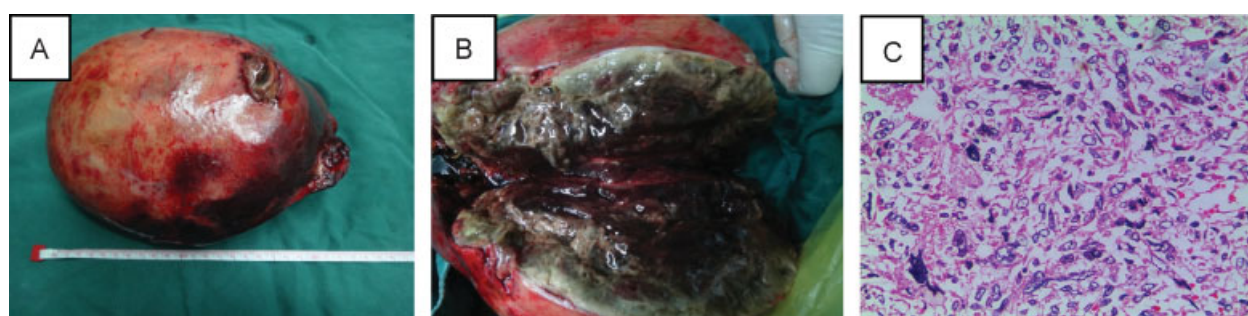


Fig. 3 The pathology of case 1. (A) The gross findings show a well-demarcated nodular mass. (B) The cut surface was soft and variegated, with white gelatinous areas and foci of tumor necrosis and hemorrhage. (C) The cellular component is composed of medium to large spindle or stellate cells with marked nuclear pleomorphism or multinucleate forms.

surgery, six courses of regular venous chemotherapy (PLA + DO) were administered.

The girl was followed up for 9 years without any events. Abdominal ultrasonography or CT scan was performed every 2 months during year 1, every 4 months during year 2, and every 6 months during year 3 of follow-up. The patient was considered successfully treated after 5 years of tumor-free follow-up from the end of treatment. No evidence of recurrence or metastases was found.

Discussion

The prognosis of UELS has been known to rely on whether surgical resection can be achieved, but total resection of the tumor at the time of initial diagnosis is often difficult. However, despite apparent complete resectability in some cases, local recurrence and distant metastases have been major impediments to achieving long-term disease-free survival.⁵ Although chemotherapy is the mainstay of treatment for UELS, its toxicity if given systemically is high may result in early death.^{6,7} In the late 1970s, TACE was first introduced for the treatment of adult primary liver tumors, and its results was reported to be more effective than those obtained by other nonsurgical treatment modalities such as systemic or regional chemotherapy.^{8,9}

TACE was introduced for the treatment of HCC and hepatoblastoma in adults and children and recently, several large reports of patients have shown favorable results.^{10–12} TACE has proven to be a valuable treatment modality for the following reasons: first, embolization increases the dwell time of the chemotherapeutic agent and second, by occlusion of the blood supply to the tumor, ischemia ensues, followed by hypoxic tissue damage to the tumor. Furthermore, lipiodol is effective as an emulsion agent in chemoembolization when mixed with chemotherapeutic agents because it is selectively absorbed and retained by emulsification and pinocytosis in hepatic tumor cells.¹³ Li et al demonstrated that adult UELS who underwent interventional therapy and surgical resection exhibited a prolonged survival compared with patients who underwent surgical resection only.⁷ However, the use of TACE in children with UELS is somewhat limited. There are no other serious adverse effects, such as liver dysfunction, renal function failure, cardiac damage, and myelosuppression. Thus, TACE may be considered as a safe preoperative treatment asset to systemic chemotherapy, particularly for patients without distant metastasis.

Conclusions

Although this is only a report of two cases, we were impressed by the dramatic reductions in tumor size achieved with TACE. The treatment of UELS with preoperative TACE may not only increase the frequency of complete resection but may decrease the operative morbidity. As in both cases, one case

of CT scan was given shortly after the TACE and before re-evaluation of tumor size. Therefore, we cannot be sure whether this effect was due to TACE or the chemotherapy or a combination of both. In conclusion, preoperative TACE might be considered to be an effective, feasible, and safe treatment in lieu of systemic chemotherapy for inducing tumor shrinkage in pediatric patients with or without surgically resectable tumors or metastases. Usually, 5-year-event-free survival is something the oncologic surgeon refers to. In patient No. 1, the follow-up of 1 year is rather short to conclude on efficacy of this method. Further experience and pediatric studies on TACE are necessary before any recommendations for its application as a first-line therapy can be made.

References

- 1 Stocker JT, Ishak KG. Undifferentiated (embryonal) sarcoma of the liver: report of 31 cases. *Cancer* 1978;42(1):336–348
- 2 Wu KT, Wang CC, Lu LG, et al. Hepatocellular carcinoma: clinical study of long-term survival and choice of treatment modalities. *World J Gastroenterol* 2013;19(23):3649–3657
- 3 Wei ZG, Tang LF, Chen ZM, Tang HF, Li MJ. Childhood undifferentiated embryonal liver sarcoma: clinical features and immunohistochemistry analysis. *J Pediatr Surg* 2008;43(10):1912–1919
- 4 Gao J, Fei L, Li S, et al. Undifferentiated embryonal sarcoma of the liver in a child: A case report and review of the literature. *Oncol Lett* 2013;5(3):739–742
- 5 Newman KD, Schisgall R, Reaman G, Guzzetta PC. Malignant mesenchymoma of the liver in children. *J Pediatr Surg* 1989;24(8):781–783
- 6 Baron PW, Majlessipour F, Bedros AA, et al. Undifferentiated embryonal sarcoma of the liver successfully treated with chemotherapy and liver resection. *J Gastrointest Surg* 2007;11(1):73–75
- 7 Li XW, Gong SJ, Song WH, et al. Undifferentiated liver embryonal sarcoma in adults: a report of four cases and literature review. *World J Gastroenterol* 2010;16(37):4725–4732
- 8 Wheeler PG, Melia W, Dubbins P, et al. Non-operative arterial embolisation in primary liver tumours. *BMJ* 1979;2(6184):242–244
- 9 Yamada R, Sato M, Kawabata M, Nakatsuka H, Nakamura K, Takashima S. Hepatic artery embolization in 120 patients with unresectable hepatoma. *Radiology* 1983;148(2):397–401
- 10 Malagari K, Pomoni M, Spyridopoulos TN, et al. Safety profile of sequential transcatheter chemoembolization with DC Bead™: results of 237 hepatocellular carcinoma (HCC) patients. *Cardiovasc Intervent Radiol* 2011;34(4):774–785
- 11 Ohtsuka Y, Matsunaga T, Yoshida H, Kouchi K, Okada T, Ohnuma N. Optimal strategy of preoperative transcatheter arterial chemoembolization for hepatoblastoma. *Surg Today* 2004;34(2):127–133
- 12 Wang S, Yang C, Zhang J, et al. First experience of high-intensity focused ultrasound combined with transcatheter arterial embolization as local control for hepatoblastoma. *Hepatology* 2014;59(1):170–177
- 13 Chou FI, Fang KC, Chung C, et al. Lipiodol uptake and retention by human hepatoma cells. *Nucl Med Biol* 1995;22(3):379–386