

Facelift 2015

Chiara Botti, MD¹ Giovanni Botti, MD¹

¹ Villa Bella Clinic, Salò, Italy

Facial Plast Surg 2015;31:491–503.

Address for correspondence Giovanni Botti, MD, Villa Bella Clinic, Viale Europa 55, Salò 25087, Italy (e-mail: botti@villabella.it).

Abstract

Among the current topics, one that is more commonly discussed is that of the mini-invasive or “soft” techniques that seem to attract doctors and patients more than real surgery. We instead propose a relatively aggressive technique that can really rejuvenate the faces and necks of our patients. Are we not in step with the times? The problem is, unfortunately, that until now there is nothing that, without anesthesia, swelling, bruising, and so forth, can magically bring about the result of a well-done facelift. There are no “thread lifts” or fillings or endopeels or weird devices using radiofrequency, ultrasound, or shock waves—the list could go on forever—that can compare with a properly performed facelift. But how should a good facelift be done? For many years, we have been using the protocol described in this article, and the request for facelifts has not dropped, despite never having used advertising in our practice. We want to give our patients natural and long-lasting results, and for this purpose we must use an effective and individualized technique, even if it implies a relatively long down time. In this article, we describe the technical choices that we have made based on a long clinical experience and on detailed anatomical studies. Most difficulties that are encountered with this type of surgery concern finding the proper dissection plane and the proper amount of traction to be applied to the different tissue layers. It is indeed not at all easy, especially for a beginner, to be sure that one has reached the proper depth of dissection, which will allow the elevation of the superficial musculo-aponeurotic system (SMAS) in a risk-free manner even in the area which is medial to the anterior border of the parotid gland where the facial nerve is no longer protected by the gland itself. We will nevertheless try to provide precise indications concerning every important detail needed to perform the operation safely.

Keywords

- ▶ effective facelift
- ▶ deep plane
- ▶ embriation
- ▶ stable fixation
- ▶ natural results
- ▶ long-lasting results

Why Deep Plane?

To immediately improve the appearance of an aging and sagging face, it is enough to pull back the soft tissues with a fingertip applied to the cheek. Starting from this simple observation, more than a century ago, the operation called *facelift* was conceived, which, in short, consisted in fact of repositioning the ptotic soft tissues into their original position.^{1–14} Many techniques have been proposed and re-proposed since then (▶ **Fig. 1**). Initially, this was limited to the removal of a segment of skin, more or less extended around the ear, closing the wound with sutures. Then, a wider subcutaneous undermining was introduced, complemented

by plication of the underlying adipose tissues. These sutures were proposed both as single sutures, running sutures, or “purse string” sutures. Much time passed before a deeper plane of undermining was considered. The anatomy of the superficial musculo-aponeurotic system (SMAS)—an acronym proposed by Tessier as it would be the same in French as it was in English—had already been described in detail decades ago by the Italian Sterzi,¹⁵ and a study on it was later published in *Plastic and Reconstructive Surgery* (PRS) by Mitz and Peyronie,¹⁶ working under the supervision of Tessier. On the basis of this anatomical framework, the French school introduced a somewhat timid sub-SMAS undermining,

Issue Theme The Facial Profile; Guest Editors, Werner J. Heptt, MD, and Stefan Zachow, PhD

Copyright © 2015 by Thieme Medical Publishers, Inc., 333 Seventh Avenue, New York, NY 10001, USA.
Tel: +1(212) 584-4662.

DOI <http://dx.doi.org/10.1055/s-0035-1566270>.
ISSN 0736-6825.

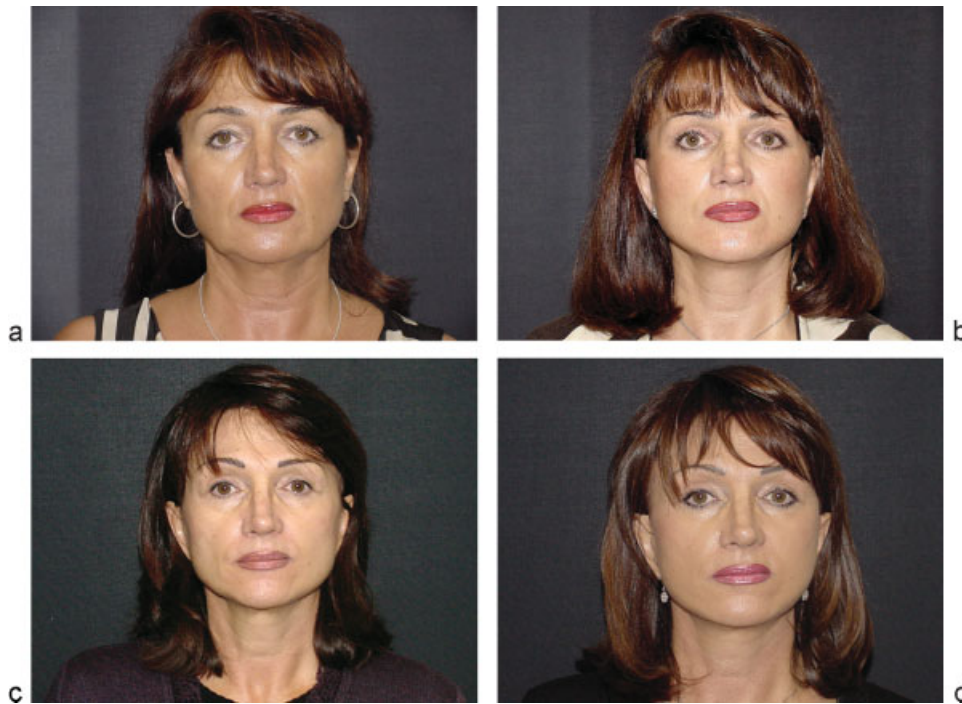

Fig. 1 Deep plane facelift: long-term result. (a) preoperative (52 years old), (b) 9 months later, (c) 10 years later without any further surgery, (d) the same patient at the age of 63, after a secondary facelift. A complete repositioning of the sagging soft tissues coupled with a strong anchoring to solid points of fixation allows to obtain a natural and long-lasting result. One cannot stop the aging process, but often, even 10 years after the operation, jowls and bands are still less evident than before the operation.

mainly limited to the area above the parotid gland. However, it was without doubt Skoog was the first to demonstrate an extended deep-plane dissection. What had Skoog¹⁷ intuited before everybody else? The great Swedish plastic surgeon understood that to obtain a true correction of the ptotic soft tissues of the face and neck, it would be necessary to first elevate them all together following a deep plane of dissection and then move them back into their original position. After that, the door was open, not just simple lateral traction, but liberation of all deep adhesences and cephalad repositioning of fascia, platysma muscle, fat, and skin. In the following years, the deep plane technique was further elaborated and currently, in the form that we use, calls for a precise dissection of a composite flap (skin, fat, SMAS) as proposed by Bonnefon,¹⁸ while absolutely respecting the “noble” structures (vessels and motor nerves), and a robust anchorage to firm structures, so as to obtain a stable repositioning.^{19–26} We have participated in innumerable round tables in which often expert colleagues stated that they had gone from imbrication (dissection and elevation) to plication (direct fascial suture without undermining) obtaining the same results and to have therefore chosen the simpler method. We have had the occasion to follow in various cases this “evolution,” but we realized that what was being called “imbrication” had actually nothing to do with the technique that we had been proposing for many years. In their idea, imbrication consisted, in the best case, of a simple (and scarcely effective) undermining of a small flap of SMAS above the parotid gland with anchoring to the same fascial tissue. We are therefore not

surprised that they did not notice any difference between this imbrication and SMAS plication.

Why the Dissection of an Ample Composite Flap with Anchorage to Deep Fixed and Robust Tissues?

We prefer this technique, indubitably more complex, not only because it makes it possible to obtain more natural and long-lasting results but also because we can restore normal anatomy, respecting each tissue, which is repositioned in its original place, after having its dimensions being suitably restored. Contrary to plication, which in fact involves the suture of the SMAS to itself (a thing that also happens in the so-called SMASectomy²⁷), in the procedure which will be described in detail later, the anatomy of the superficial soft tissue is not altered but rather restored. No overlapping of fat in improper position with a triple layer stacking occurs, but a return to normal anatomy after having removed the excess of SMAS and fat, thereby obtaining a good three-dimensional remodeling. The anchorage to solid and immobile tissues (mastoid periosteum, Lore fascia or platysma-auricular ligament,²⁸ periosteum of the posterior third of the zygomatic arch, and the deep temporal fascia) allows a stable repositioning of the deep ptotic tissues. This will provide not only a long-lasting effect but also a release of all tension along the cutaneous margins with the likelihood of an optimal scar. The movement of the mandible, which has its widest extension in the anterior portion of the face, does not interfere with the

stability of the fixation, also because the medial portion of the SMAS is rather elastic. We resort to plication only in the rare cases where the musculo-fascial and adipose tissues are sparsely present, and/or excessively thin and therefore not very substantial. In these cases, in fact, not only is it preferable to avoid making a too delicate and fragile flap, the anchoring of which would be precarious, but it can also be convenient to increase the projection of the malar area.

Inflate or Elevate?

There is no doubt that aging involves phenomena of cutaneous degeneration, consisting mainly of skin thinning and cutaneous elastosis, with progressive reduction of elastic and collagen fibers. In other words, the skin loses its original thickness and above all it increases its extensibility, and the skin therefore becomes excessive in respect to the surface that it has to cover. At the same time, however, the underlying adipose tissue and even the bony support are undergoing progressive atrophy. If, on the one hand, we observe a natural skin expansion (the container enlarges), we see a gradual loss of fat and bone thickness (the content reduces) on the other hand. The evolution of this disparity between content and container determines the noticeable changes in the appearance of the face, which in fact with aging becomes deformed. The superolateral portion of the cheek tends to flatten, while the anterior portion thickens, giving the face a new form, changing from triangular to square. The imbalance between excess skin and reduced osteo-adipose thickness allows for the subcutaneous fat, driven by the force of gravity, to descend along an inferomedial vector. Once having reached the level of the nasolabial and labiomandibular adherences, which prevent the fat from moving even more inferiorly, the fat remains above the groove that forms the characteristic folds that next to the chin are called *jowls*. Therefore, taking into account that the basis of facial relaxation is the double mechanism of skin dilatation and osteo-adipose atrophy, beside uplifting the soft tissues en bloc, and trimming the excess, in the majority of cases we believe that it is proper to restore the correct volumes in the different areas. In practice,

the excessive thickness of the perioral areas is reduced by repositioning the SMAS, fat, and skin that partially is returned to fill in the upper lateral part of the face (– Fig. 2). But, to obtain a more complete and natural result, it is often necessary to graft fat where there is more atrophy. Usually, fat is injected into the zygomatic and periorbital areas, in particular, into the palpebral-jugal groove, at the level of the labio-mandibular groove, and at times into the lips. In some cases, it is used to give projection to the gonial angle and to the chin. The problem yet to be solved in lipofilling concerns the take-rate of the fat. We have used all the techniques that have been described up until now, comparing all those considered to be the most effective,²⁹ and we have used cannulas of various types and size, with both large and small holes; we have harvested the fat from different areas of the body, and we have tried to avoid the use of local anesthetic solutions and vasoconstrictors. In the final analysis, the take has not been shown to be 100% certain with any technique, instrumentation, or trick. We have only noticed a potentially better take-rate in the periorbital and zygomatic areas, while in our experience in general, fat provides short-lasting results in the lips, along the nasolabial grooves, and into the temporal area. In spite of this, in our opinion, it is worth trying to inject fat when thought to be indicated: if it takes, good, if not, you can always try again, or give up. It must be noted that within a few months after the operation, often the skin appears to have a better quality, even if it is difficult to state with certainty that this phenomenon is actually due to the stem cells contained in the fat, rather than to the fibroblastic stimulus linked to the undermining.

Facelifting: Technical Details

For more than 15 years, we have standardized our facelift technique, which includes some fundamental steps, common to all cases, together with subjective variations relative to each specific deformity to be treated, as well as to the sex and age of the patient. The preoperative examination makes it possible to give the patient correct and precise information concerning surgical techniques and possible

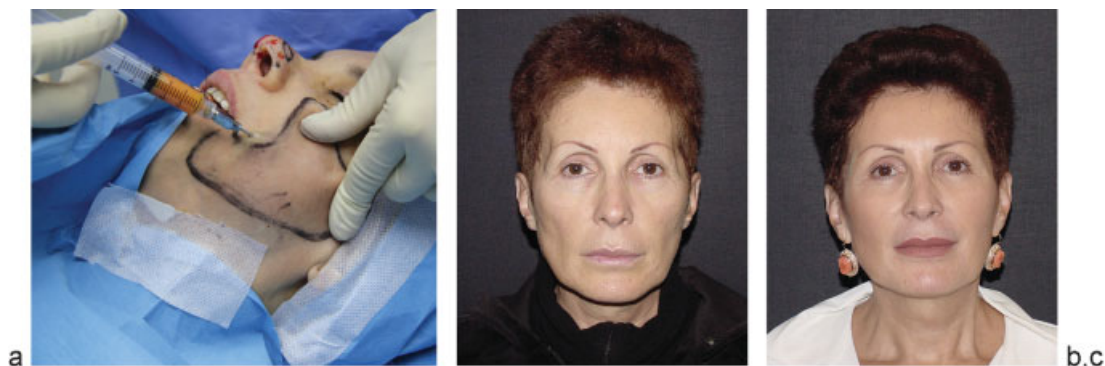


Fig. 2 Cheek and temple fat grafting. (a) Fat is injected in the cheek. (b) Preoperative, (c) 2 years postoperative. Within the correct indications, pure fat grafting can give satisfactory results. It is not advisable, though, just to resort to fat filling alone, when soft-tissue lifting would also be indicated.

complications, besides deciding upon any variations in approach. It needs to be decided, together with the patient, if the operation is to be limited to the lower part of the cheeks and neck, or if it must be extended to the mid-face and temporofrontal areas. One also needs to choose if it is necessary to perform a concomitant dermabrasion to correct wrinkles and skin blemishes, a blepharoplasty (with canthopexy when required), for eyelid problems, a regional lifting (upper lip or eyebrows), or other procedures which help obtain a more harmonious and complete result. Among the latter, a main role is played by those techniques which are aimed at restoring lost volumes due to osteo-adipose atrophy. In fact, in ~80% of our patients we couple facelifting with fat grafting, while in ~10% of them we use facial implants, mainly for the chin and zygoma. Quite frequently, we also use liposuction when there is a fat excess, particularly in the cervical area (►Figs. 3 and 4).

Anesthesia

We prefer to carry out this operation under general anesthesia, with infiltration of very dilute local anesthetic and vasoconstrictor solution. General anesthesia, using propofol, remifentanyl, curare, and assisted respiration with orotracheal intubation, is given after having marked the incisions and taken appropriate measures to get the hair out of the surgical field. The anesthesiologist is expected to keep systolic arterial pressure between 75 and 95 mm Hg throughout the whole procedure. The pressure will need to remain under control even during the delicate moment of extubation, when it might elevate and for the same reason one must use every possible means to avoid vomiting. Having put the patient under general anesthesia, and prepared the surgical field, one proceeds with the local anesthetic infiltration. On average, 120 mL of mepivacaine 0.2% with adrenaline 1:500,000 are

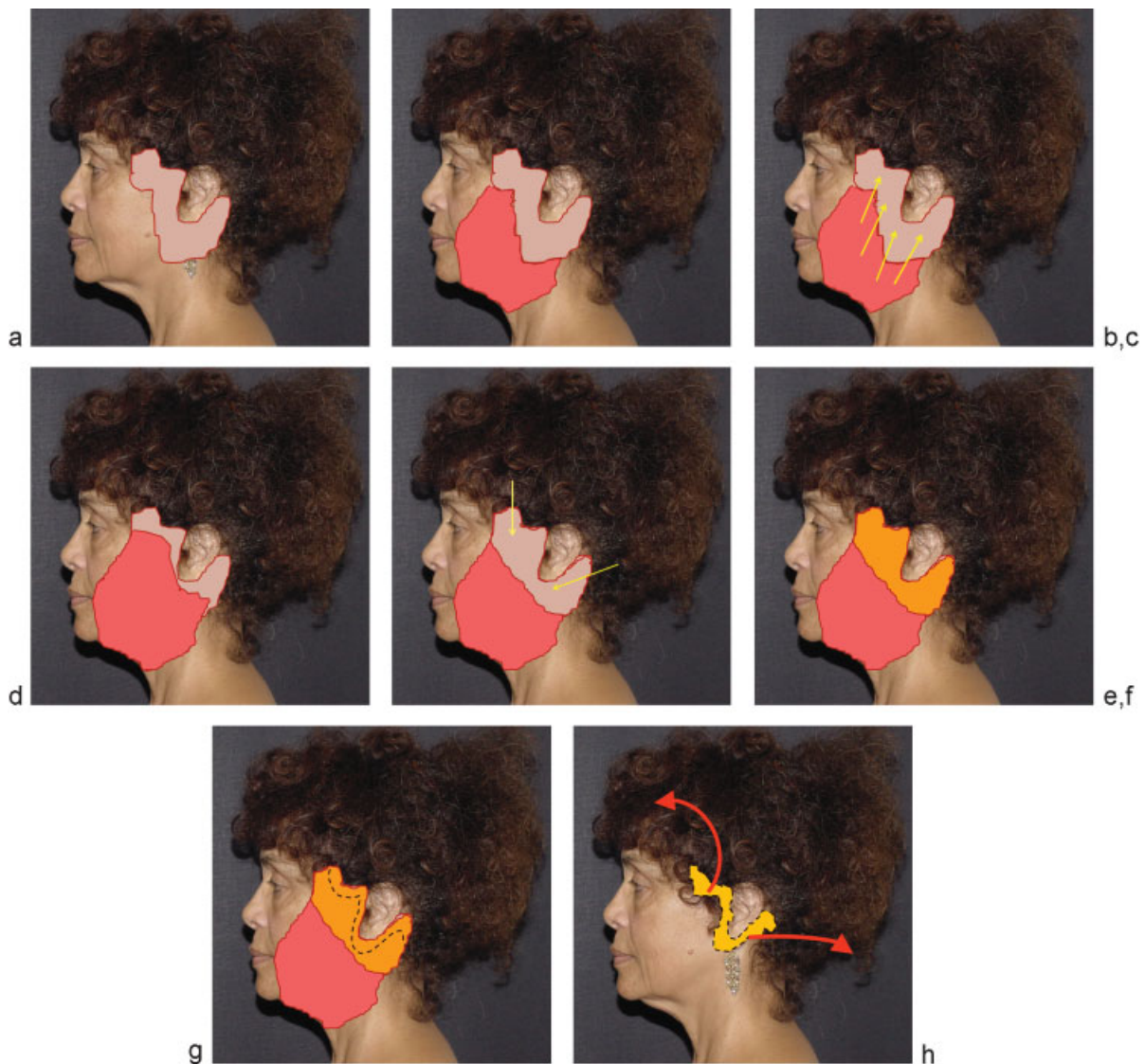


Fig. 3 Deep plane facelift. (a and b) Short subcutaneous dissection and large sub-SMAS undermining. (c and d) SMAS lifting and fixation. (e and f) fibrin glue is applied. (g and h) The extra skin is removed.

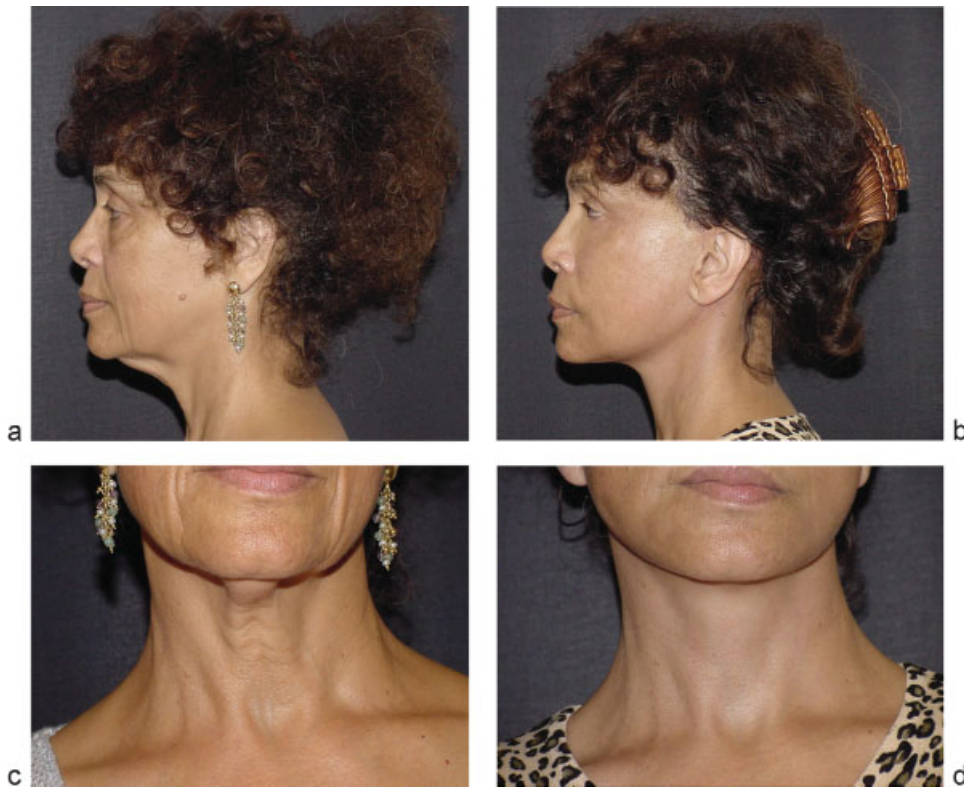

Fig. 4 The result of the case illustrated in the previous pictures. (a and c) preoperative; (b and d) 6 months postoperative. This technique is quite effective and reliable. It gives constantly predictable and complete results.

used per side. The slight tumescence obtained with the injection of this very dilute cocktail of anesthetic and vasoconstrictor facilitates the dissection.

Incisions

When it is necessary to correct defects located predominately in the lower part of the cheek and the neck, the incision can be started directly in the lower portion of the sideburn, then extend caudally into the preauricular area. On the other hand, if problems of the temporal and midface areas are to be treated, it is usually preferable to extend the incision into the temporal area. When the distance between the orbital rim and the hairline is short (< 4 cm), an incision into the scalp can be made, parallel to the hairline and approximately 3 cm from it. At its most cephalad extremity, this incision curves slightly in an inferomedial direction to avoid dog ears. If on the other hand, the distance between orbital rim and hairline is longer (> 4 cm), it is best to make the incision along the hairline to avoid cephalad displacement. In the latter case, the scalpel blade must be sharply beveled so that the hair, when it grows back, will cross the scar and camouflage it. This type of incision follows the hairline in a zig-zag fashion. In front of the anterior border of the ear, one can choose between a pretragal incision, which we prefer for men, and a post-tragal one, which is better in women. At the level of the lower border of the tragus, it is best to break the incision line with an angle or a short perpendicular cut, to preserve the incisura intertragica. One then proceeds inferiorly, around the earlobe, and

then upward into the retroauricular sulcus, until the hairline is reached, which is then followed for a few centimeters, toward the occipital area (► Fig. 5).

Subcutaneous Undermining

The dissection is initially subcutaneous and usually becomes sub-SMAS only in the cheek and the anterior portion of the neck. One normally starts from the mastoid area in which the subcutaneous dissection plane is the only possible one, extending caudally until ~2 cm below the posterior projection of the gonial angle. Then, one proceeds with a limited dissection in the same plane also in front of the ear. In this area, the dissection is extended ~3 cm from the skin incision, except from the part above the zygomatic arch, in which it reaches the orbital rim. If a temporal lift is required, if the incision is prefollicular, the undermining in the temporal area is subcutaneous, while when the incision is in the scalp, the undermining to the hairline is subfascial (beneath the superficial temporal fascia), and from then it extends caudally in the subcutaneous plane. The subcutaneous dissection in the cheek must be performed rather superficially to leave a large portion of the fat on the underlying SMAS.

Sub-SMAS Undermining

Before starting a sub-SMAS undermining, it is very important to identify the correct level of depth in which to work. To accomplish this, it is good, at least the first times, to incise the

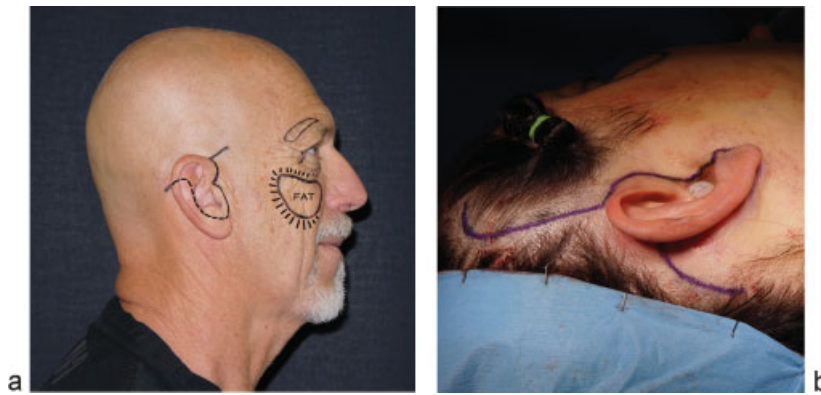


Fig. 5 Most used skin incisions. (a) Short periauricular incision, running pre-tragal along a natural groove with a quite limited mastoid extension. (b) Retro-tragal incision with the usual temporal and occipital extensions.

SMAS over the parotid gland, in order that the branches of the facial nerve remain totally protected from harm and that the various tissue planes be easily recognizable. It is useful to begin the process elevating the musculofascial tissue with tissue forceps ~ 2 cm in front of the earlobe. After having verified the mobility of the flap that is being held, behind where the tip of the forceps is placed, make a short incision. If the parotid gland becomes exposed, that means that the plane is too deep and therefore the dissection from then on should be performed more superficially (~ 0.2 mm, a hair's breadth), so as to be above the capsule of the gland. As the undermining is extended anteroinferiorly, it will be easy to identify the muscle fibers of the cervical platysma that are cranially in continuity with the fascial tissue of the cheek. Once the incision has been made, the Trepsat dissecting forceps (which have blunt paddles at their tips) are inserted. By using this instrument, the sub-platysmal undermining is performed, first in the neck, and then in the cheek. Great attention must be paid not to damage any of the branches of the facial nerve. In the neck, the cervical branches of the platysma become superficial at the level of its middle third, and it is therefore important to use even more caution in the anterior dissection. In the cheek, in front of the anterior border of the parotid gland, the branches of the facial nerve are protected only by the thin parotid-masseteric fascia, and it is fundamental that the dissection be performed in the correct plane between this deep fascia and the SMAS. As concerns the facial nerve in particular, the riskiest areas in the deep dissection are two. One is along the mandible at the level of the anterior border of the masseter where the marginal mandibular branch becomes superficial, often passing above the facial vessels. The other area is at the level of the middle third of the zygomatic arch, where the temporofrontal branches lose the protection of the parotid gland, and pass through the superficial temporal fascia above the zygomatic arch itself. As concerns the marginal branch, it is useful to join the two dissections—the cervical and the cheek—with prudence in front of the masseter, along the mandibular body. This should be carefully done and with visual verification in order not to damage the nerve. The temporofrontal branches are still deep at the level of the zygomatic arch, and are

adherent to the periosteum, before becoming more superficial in the temporal area. Consequently, if you extend the deep dissection cranially, to avoid harming these branches, it is sufficient to grasp with your forceps and elevate the SMAS. If one chooses the so-called high SMAS technique, it can be even safer to make the incision over the anterior third of the zygomatic arch, in front of the usual course of the temporo-frontal branches. The SMAS, including the superficial fascia in the cheek and the platysmal muscle in the neck, must be elevated until it is necessary to correct the defect (**Fig. 6**). We noticed that, to obtain a natural and long-lasting result, it is almost always good to extend the undermining until the area where the problem we wish to eliminate is located. For instance, if you wish to remove an anterior platysmal band on long term, it is necessary to carry the cervical sub-SMAS dissection all the way to the midline. In such cases, the deep undermining of one side will join with deep dissection on the other side. In the same way, when it is necessary to correct heavy jowls, the deep dissection should be extended until the mandibular ligament, which is found immediately anterior to the jowls.

Treatment of Platysmal Bands

A wide deep plane dissection makes it possible to avoid a direct anterior approach to the medial margins of the platysma in most cases. Although, in those cases where the main problem to be corrected is the presence of very evident platysmal bands, it is often best to consider a submental incision, through which the medial borders of the platysma can be accessed. We prefer to lengthen them with a Z-plasty, thus reducing any relative hypertonicity, so that the muscle can better adapt to the rest of the soft tissue that will be placed under tension. Alternatively, one could use a direct suture, completed by a transverse division of the muscle, or one could even completely remove the platysmal bands. A new and interesting approach has been recently described,⁷ who, inspired by an idea of Gonzales, proposed making a longitudinal section of the platysma along the direction of its fibers, at ~ 5 to 6 cm from its anterior border. A transverse section of the platysma follows to create two small muscle

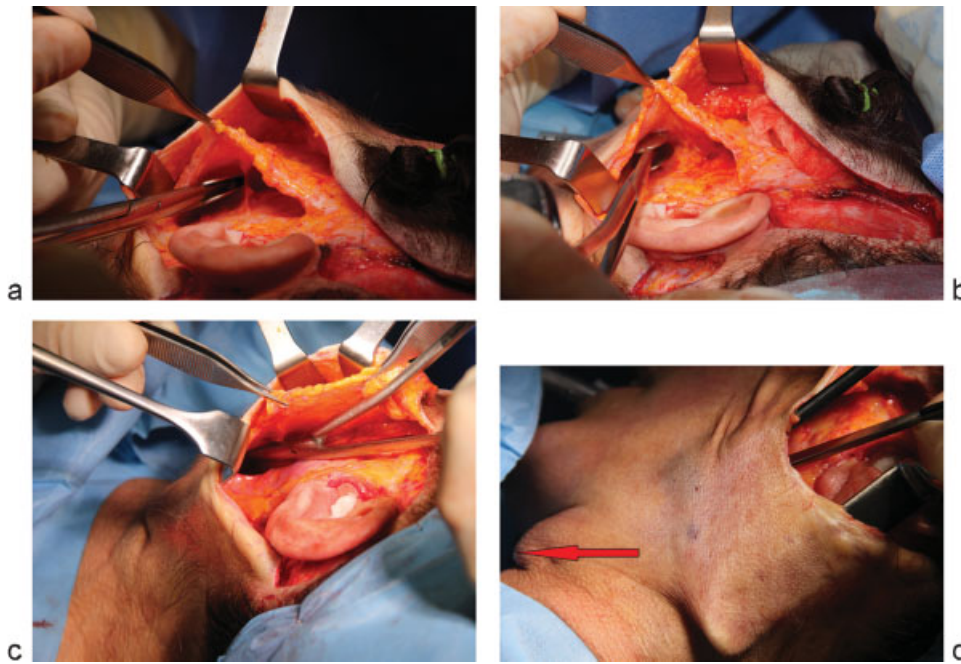


Fig. 6 Sub-SMAS undermining. (a and b) The limited subcutaneous undermining and the more extended sub-SMAS dissection are shown. (c) The sub-SMAS undermining is extended behind the platysma until the midline, as clearly indicated by the red arrow (d).

flaps, which then are put under posterior traction by means of suspender sutures. This change in the anatomy makes it possible to correct the bands.

The Midface Area

We are convinced that when the soft tissues of the midface area are severely ptotic, it is necessary to resort to a vertical lift, undermining subperiosteally, and anchoring the flap, preferably to the bone. Our midface lift technique has recently been described in detail elsewhere.^{30,31} In many of these cases, it is furthermore useful to combine this type of facelift with appropriate lipofilling in the subcutaneous plane. In less severe cases, it can be sufficient to extend a “classical” cervicofacial lift as described earlier to the area below the lower eyelid. It is preferable to at first extend cranially the preauricular cutaneous incision, possibly remaining within the scalp, at ~2 to 3 cm from the hairline (see section “Incisions”). Starting from the temporal incision, one should carry out a deep undermining between the superficial and deep temporal fascia, until the hairline is reached. From then on, the dissection will continue in the subcutaneous plane, as already described, extending as far as the lateral canthus, and the lateral portion of the malar bone. As concerns the sub-SMAS undermining, it will be necessary to carry the facial incision above the anterior portion of the zygomatic arch so as to permit the medial deep undermining between the anterior cheek fat pad and the elevator muscles of the lip (zygomaticus major and minor). Palpating the inferior border of the zygomatic arch, where it thickens to join with the malar bone, the skin is anchored to the periosteum by the zygomatic ligament, which must be released with prudence to avoid damaging the

branch of the facial nerve that runs nearby. Finding the zygomaticus major muscle, which inserts right in front of the ligament, will allow one to slide with the Trepstat forceps toward the nasolabial fold in the correct plane, which will be nothing but the cranial extension of the usual deep dissection in the cheek.

Repositioning, Anchoring, and Trimming the Composite Flap

After having completed the deep undermining, which, as already stated, must be extended enough to correct all of the deformities, the mobility of the composite flap (SMAS, fat, skin) is verified, and, if necessary, a trim of its anterior margin is performed. Then, it is elevated along a superolateral vector, and anchored under appropriate tension to firm anatomical structures (► Fig. 7). It can also be split into two smaller flaps at the level of the gonial angle, so as to pull the caudal flap posteriorly and the cranial flap superiorly. This division with more posterior tension on the caudal flap accentuates the cervical angle, while predominately superior traction (without splitting the flap) is perhaps more effective in correcting the laxity in the inferior portions of the neck. The main anchoring points are four. The first is the periosteum over the mastoid bone; the second is Lore fascia, in front of the earlobe (► Fig. 8). The third is the periosteum over the posterior third of the zygomatic arch; the fourth is the deep temporal fascia (► Fig. 9). The flap can be anchored with absorbable sutures (we use 2-0 Vicryl), because in a short time fibrotic adherence will develop that will provide stability of the repositioning. Other intermediate sutures interposed between the main sutures will complete the

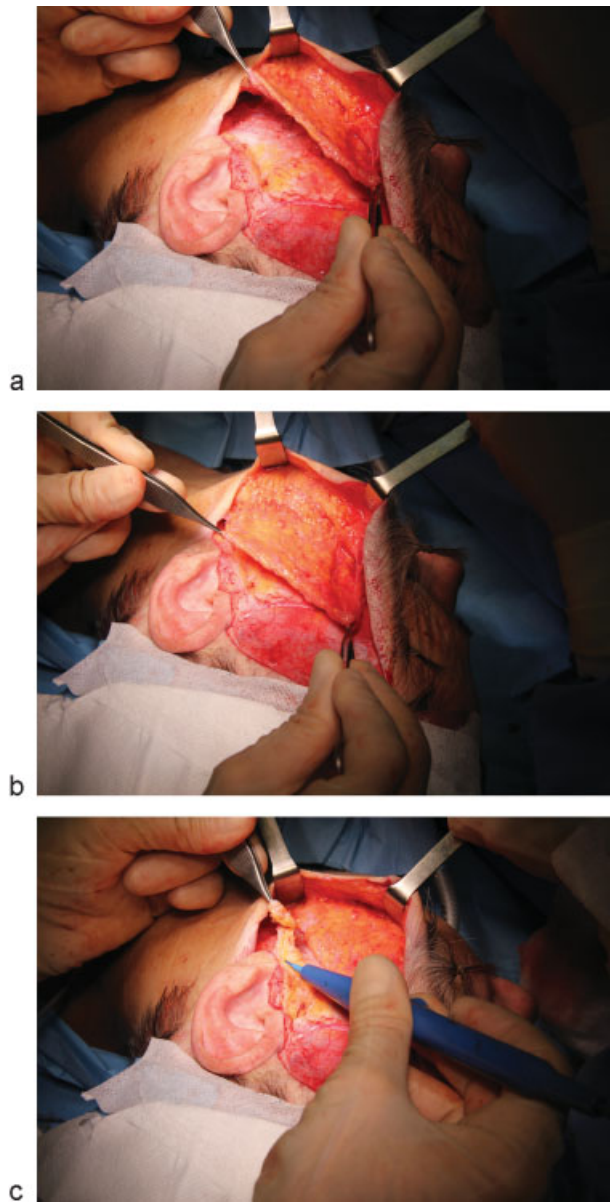


Fig. 7 Lifting the SMAS flap. (a and b) The totally released SMAS flap is elevated and moved upward along a vertical vector. (c) The subcutaneous fat pad is removed in the preauricular area to recreate a natural looking concavity in front of the ear, thus preventing an artificially flat appearance.

SMAS fixation. The excess myofascial tissue can simply be trimmed, or folded over on itself for further augmentation,³² used to reinforce the retroauricular suspension, or to harvest grafts for lips, glabellar furrows, nasolabial folds, or tear troughs, and so on.

Adapting, Trimming, and Suturing the Cutaneous Flap

Once the SMAS flap has been anchored, the skin must simply be laid down over it in its new position. Any incidental irregularities along the margins of the subcutaneous dissec-

tion that will show as little notches or grooves or wrinkles can be eliminated with further scissor dissection. At this stage, the two key sutures are placed, which will help in getting adequate skin redistribution: one in front of the ear, at the height of the superior margin of the concha, and the other behind the ear, where the retroauricular skin incision curves posteriorly. Now, the skin excess, which is partially covering the ear and the temporal and mastoid incision, is trimmed away. The amount to be removed is evaluated with the help of other small incisions perpendicular to the flap margins, reaching the underlying posterior margin of the original cutaneous incision (→ Fig. 9d). Fibrin glue is sprayed over the whole area of the subcutaneous undermining, which is now smaller thanks to the SMAS flap repositioning.^{33–36} The cutaneous margins are sutured with either subcuticular 5–0 Monocryl or Vicryl Rapid. A slightly compressive dressing, preferably made of cotton, and an individualized facial support garment, completes the operation. When fibrin glue is used, drains are not employed. The anesthesiologist will remove the endotracheal tube, trying to avoid coughing, and by all possible means nausea and postoperative vomiting, to prevent sudden increases in blood pressure. For the same reason, the patient will wear a Clonidine patch for 5 days, and the blood pressure will constantly be monitored for at least 24 hours postoperatively. The patient should be kept in a semi-sitting position as well.

Complications

There is no surgical procedure that is without complications, but we should point out that even if facelift is among the procedures most commonly performed at our clinic, it is also among those who have the least number of problems. It probably depends on the fact that we use a strict protocol that allows us to avoid most unforeseen events. That being said, we will briefly examine the complications that can occur, although quite rarely, and try to analyze their treatment. At one point, the most common complication was hematoma, currently occurring in less than 1% of the cases. Prevention is based on a perfect intraoperative hemostasis, and the control of the blood pressure during and after the intervention. It is obviously also important to verify that coagulation parameters are normal before the operation, as well as to avoid taking drugs or foods that might interfere with the coagulation process. The narrow subcutaneous undermining, reducing the dead space, certainly contributes to the limiting of blood collections, as does the use of fibrin glue. As concerns the latter, it is essential that the area of application be perfectly dry, so as to provide better sealing off of the dissected area. Infections are quite rare in this type of surgery, thanks to the excellent blood supply, if the basic rules of asepsis are respected. In the 35 years of experience of the senior author (G.B.), there has not been a single case of infection as a complication of a facelift. Small areas of ischemic necrosis can occur and are not considered to be infectious in nature. These areas, located at the end of the flaps, particularly in the post-auricular region, are more common in smokers, even for some time after they have stopped.

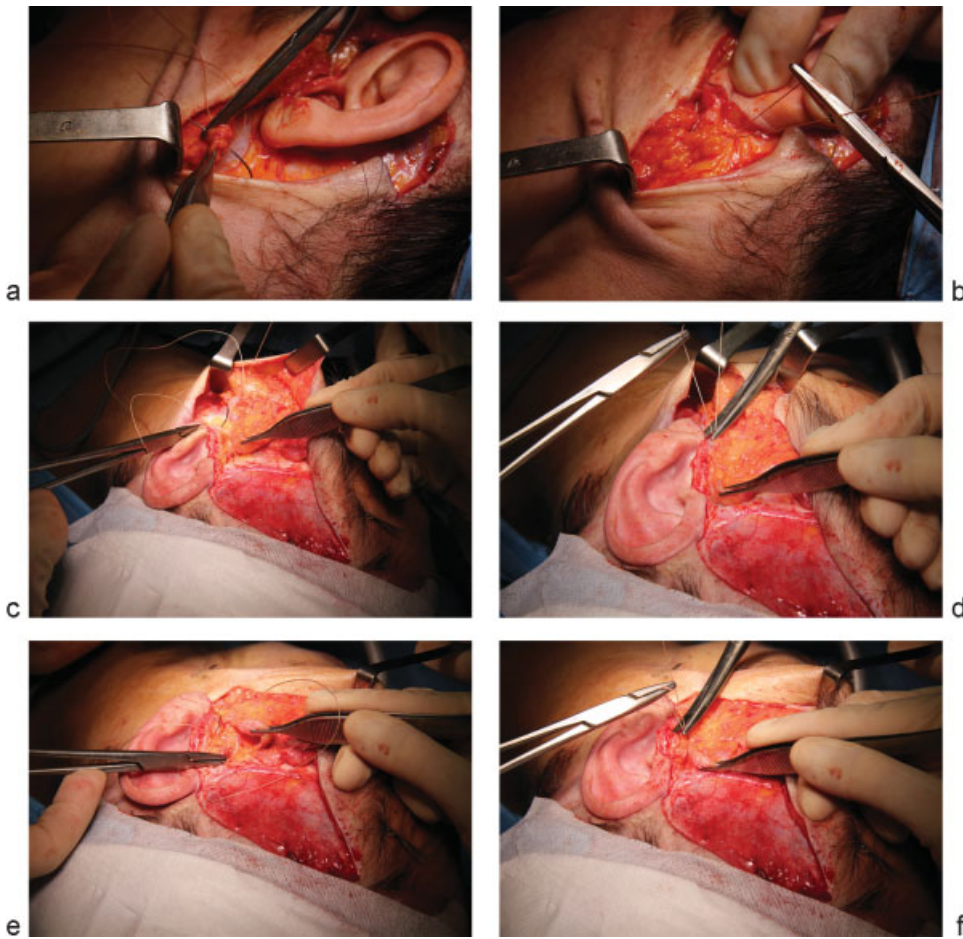


Fig. 8 Anchoring the SMAS flap. (a and b) Platysma flap fixation to the mastoid periosteum. (c and d) SMAS anchoring to Lore fascia. (e and f) SMAS fixation to the periosteum of the posterior third of the zygomatic arch.

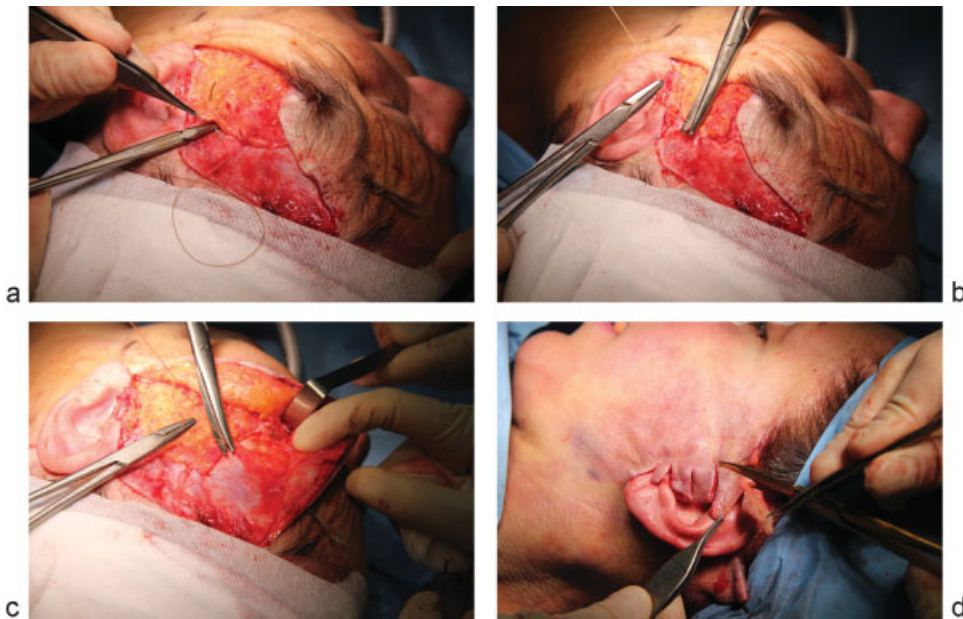


Fig. 9 Completing the SMAS fixation and trimming the skin. (a–c) Suturing the upper part of the SMAS flap to the deep temporal fascia. (d) Careful skin trimming with “fringe” incisions perpendicular to the initial cutaneous flap margin.

Discussion

As was mentioned in the Preface, for more than 15 years we have performed every single facelift according to the protocol described in these pages. We do not feel the need to modify it because the operation thus conceived can offer, in the majority of cases, pleasing, natural, and generally long-lasting results (► **Figs. 10** and **11**). It needs to be emphasized, though, that the durability of the result of any operation of this kind depends a lot on the patients' tissues and age. The younger the patient, the less the degenerative process linked to the passage of time. The older the patient, the more the phenomena reach a full gallop. Therefore, the result of a lifting done at 45 years of age in a person with tissues still in good condition will last much longer than one performed on a 65-year-old. We are convinced that an excellent result in this type of lifting is owing to many factors. In particular, we think it is essential to perform a wide, deep undermining and a fixation to solid stable structures. A major contribution to the success of this

type of approach is also provided by individualization of the procedure, obtained, for instance, by joining the lifting of the sagging tissues with the restoration of volume if necessary with fat grafting or, less frequently, with implants (► **Fig. 12**). At least in 50% of the cases, if the patient wishes, there are also indications to perform a procedure in the palpebral and periorbital areas, such as blepharoplasty, midface lift, eyebrow lift, etc.³⁷⁻³⁹ Furthermore, it is often best to correct dermal-epidermal blemishes by a resurfacing procedures (chemical peel, dermabrasion, or laser treatment). It is always advisable to carry out regular postoperative surveillance for maintenance of the face, with local infiltration of hyaluronic acid and botulinum toxin, which can contribute to refine the results of the operation and keep a fresh appearance of the face for a longer time. We would like to add other considerations concerning the opportunity to use imbrication rather than plication. In our experience, imbrication brings about more natural and long-lasting results than plication. A few years ago, for 6 months we plicated the SMAS on one side and

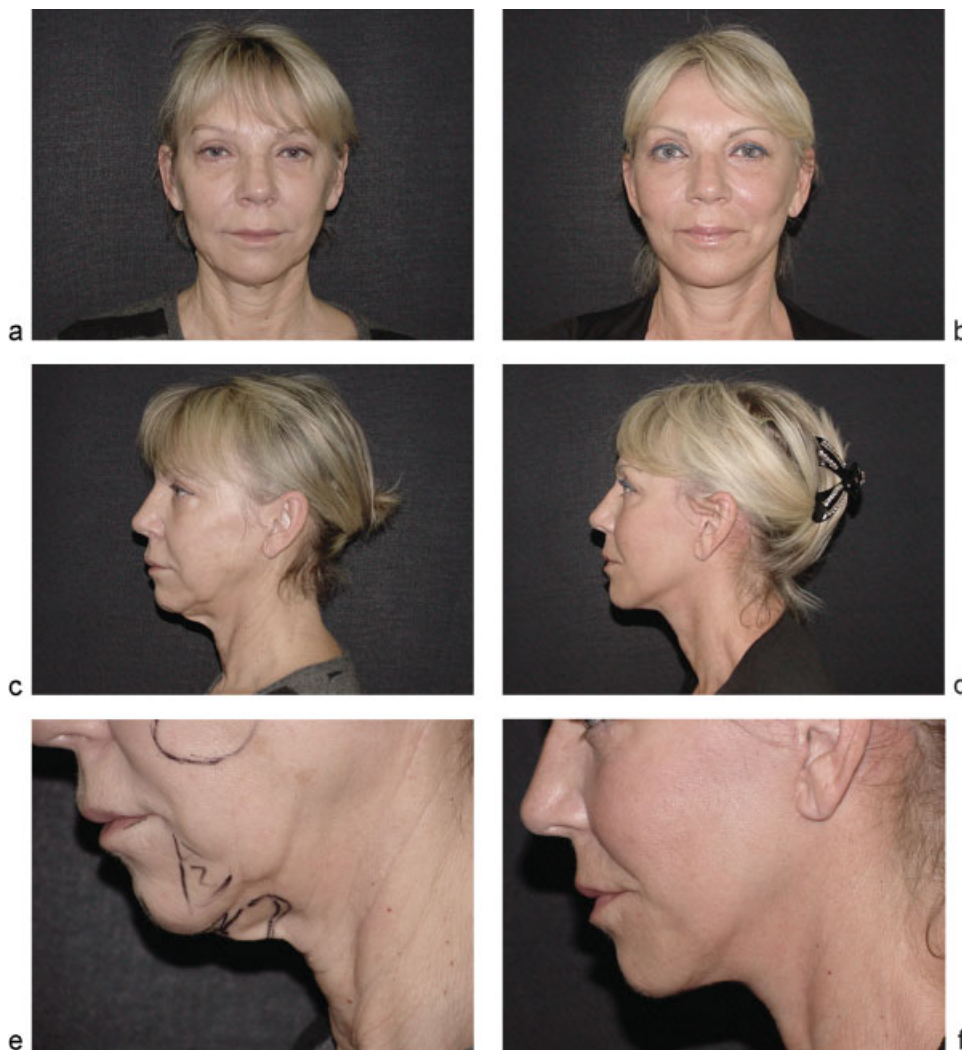

Fig. 10 Facelift and fat graft. (a–c) Before the operation; (d–f) 6 months later. The facelift was performed according to the aforementioned technique. Fat was injected in the malar and pre-jowl areas. Platysma bands were treated by a direct anterior approach, through a submental incision with myorrhaphy and Z-plasty.

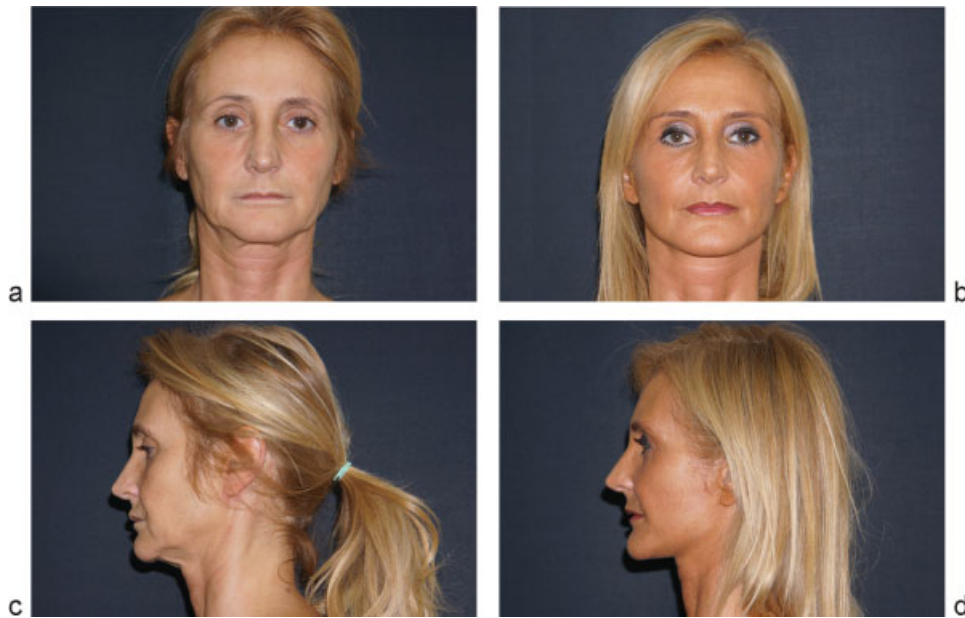

Fig. 11 Facelift and conspicuous “lipofilling.” Before (a and c) and 9 months after (b and d) the operation. In this case, the very skeletonized face required 60 mL of fat grafting to replace the atrophied adipose tissue. Fat was injected in the malar and pre-jowl areas, in the nasolabial and submental grooves, as well as in the upper orbits. No anterior approach to the platysma bands was necessary, due to the lateral position of the muscle medial margins.

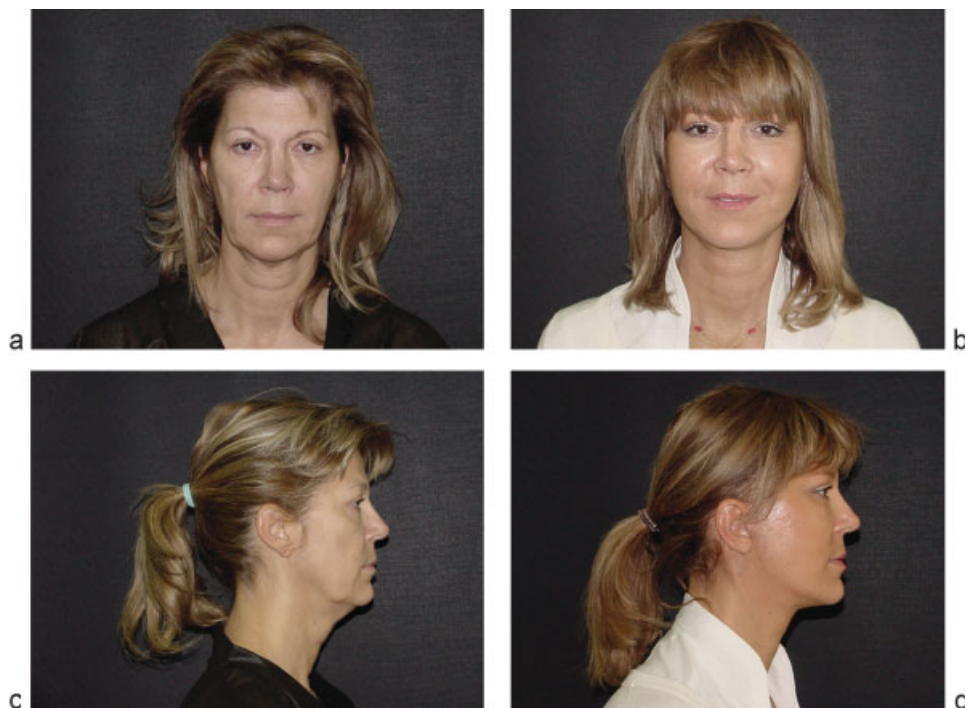

Fig. 12 Facelift, neck liposuction, and fat grafting. (a and c) before the operation; (b and d) 6 months later. This “long” face, with heavy jowls and severe soft-tissue laxity in the neck, was improved by a deep-plane facelift with strong and solid anchorage, coupled with a moderate cervical liposuction and fat grafting in both cheeks.

performed imbrication on the other side. After a few months, we noticed that the imbricated side maintained its new position better (► Fig. 13).

Imbrication does not exert any compression on the adipose tissue that is instead made ischemic by plication. Imbrication

does not stack three layers of tissue as occurs with plication, but partially involves only two. Therefore, imbrication allows the restoration of normal anatomy, without altering it the way plication does. Imbrication, based on a sub-SMAS dissection, allows one to actually see the branches of the facial nerve, which



Fig. 13 Imbrications versus plications. One of the cases from our clinical trial comparing imbrications and plications, before and 1 year later (a and b). On the plicated side (the left), the jowl is already relapsing.

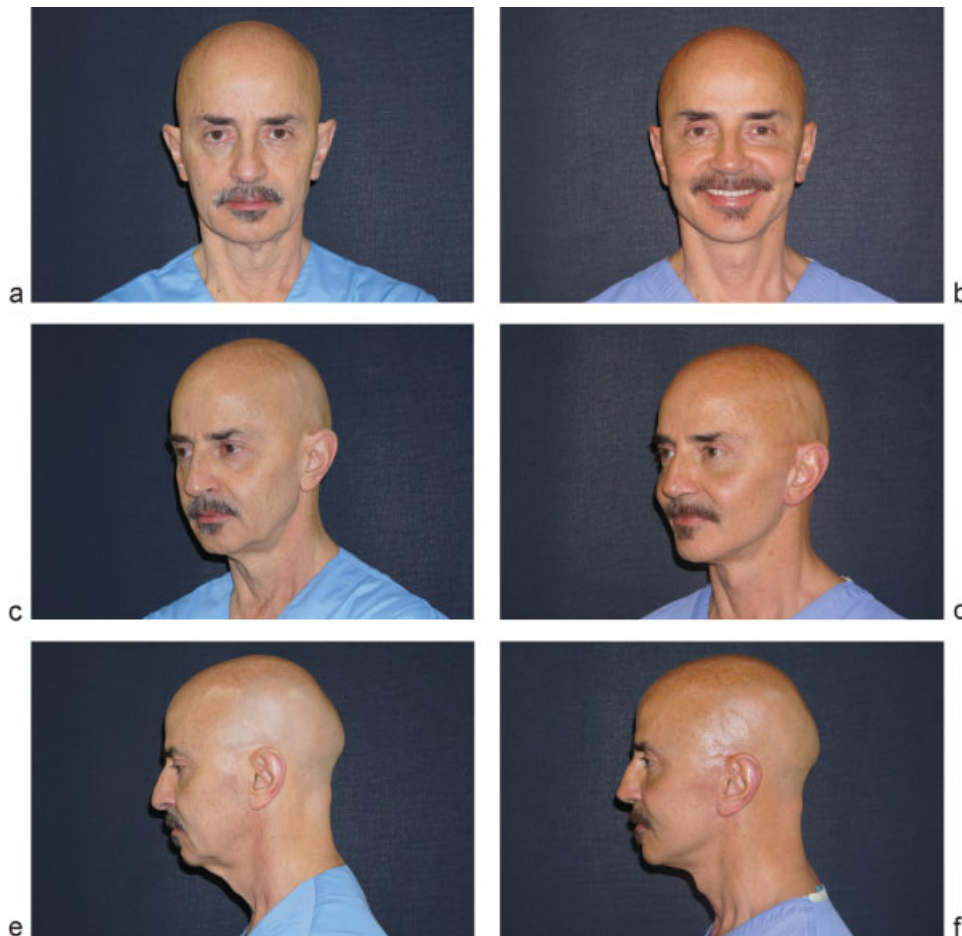


Fig. 14 A very peculiar case. The junior author (G.B.) performed a facelift according to the described technique of the senior author. Nose tip touch up and lipo filling were also associated. These are preoperative (top) and 2 years postoperative (bottom) pictures.

in front of the parotid gland are covered only by the perimysium of the masseter muscle, and thereby to avoid damaging them. On the other hand, plication in front of the parotid gland has a greater risk of involving these branches with the sutures because these are performed blindly. After many years of experience (more than 35 years for the senior author [G.B.]), we are convinced that imbrication can offer more stable and certain results than plication. We use plication only in the rare cases of

very thin patients in which a myofascial flap would be very flimsy, and not very reliable. In those patients, furthermore, the lateral staking of soft tissue may indeed be an advantage.⁴⁰⁻⁴² To move the SMAS flap with imbrication, as we know, it is necessary to first make an incision through the one that can carry out the undermining. For a long time, we made the SMAS incision rather anteriorly (~4 cm in front of the cutaneous incision), and we were convinced that the more the traction was applied near the

defect to be treated, the better the correction. According to the current protocol, however, we went back to making the SMAS incision ~2 cm in front of the skin incision because we prefer avoiding separating the skin from the musculofascial tissue. This way, in fact, we can elevate a composite SMAS-fat-skin flap, which allows one to obtain noticeable improvement even in the anterior parts of the face and neck (–Fig. 14). Furthermore, a more posterior incision makes the anchorage of the flap easier (see section “Repositioning, Anchoring, and Trimming of the Composite Flap”). In fact, we think it is advisable to avoid suturing the SMAS on itself, as done in other techniques, while preferring anchorage to more stable and robust structures. Another controversial technical detail concerns the need of freeing the facial ligaments. We are convinced that it is indispensable to free up the zygomatic ligament if one wants to obtain adequate uplifting of the superior part of the cheek. At the same time, we believe that the masseteric ligament should be released to get adequate mobilization of the central and lower portion of the cheek. In the majority of cases, however, we do not think that it is necessary to disinsert the mandibular ligament, which can often be useful to maintain the soft tissues of the chin region in their proper position. In conclusion, in our opinion, it is possible to offer excellent results to the majority of patients asking for a facelift procedure.

References

- Wu WT. Barbed sutures in facial rejuvenation. *Aesthet Surg J* 2004; 24(6):582–587
- DeLorenzi C. Barbed sutures: rationale and technique. *Aesthet Surg J* 2006;26:223–229
- Paul MD. Complications of barbed sutures. *Aesthetic Plast Surg* 2008;32(1):149
- Sulamanidze MA, Paikidze TG, Sulamanidze GM, Neigel JM. Facial lifting with “APTOS” threads: featherlift. *Otolaryngol Clin North Am* 2005;38(5):1109–1117
- Trévidic P, Alkebaisi A. Facial threads for face lift [in French]. *Rev Laryngol Otol Rhinol (Bord)* 2006;127(1–2):57–59
- Bacci PA. Chirurgia Estetica Mini Invasiva Con Fili Di Sostegno. Collana di Arti, Pensiero e Scienza; 2006; Minelli, Arezzo
- Botti G, Pelle Ceravolo M. Midface and Neck Aesthetic Plastic Surgery. Parma, Italy: Acta Medica Edizioni; 2012
- Botti G. Facelifts and their long term results. *Am J Cosmet Surg* 1999;16:129
- Botti G. Endoscopy in facial rejuvenation. *Plast Reconstr Surg* 1997;99(2):593–595
- Botti G. The future of face lifts: a comparison between traditional surgery and advanced techniques. *Facial Plast Surg* 1996;12(4): 379–387
- Botti G. Chirurgia Estetica dell’Invecchiamento Facciale. Piccin, Padova; 1995
- Botti G, Villedieu R. Lifting: résultats à long terme. *Rev Chir Esthet Lang Fr* 1997;88:21
- Botti G. Transpalpebral lift of the superior and median areas of the face. *Face* 1998;5:119
- Botti G. Lifting: dissezione e riposizionamento dello SMAS pre- parotideo. *Riv Ital Chir Plast* 1992;24:335
- Sterzi G. Il Tessuto Sottocutaneo. Officine grafiche Ferrari, Venezia; 1910
- Mitz V, Peyronie M. The superficial musculo-aponeurotic system (SMAS) in the parotid and cheek area. *Plast Reconstr Surg* 1976; 58(1):80–88
- Skoog TG. Plastic Surgery: New Methods and Refinements. London: Saunders; 1974
- Bonnefon A. The face lift, a light, efficient and long lasting operation [in French]. *Ann Chir Plast Esthet* 2011;56(1):80–88
- Becker FF, Bassichis BA. Deep-plane face-lift vs superficial musculoaponeurotic system plication face-lift: a comparative study. *Arch Facial Plast Surg* 2004;6(1):8–13
- Warren RJ, Aston SJ, Mendelson BC. Face lift. *Plast Reconstr Surg* 2011;128(6):747e–764e
- Stuzin JM, Baker TJ, Gordon HL, Baker TM. Extended SMAS dissection as an approach to midface rejuvenation. *Clin Plast Surg* 1995; 22(2):295–311
- Chang S, Pusic A, Rohrich RJ. A systematic review of comparison of efficacy and complication rates among face-lift techniques. *Plast Reconstr Surg* 2011;127(1):423–433
- Pastorek N, Bustillo A. Deep plane face-lift. *Facial Plast Surg Clin North Am* 2005;13(3):433–449
- Narasimhan K, Stuzin JM, Rohrich RJ. Five-step neck lift: integrating anatomy with clinical practice to optimize results. *Plast Reconstr Surg* 2013;132(2):339–350
- Liu TS, Owsley JQ. Long-term results of face lift surgery: patient photographs compared with patient satisfaction ratings. *Plast Reconstr Surg* 2012;129(1):253–262
- Swanson E. Outcome analysis in 93 facial rejuvenation patients treated with a deep-plane face lift. *Plast Reconstr Surg* 2011; 127(2):823–834
- Baker D. Rhytidectomy with lateral SMASectomy. *Facial Plast Surg* 2000;16(3):209–213
- Labbé D, Franco RG, Nicolas J. Platysma suspension and platysmaplasty during neck lift: Anatomical study and analysis of 30 cases. *Plast Reconstr Surg* 2006;117(6):2001–2007
- Botti G, Pascali M, Botti C, Bodog F, Cervelli V. A clinical trial in facial fat grafting: filtered and washed versus centrifuged fat. *Plast Reconstr Surg* 2011;127(6):2464–2473
- Pascali M, Botti C, Cervelli V, Botti G. Midface rejuvenation: a critical evaluation of a 7-year experience. *Plast Reconstr Surg* 2015;135(5):1305–1316
- Botti G, Botti C. Midface lift: our current approaches. *Handchir Mikrochir Plast Chir* 2014;46(4):224–233
- Tapia A, Mejina D, Rengifo M, Blanch A, Ferreira B. Improving the aesthetics of the cheek bone projection during facial lifting. *Aesthetic Plast Surg* 2000;24(2):85–89
- Botti G, Pascali M, Botti C, Bodog F, Gentile P, Cervelli V. Comparison of commercial fibrin sealants in facelift surgery: a prospective study. *Clin Cosmet Investig Dermatol* 2013;6:273–280
- Marchac D, Greensmith AL. Early postoperative efficacy of fibrin glue in face lifts: a prospective randomized trial. *Plast Reconstr Surg* 2005;115(3):911–916, discussion 917–918
- Por Y-C, Shi L, Samuel M, Song C, Yeow VK-L. Use of tissue sealants in face-lifts: a metaanalysis. *Aesthetic Plast Surg* 2009;33(3):336–339
- Kamer FM, Nguyen DB. Experience with fibrin glue in rhytidectomy. *Plast Reconstr Surg* 2007;120(4):1045–1051, discussion 1052
- Marten TJ. High SMAS facelift: combined single flap lifting of the jawline, cheek, and midface. *Clin Plast Surg* 2008;35(4):569–603, vi–vii
- Hamra ST. The deep-plane rhytidectomy. *Plast Reconstr Surg* 1990;86(1):53–61, discussion 62–63
- Hamra ST. Composite rhytidectomy. *Plast Reconstr Surg* 1992; 90(1):1–13
- Kamer FM, Mingrone MD. Deep plane rhytidectomy: a personal evolution. *Facial Plast Surg Clin North Am* 2005;13(1):115–126
- Berry MG, Davies D. Platysma-SMAS plication facelift. *J Plast Reconstr Aesthet Surg* 2010;63(5):793–800
- Adamson PA, Dahiya R, Litner J. Midface effects of the deep-plane vs the superficial musculoaponeurotic system plication face-lift. *Arch Facial Plast Surg* 2007;9(1):9–11