

Transcranial Color-coded Sonography to assess Collateral Posterior Pathways in a case of spontaneous Bilateral Carotid Arteries Dissection in the Absence of Ischaemic Event

Introduction

Stroke is the most common brain disease. Spontaneous cervical artery dissection (sCAD) is a relative rare cause of stroke overall, but is an important cause among young adults. Otherwise sCAD may sometimes affect several vessels (Hassan AE et al. *J Stroke Cerebrovasc Dis* 2013; 22: 42–48).

Conventional angiography has long been the gold standard in the diagnosis of sCAD but has been replaced recently by magnetic resonance imaging (MRI) and MR angiography (MRA) as well as computed tomography (CT). In any case, only ultrasound techniques enable visualization and measurement of flow dynamics in a vessel.

Transcranial color-coded sonography (TCCS) is a radiation-free, non-invasive screening method to explore intracranial arteries. Moreover, TCCS is easy to implement at the patient's bedside and can be repeated as often as required like an arterial monitoring system especially in stroke units. Although TCCS has proved effective in assessing the collateral function of the circle of Willis in healthy volunteers (Hoksbergen AW et al. *Am J Neuroradiol* 2003; 24: 456–462), its use in clinical practice is relatively sparse especially in neurologic teams.

We report the case of a young woman with sCAD of both extra-cranial internal carotids presenting with pain as the only symptom (Arnold M et al. *J Neurol Neurosurg Psychiatry* 2006; 77: 1021–1024). TCCS was of real clinical interest to confirm the presence and direction of collateral flows in posterior communicating arteries (PcoA).

Case presentation

A 31 year-old woman was admitted for severe subacute headache resistant to usual medications. Her past medical his-

tory was unremarkable. On admission, neurologic examination was normal including an accurate analysis of the cranial nerves, visual field and visual acuity. Routine blood analysis and brain MRI were normal. Extracranial duplex sonography revealed no structural abnormality in B-mode. Color-flow images of the right and left internal carotid arteries (ICA) demonstrated a reduction in the lumen distal to the carotid bifurcation caused by nonechogenic material. Doppler spectrum analysis in these areas revealed a collapse of flow velocities. Assessment of the vertebral arteries was normal. An MR angiogram was then performed and revealed a bilateral ICA severe extensive narrowing with occlusion due to dissections (Fig. 1). Time-of-flight (TOF) in MRI showed a complete Willis circle.

TCCS was performed in the supine position using a low-frequency S5–2 phased array transducer (Philips HD 15 ultrasound system, Netherlands). Intracranial arteries were studied via temporal acoustic windows. Middle cerebral arteries were both normal with normal velocities and systolic ascent time. The precommunicating parts (A1) of both anterior cerebral arteries showed normal spectra and a non-reversed blood flow. Posteroanterior flows in PcoAs were highlighted (Fig. 2). These flows indicated the anterior arterial cerebral network suppletion by the vertebro-basilar system (collateral flows from the posterior to the anterior circulation). Finally a non-reversed blood flow was recorded in the ophthalmic arteries.

TCCS controls showed the persistence of the initial values during all the acute period while ICA stayed occluded. Controls were implemented at 3, 6, 9 and 12 months. These findings were corroborated by a CT angiogram at 6 months. 3-year follow-up revealed no further clinical events, and the neurosonologic findings were unchanged.

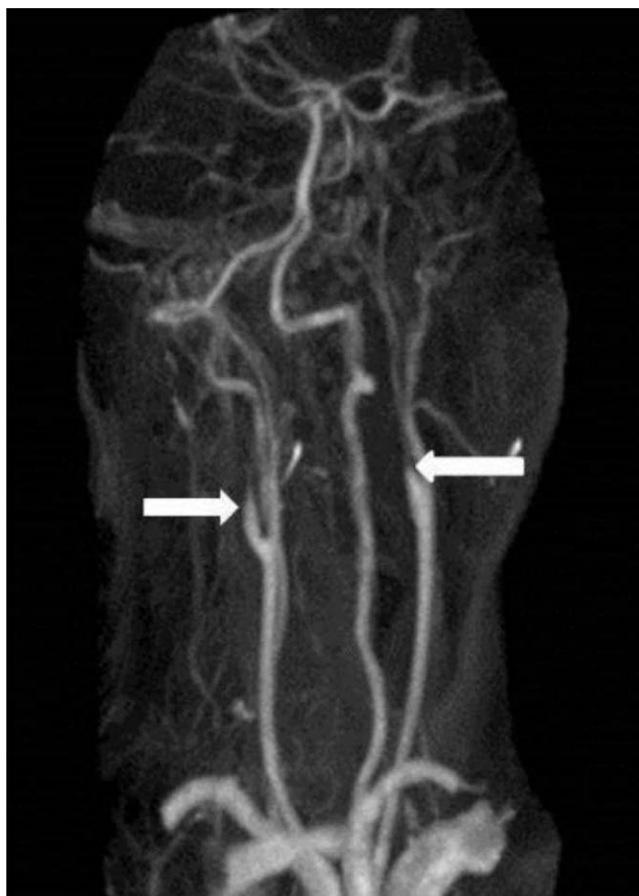

Fig. 1 Magnetic resonance cervical angiogram showing significant stenoses and near occlusion of both the internal carotid arteries from dissection. (white arrows).

License terms



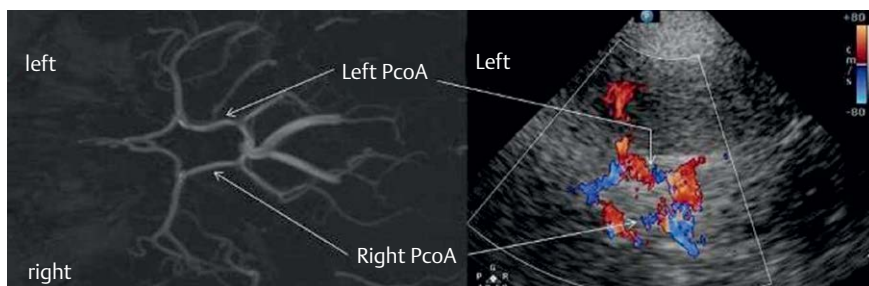


Fig. 2 Willis circle visualized on axial time-of-flight magnetic resonance angiography **a** and transcranial color-coded sonography through the left temporal bone window **b**.

Discussion

Diagnostic ultrasound is a noninvasive technique which became a reliable method for neurovascular imaging in the 1980s with the use of extracranial color-coded duplex sonography and transcranial Doppler techniques. Recent technical innovations of TCCS have enhanced the visualization of the intracranial vessels, and this should allow its dissemination to stroke units. Even if TCCS is

operator-dependent and sometimes limited by an inadequate acoustic temporal bone window, it is of real interest to try to monitor intra-cranial blood flows. Studies are needed to investigate whether early assessment of intracranial collateral flows can help taking decision about treatment modalities as soon as the patient arrives in the Emergency department (Silvestrini M et al. *Stroke* 2011; 42: 139–143). Thus this case report emphasizes the major role of efficient intracranial colla-

teral pathways to predict good functional outcome when several cervical vessels are affected by a dissection mechanism (Silvestrini M et al. *Stroke* 2011; 42: 139–143). If the anterior communicating artery (AcoA) is generally considered the most important route for collateral flow in cases of unilateral ICA occlusion, PcoA pathways seem to play a major role in cases of bilateral ICA occlusive disease (Kluytmans M et al. *Stroke* 1999; 30: 1432–1439). Like other authors, we believe that anatomic predisposition as well as timing of ICA lumen narrowing are supposed to explain individual ability to prevent a potentially devastating cerebral vascular event (Silvestrini M et al. *Stroke* 2011; 42: 139–143). This is why we encourage vascular neurologists to perform TCCS as a remarkable bedside intracranial vascular monitoring tool.

B. Barroso; France

bruno.barroso@ch-pau.fr