

Multipplanar Intracranial Hemorrhage in Trivial Head Injury: Impact of Coagulation Disorders on Perioperative Outcome

Pattanagere Manjunatha Suryanarayana Sharma¹ Masoom Abbas Mirza² Rangasetty Srinivasa²

¹Department of Neurology, BGS Global Hospital, Uttarahalli, Bangalore, Karnataka, India

²Department of Neurology, M.S. Ramaiah Medical College, MSRIT Post, Bangalore, Karnataka, India

Address for correspondence Dr. Pattanagere Manjunatha Suryanarayana Sharma, DM, Department of Neurology, First Floor, BGS Global Hospital, Uttarahalli Main Road, Kengeri, Bangalore, Karnataka 560060, India (e-mail: pmssharma17@gmail.com).

Indian J Neurotrauma 2015;12:167–168.

Abstract

Keywords

- ▶ multiplanar intracranial hemorrhage
- ▶ coagulopathy
- ▶ trivial trauma

Multipplanar intracranial hemorrhage with coagulopathy significantly increases perioperative morbidity and should always be considered while evaluating brain injury in setting of trivial trauma. Aneurysm and cerebral venous thrombosis (CVT) must always be ruled out before definite surgical intervention. Here, we report a case of intracranial hemorrhage in multiple planes occurring in the setting of coagulopathy, its early diagnosis and its treatment which resulted in a good outcome.

Traumatic brain injury is the most common cause of simultaneous bleeding at multiple planes on computed tomography (CT) of the brain. Systemic coagulopathies increase the risk of symptomatic intracranial hemorrhage following trauma. Here, we report a 56-year-old man who presented with four episodes of generalized seizures followed by fall and head injury. He had history of chronic alcohol intake, last binge 2 days prior to the fall. On evaluation, he had frontal contusion, with the Glasgow Coma Scale (GCS) score of 12/15 and right hemiparesis. He had clinical features suggestive of chronic liver disease. His CT of the head showed left temporal contusion along with intraventricular extension, left temporal subdural hemorrhage, and right temporal subarachnoid hemorrhage as shown in ▶ **Fig. 1**. There was no skull fracture on the bone window. His laboratory investigations revealed thrombocytopenia (50,000/ μ L), deranged liver function test (LFT), and prolonged prothrombin time (test: 16.4 seconds, control: 13, international normalized ratio [INR]: 1.34). His coagulation parameters were corrected with platelet transfusion, fresh frozen plasma, and he underwent left frontotemporal

craniotomy and evacuation of hematoma. He had uneventful postoperative recovery with residual sensory aphasia and discharged 2 weeks later. Coagulopathy is most commonly associated with intraparenchymal hemorrhage, subdural is less often encountered, and combined subdural and intraparenchymal can be seen rarely.¹ However, simultaneous bleeding in multiple planes in subdural, subarachnoid, intraparenchymal with intraventricular extension following trivial trauma without open fracture as seen in our patient is distinctly rare. The presence of multiple planar bleed should alert the physician for presence of an underlying coagulopathy as it has different therapeutic implications during perioperative period.²

Context

Multipplanar intracranial bleeds in the setting of trivial trauma is exceedingly rare and occurrence of which should prompt the clinician to suspect underlying systemic coagulopathy that may have different therapeutic implications during perioperative period.

received

June 8, 2015

accepted

October 15, 2015

published online

December 17, 2015

© 2015 Neurotrauma Society of India

DOI <http://dx.doi.org/>

10.1055/s-0035-1569474.

ISSN 0973-0508.

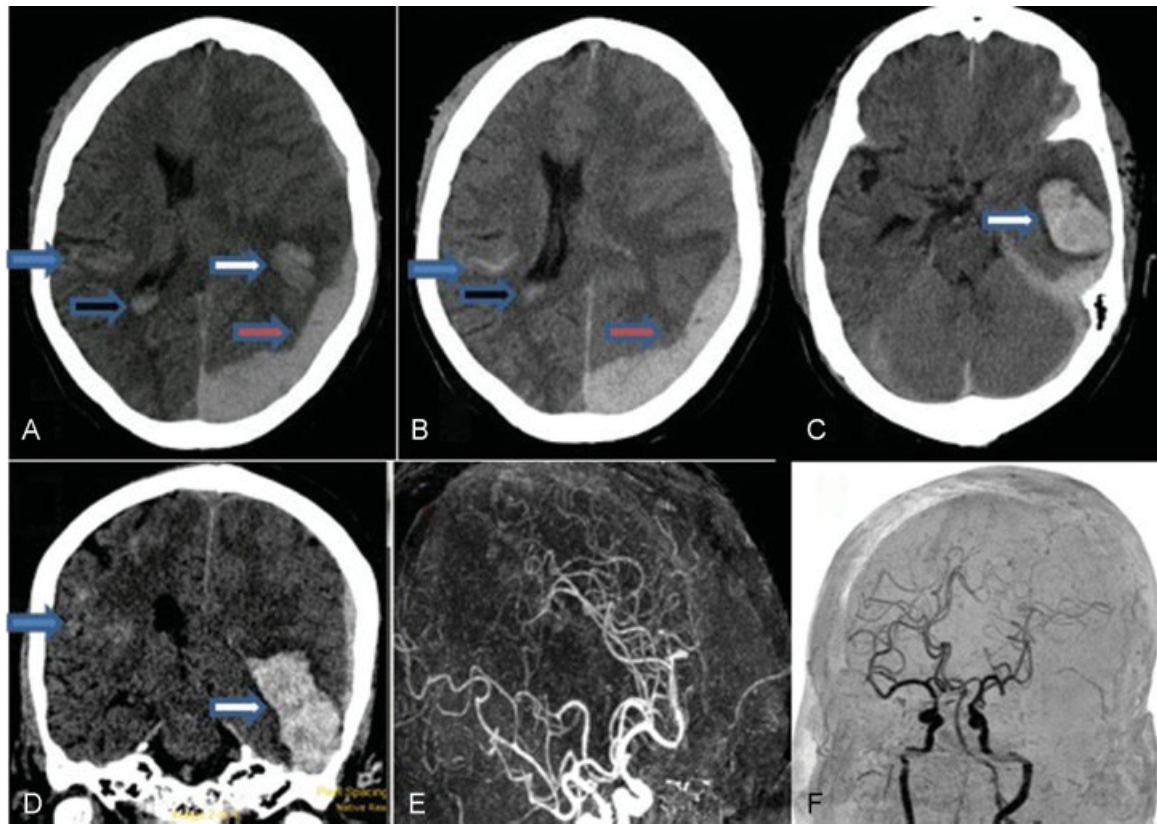


Fig. 1 (A–C) CT brain axial view showing subdural/subarachnoid/parenchymal/intraventricular bleeds in bilateral (left > right) temporoparietal region as pointed by different colored arrows. No evidence of fracture (D) in coronal section. (E and F) CT angiogram revealing no abnormality.

Presentation at a Meeting

No.

Conflict of Interest

No.

Funding

No.

References

- 1 Hart RG, Boop BS, Anderson DC. Oral anticoagulants and intracranial hemorrhage. Facts and hypotheses. *Stroke* 1995; 26(8):1471–1477
- 2 Tieu BH, Holcomb JB, Schreiber MA. Coagulopathy: its pathophysiology and treatment in the injured patient. *World J Surg* 2007;31(5):1055–1064