

Rapid Effect of Gamma Knife Radiosurgery on Clivus Metastasis: A Case Report

Ahmet F. Atik¹ Timur S. Akpınar² Askin Seker¹

¹Department of Neurosurgery, Institute of Neurological Sciences, Marmara University, Istanbul, Turkey

²Department of Internal Medicine, Istanbul Faculty of Medicine, Istanbul, Turkey

Address for correspondence Ahmet F. Atik, MD, Institute of Neurological Sciences, Marmara University, Istanbul 34840, Turkey (e-mail: afa@afatihatik.com).

Indian J Neurosurg 2016;5:25–27.

Abstract

Breast cancer may cause distant metastasis even though there is no local recurrence. Disease can spread to any part of body via lymphoid and hematogenous way, and clivus is one of the most common locations. Total excision of clival lesions carries a significant risk of neurologic damage due to proximity to cranial nerves. We present 62-year-old woman who has a previously known breast cancer history. She admitted to our clinic with unilateral sixth nerve palsy and diplopia. Imaging studies revealed clivus metastasis. Patient was treated with gamma knife radiosurgery. In the next 2 months, sixth nerve palsy recovered along with diplopia. In this case report we would like to emphasize the importance of gamma knife radiosurgery at the deeply located breast cancer metastasis.

Keywords

- clivus
- radiosurgery
- metastasis

Introduction

The clivus is located at an anatomically critical location next to brainstem and the majority of the cranial nerves. The most frequent differential diagnosis for a clival lesion is a chordoma, with a 8/100000 incidence rate.¹ Although clival metastases are rare, prostate and thyroid carcinomas are the most frequent metastasis sites,² followed by hepatocellular, renal, gastric carcinomas, melanomas, and liposarcomas. Although cancers tend to spread via the lymphoid system, metastasis to the clivus occurs through hematogenous spread.²

Here we report a unique example of bone metastasis without a local recurrence of the primary disease as determined radiographically. Gamma knife radiosurgery (GKR) was used as the primary treatment method; the patient also underwent subsequent chemotherapy as a neoadjuvant treatment for breast cancer recurrence.

This case report proposes GKR may cure clinical manifestations of clivus metastasis even before obvious shrinkage occurs.

Case Report

A 62-year-old woman presented with unilateral sixth nerve palsy and diplopia (►Fig. 1A). Her medical history revealed an invasive ductal carcinoma diagnosed 20 years prior. Modified radical mastectomy was performed, and the pathologic evaluation revealed the tumor stage was T3N2M0. The patient was treated with adjuvant chemotherapy (Endoxan + 5 fluorouracil + tamoxifen citrate) for six cycles. The patient did not show any signs of recurrence or distant metastasis for 10 years, after which time the patient had local recurrence. Conventional radiotherapy + anastrozole chemotherapy were used to treat the relapsed cancer. The recurrent tumor disappeared following treatment.

Current day, the patient visited our hospital with the aforementioned complaint. A cranial magnetic resonance imaging (MRI) scan was performed and an irregular heterogeneously contrast enhancing, osteolytic lesion was detected on the left half of the clivus (►Fig. 2A–C).

In consideration of the patient's history, the detection of the intracranial lesion was considered a metastasis and a

received
May 29, 2015
accepted

November 18, 2015
published online
February 19, 2016

DOI <http://dx.doi.org/10.1055/s-0036-1572371>.
ISSN 2277-954X.

© 2016 Neurological Surgeons' Society of India

License terms



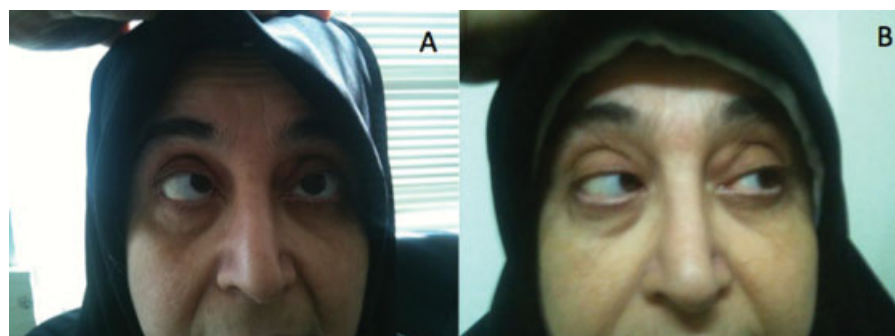


Fig. 1 (A) Patient had left-sided sixth nerve palsy. Pretreatment photograph. (B) Recovered sixth nerve palsy. Posttreatment second month.

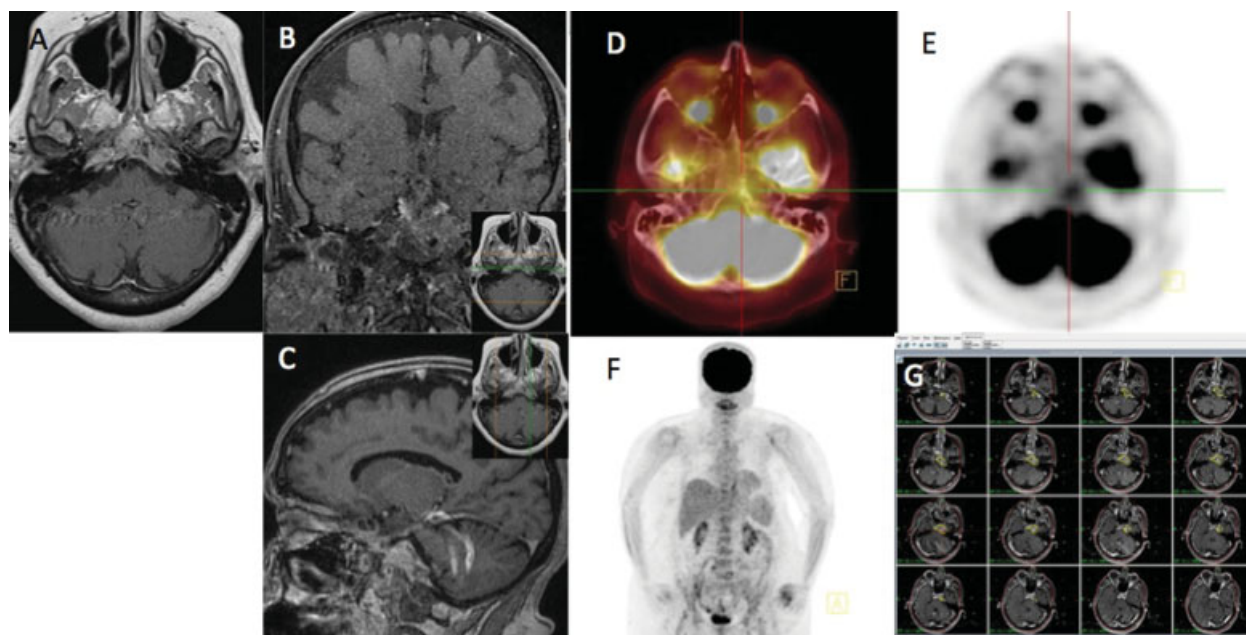


Fig. 2 (A) Preoperative contrast enhanced axial T1 magnetic resonance imaging. (B) Preoperative contrast enhanced coronal T1 MRI. (C) Preoperative contrast enhanced sagittal T1 MRI. (D, E) Preoperative positron emission tomography images of cranial base. (F) Preoperative PET images of body, showing no fluorodeoxyglucose enhancement. (G) Gamma knife treatment planning of clivus lesion.

positron emission tomography (PET) was performed to detect the possible origin of the lesion. The results did not detect a relapse on either breast or elsewhere in the body, but a fluorodeoxyglucose uptake was demonstrated on the clivus consistent with other imaging studies (► **Fig. 2D–F**).

Although there was no radiologic evidence of recurrence in the breast tissue, the lesion was considered as metastasis due to the patient history and location of the intracranial lesion. In addition, serum CA 15–3 levels were found above normal levels (55.44 U/L).

Following this diagnosis, the patient underwent gamma knife stereotactic radiosurgery for clival metastasis that encompassed 15 Gy to 50% isodose area (► **Fig. 2G**). The patient was further treated with 50 mg IM prednisolone and discharged the same day with regular control tests planned for every 2 months.

The first postoperative visit determined that even though the tumor size was not altered, a neurologic examination indicated a full recovery of the sixth nerve palsy (► **Fig. 1B**). Because of high CA 15–3 levels, the patient received six cycles

of docetaxel + capecitabine + ibandronic acid treatment for a radiologically invisible breast cancer relapse following the clinical recovery of the damage to the sixth cranial nerve.

Discussion

GKR is an effective treatment modality with a good tumor control rate and minimal morbidity. GKR can be used as either a primary treatment or a secondary addition to the surgery to combat either metastasizes or primary skull base tumors.³ Although radiotherapy may cause morbidities such as cranial nerve damage or cerebro spinal fluid leakage, GKR has not been reported to result in any of these complications.³ This case report is an example of a clivus-skull base metastasis that was successfully treated by GKR with a rapid recovery of neurologic damage.

Bone metastases are frequently detected in many types of cancers in the advanced stages of disease, with the highest occurrence rates in patients with advanced breast and lung cancer. It has been reported that prostate carcinoma in men

and breast cancer in women are the primary source of skull base metastasis. Other cancers that lead to clivus metastasis include prostate cancer, thyroid cancer, or hepatocarcinoma.²

Breast cancers most frequently metastasize to the bone and result in a poor prognosis following spreading; only 20% of breast cancer patients survive 5 years postdiagnosis of metastasis.⁴ There are two types of bone metastasis: osteolytic and osteoblastic. Osteolytic metastases often presents with pain, hypercalcemia, or nerve compression syndromes. This case study presented with sixth nerve palsy due to the osteolytic effect around the Dorello's canal.

There are few reported cases that describe metastasis without local tumor recurrence. A review by Pallini et al (need reference number linked here) found that 6 out of 34 patients in the literature displayed symptoms caused by metastasis whereas the primary tumor was clinically silent.² Similarly, the case study we present here presented with only the sixth nerve palsy, but it was treated as a local recurrence due to the high CA15-3 levels even in the absence of tumor relapse at the primary location as determined by PET scan. Therefore, the patient was treated with chemotherapy for six cycles.

Although Patanaphan et al reported the median time from breast cancer diagnosis to bone metastasis was 12 months,⁵ our case study presented with a metastasis 240 months following the primary diagnosis. According to the literature, this case study is longest reported time

interval for a breast cancer patient to present with a bone metastasis.

Conclusion

Breast cancer may spread to other tissues even in the absence of evidence for a local recurrence. Given that clivus is in an anatomically challenging location to resect the lesion using current surgical techniques, we emphasize the value of GKR on the treatment of breast cancer metastasis of clivus and may rapidly improve clinical symptoms.

References

- 1 McMaster ML, Goldstein AM, Bromley CM, Ishibe N, Parry DM. Chordoma: incidence and survival patterns in the United States, 1973–1995. *Cancer Causes Control* 2001;12(1):1–11
- 2 Pallini R, Sabatino G, Doglietto F, Lauretti L, Fernandez E, Maira G. Clivus metastases: report of seven patients and literature review. *Acta Neurochir (Wien)* 2009;151(4):291–296, discussion 296
- 3 Francel PC, Bhattacharjee S, Tompkins P. Skull base approaches and gamma knife radiosurgery for multimodality treatment of skull base tumors. *J Neurosurg* 2002;97(5, Suppl):674–676
- 4 Coleman RE. Metastatic bone disease: clinical features, pathophysiology and treatment strategies. *Cancer Treat Rev* 2001;27(3):165–176
- 5 Patanaphan V, Salazar OM, Risco R. Breast cancer: metastatic patterns and their prognosis. *South Med J* 1988;81(9):1109–1112