

Intracerebral Hemorrhage: A Rare Snake Bite Sequelae

Muhammed Jasim Abdul Jalal¹ Annie Thomas² Prithvi Varghese³

¹Department of Family Medicine, Lakeshore Hospital and Research Centre, Ernakulam, Kerala, India

²Department of Anaesthesia and Critical Care, Lakeshore Hospital and Research Centre, Ernakulam, Kerala, India

³Department of Neurosurgery, Lakeshore Hospital and Research Centre, Ernakulam, Kerala, India

Address for correspondence Muhammed Jasim Abdul Jalal, MBBS, DNB, Department of Family Medicine, Lakeshore Hospital and Research Centre, Nettoor P.O., Maradu, NH 47-Bypass, Ernakulam, Kerala 682040, India (e-mail: jasimabduljalal@yahoo.com).

Indian J Neurosurg 2017;6:27–30.

Abstract

Introduction Annually, more than 2,500,000 snake bites are reported in India, out of which 30,000 to 50,000 cases end in mortality. Here, we report an unusual complication of intracerebral hemorrhage following a snake bite.

Case Report A 48-year-old diabetic and hypertensive male patient presented with loss of consciousness following a suspected snake bite. Unconsciousness was preceded by vomiting. His neurological status deteriorated to a Glasgow coma score of 7/15 (E₁M₅V₁). Pupils showed anisocoria. Computed tomographic scan of the brain revealed large intracerebral hemorrhage in the left temporal lobe and another large intracerebral hemorrhage in the left parietal lobe with significant mass effect and signs of early transtentorial herniation. He was taken up for left frontotemporoparietal craniotomy and evacuation of left temporoparietal intracerebral hemorrhage.

Conclusion Cerebral complications following snake bite envenomation include infarcts and hemorrhages. Even though rare in incidence, cerebral complications following snake bites are associated with high morbidity and mortality. The patient presented here had left temporal and left parietal intraparenchymal hemorrhage with impending transtentorial herniation following a snake bite. Prompt treatment of raised intracranial tension simultaneously with aggressive correction of the coagulation disorders and appropriate supportive measures can result in better outcomes in patients having cerebral complications of snake bite envenomation.

Keywords

- ▶ snake bite
- ▶ intracerebral hemorrhage
- ▶ coagulopathy

Introduction

Annually, more than 2,500,000 snake bites are reported in India, out of which 30,000 to 50,000 cases end in mortality.¹ Ophitoxaemia (snake bite envenomation) can present with local cellulitis, renal failure, and hemorrhagic manifestations including intracranial hemorrhage. Here, we report an unusual complication of intracerebral hemorrhage following a snake bite.

Case Report

A 48-year-old diabetic and hypertensive male patient presented with loss of consciousness following a suspected snake bite. Unconsciousness was preceded by vomiting. On examination, the patient was irritable, with a Glasgow coma score of 13/15. His pupils were equal and reactive to light. General examination revealed extensive ecchymosis over his left shoulder and left upper limb. Snake bite mark was

received
March 16, 2015
accepted after revision
December 23, 2015
published online
June 8, 2016

DOI <http://dx.doi.org/10.1055/s-0036-1581985>.
ISSN 2277-954X.

© 2017 Neurological Surgeons' Society of India

License terms



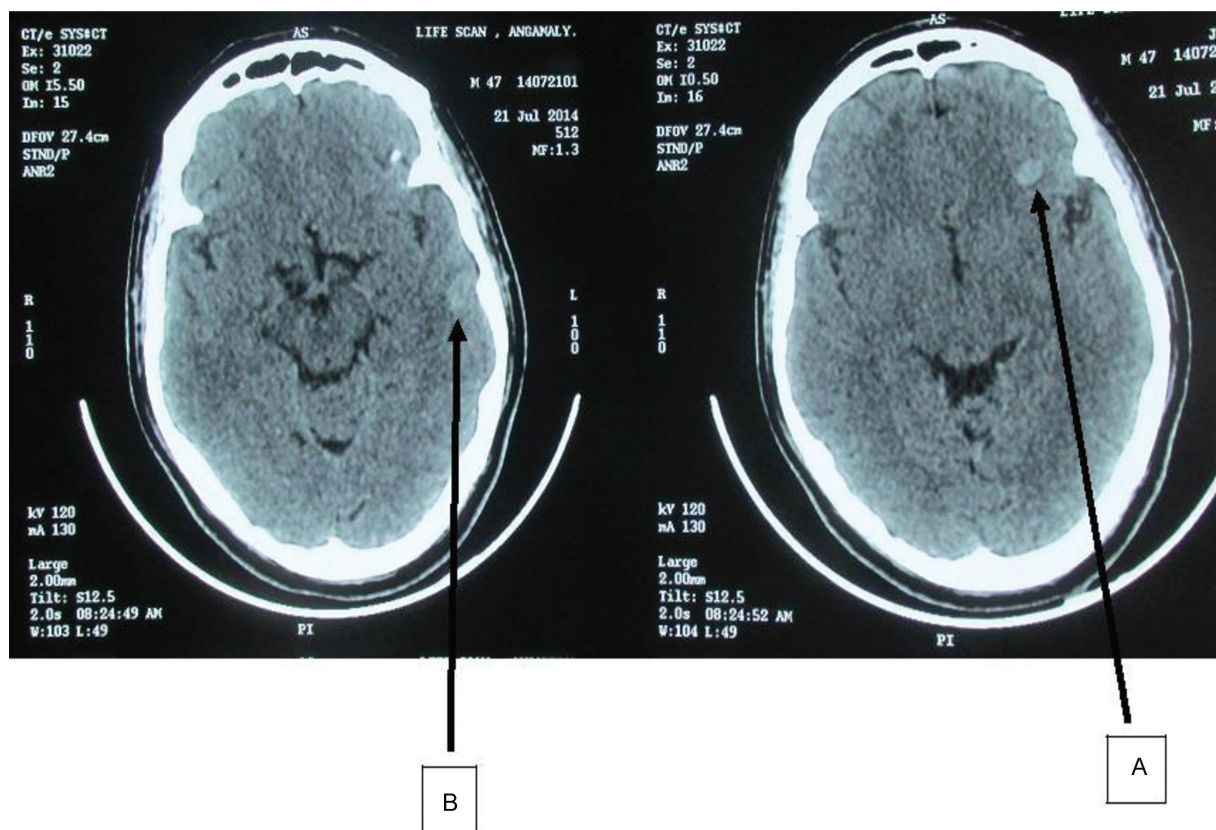


Fig. 1 Initial CT scan of the brain. (A) A small hemorrhage in the left lobe and (B) a suspicious hemorrhage in the left temporal lobe with no significant mass effect. CT, computed tomography.

noticed near the left ankle. The coagulation profile was deranged (prothrombin time: 17.8 seconds, international normalized ratio: 1.34). The patient was administered antsnake venom therapy (10 vials–100 mL of antsnake venom diluted in 500 mL of 0.9% saline over 2 hours). Each 1 mL of antsnake venom neutralizes 0.60 mg of cobra venom, 0.45 mg of krait venom, 0.6 mg of Russell viper venom, and 0.45 mg of saw-scaled viper venom.

Initial computed tomographic (CT) scan of the brain (CT-brain, **Fig. 1**) showed a small hemorrhage in the left frontal lobe and a suspicious hemorrhage in the left temporal lobe with no significant mass effect. Later on, his neurological status deteriorated to a Glasgow coma score of 7/15 ($E_1M_5V_1$). Anisocoria was noticed. Repeat CT-brain (**Fig. 2**) revealed large intracerebral hemorrhage in the left temporal lobe and another medium sized intracerebral hemorrhage in the left parietal lobe with significant mass effect and signs of early transtentorial herniation. The left frontal lobe intracerebral hemorrhage showed only minimal expansion.

At this stage, the patient was intubated and connected to a ventilator. The coagulation profile was corrected with platelet concentrates and fresh frozen plasma transfusions. In view of impending transtentorial herniation, the patient was taken up for left frontotemporoparietal craniotomy. At surgery, the brain was found severely edematous and the left temporal lobe hematoma was evacuated. The dura was not closed but approximated with an expansile duroplasty.

Anticipating a further increase in cerebral edema, bone flap was not replaced and instead, preserved in the anterior abdominal.

Postoperatively, the neurological status stabilized and the patient was gradually weaned off the ventilator after tracheostomy. Postoperative CT-brain (**Fig. 3**) showed resolution of the mass effect. Patient steadily improved and 2 months later, bone flap was replaced. Presently, he is conscious, oriented, and ambulant with no focal neurological deficits.

Discussion

Ophitoxaemia is rather an exotic term that characterizes the clinical spectrum of snake bite envenomation. In India, Maharashtra has the highest incidence of snake bites (70 snake bites per lakh population), followed by Kerala, Tamil Nadu, Uttar Pradesh, and West Bengal. Mortality due to snake bite is associated with renal failure, central nervous system hemorrhage, and secondary infection. Cerebral complications following snake bite envenomation are rare and it includes infarcts and cerebral hemorrhages.^{2,3}

Multiple mechanisms have been suggested for cerebral hemorrhages following snake bite, of which the most common is venom-induced consumptive coagulopathy and hemorrhagin-induced direct endothelial injury. Cerebral hemorrhages have been linked to the bite of venomous snakes (**Table 1**). In a study of 309 patients with snake bite,

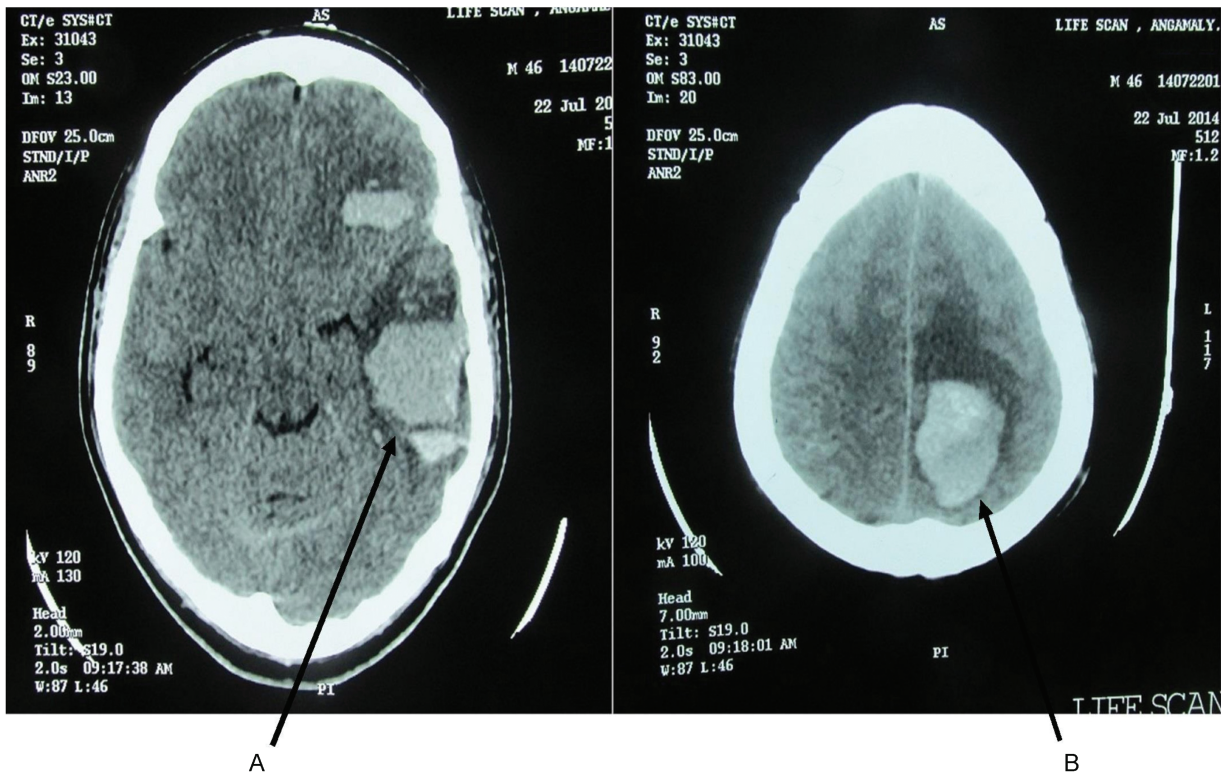


Fig. 2 Repeat CT scan of the brain. (A) A large intracerebral hemorrhage in the left temporal lobe and (B) another large intracerebral hemorrhage in the left parietal lobe with significant mass effect and signs of early transtentorial herniation. CT, computed tomography.

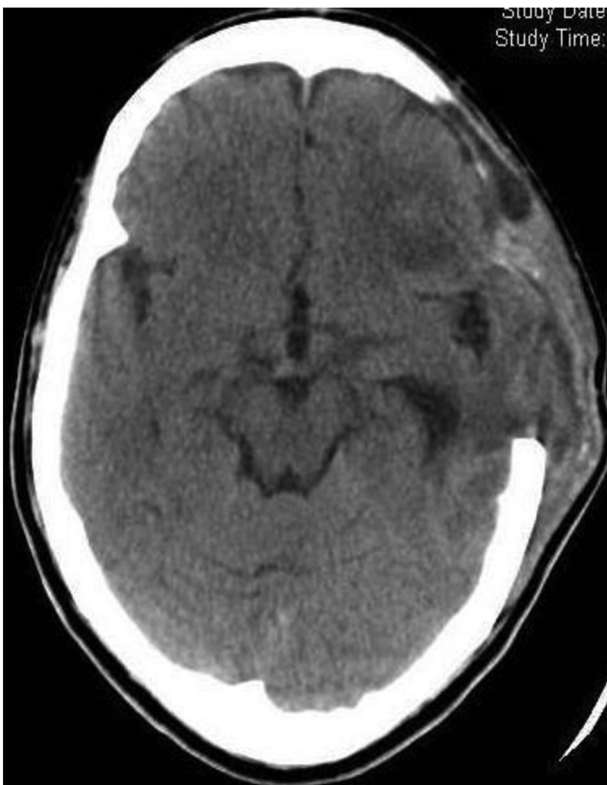

Fig. 3 Postoperative computed tomographic scan of the brain: resolution of the mass effect.

Mosquera et al reported cerebrovascular complications in only 8 patients (2.6%) of which 7 patients had cerebral hemorrhages.⁴ Coagulopathy and intracerebral hemorrhage was reported in an 85-year-old woman attacked by a serpent of Elapididae family (*Notechis scutatus*).⁵

Snake venom contains proteases, phospholipases, collagenases, metalloproteinases, and thrombin-like enzymes.⁶ These interfere with normal blood clotting. They generate anticoagulant and coagulant effects. The coagulant effect is due to the presence of the arginine esterase hydrolase, which has a similar action of thrombin on platelet aggregation. Snake venom also contains a factor X activator, which causes coagulopathy by platelet aggregation inhibition.

Venom-induced consumptive coagulopathy (VICC) results from activation of the coagulation pathway at various levels by procoagulant toxins. VICC is characterized by a prolonged 20-minute whole blood clotting test, prothrombin time, and activated partial thromboplastin time. VICC also causes a marked increase in the fibrinogen degradation products.⁷

Metalloproteinases (ecarin and carinactivase) are prothrombin activators which act by reducing the levels of fibrinogen, factor V, and factor VII resulting in hemorrhages including cerebral hemorrhages. Hemorrhagin toxin causes VICC as well as direct endothelial injury which can lead to fatal intracerebral hemorrhage such as subarachnoid hemorrhage.⁷ Proteases destroy the wall of blood vessels, activate fibrinolysis, and cause serious hemorrhages. Prothrombinase complex in snake venom is composed of protease factor (f) Xa and cofactor (f) Va. These factors

Table 1 Cerebral hemorrhages linked to the bite of venomous snakes

Snake	Toxins	Effect on brain
<i>Bothrops</i> species	Aspercitin, hemorrhagins, metalloproteinases	Subarachnoid and parenchymal brain hemorrhages
<i>Daboia russelli</i> (Russell viper)	Proteases	Pituitary hemorrhages
<i>Pseudonaja textilis</i> (Brown snake)	Prothrombinase	Parenchymal brain hemorrhages
<i>Notechis scutatus</i> (Tiger snake)	Toxic acidic proteins	Parenchymal brain hemorrhages

convert prothrombin to thrombin causing coagulopathy, which can result in brain parenchymal hemorrhages.

Conclusion

Cerebral complications following snake bite envenomation include infarcts and hemorrhages. Even though rare in incidence, cerebral complications following snake bites are associated with high morbidity and mortality. The patient presented here had left temporal and left parietal intraparenchymal hemorrhage with impending transtentorial herniation following a snake bite. Prompt treatment of raised intracranial tension simultaneously with aggressive correction of the coagulation disorders and appropriate supportive measures can result in a better outcome in patients having cerebral complications of snake bite envenomation.

Funding

None.

Financial Disclosure

The authors have no financial relationships to declare relevant to this article.

Conflict of Interest

The authors have no conflicts of interest to declare relevant to this article.

References

- 1 David AW. Guidelines for the Clinical Management of Snake-Bites in the South-East Asia Region. New Delhi, India: World Health Organization; 2005:1–67
- 2 Boyer LV, Seifert SA, Clark RF, et al. Recurrent and persistent coagulopathy following pit viper envenomation. Arch Intern Med 1999;159(7):706–710
- 3 Murthy JM, Kishore LT, Naidu KS. Cerebral infarction after envenomation by viper. J Comput Assist Tomogr 1997;21(1): 35–37
- 4 Mosquera A, Idrovo LA, Tafur A, Del Brutto OH. Stroke following Bothrops spp. snakebite. Neurology 2003;60(10):1577–1580
- 5 Yap CH, Ihle BU. Coagulopathy after snake envenomation. Neurology 2003;61(12):1788
- 6 Cortelazzo A, Guerranti R, Bini L, et al. Effects of snake venom proteases on human fibrinogen chains. Blood Transfus 2010;8 (Suppl 3):s120–s125
- 7 Isbister GK. Snakebite doesn't cause disseminated intravascular coagulation: coagulopathy and thrombotic microangiopathy in snake envenoming. Semin Thromb Hemost 2010;36(4): 444–451