

# Pediatric Patient with Incidental Os Odontoideum Safely Treated with Posterior Fixation Using Rod-Hook System and Preoperative Planning Using 3D Printer: A Case Report

Toshinori Sakai<sup>1</sup> Fumitake Tezuka<sup>1</sup> Mitsunobu Abe<sup>1</sup> Kazuta Yamashita<sup>1</sup> Yoichiro Takata<sup>1</sup>  
Kosaku Higashino<sup>1</sup> Akihiro Nagamachi<sup>1</sup> Koichi Sairyo<sup>1</sup>

<sup>1</sup>Department of Orthopedics, Tokushima University Graduate School, Tokushima, Japan

Address for correspondence Toshinori Sakai, MD, PhD, Department of Orthopedics, Tokushima University, 3-18-15 Kuramoto, Tokushima 7708503, Japan (e-mail: norinoridowluck@yahoo.co.jp).

J Neurol Surg A 2017;78:306–309.

## Abstract

Os odontoideum is often found incidentally. Surgical treatment is recommended for patients with atlantoaxial instability or neurologic deficits. Although various techniques have been used for C1–C2 fusion in adults, the use of these procedures in children is not widely accepted. We present a 12-year-old boy with incidental os odontoideum and obvious C1–C2 instability, in which bony union was achieved safely and successfully by posterior fixation using a rod-hook system and perioperative planning using a three-dimensional printer. At the 2-year follow-up, bone formation around the gap of the dens, which has been generally considered as pseudoarthrosis, was obtained after union of the posterior element of C1–C2.

## Keywords

- ▶ os odontoideum
- ▶ instability
- ▶ surgery
- ▶ pediatric

## Introduction

Os odontoideum was first described in the late 1880s.<sup>1</sup> It is often found incidentally and is asymptomatic, but it can result in neurologic deficits with atlantoaxial dislocation. According to the current management strategies for incidental os odontoideum reported by Klimo et al, patients showing evidence of atlantoaxial instability who are < 20 years of age should be considered for surgery.<sup>2</sup>

Various techniques for C1–C2 fusion have been described. Posterior sublaminar wiring and C1–C2 transarticular fixation have been frequently used, but they are intricate and may cause neural injury. C1–C2 segmental rod-screw fixation has become the preferred option.<sup>3</sup> However, various complications can occur with these surgical procedures. Even if the C1–C2 segmental rod-screw fixation is used, sacrifice of the C2 root is sometimes required to improve visualization. The use of these procedures in children has not gained widespread acceptance because safety and efficacy, of particular importance in pediatrics, have not been demonstrated in pediatric patients.

We present a pediatric case of os odontoideum in which bony union was safely and successfully achieved by posterior fixation using a rod-hook system and perioperative planning.

## Case Report

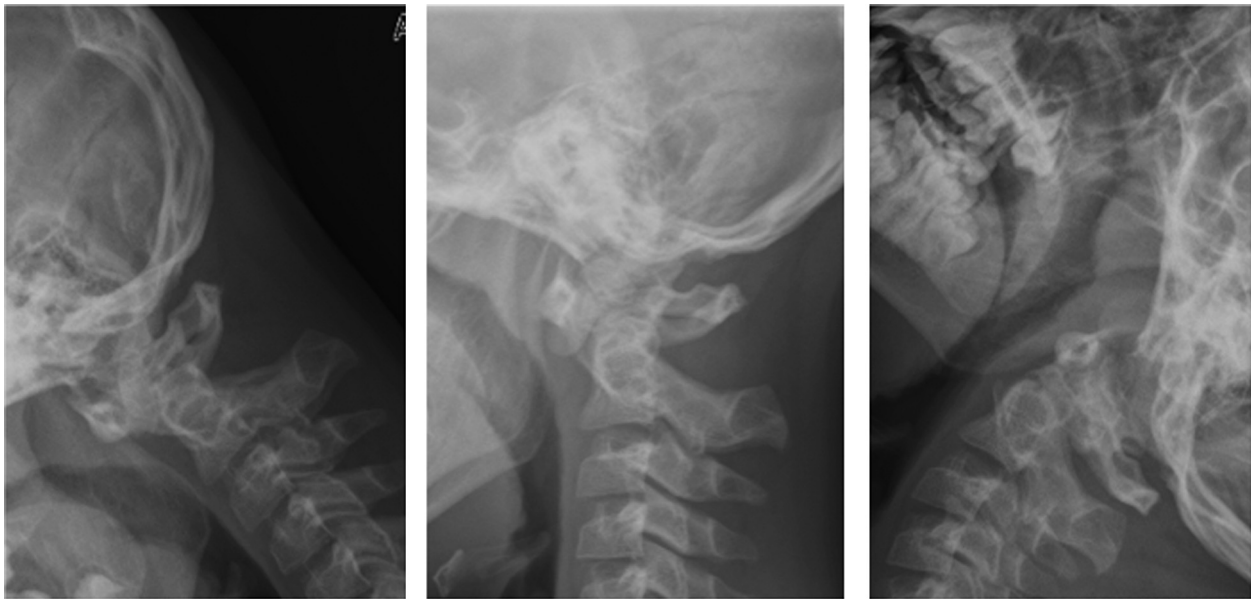
The patient was a 12-year-old boy who was referred because of C1–C2 instability due to os odontoideum. He fell while playing basketball and bruised the occipital region of his head. Although he had no symptoms, his parents took him to see a local doctor. Radiographs of the cervical spine showed C1–C2 instability due to os odontoideum, but he had neither neck pain nor neurologic findings.

He was referred to our hospital for surgical treatment because of the prominent instability. Plain radiographs showed a bony defect in the dens of C2 and obvious C1–C2 instability (▶ Fig. 1). After a thorough discussion with his family on the surgical indication, posterior fusion using a rod-hook system for the C1–C2 (3XS system; Kisco DIR, Paris, France) was used. It can be performed more safely

received  
September 4, 2015  
accepted  
March 24, 2016  
published online  
May 31, 2016

© 2017 Georg Thieme Verlag KG  
Stuttgart · New York

DOI <http://dx.doi.org/10.1055/s-0036-1584211>.  
ISSN 2193-6315.



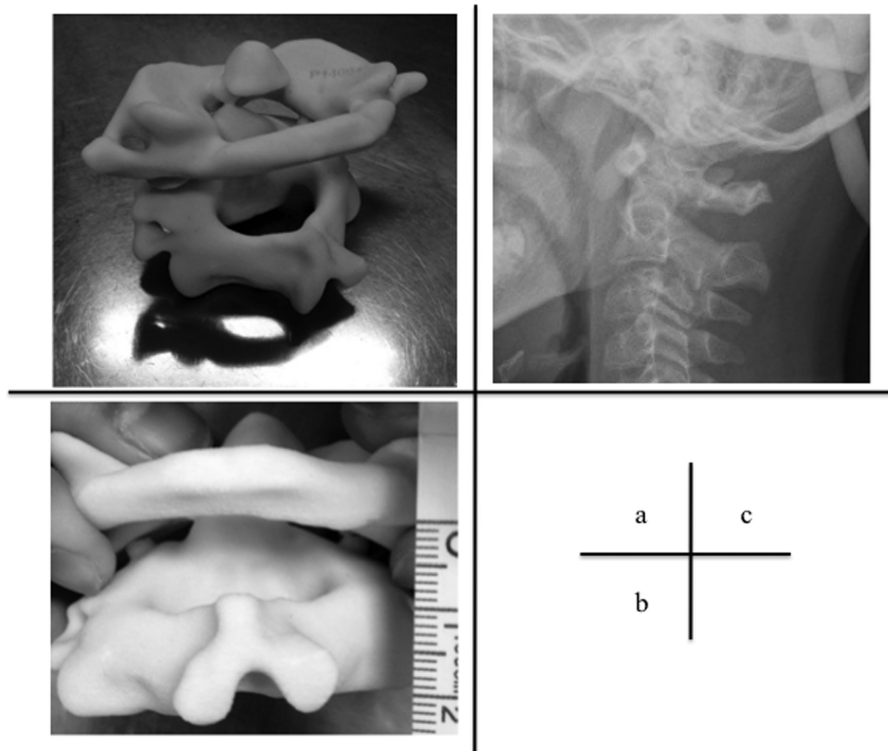
**Fig. 1** Plain radiographs showing a bony defect in the dens of C2 and obvious C1–C2 instability in a pediatric patient.

than the procedure using screws, but stabilization is not as effective.

Preoperatively, we made an actual-size replica of his C1–C2 using a three-dimensional (3D) printer to confirm whether the instrumentation could fit his immature cervical spine (►**Fig. 2A, B**). Also, on the day before surgery, we

applied the halo vest to acquire a reduced position of C1–C2 preoperatively and confirmed that no neurologic deterioration occurred after the reduction (►**Fig. 2C**).

The patient underwent posterior fusion with minimal exposure of the muscles; those attached to the C2 spinous process in particular were preserved as much as possible. The



**Fig. 2** Preoperative surgical planning. (A) Actual-size replica of C1–C2 created using a three-dimensional printer to confirm whether instrumentation could fit his immature cervical spine. (B) The halo vest was used to acquire a reduced position of C1–C2 preoperatively, and it was confirmed that no neurologic deterioration occurred after the reduction.

This document was downloaded for personal use only. Unauthorized distribution is strictly prohibited.

plate and hook system device was placed on the C1 and C2 laminae correctly, and autografted iliac bone was placed on the laminae after decortication. The grafted bone was fixed to the decorticated laminae with Nesplon tape (Alfreds Pharma Corp., Osaka, Japan).

The postoperative course was uneventful, and neurologic deterioration did not occur. External fixation using the halo vest was continued for 3 months after the operation, after which it was removed when bony union was confirmed.

At the 2-year follow-up at age 14, complete bony union of the posterior element was observed. In addition, at the cleft of the divided dens, which had been generally considered as pseudoarthrosis, bone formation was found after bony union of the posterior element of C1–C2 (►Fig. 3).

## Discussion

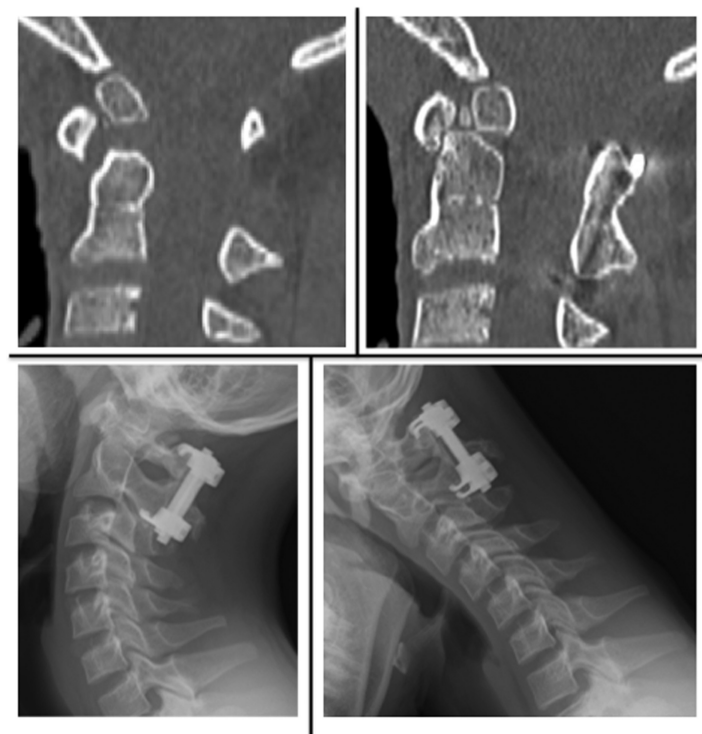Os odontoideum is a condition in which the C2 dens lacks bony continuity with the C2 body. Although its etiology has not been elucidated, two main theories have been proposed: one is related to a congenital abnormality and the other is related to trauma.<sup>4</sup> In the present case, although the boy visited the first hospital because he had a bruise in the occipital region, he had no symptoms, and plain radiographs showed no new fresh fracture at the C2 dens. Os odontoideum is most commonly believed to result from remote trauma, but he and his parents had no recollection of an obvious remote traumatic episode. In the present case, bone formation in the gap due to the os odontoideum was obtained after posterior bony fusion was achieved. This result indicates that os odontoideum is not a pseudoarth-

rosis and has the potential for bony fusion. Also, it could strongly support the so-called trauma theory.

There have been several reports of asymptomatic cases of os odontoideum. Klimo et al stated in their review article that relatively young patients (< 20 years old) with incidental os odontoideum should be strongly considered for surgery.<sup>2</sup> Screwing including transarticular fixation and segmental rod-screw fixation is considered the most rigid fixation method for C1–C2 instability. However, various complications such as vertebral artery injury have been reported. According to the report by Gluf and Brockmeyer, complications occurred in 7 patients (10.4%), including 2 vertebral artery injuries, in a cohort of 67 pediatric patients.<sup>5</sup> In pediatric patients especially, the difficulty of the surgical procedure and associated risks would be higher because the immature spine is anatomically smaller than the mature spine. Also, the screwing system usually requires large exposure, which leads to soft tissue damage, and C2 root sacrifice is sometimes required to improve visualization.

To reduce potential technical errors and critical risks, posterior interlaminar fixation using the 3XS system was applied in this pediatric case. Although critical complications may be avoided using this system, maintenance of stiffness in rotation is relatively weak. Therefore, we used the halo vest until bony union was achieved. Biomechanically, the 3XS system has been proven to be capable of tolerating the rotational forces between C1 and C2.<sup>6</sup>

To confirm whether the device fits the pediatric cervical spine correctly, we recreated a full-scale replica of the patient's C1–C2 preoperatively using a three-dimensional



**Fig. 3** At the 2-year follow-up, bone formation at the gap of the dens, which has been generally considered as pseudoarthrosis, was found after bony union of the posterior element of C1–C2 occurred.

(3D) printer.<sup>7</sup> This virtual planning has recently become popular in several fields, and its adoption will increase the safety of various surgeries, particularly those for pediatric patients.

In conclusion, we believe that preoperative planning using a 3D printer, preoperative reduction of C1–C2 using the halo vest, and posterior interlaminar fixation using a rod-hook system resulted in a safe and good outcome for this patient.

## References

- 1 Cunningham DJ. Connection of the os odontoideum with the body of the axis vertebra. *J Anat Physiol* 1886;20(Pt 2):238–243
- 2 Klimo P Jr, Coon V, Brockmeyer D. Incidental os odontoideum: current management strategies. *Neurosurg Focus* 2011;31;(6):E10
- 3 Haque A, Price AV, Sklar FH, Swift DM, Weprin BE, Sacco DJ. Screw fixation of the upper cervical spine in the pediatric population. Clinical article. *J Neurosurg Pediatr* 2009;3(6):529–533
- 4 Arvin B, Fournier-Gosselin MP, Fehlings MG. Os odontoideum: etiology and surgical management. *Neurosurgery* 2010;66(3, Suppl):22–31
- 5 Gluf WM, Brockmeyer DL. Atlantoaxial transarticular screw fixation: a review of surgical indications, fusion rate, complications, and lessons learned in 67 pediatric patients. *J Neurosurg Spine* 2005;2(2):164–169
- 6 Nishizawa S, Yamaguchi M, Matsuzawa Y. Interlaminar fixation using the atlantoaxial posterior fixation system (3XS system) for atlantoaxial instability: surgical results and biomechanical evaluation. *Neurol Med Chir (Tokyo)* 2004;44(2):61–66; discussion 67
- 7 Cheung CL, Looi T, Lendvay TS, Drake JM, Farhat WA. Use of 3-dimensional printing technology and silicone modeling in surgical simulation: development and face validation in pediatric laparoscopic pyeloplasty. *J Surg Educ* 2014;71(5):762–767