

Osteoplastic Orbitozygomatic-Mastoid-Transattical Craniotomy

Craniotomia orbitozigomático-mastóideo-transattical osteoplástica

Ilton Guenhiti Shinzato^{1,2,3,4} Felipe Bouchabki de Almeida Guardini^{4,5} Fernando Kobayashi^{4,5}

¹Neurosurgery Residency Program Supervisor of Santa Casa, Universidade Federal do Mato Grosso do Sul, Campo Grande, MS, Brazil

²DSc, COPPE/UFRJ, Rio de Janeiro, RJ, Brazil; Thesis Research done at Teikyo University, Chiba, Japan

³Titular Member of ABNC, ABORL, FLANC, WFNS; Active Member of the Walter E. Dandy Neurosurgical Society, St. Louis, United States

⁴Titular Member of Brazilian Neurosurgery Society – SBN, São Paulo, SP, Brazil

⁵Neurosurgeon, Residency at Santa Casa, Universidade Federal do Mato Grosso do Sul, Campo Grande, MS, Brazil

Address for correspondence Ilton Guenhiti Shinzato, MD, DSc, Neurosurgery Service, Santa Casa Hospital, Rua Eduardo Santos Pereira, 88, 79002-251, Campo Grande, MS, Brazil (e-mail: iltonshinzato@uol.com.br).

Arq Bras Neurocir 2016;35:257–269.

Abstract

Objective The objective of this study is to introduce and describe a surgical technique called Osteoplastic Orbitozygomatic-Mastoid-Transattical Craniotomy (Osteoplastic OZ-MT) and to show the possibility of accomplishing osteoplastic craniotomies for other classical lateral transcranial approaches.

Technique The Osteoplastic OZ-MT combines many lateral transcranial approaches. The surgical approach involves structures of lateral and basal portions of the skull, from the frontal bone, superolateral-inferolateral-posterolateral walls of the orbit, zygoma, zygomatic process, sphenoid greater and lesser wings, temporal fossa, mandibular fossa, zygomatic process of the temporal bone, petrous pyramid, mastoid, up to the parietal and occipital regions. The temporal muscle is totally preserved and attached to the one-piece-only bone flap.

Results We have developed and used routinely the technique, including its variants and combinations, for about twenty years in children and adults to treat and/or remove mainly mesial, basal, intra, and/or extra-cranium lesions, from the anterior fossa, passing through the middle fossa and going up to the regions of the clivus, basilar artery, and cerebellum-pontine angle, with greater surgical degree of freedom and consequent reduction of morbidity and mortality. So far, we have not had any complications nor important sequels, and the aesthetic and functional results are quite favorable.

Conclusion The Osteoplastic OZ-MT is a very systematic, anatomical, feasible, and safe craniotomy. The synthesis is easy to do and can be reopened quickly if necessary. Variants and combinations allow us to opt for a more appropriate approach according to each case.

Keywords

- ▶ craniotomy
- ▶ skull base
- ▶ sphenoid bone
- ▶ zygoma
- ▶ petrous bone
- ▶ mastoid

received
January 12, 2016
accepted
April 13, 2016
published online
June 20, 2016

DOI <http://dx.doi.org/10.1055/s-0036-1584558>.
ISSN 0103-5355.

Copyright © 2016 by Thieme Publicações Ltda, Rio de Janeiro, Brazil

License terms



Resumo

Objetivo Apresentar e descrever uma técnica cirúrgica denominada de Craniotomia Orbitozygomatica- Mastóideo-Transattical Osteoplástica (OZ-MT Osteoplástica) e mostrar a possibilidade de realizar craniotomias osteoplásticas para os outros acessos transcranianos laterais clássicos.

Técnica A OZ-MT Osteoplástica combina vários acessos transcranianos laterais. O acesso cirúrgico envolve estruturas das porções lateral e basal do crânio, do osso frontal, paredes súperolateral-inferolateral-pósterolateral da órbita, zigoma, processo zigomático, asas maior e menor do esfenóide, fossa temporal, fossa mandibular, processo zigomático do osso temporal, pirâmide petrosa, mastoide, até as regiões parietal e occipital. O músculo temporal é totalmente preservado e aderido ao retalho ósseo de uma-peça-só.

Resultado Temos desenvolvido e usado de rotina a técnica, incluindo suas variantes e combinações, por cerca de vinte anos, em crianças e adultos, para tratar e/ou remover principalmente aquelas lesões mesial, basal, intra e/ou extracranianas, desde a fossa anterior, passando pela fossa média e indo até às regiões do clivus, artéria basilar e ângulo ponto-cerebelar, com maior grau de liberdade cirúrgica e consequente redução da morbidade e mortalidade. Até agora, não tivemos nenhuma complicação e nem sequelas importantes e os resultados estético e funcional são bastantes favoráveis.

Conclusões A OZ-MT Osteoplástica é uma craniotomia bastante sistematizada, anatômica, factível e segura. A síntese é fácil de ser feita e que pode ser reaberta rapidamente se necessário. Variantes e combinações nos permitem optar por um acesso mais apropriado conforme cada caso.

Palavras-chave

- ▶ craniotomia
- ▶ base de crânio
- ▶ osso esfenóide
- ▶ zigoma
- ▶ osso petroso
- ▶ mastoide

Introduction

In 1974, Salaverry^{1,2} published a technique to explore and decompress the geniculate ganglion and the labyrinthine segment of the facial nerve called *transattical approach* because it is done through the attical or supracoclear cells. Later, other authors³⁻⁵ published similar techniques.

In 1995, we modified the orbitozygomatic craniotomy accomplished by Hakuba et al⁶ to a one-piece-only technique that was called the *en bloc orbitozygomatic craniotomy (en bloc OZ)*, which was developed independently and differently from the Ikeda et al⁷ technique, where we preserve the posterolateral orbital wall. In 1997, the *en bloc OZ* was combined with a modified Salaverry's technique, called the *en bloc orbitozygomatic-mastoid-transattical craniotomy (en bloc OZ-MT)*. This technique would allow opening all the laterobasal wall of the cranium in only one bone piece, unifying all the lateral intracranial approaches. The resulting operatory field increases the surgical freedom and allows us to operate with lesser morbidity and mortality on (a) skull-base large tumors close to the midline, transincisural masses, with components from prechiasmatic region up to the cerebellum-pontine angle region, (b) large intra and extracranial tumors through the anterior and media fossa, like juvenile angiofibroma and trigeminal schwannoma, (c) the clivus region tumor, combined with the transpetrosal approaches,⁸⁻¹⁰ (d) aneurism of the posterior cerebral artery and basilar artery from the pre-pontine up to the interpeduncular cisterns, and (e) surgical treatment of the temporal

lobe epilepsy for basal and mesial lesion by the subtemporal approach (*Skull base approach for temporal lobe epilepsy treatment. III International Skull-base Congress. Foz do Iguaçu, 2000*).

During the past five years, the approach was updated and improved to the *osteoplastic orbitozygomatic-mastoid-transattical craniotomy (osteoplastic OZ-MT)*. Due to the fact that there is only one bone piece attached to the temporal muscle, the synthesis requires lesser surgical duration, and results in lesser temporal muscle atrophy and better aesthetics. In addition, the concept was extended to many variant approaches and combinations, allowing us to have a more systematic and appropriate osteoplastic approach for each case. Then, the objective of this work is to introduce and describe a general surgical technique of the *osteoplastic OZ-MT* and to show the possibility to accomplish the osteoplastic craniotomies for the various classical lateral transcranial approaches end combinations.

Technique

This surgical approach involves structures of lateral and basal portions of the skull, from the frontal bone, superolateral-inferolateral-posterolateral walls of the orbit, zygoma, zygomatic process, sphenoid greater and lesser wings, temporal fossa, mandibular fossa, zygomatic process of the temporal bone, petrous pyramid, mastoid, and up to the parietal and occipital regions. In this technique, the temporal muscle is totally preserved attached to the one-piece-only

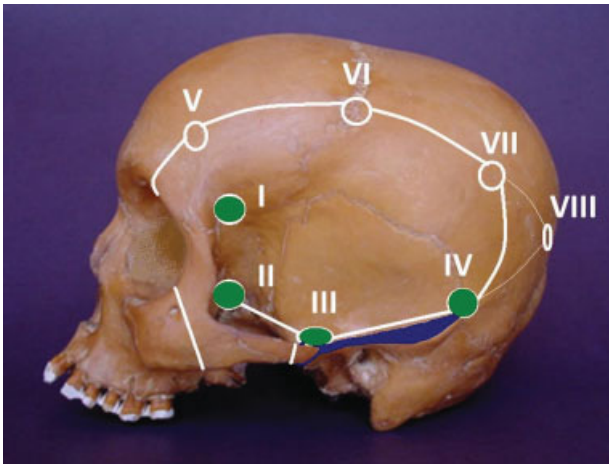


Fig. 1 The *en bloc orbitozygomatic-mastoid-transattical craniotomy (en bloc OZ-MT)* with its four defined keyholes I, II, III, IV. The others burr holes positions vary if the craniotomy needs to be larger or smaller and/or combined with other approaches. The blue area is the transattical mastoidectomy region, which can be extended either below or above the zygomatic process of temporal bone, depending on the goal, to either preserve or not the integrity of the zygomatic arch, respectively. For practical purposes, to cut the stretch between keyhole III and IV, instead of using the ideal transattical mastoidectomy, we can use an approximate and not so basal approach, the transattical craniotomy (white line).

bone flap. On the photograph of the skull, we mark the burr holes spots as well as the *transattical mastoidectomy* region, and the cutting lines of the *en bloc orbitozygomatic-mastoid-transattical craniotomy (en bloc OZ-MT)*. There are four well-defined burr holes that are called keyholes I, II, III, and IV. The other burr holes or marks V, VI, VII, and eventually VIII, have less rigid positions (►Fig. 1).

Many craniotomies were performed in the skull in such a way so that the burr holes, the cut lines, intracranial, and extracranial structures could be seen simultaneously through the temporal fossa, orbital cavity, anterior fossa, and middle fossa, where the Gasser ganglia and its branches and the middle meningeal artery were highlighted. In addition, a mastoidectomy on the anatomic piece shows some important structures such the *sigmoid sinus*, the *sinodural angle of Citelli*, and the *semicircular canals* (►Fig. 2).

To perform the osteoplastic OZ-MT craniotomy we adopt the following sequence: (1) fronto-mastoid bow-shaped incision directly to the cranium bone, (2) interfascial dissection and detachment of the scalp flap, complemented by dissection and exposition of the orbital ridge, zygoma, and the zygomatic arch until its base in the temporal bone, (3) dissection and releasing of the temporal muscle from the zygoma and zygomatic arch, except from the medium and superior region of the lateral orbital ridge, (4) subperiosteal dissection and detachment of the eyeball from the orbital superolateral and lateral wall, (5) keyhole I trepanning with simultaneous access to orbital cavity and anterior fossa, (6) keyhole II trepanning with simultaneous access to orbital cavity and middle fossa, (7) keyhole III trepanning with access to the medium laterobasal region of the tem-

poral lobe, (8) keyhole IV trepanning with access to the supratentorial region, just above the sigmoid sinus, (9) marking or trepanning points V, VI, VII, and eventually VIII, around the temporal muscle, (10) fronto-orbital cut passing through keyhole I, (11) orbitozygomatic cut passing through keyhole II, (12) superolateral craniotomy through trepanning or marks V, VI, VII, (VIII) until reaching keyhole IV, (13) inferolateral craniotomy from IV to III, and from III to II under the temporal muscle, (14) inside cut of the posterolateral orbital wall through keyhole I toward keyhole II, and (15) dura mater dissection, lifting the bone flap by leveraging, and following by fracture and osteoplastic opening.

Fronto-mastoid Bow-shaped Incision

The cut of the scalp is done only on one layer, including the periosteum that must be dissected from the bone and lifted. We start the incision in the medial frontal region just behind the hairline and continue with a harmonic curve around the temporal muscle insertion line, toward the retroauricular region, up to the mastoid tip. It is not advisable to cut deeper beyond the mastoid tip so that there is no lesion in the facial nerve. The retroauricular incision must be done further from the ear if you want to combine it with the retrosigmoid approach, and in that case, the incision ought not to be directed to the mastoid tip, but to a more posterior spot. The incision must be more posterior if you want to extend the craniotomy up to burr hole VIII at the occipital region. The classical question mark-shaped incision can be used in many variant approaches, but it should always go around the temporal muscle (►Fig. 3).

Interfascial Dissection and Detachment of the Scalp Flap

The interfascial dissection¹¹ is achieved in an anatomical, natural, and immediate way when you enter with a Lambotte rugine into the subperiosteum space of the frontal scalp region, just anterior to the temporal muscle, and from there, using a resistant spatula, rotate it toward a posterior and superior direction up to the incision line (►Fig. 4).

Keyhole I

This is a well-known trepanning of MacCarty¹²⁻¹⁴ that allows access to the epidural space of the anterior fossa and the laterosuperior region of the orbital cavity simultaneously. Theoretically, according to Shimizu et al,¹⁵ the most appropriate place to drill keyhole I is on the frontosphenoidal suture, 5mm posterior to the junction of the three sutures: frontozygomatic, sphenozygomatic, and frontosphenoidal; in practice, however, aside from the anatomical spot that you cannot see, access also depends on the inclination of the trephine relative to the orbit and the anterior fossa. Thus, optimized access is reached only by experience. To drill keyhole I, the temporal muscle should be cut and dissected vertically, parallel to the direction of its fibers, over the region of trephination but without releasing it from the edge of the orbit in its laterosuperior portion because that would cause an unfavorable aesthetic result as that region

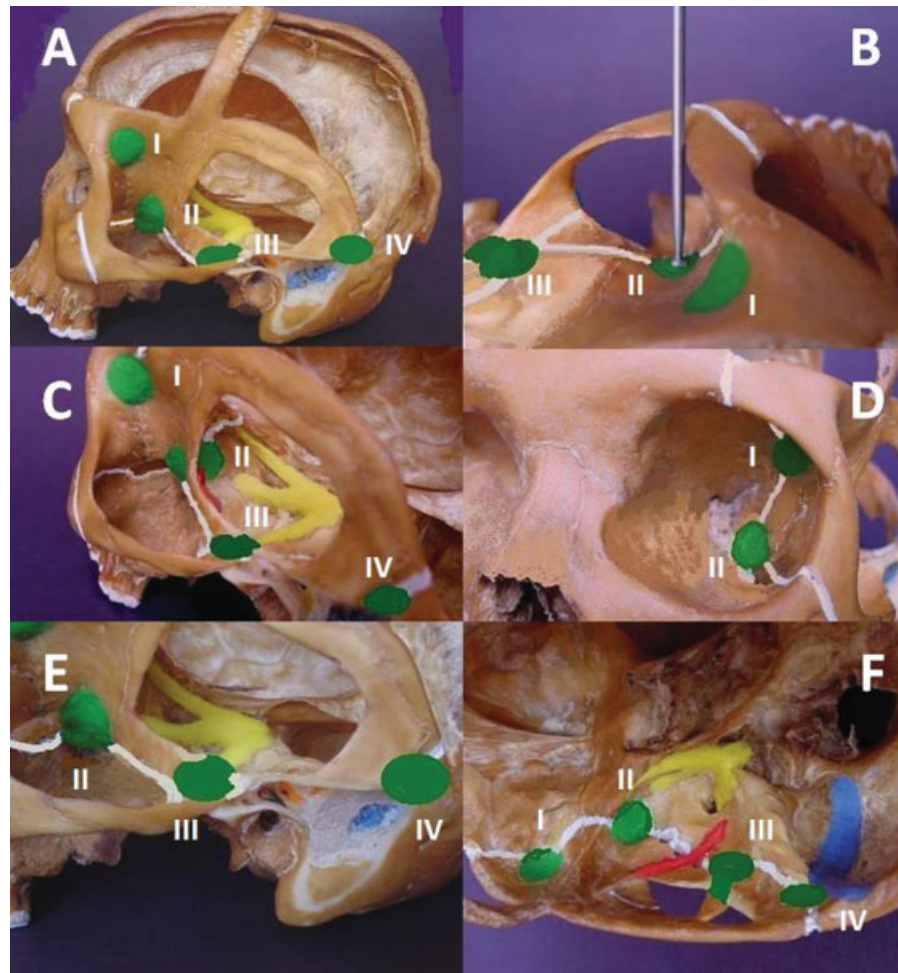


Fig. 2 Craniotomies were made to show the relationships of keyholes (filled with green wax), cutting lines (white) and the intracranial and extracranial structures as the Gasser ganglion and its branches (yellow wax), medium meningeal artery (red wax), and sigmoid sinus (blue wax). (A) Left lateral view. (B) Superior-inferior view: position of keyhole II. (C) Posterior-anterior view: keyhole II communicates the temporal fossa to the tip of temporal lobe region. (D) Anterior-posterior view: keyholes I and II communicate to the orbital cavity. (E) Lateral view: the cut line can pass above or below the temporal zygomatic process to reach keyhole III; a mastoidectomy shows some of the important structures, like the semicircular canals (orange), the sigmoid sinus (blue) and the sinodural angle of Citelli, where keyhole IV is drilled above the sigmoid sinus. (F) Superior view: keyhole I communicates to the anterior fossa, and keyholes II, III, and IV communicate to the middle fossa.

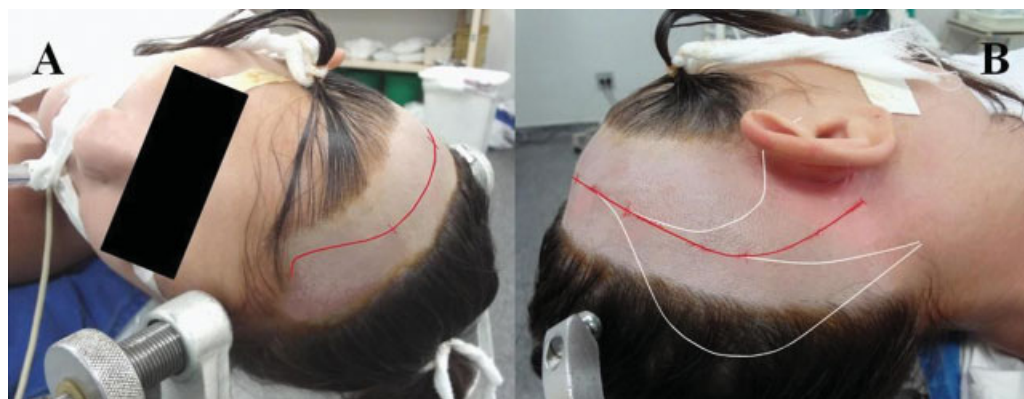

Fig. 3 (A) and (B): The main incision line (red line) and some variants (white lines). The patient position is dorsal decubitus with the dorsum a little elevated. The head must be fixed with a Mayfield apparatus. The fall and rotation of the head depend on the strategies you will adopt. The organization and the cleaning of the surgical field and room are essential throughout the procedure, from the beginning to the end.

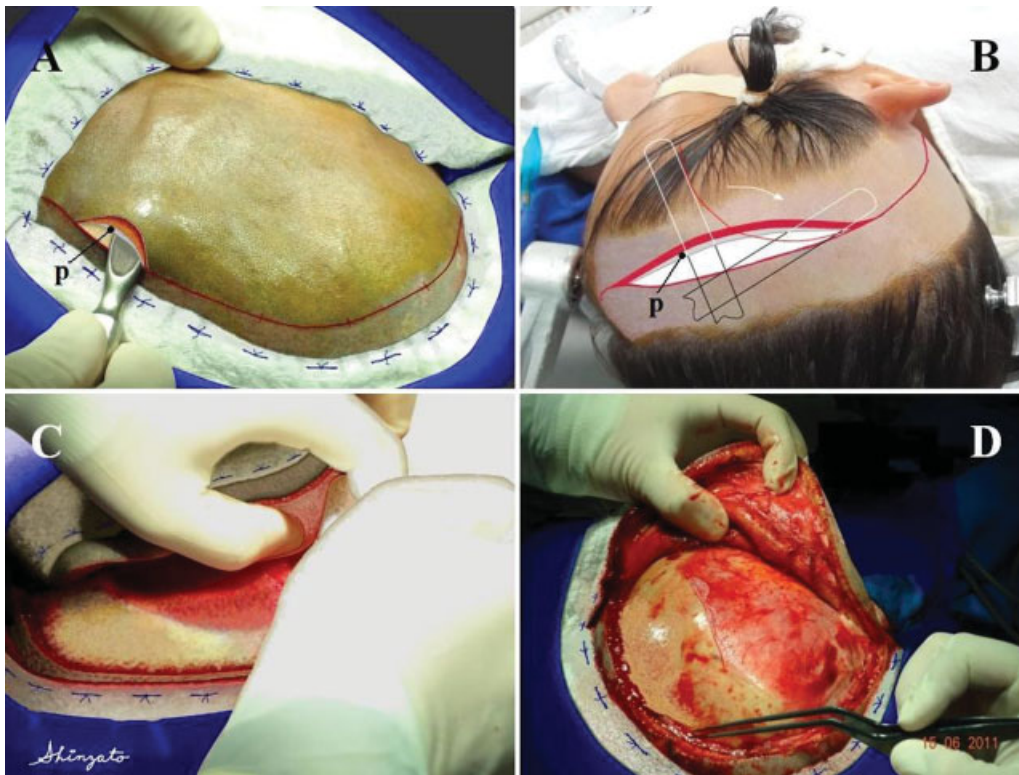


Fig. 4 Interfascial dissection in only one rotating movement of the spatula. (A) With a Lambotte rugine, we lift the scalp, inserting it under the periosteum (p) of the frontolateral region just anterior to the temporal muscle. (B) Still under the periosteum (scheme), with a resistant blade spatula, we can dissect easily the periosteum (the external fascia) from the temporal muscle fascia (the internal fascia) with only one rotating movement of the spatula toward the incision line. (C) After finishing the incision, we can easily detach the flap in the interfascial layer by lifting the skin flap using the thumbs and by pressing them. (D) To finish the skin flap overture, we need to complement it with hemostasis, dissection of the orbital rim, zygoma, zygomatic arch and the superior and posterior mastoid regions. (Technique presented in XXII Congresso Brasileiro de Neurocirurgia, Rio de Janeiro, September 1998; unpublished).

would sink. The incision size should be just enough to allow you to make the trephination (► Fig. 5).

Keyhole II

Keyhole II is a burr hole that we make on the sphenoidal greater wing, on the anterior part of the inferior orbital fissure, which gives simultaneous access to the inferolateral

region of the orbit and to the epidural space at the temporal lobe tip. Usually, keyhole II is determined by an orthogonal line toward the sphenoidal wing, tangential to the orbitozygomatic angle (formed by the orbital and zygomatic processes), which is located just above or can match the superior limit of the anterolateral part of the inferior orbital fissure. The work of Shimizu et al¹⁵ concludes that the anterolateral

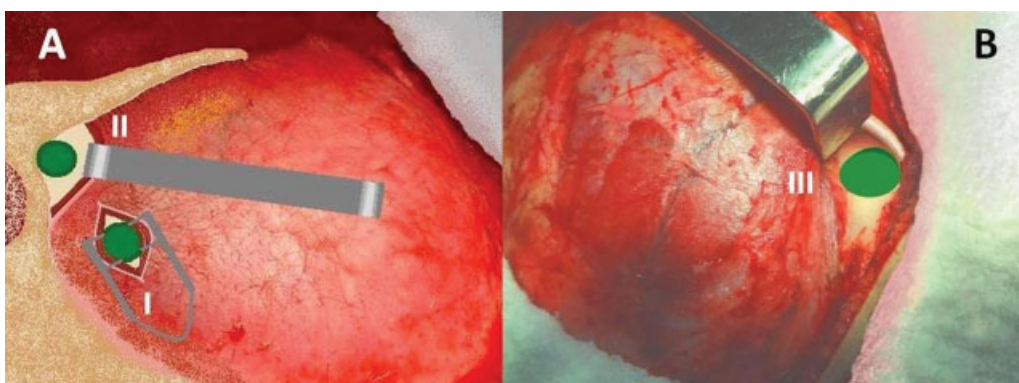


Fig. 5 Practical aspects to trepan the keyholes I, II and III. (A) Keyhole I: the temporal muscle should be cut and dissected vertically, parallel to the direction of its fibers, over the region of trephination, but without releasing it from the laterosuperior edge of the orbit. Keyhole II: dissect and release the temporal muscle from the inferolateral orbital ridge, zygoma and zygomatic arch, which later, you pull it away to the posterosuperior direction exposing the sphenoidal greater wing. (B) Keyhole III: palpate the base of the zygomatic process of the temporal bone under which lays the posterior limit of the temporal muscle, dissect and pull it away to the anterosuperior direction.

part of the inferior orbital fissure is a safe place to cut and drill. To accomplish keyhole II, you must dissect and release the temporal muscle from the inferolateral orbital ridge, zygoma, and zygomatic arch, which later, you pull it away to the posterosuperior direction exposing the sphenoidal greater wing. You can trepan it with a drill or a long trephine (→ Fig. 05).

Keyhole III

To accomplish keyhole III, we palpate the base of the zygomatic process of the temporal bone under which lays the posterior limit of the temporal muscle. We dissect the muscle and pull it away toward the anterosuperior direction and make a burr hole just anterior and above the base of the zygomatic process of the temporal bone; if you use a drill, the hole can be made lower than that (→ Fig. 5). In the past, neurosurgeons adopted this hole to accomplish craniotomies for the trigeminal rhizotomy¹⁶ and basilar aneurysm surgery by the subtemporal approach.^{17,18} Otologists did the same to access the internal acoustic meatus by the middle fossa approach.^{19,20} Keyhole III gives access to the medium laterobasal region of the temporal lobe, more specifically, on the inferior temporal gyrus in the transition between the temporal fossa and the anterior ascendant surface of the petrous bone; in the coronal plane it relates to the upper portion of the clivus.²¹

Keyhole IV

To accomplish keyhole IV you can perform the transattical mastoidectomy, identify the sinodural angle of Citelli and after that, drill a greater hole just above its vertex, above the sigmoid sinus. In practice, opening keyhole IV can be simplified by performing a trepanation on the squamosal suture (see later).

Others Burr Holes or Marks

Burr hole V should be made in the frontolateral region, preferably above of the hairline for aesthetic reason, and preventing to open the frontal sinus and to cause injury the supraorbital nerve. Mark VI is situated in the frontoparietal region, mark VII has parieto-occipital location and mark VIII, if present, will have an occipital location. Marks and craniotomy cutting lines should be outside of the temporal muscle insertion line (→ Fig. 1).

Orbital Dissection

The periosteum is cut along the orbital rim with a scalpel, carrying out the dissection with a sharp dissector and entering the orbital cavity by continuously scraping the bone. The periorbita, the periosteum of the orbit, should be dissected and detached along the laterosuperior and lateroinferior wall of the orbital cavity, deeply enough to expose keyholes I and II internally. The strength applied to the cutaneous flap retraction should be done gradually with hooks, and as needed to dissect the periorbita. The regions of greater fragility of the periorbita are the laterosuperior region, close to the frontozygomatic suture, due to the presence of the lacrimal gland and in the upper region next to the supraorbital nerve foramen, especially if it stays

in a canal, which should be opened with a diamond drill to release the nerve. Despite this, often the periorbita rips releasing some of the orbital fat, but that does not lead to any dysfunction if it is repaired and/or protected accordingly; it can be sutured with some stitches of Vicryl 4/0 and/or covered with Surgicel or a layer of Gelfoam or equivalent materials. To protect the eyeball, it is always good practice to cover it with the dura mater flap during the surgery.

Fronto-orbital Cutting

To cut the fronto-orbital region, you need to insert one end of the Gigli saw through keyhole V and pull it out through keyhole I, and again, insert it in the same keyhole I, but now, pull it out through the orbital cavity. The eyeball must be properly protected during the osteotomy. By doing that, you cut the skull along with the upper edge of orbit. The cutting will be more medial if burr hole V is more medial but we avoid opening the frontal sinus and/or injure the supraorbital nerve, branch of the trigeminal ophthalmic nerve, responsible for regional sensitivity of the skin of the forehead, and of the skin and tunica conjunctiva of the central part of the upper eyelid (→ Fig. 6A).

Orbitozygomatic and Zygomatic Arch Cutting

The lateroinferior wall of the orbit and the zygoma can be cut along with a Gigli saw or with a manual or electric saw, or alternatively, with a drill, while the eyeball is kept properly protected. If you are going to use the Gigli saw, insert one end through the orbital cavity, allowing it to get out through keyhole II and thereafter, pass it underneath the zygomatic arch, but above the temporal muscle. Then, adjust the saw below the zygoma and cut it along with the inferolateral wall of the orbit (→ Fig. 6A). We try to cut the zygoma just beside the zygomaticofacial foramen, preserving the zygomaticofacial nerve, branch of the maxillary nerve of the trigeminal nerve that is responsible for the sensitivity of the skin of that region. Still during the surgery, if the integrity of the zygomatic arch is not maintained, you need to cut it near its base in the temporal bone, but sometimes the arch disarticulates itself while it is being cut.

Laterosuperior Craniotomy

We cut the bone skirting the temporal muscle through burr holes or marks V, VI, VII, and eventually VIII, until keyhole IV with a Gigli saw or craniotome (→ Fig. 6B). The supratentorial burr hole VIII can be accomplished near the inion when you want to combine it with an infratentorial or transtentorial approach. The line provided by the external occipital protuberance between the inion and asterion roughly indicates the position of the transversal sinus and can be a baseline for further posterior extensions.

Lateroinferior Craniotomy

The length between keyholes III and IV: If you opt for the *transattical craniotomy*, instead of *transattical mastoidectomy*, it is safer to use a Gigli saw. Stretch between keyholes III and II: the osteotomy of the laterobasal wall of the temporal fossa should be straight and as low as possible; you can use the Gigli saw and cut the bone only partially to avoid any

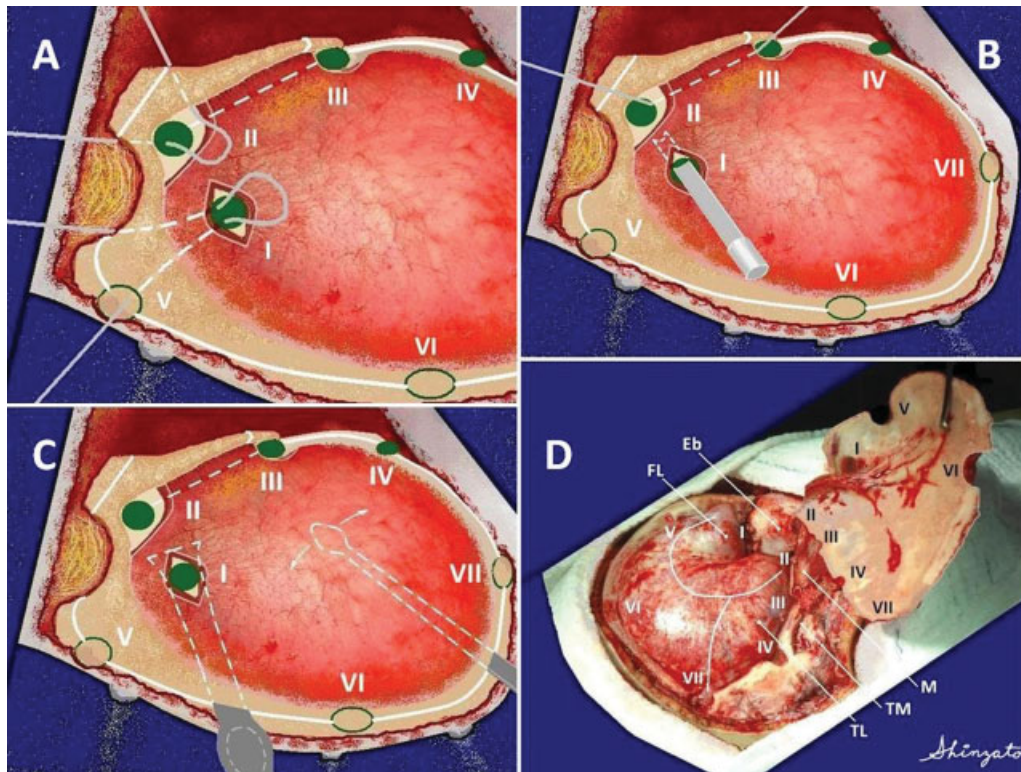


Fig. 6 Osteoplastic Orbitozygomatic-Mastoid-Transattical craniotomy (osteoplastic OZ-MT). (A) Definition of keyholes I, II, III, and IV, and fronto-orbital, orbitozygomatic, and zygoma cutting. (B) Cutting of the lateral wall of the cranium and the posterolateral orbital wall. (C) Dura mater detachment with a dissector and lifting the bone applying a lever with a Lambotte rugine mainly under the sphenoid lesser wing between keyholes I and II. (D) An oblique posteroanterior view of the osteoplastic OZ-MT craniotomy showing keyholes positions, the eyeball (Eb), the frontal lobe (FL), the temporal lobe (TL), the transattical mastoidectomy (TM), the temporal muscle attached to the bone flap (M), and the white line suggesting a dura mater opening.

injury to the temporal muscle; otherwise, use a 2–3 mm diameter diamond drill to make several holes in the bone from keyhole III to keyhole II, or, with a gouge forceps, cut the bone partially from keyhole III to keyhole II, and vice versa. At the end of the craniotomy, this region will be fractured (► Fig. 6B). It is necessary to bear in mind that near the path between keyholes II and III there are the *foramen spinosum* with its middle meningeal artery and the *foramen ovale* with the branch (V3) of Gasser ganglion located more medially (► Fig. 2).

Posterolateral Orbital Wall Cutting

The penultimate stage of the osteoplastic OZ-MT craniotomy, which opens the flap like a “door,” is the internal cutting of the sphenoidal smaller and greater wings that form the posterolateral wall of the orbit. To perform the cutting, we use a suitable chisel that is inserted through keyhole I and, internally, is directed to keyhole II. The chisel should be positioned tangential to the skull as much as possible because medially to keyhole II, ~1 to 1.5 cm in adults, there is the optic nerve, which cannot be forgotten. We used to expand keyhole I by drilling its upper side ridge to have a bigger tilted angle, a better view of its inside, and to insert the chisel correctly (► Fig. 6B). The alternatives to cut the sphenoidal smaller wing internally are by using a diamond drill or a fine-tipped gouge forceps or a Kerrison

rongeur. The cutting can be only partial, but enough to be fractured.

Lifting and Opening

Finally, with a dissector, you lift progressively the osteoplastic flap and with the aid of another dissector, you detach the dura mater from the bone flap and after that, with a Lambotte rugine supported mainly on the lesser sphenoid wing, between keyhole I and keyhole II, you lever the osteoplastic flap until it is fractured. By doing that, you perform the *osteoplastic orbitozygomatic-mastoid-transattical craniotomy (osteoplastic OZ-MT)* (► Fig. 6C–D).

Transattical Mastoidectomy – An Otoneurosurgical Approach

The anatomical and surgical terms and details of the temporal bone follow the description of Salaverry,^{1,2} Portmann,²² Anson and Donaldson,²³ Rothon,²⁴ and some of our own observations. The *petrous process* or *petrous pyramid* is a pyramid-shaped bone with three sides with its base directed toward the lateral skull surface and the apex toward the medial area. At the junction of the anterior and posterior faces, there is a crest, the anatomical limit between the middle and posterior fossae; the most lateral part of the crest is formed by the superior side of the sigmoid sinus sulcus. In the central region of the anterior face of the petrous

pyramid, there is the *arcuate eminence* that is the projection of the superior semicircular canal into the middle fossa, an important surgical reference. On the lateral surface, the superior limit of the mastoid can be defined approximately by the *temporal line*²³ or *supramastoid crest*,²⁴ which is not always obvious. At the posterosuperior part of the *external acoustic meatus* there is the *suprameatal spine of Henle*, which is also an important mark where the surgery on the mastoid should start because below the superficial cells is where the *antrum mastoideum* is located, which provides access to the *tympanic cavity*. On the medial wall of the tympanic cavity, there are the *cochlea* and the *semicircular canals*. The facial nerve enters the *internal acoustic meatus* and crosses the *fallopian canal*, and above the cochlea, it forms the *geniculate ganglion* and continues to the lateral direction. The superior part of the tympanic cavity, above the facial nerve route, is called *epitympanum* or *atticus*, where there are some air cells, the *attical* or *supracochlear cells*, limited by the *tegmen tympani*, which is the cortical limit to the middle fossa. Just above the external acoustic meatus there are pneumatized cells, the *suprameatal cells*, and anteriorly, where the zygomatic process originates, there are also pneumatized cells, the *zygomatic cells*. In the *transattical approach* of Salaverry,^{1,2} to reach the geniculate ganglion, Salaverry drilled the suprameatal, zygomatic and attical cells, and frequently, the tegmen tympani, exposing the dura mater.

We use the term *transattical mastoidectomy* for drilling and cutting the mastoid and the regions of suprameatal and zygomatic cells, and that process is divided into three stages: *trans-sinodural*, *transattical*, and *transzygomatic*. The transattical mastoidectomy is the lowest suprapetrosal craniotomy possible that preserves the functional structures related to the VII and VIII cranial nerves:

- **Trans-sinodural stage.** One begins to drill the mastoid ~5 mm behind and above the suprameatal spine of Henle and follows the supramastoid crest toward the posterior direction, exposing the dura mater and reaching the end of the mastoid air cells, where the *sinodural angle of Citelli* is located, which vertex coincides with the joint of the parietomastoid and the squamosal sutures, on the surface. This spot matches to the *posterior temporobasal point*, described by Gusmão et al.²⁵ as the most lateral point of the superior edge of the petrosal pyramid, which intracranially, is related to the fusiform gyrus. To define keyhole IV, we drill a larger hole just above the Citelli's angle vertex, above the sigmoid sinus. Keyhole IV can be used to extend the craniotomy to the parietal or occipital region, and/or combined with the pre/postsigmoid approaches.
- **Transattical stage.** Next, going to the anterior direction on the supramastoid crest, one drills the mastoid exposing the dura mater. Still maintaining the anterior direction, one arrives to the suprameatal air cells. At this region, if one drills deeper medially, sometimes exposing the dura mater, one reaches the attical or supracochlear air cells. We call this stage transattical because it was through this approach that Salaverry^{1,2} reached the attical air cells and geniculate ganglion. For our purposes, it

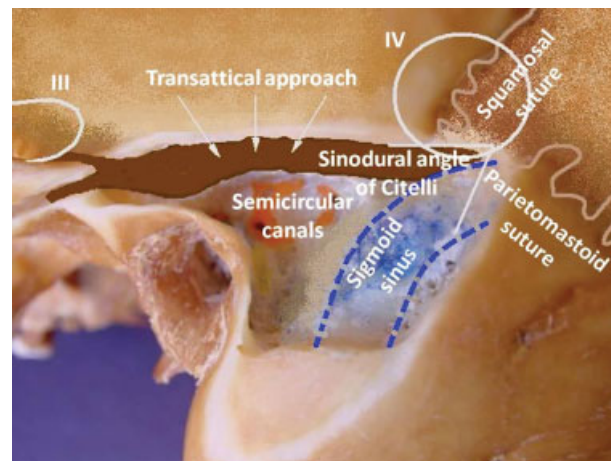


Fig. 7 Anatomical details and relationship of the *transattical mastoidectomy* (the brown area) that is drilled along the supramastoid crest or temporal line. The trans-sinodural stage is on the right, the transattical stage is in the middle, and trans-zygomatic stage is on the left. Keyhole IV is drilled just above the vertex of the sinodural angle of Citelli. To reach the keyhole III we can follow two drilling routes, above or below the zygomatic process. Therefore, in this technique, keyholes III can be localized in front or even below the temporal zygomatic process base.

is only necessary to expose the local dura mater without reaching the attical region.

- **Trans-zygomatic stage.** Continuing anteriorly and drilling the zygomatic air cells, always exposing the dura mater, one can follow two alternative routes: (1) the drilling line passing just under the zygomatic process to reach keyhole III (in this case, the zygomatic arch will be totally preserved) or (2) the drilling a line passing a little higher than the zygomatic arch to reach keyhole III (in this case, the zygomatic arch must be cut) (► Fig. 7).

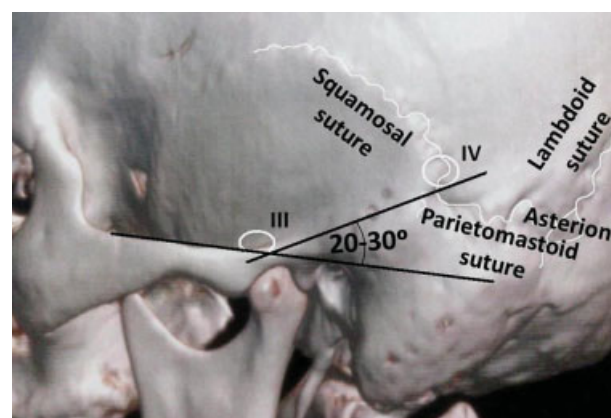


Fig. 8 The *transattical craniotomy*. We drill or trephine the keyhole IV on the squamosal suture ~5 to 10mm above the supramastoid crest or above the spot where parietomastoid suture meets the squamosal suture. If those anatomical elements are not visible, they can be estimated: starting from the temporal zygomatic process, we can draw a straight line ~20 to 30 degrees above the direction of the zygomatic arch to represent the temporal line or the supramastoid crest. Keyholes III is situated in front of and above the base of the temporal bone zygomatic process.

We emphasize that it is not necessary to drill and open the *antrum*, expose the semicircular canals, nor reach the attical region. The sigmoid and transverse sinus will be exposed only when one wants to combine pre and or postsigmoid approaches. Also, we do not recommend preserving the zygomatic arch in people who have weak bones due to the risk of compromising the anatomy and physiology of the temporomandibular joint.

Transattical Craniotomy – A Practical Approach

The transattical mastoidectomy can be simplified and approximate (less basal) by the *transattical craniotomy*. In this technique, originating from the otologic concept of the sinodural angle of Citelli, the craniotomy practically matches the first stretch of the suprapetrosal craniotomy described by Ribas et al.²¹ We drill or trephine keyhole IV on the squamosal suture ~5 to 10 mm above the supramastoid crest or above of the spot where the parietomastoid suture meets the squamosal suture. If those anatomical elements are not visible, starting from the temporal zygomatic process, we can draw a straight line ~20 to 30 degrees above the

zygomatic arch direction to represent the temporal line or supramastoid crest (in children and women the angle is smaller than in adult men). Keyhole IV must always be drilled or trephined carefully using bone wax because its location is just above the sigmoid sinus. To finish, one cuts the cranium in a straight line uniting keyholes III and IV, without tilting and preferably using the Gigli saw. The transattical craniotomy does not preserve the zygomatic arch integrity (– Fig. 8).

Results

The *osteoplastic OZ-MT* craniotomy is an anatomical, very systematized type of skull base approach which unifies all lateral transcranial accesses and enables the opening in a one-piece-only bone flap, of all the laterobasal wall of the skull and the removal in one or more surgical stages, those large intra and/or extracranial lesions or tumors. Despite the the opening of the cranium being wide, its shutting is immediate, similar to the action of “closing door.” We fix the bone only in three or four points: fronto-orbital, zygoma,

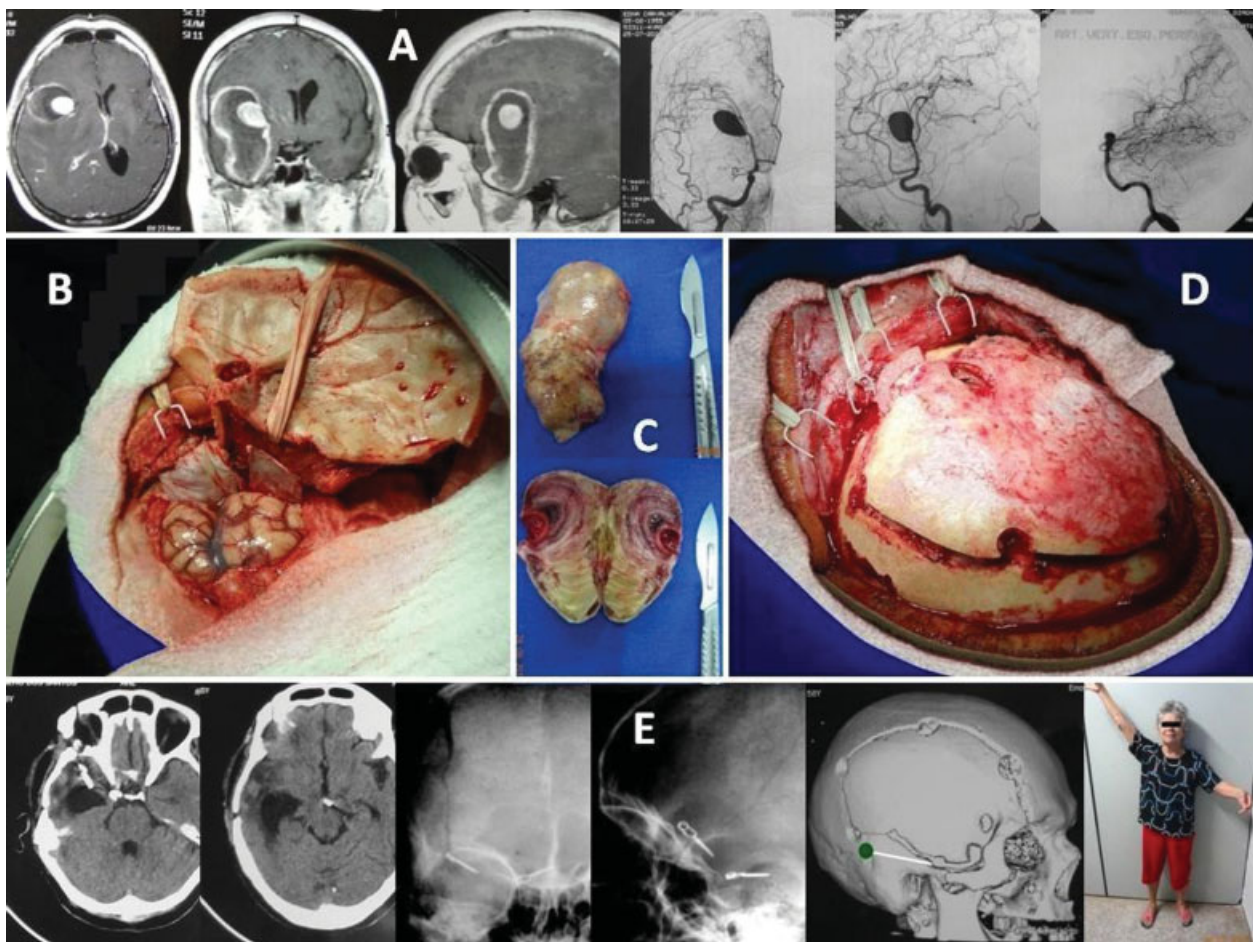


Fig. 9 Patient ECS, female, 58 years old, with chronic headache and left hemiparesis. (A) MRI and angiography showed a big aneurysm at the right M1/M2 and another one at the basilar artery tip. (B and C) We used the osteoplastic orbitozygomatic craniotomy (osteoplastic OZ) to clip the aneurysms and to remove the giant aneurysm that was almost totally thrombosed. (D) The bone and muscle synthesis were done easily like shutting a “door.” (E) The postoperative CT and X-ray control show the craniotomy and the presence of the aneurysm clips at the M1/M2 and at the basilar tip. For didactic purposes, the green mark on the 3D reconstruction shows the position of keyhole IV and the white line would be the transattical mastoidectomy or transattical craniotomy that were not necessary to use in this case. After two years post-surgery, the patient is well, only with the initial hemiparesis, but with perfect facial and head aesthetic condition.

on the superior or posterior region of the craniotomy, and the zygomatic arch if it is cut. We have not had any complications nor any important sequels related to those techniques so far. The aesthetic and functional result is very good, with little or no atrophy or sinking of the temporal muscle because it is not detached from the bone, and the subjacent greater wing of the sphenoidal bone is kept almost intact without the formation of a groove.

The osteoplastic OZ-MT craniotomy allowed us to conceive several osteoplastic craniotomies, variants of the classic techniques, making it possible to opt for a most appropriate approach according to each case: (1) osteoplastic pterional craniotomy (osteoplastic P), an extended variant of the pterional craniotomy, that coincides with the (2) osteoplastic pretemporal craniotomy (osteoplastic PT), a variant of the pretemporal craniotomy; (3) osteoplastic orbitozygomatic craniotomy (osteoplastic OZ), an extended variant of the orbitozygomatic craniotomy (→Fig. 9); (4) osteoplastic supraorbital-pterional craniotomy (osteoplastic SP), an extended variant of the supraorbital-pterional craniotomy; (5) osteoplastic pterional-mastoid-transattical craniotomy (osteoplastic P-MT), a combination of the pterional craniotomy with the transattical mastoidectomy; (6) osteoplastic supraorbital pterional-mastoid-transattical craniotomy (osteoplastic SP-MT), a combination of the supraorbital-pterional craniotomy with the transattical mastoidectomy; (7) osteoplastic pretemporal mastoid-transattical craniotomy

(osteoplastic PT-MT), a combination of the pretemporal craniotomy with the transattical mastoidectomy; (8) osteoplastic OZ-MT or osteoplastic SP-MT or osteoplastic P-MT or osteoplastic PT-MT combined with transpetrosal, transtentorial, retrosigmoid and/or presigmoid approaches; (9) osteoplastic decompressive craniotomy, unilateral or bilateral.

Discussion

Historically, we understand that the current lateral transcranial approaches are made up of: (1) the *subfrontolateral* or *unilateral subfrontal* by Krause,²⁶ initially suggested by Horsley²⁷ that this approach offers accesses to the olfactory, chiasmatic, and lamina terminalis cistern regions; later, the technique was improved by resection of the supraorbital ridge; the pioneering works with resection of the orbital ridge belong to McArthur,²⁸ Frazier,²⁹ and Jane et al³⁰; (2) the *subfrontotemporal*, initially accomplished in 1918 by George J. Heuer,^{31,32} which was adopted and modified in 1942 by Walter E. Dandy,^{33,34} and in 1968 by Ludwig G. Kempe^{35,36} allowing greater retraction of the temporal lobe; finally, it was refined in 1975 by Yasargil et al,^{11,37-39} with an interfascial approach, drilling of the sphenoid ridge with a wider visualization of the Sylvian fissure that promotes the transsylvian and lateral subfrontal views, as well as a straight downward view of the anterolateral aspect of the basilar bifurcation; today it is established as *pterional*

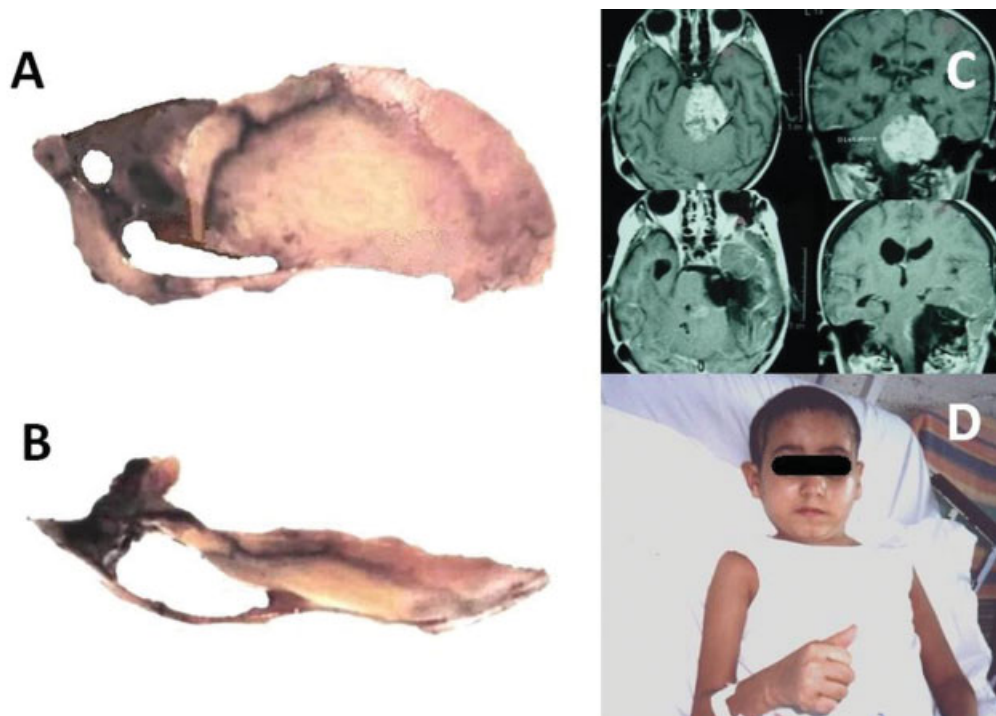


Fig. 10 Patient EO, male, 9 years old, gcs = 15 after hydrocephalus treatment, paresis of III, IV and VI nerves on left and right hemiplegia. One of the first cases (1998) submitted to the *en bloc orbitozygomatic-mastoid-transattical craniotomy (en bloc OZ-MT)* performed in two steps: one surgery for the craniotomy and other to operate the tumor. (A) and (B): lateral and superior views of the *en bloc OZ-MT* bone piece preserving the zygomatic arch. (C): Pre and postoperative MRI. (D): Ten days after the tumor removal the patient told us that he was feeling fine, but unfortunately the histopathological result was a grade three astrocytoma. (*En bloc orbitozygomatic-mastoid-transattical craniotomy. III International Skull Base Congress. Foz do Iguaçu, 2000*) (*Craniotomia orbitozygômático-matoideo-transattical en bloc. XXV Congresso Brasileiro de Neurocirurgia. Goiânia, 2004*).

craniotomy^{40,41}; (3) the *orbitozygomatic infratemporal approach* by Hakuba et al,⁶ published in 1986, the *supraorbital-pterional approach* of 1987 and the *zygomatic approach to skull base lesion* from 1990 published by Al-Mefty et al⁴²⁻⁴⁴ extend the pterional craniotomy and enable an upward vision of the frontal lobe and third ventricle proximity; the *orbitozygomatic infratemporal approach* also promotes a better surgical access to the basilar tip; the idea of an orbito-frontomalar approach was initiated by Pellerin et al⁴⁵ in 1985 and the orbitozygomatic craniotomy was improved by Ikeda et al⁷ in 1991, transforming it into a one-piece approach; (4) the *pretemporal craniotomy* described by De Oliveira et al^{46,47} in 1993 and 1995, and afterward by other authors,^{48,49} exposes the entire temporal lobe to offer the transsylvian and lateral subfrontal views along with the subtemporal and temporopolar views to access the interpeduncular fossa; the technique was based on the *subtemporal approach* by Drake^{50,51} that offers a lateral view of the interpeduncular fossa, and on the *temporopolar approach* of Sano⁵² of 1980 that pulls back the temporal pole enlarging an anterolateral view of the interpeduncular fossa; the addition of the subtemporal and temporopolar views to the transsylvian and subfrontal views is of great importance when a neurosurgeon needs to expose the interpeduncular cistern region or the entire temporal lobe, including the medial portion; (5)

the suprapetrosal craniotomy²¹ that presents the basal aspect of supratentorial temporo-occipital craniotomies.

For about twenty years, we have routinely used the *en bloc OZ* and the *en bloc OZ-MT* in children (►Fig. 10) and adults (►Fig. 11) up to the development of the *osteoplastic OZ-MT* and its variants craniotomies, unifying all classical lateral transcranial accesses. We use it and/or its variants, without/with combinations of accesses, to treat and/or remove mainly mesial, basal, intra, and or extra-cranium lesions, starting from the anterior fossa, passing through the middle fossa and going up to the regions of the clivus, basilar artery, and cerebellum-pontine angle, with greater surgical degree of freedom, and consequent reduction of morbidity and mortality.

With training, practice, and use of appropriate instruments, the *osteoplastic OZ-MT* craniotomy can be accomplished in less than two hours. Classical approaches variants can spend only one hour. In more fragile patients, due to hematologic depletion and easiness to shut and reopen the cranium, we sometimes have used the option to operate large tumors in two steps: initially, we accomplish the osteoplastic craniotomy and “shut the door.” After one to two weeks, we “reopen the door” and operate immediately. If the osteoplastic flap is maintained away properly, it does not disturb the surgery. Usually we use a compressive bandage at the postoperative time, with a subgaleal Penrose or suction drain.

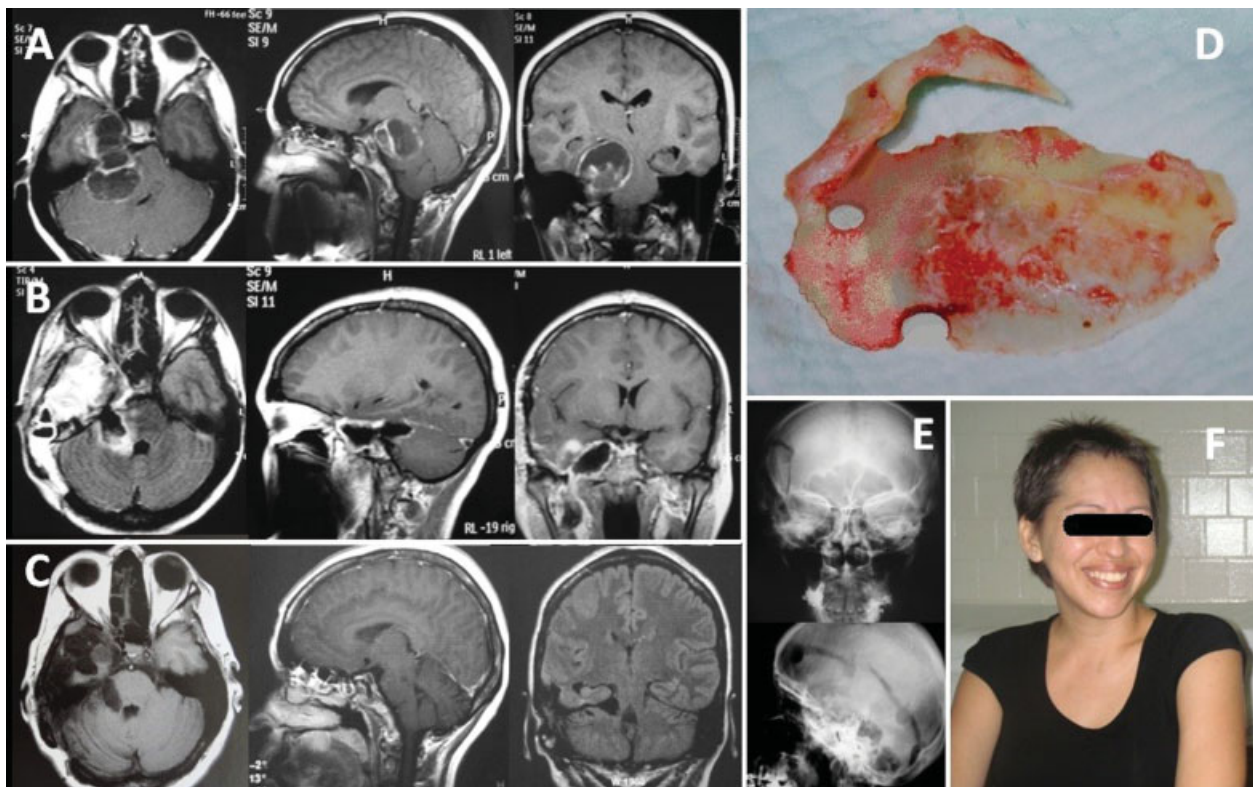


Fig. 11 Patient MP, female, 30 years old, with refractory hemifacial pain and corneal hypoesthesia on the right, and mild hemiparesis on the left. (A) Trigeminal “dumbbell-shaped” schwannoma that was operated by the *en bloc OZ-MT* in 2009. (B) First week and (C) five years postoperative follow-up. (D) The *en bloc OZ-MT* bone piece without preserving the whole zygomatic arch. (E) The postoperative X-ray control and (F) the patient after three months postoperative with perfect aesthetic appearance, which is preserved until nowadays, without any complaint or sequel. (Acesso cirúrgico para neurinomas trigeminais. XXI Encontro dos Neurocirurgiões do Brasil Central, Bonito, MS, 2010).

Conclusion

The *osteoplastic OZ-MT* is a very systematic, anatomical, feasible, and safe craniotomy. The synthesis is easy to do and the craniotomy can be easily and quickly reopened, if necessary. Variants and combinations allow us to opt for a more appropriate approach according to each case.

Acknowledgments

We would like to acknowledge and show gratitude to the following people who somehow contributed to the publication of this work:

Professor Flávio Freinkel Rodrigues (UFRJ) and Professor José Francisco Salomão (IFF-FioCruz) for their teachings in Neurosurgery. In memoriam, Gianni Maurélio Temponi (UFRJ) for his teaching in Neurosurgery, Professor Marcial Armando Salaverry (UFRJ) for the training provided in Otoneurosurgery, and Professor Akira Hakuba (Osaka City University), who encouraged us to develop and publish this work.

We also would like to thank all our colleagues at Santa Casa Hospital, especially Doctor Joel de Brito Daroz, with whom we have accomplished *en bloc* OZ craniotomies for decades.

References

- Salaverry MA. Via Transsattical. Variante técnica para a descompressão total do nervo facial. *Rev Bras Otorinolaringol* 1974;40:262-264
- Salaverry MA. Transsattical Approach to the Labyrinthine Segment of the Facial Nerve. In: Graham MD, House MF. *Disorders of the Facial Nerve*. New York: Raven Press; 1982
- May M. Total facial nerve exploration: transmastoid, extralabyrinthine, and subtemporal indications and results. *Laryngoscope* 1979;89(6 Pt 1):906-917
- Yanagihara N. Transmastoid Decompression of the Facial Nerve Using Supralabyrinthine Approach. In: Portmann M. - *Facial Nerve*. New York: Masson Publishing USA, Inc; 1984
- Pierre JHAA. A César o que é de César. *Int Arch Otorhinolaringol* 1998;2(4):6
- Hakuba A, Liu S, Nishimura S. The orbitozygomatic infratemporal approach: a new surgical technique. *Surg Neurol* 1986;26(3):271-276
- Ikeda K, Yamashita J, Hashimoto M, Futami K. Orbitozygomatic temporopolar approach for a high basilar tip aneurysm associated with a short intracranial internal carotid artery: a new surgical approach. *Neurosurgery* 1991;28(1):105-110
- Hakuba A, Nishimura S, Jang BJ. A combined retroauricular and preauricular transpetrosal-transtentorial approach to clivus meningiomas. *Surg Neurol* 1988;30(2):108-116
- Al-Mefty O, Fox JL, Smith RR. Petrosal approach for petroclival meningiomas. *Neurosurgery* 1988;22(3):510-517
- Kawase T, Shiobara R, Toya S. Anterior transpetrosal-transtentorial approach for sphenopetroclival meningiomas: surgical method and results in 10 patients. *Neurosurgery* 1991;28(6):869-875, discussion 875-876
- Yaşargil MG, Reichman MV, Kubik S. Preservation of the frontotemporal branch of the facial nerve using the interfascial temporalis flap for pterional craniotomy. Technical article. *J Neurosurg* 1987;67(3):463-466
- MacCarty CS. Surgical techniques for removal of intracranial meningiomas. *Clin Neurosurg* 1959;7(7):100-111
- MacCarty CS. The Surgical Treatment of Intracranial Meningiomas. *Springfield Charles C Thomas* 1961:57-60
- MacCarty CS, Brown DN. Orbital tumors in children. *Clin Neurosurg* 1964;11:76-93
- Shimizu S, Tanriover N, Rhoton AL Jr, Yoshioka N, Fujii K. MacCarty keyhole and inferior orbital fissure in orbitozygomatic craniotomy. *Neurosurgery* 2005;57(1, Suppl):152-159, discussion 152-159
- Frazier CH, Gardner WJ. The Radical Operation for the Relief of Trigeminal Neuralgia. *Surg Gynecol Obstet* 1928;47:73-77
- Drake CG. Aneurysms of the Posterior Circulation. In: Symon L. (ed.): *Operative Surgery: Neurosurgery*, ed. 3. London: Butterworths; 1979:263-291
- Drake CG. Bleeding aneurysms of the basilar artery. Direct surgical management in four cases. *J Neurosurg* 1961;18:230-238
- House WF. Surgical exposure of the internal auditory canal and its contents through the middle, cranial fossa. *Laryngoscope* 1961;71:1363-1385
- Brackman DE, Hitzelberger WE, Beneke JE, House WF. Acoustic Neuromas: Middle Fossa and Translabyrinthine Removal. In: Rand RW. (ed.): *Microneurosurgery*, ed. 3. St. Louis: Mosby; 1985:311-334
- Ribas GC, Rodrigues AJ Jr. The suprapetrosal craniotomy. *J Neurosurg* 2007;106(3):449-454
- Portmann M. Les Voies D'accès Chirurgical. In *Traité de Technique Chirurgicale ORL et Cervico-Faciale*. Tome premier: Oreille et Os Temporal. Paris: Editeurs Masson & Cie; 1975:29-39
- Anson BJ, Donaldson JA. *Surgical Anatomy of the Temporal Bone and Ear*. Philadelphia: WB Saunders Company; 1973
- Crânio RAL Jr. *Anatomia e acessos cirúrgicos: osso temporal e acessos transtemporais*. Di Livros Editora Ltda. Rio de Janeiro, RJ, 2009; pp 635-687
- Gusmão S, Silveira RL, Arantes A. Landmarks to the cranial approaches. *Arq Neuropsiquiatr* 2003;61(2A):305-308
- Krause F. *Hirnehirurgie*. Deutsch. Klib. 1905;8:953-1024
- Horsley V. On the Technique of Operations on the Central Nervous System. *BMJ* 1906;2:411-423
- McArthur LL. An Aseptic Surgical Access to the Pituitary Body and its Neighborhood. *JAMA* 1912;58:2009-2011
- Frazier CH. I. An Approach to the Hypophysis through the Anterior Cranial Fossa. *Ann Surg* 1913;57(2):145-150
- Jane JA, Park TS, Pobereskin LH, Winn HR, Butler AB. The supraorbital approach: technical note. *Neurosurgery* 1982;11(4):537-542
- Heuer GJ. Surgical Experience with an Intracranial Approach to Chiasmal Lesions. *Arch Surg* 1920;1:368-381
- Borden WB, Tamargo RJ, George J, Heuer: forgotten pioneer neurosurgeon at the Johns Hopkins Hospital. *J Neurosurg* 2002;96(6):1139-1146
- Dandy WE. Aneurysms of the Anterior Cerebral Artery. *JAMA* 1942;119:1253-1254
- Dandy WE. *Intracranial Arterial Aneurysms*. New York: Hafner. 1944, reprinted 1969
- Kempe LG. *Operative Neurosurgery*. Springer Verlag New York 1970
- Kempe LG. *Operative Neurosurgery*, vol. 1, Cranial, Cerebral and Intracranial Vascular Disease. Berlin: Springer-Verlag; 1968
- Yaşargil MG, Fox JL. The microsurgical approach to intracranial aneurysms. *Surg Neurol* 1975;3(1):7-14
- Yaşargil MG, Fox JL, Ray MW. The Operative Approach to Aneurysms of the Anterior Communicating Artery. In: Krayenbühl H. (ed.): *Advances and Technical Standards in Neurosurgery*. Vienna-New York: Springer-Verlag; 1975:113-170
- Yaşargil MG, Antic J, Laciga R, Jain KK, Hodosh RM, Smith RD. Microsurgical pterional approach to aneurysms of the basilar bifurcation. *Surg Neurol* 1976;6(2):83-91

- 40 Ljunggren B, Fox JL. History of the Pterional Approach. *Atlas of Neurosurgical Anatomy*. New York: Springer; 1989:1–9
- 41 Wen HT, Oliveira E, Tedeschi H, et al. The Pterional Approach: Surgical Anatomy, Operative Technique, and Rationale. In: *Operative Techniques in Neurosurgery*, vol. 4, issue 2. Elsevier Inc; 2001:60–72
- 42 Al-Mefty O. Supraorbital-pterional approach to skull base lesions. *Neurosurgery* 1987;21(4):474–477
- 43 al-Mefty O, Anand VK. Zygomatic approach to skull-base lesions. *J Neurosurg* 1990;73(5):668–673
- 44 Al-Mefty O, Borba LAB. Skull Base Highways: Surgical Approaches to Lesions of the Cranial Base. *J Bras Neurol* 1996;7(3):5–16
- 45 Pellerin P, Lesoin F, Dhellemmes P, Donazzan M, Jomin M. Usefulness of the orbitofrontomalar approach associated with bone reconstruction for frontotemporosphenoid meningiomas. *Neurosurgery* 1984;15(5):715–718
- 46 De Oliveira E, Siqueira M, Tedeschi H, Peace DA. Surgical Approaches for Aneurysms of the Basilar Artery Bifurcation. In: Matsushima T. (Ed.). *Surgical Anatomy for Microneurosurgery VI: Cerebral Aneurysms and Skull Base Lesions*. Fukuoka City, Japan: Sci Med Publications; 1993:34–42
- 47 De Oliveira E, Tedeschi H, Siqueira MG, Peace DA. The pretemporal approach to the interpeduncular and petroclival regions. *Acta Neurochir (Wien)* 1995;136(3–4):204–211
- 48 Tedeschi H, De Oliveira E, Wen HT. Pretemporal Approach to Basilar Bifurcation Aneurysms. *Tech Neurosurg* 2000;6:191–199
- 49 Chaddad-Neto F, Dória-Netto HL, Campos-Filho JM, Reghin-Neto M, Oliveira E. Pretemporal craniotomy. *Arq Neuropsiquiatr* 2014;72(2):145–151
- 50 Drake CG. The surgical treatment of aneurysms of the basilar artery. *J Neurosurg* 1968;29(4):436–446
- 51 Drake CG. The treatment of aneurysms of the posterior circulation. *Clin Neurosurg* 1979;26:96–144
- 52 Sano K. Temporo-polar approach to aneurysms of the basilar artery at and around the distal bifurcation: technical note. *Neurol Res* 1980;2(3–4):361–367