

# Caudal Regression Syndrome in a 12-Year-Old Boy Associated with Thecal Sac Ending at Fifth Lumbar Vertebrae Associated with Caudal Stenotic Dural Sac and Thickened Filum Terminale, Bifid Lumbar Vertebrae with Sacral Vertebral Agenesis: Pentads Defects

Guru Dutta Satyarthee<sup>1</sup> Ashok Kumar Mahapatra<sup>2</sup>

<sup>1</sup>Department of Neurosurgery, Neurosciences Centre, All India Institute of Medical Sciences, New Delhi, India

<sup>2</sup>Department of Neurosurgery, Neurosciences Centre, All India Institute of Medical Sciences, Bhubaneswar, Odisha, India

Address for correspondence Guru Dutta Satyarthee, MCh, Department of Neurosurgery, Neurosciences Centre, All India Institute of Medical Sciences, Room No. 714, New Delhi-110029, India (e-mail: duttaguru2002@yahoo.com).

Indian J Neurosurg 2017;6:62–66.

## Abstract

Caudal regression syndrome is characterized by a spectrum of structural defects of the caudal vertebral region, varying from isolated agenesis or dysgenesis of coccyx to lumbosacral agenesis. It may be associated with congenital anomaly, spinal cord, distal genitourinary tract, and gastrointestinal tract. The authors report late presentation of caudal regression syndrome in a 12-year-old male student who had low backache and deformity of foot since childhood. He developed urinary incontinence by the age of 7 years. Magnetic resonance imaging revealed complete agenesis of lower three sacral and coccyx vertebral segments, with spina bifida of lower lumbar vertebra, stenosis of lumbar dural sac and thecal sac ending at L5, associated thickened filum terminale, and tethered cord. He underwent L2–L5 laminectomy with duraplasty and detethering of cord. Intraoperatively, markedly overcrowded lumbar and sacral nerve roots were observed. He noticed improvement of foot weakness and relief of backache following surgery.

## Keywords

- ▶ caudal agenesis
- ▶ pentads

## Introduction

Caudal regression syndrome is a rare congenital anomaly with characteristic agenesis or dysgenesis of caudal vertebrae varying from isolated partial agenesis of coccyx or entire lumbosacral vertebrae.<sup>1,2</sup> It may be associated with congenital anomaly of spinal cord, genitourinary tract, and gastrointestinal tract.<sup>3–5</sup> The children with extensive bony defects in caudal regression syndrome may present with stork leg deformity, narrow iliocostal interval, and significant smaller transverse pelvic diameter, in those cases also having complete sacrum

agenesis.<sup>6–8</sup> The authors present an interesting case in which the patient had the thecal sac extending only up to fifth lumbar vertebrae, stenotic caudal thecal sac, thickened filum terminale, bifid lumbar vertebrae, and agenesis of lower sacral and coccygeal vertebral segments.

## Case Report

A12-year-old boy was referred by the orthopedician to our neurosurgical outpatient services with a history of progressive low backache with radiation to both lower limbs. He noticed

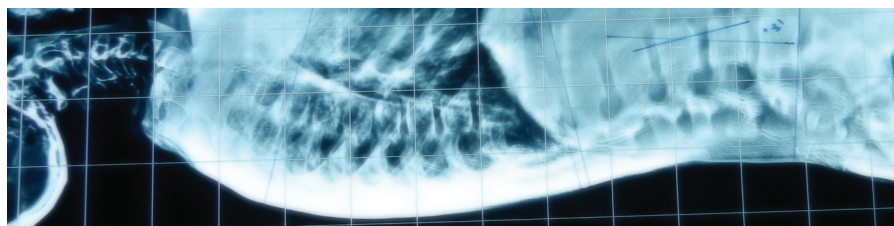
received  
March 21, 2016  
accepted  
May 5, 2016  
published online  
February 10, 2017

DOI <http://dx.doi.org/10.1055/s-0036-1585459>.  
ISSN 2277-954X.

© 2017 Neurological Surgeons' Society of India

License terms





**Fig. 1** X-ray spine lateral view showing scoliosis of dorsal spine with absent lower sacral and coccygeal spinal segment.

increase in intensity since childhood along with progressive deformity of feet and incontinence of urine since the age of 8 years. He had no other significant medical illness in the past and was delivered at full term. His early development and growth was otherwise normal. His mother had unremarkable medical history with no infection or drug intake during pregnancy. Mother had no history of diabetes mellitus. He consulted the orthopaedician for deformity of feet. On admission, he had bilateral with equinovarus foot deformity; the stigmata of spinal dysraphism or kyphoscoliosis were absent. He had wasting of both leg and foot muscles and had power of grade 4 at ankle joints. Plantars were flexors on both sides. There was no sensory impairment.

Lateral view of the spine's X-ray showed scoliosis of dorsal spine. (► **Fig. 1**) X-ray of the lumbosacral spine (lateral view) revealed spina bifida of lumbar vertebrae and complete agenesis of three distal sacral and coccygeal vertebral segments with absent lower sacral and coccygeal vertebrae. (► **Fig. 2**) Computed tomography of lumbosacral spine and sagittal section showed presence of club-shaped rudiment of upper sacral vertebrae, (► **Fig. 3**) and coronal image further clearly substantiated the X-ray findings of lower sacral agenesis (► **Fig. 4**)

Magnetic resonance imaging of lumbosacral spine sagittal T1-weighted section, demonstrated thecal sac ending at L5 vertebral level along with agenesis of lower sacral and coccygeal spinal segment, (► **Figs. 5 and 6**) presence of residual upper two sacral vertebrae, with spinal cord ending at L2 vertebral body level, associated with marked stenosis of lumbar dural sac at L2–L4 vertebral body level, and thickened filum terminale. (► **Fig. 7**)

Under general anesthesia, L4–S1 laminectomy was performed.

The ligamentum flavum was marked hypertrophied. The dural sac was marked stenosed and dura was opened. Lumbar dural sac was very tight and nerve roots were overcrowded.

The filum terminale was thickened and adherent to dural sac, untethering of cord was done with duraplasty. However, no lipoma or meningocele was observed during surgery.

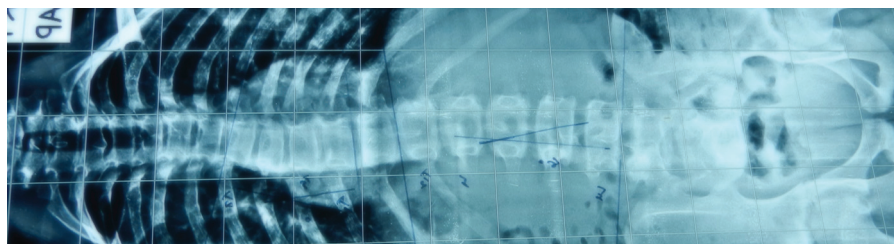
The patient had an uneventful postoperative period. His weakness markedly improved and backache completely subsided. However, he had no improvement in the incontinence of urine.

## Discussion

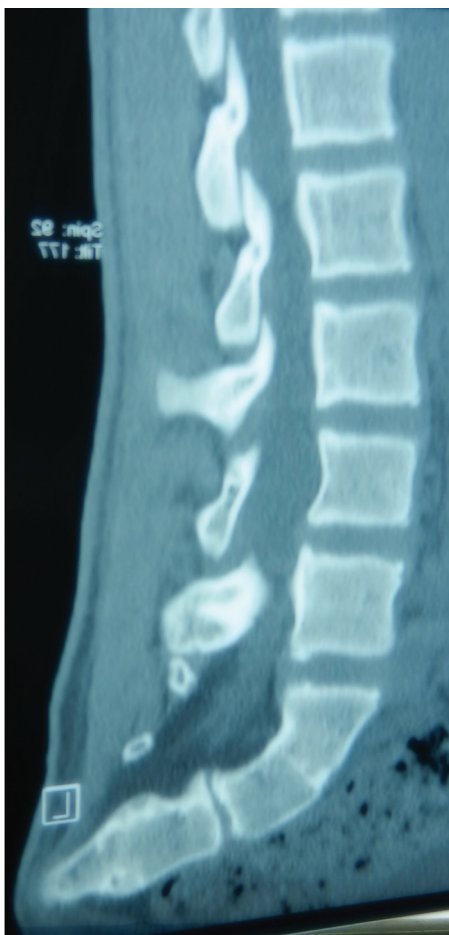Caudal regression syndrome is rare with an incidence of 1 in 7,500 to 25,000 live births,<sup>1–5</sup> but incidence associated with diabetic mother can increase up to 15%.<sup>4–8</sup> The vertebral congenital defect may range from isolated agenesis of coccyx to aplasia of the coccyx, sacrum, and lumbar and very rarely even up to the lower thoracic vertebrae. Barkovich et al<sup>3</sup> analyzed 13 cases, the last vertebra was T8 in 25% case, 17% in L1–L5, and S1 or more caudal in rest 58% cases.

Embryologically, the caudal spine, the caudal spinal cord, the anorectal complex, and lower genitourinary tract have a common origin from the caudal eminence of embryo. It is probable that a teratogenic insult during development of these structures may produce anomalies of one or more systems in the different combination. The more extensive bone defect is associated with more severe neurological defects. Nieselstein et al<sup>4</sup> proposed the defect of primary neurulation in the genesis of caudal regression syndrome. The first sacral segment is probably derived from somite 29 and 30, while S2–S5 from somite 30–34. These are formed between stage 12 and 13 of embryonic development corresponding to 26 to 28 days of fetal life.<sup>9–11</sup> The caudal neuropore closes at the development of somite 31, corresponding to development of second sacral vertebrae or somites 32–34, which corresponds to third to fifth sacral vertebrae.<sup>12</sup>

Our case was associated with stenosis of dural sac and tethered spinal cord was ending at L2 vertebral body level



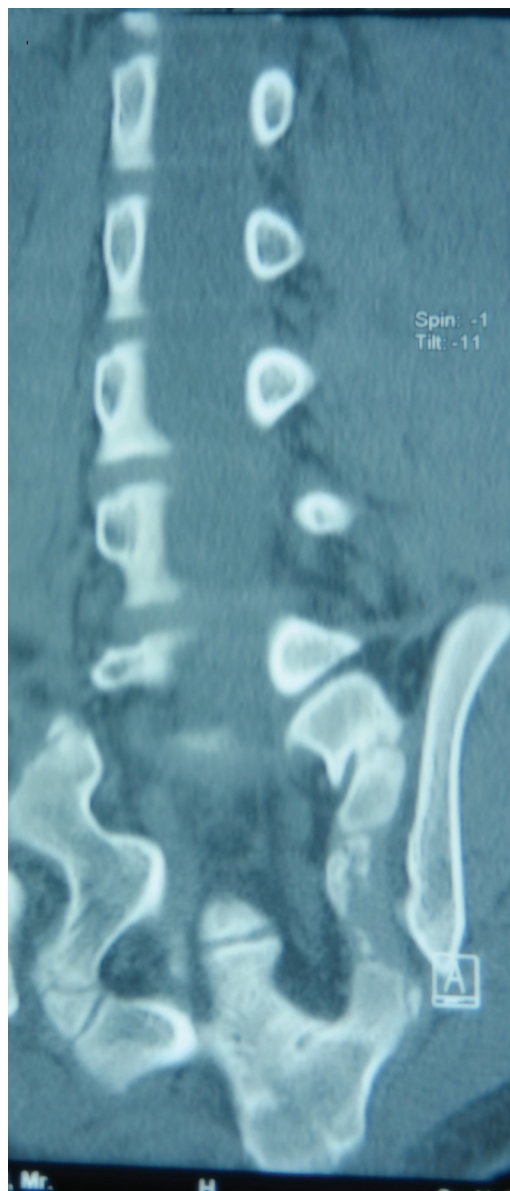
**Fig. 2** X-ray spine, anteroposterior view showing dysraphic lumbar and absent lower sacral and coccygeal spinal segment.



**Fig. 3** Computed tomography scan of lumbosacral spine, sagittal section showing club shaped rudiment of sacral vertebrae.

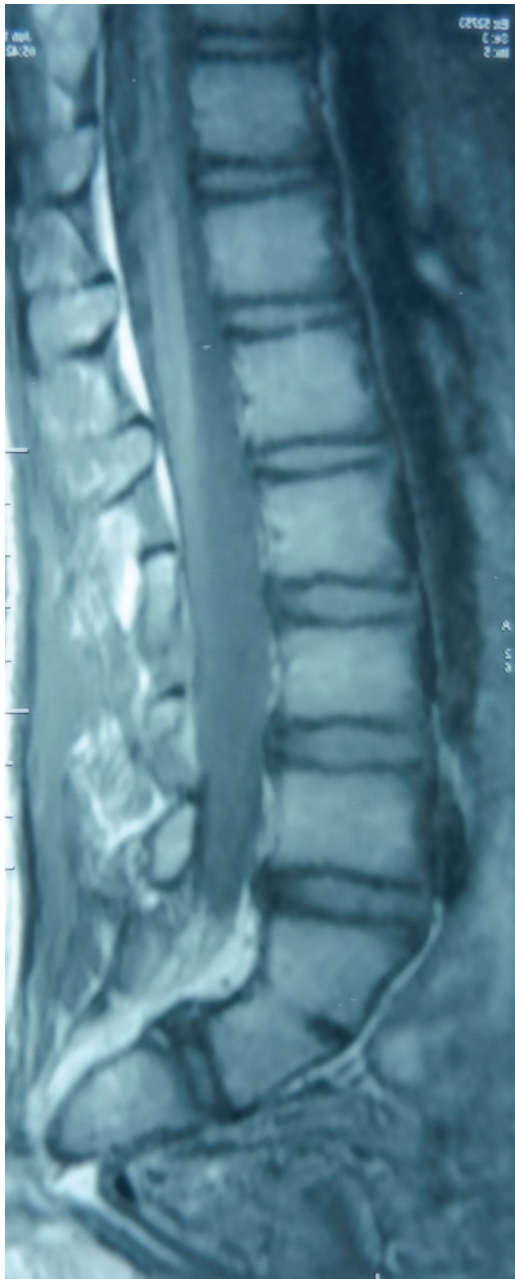
with agenesis of distal thecal sac ending at L5 level. Neurological abnormalities can vary from isolated foot deformity to complete sensorimotor paralysis of lower limbs. Our patient also had foot deformity with weakness of muscles of foot bilaterally. However, children with extensive bony defects may have fat buttocks, narrow iliacostal interval, and stork leg deformity.<sup>2,9</sup> Iliac may articulate below the last available lumbar vertebrae thereby causing significant narrowing of transverse pelvic diameter associated with complete agenesis of sacrum. Patients may have various grades of neurological deficits, but motor deficit is relatively more pronounced than sensory deficit. The characteristic stork leg deformities due to selective involvement of the muscle of perineum supplied through sacral S2 to S5 and of the legs and buttocks L5 and S1 nerve roots.<sup>11,13</sup> Sensory findings are less pronounced. The dorsal root ganglion and associated peripheral sensory elements, being of neural crest origin, are unaffected by the pathological process of caudal agenesis even though the corresponding segment of neural tube are affected.

Urinary problems are extremely common,<sup>10,14</sup> as our patient had no sensory impairment but had urinary incontinence. It may be associated with abnormality of anorectal complex or genitourinary tract.<sup>15-17</sup> It may be associated with vertebral anomalies, anal imperforation, tracheoesophageal fistula and/or



**Fig. 4** Computed tomography scan of lumbosacral spine of a 12-year-old boy, coronal image demonstrating lower sacral agenesis.

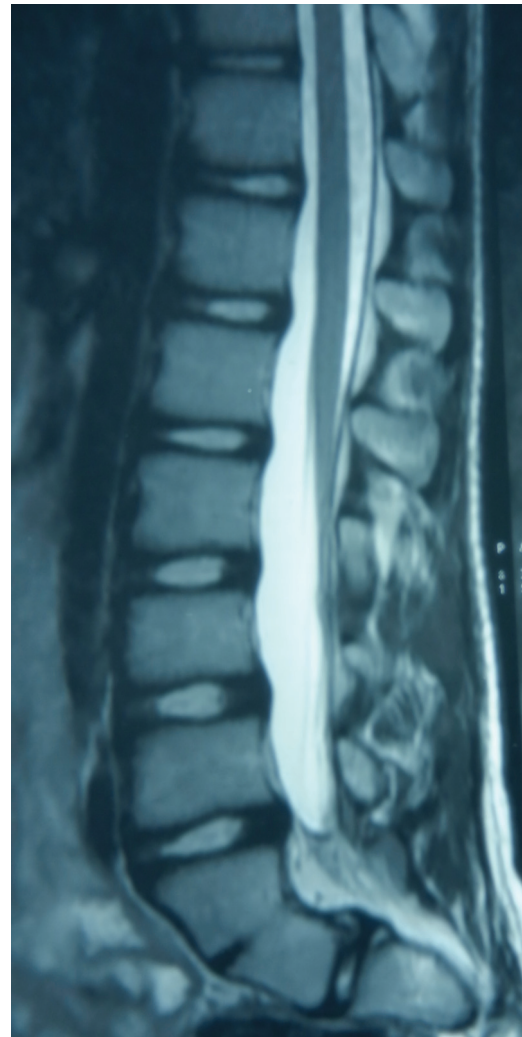
esophageal atresia, and radial and renal dysplasia anomalies (VATER association).<sup>13</sup> Caudal dural sac also has many abnormalities.<sup>16,18</sup> The caudal dural sac often tapers narrowing below the cord terminus and ends at unusually high level. The tapering is more obvious if associated with agenesis of higher segments of vertebral column. In some cases, narrowing of dural sac may be extreme leading to dural canal stenosis.<sup>17,18</sup> Dural canal stenosis was observed in our patient both radiologically as well during surgery. Surgical therapy is advised to the patients having treatable neural lesion, that is, tethered cord, dural canal stenosis, and myelocystocele.<sup>9,16,19</sup> Muthukumar et al<sup>6</sup> also advocated surgery, even in cases where sacral agenesis is associated with nonprogressive neurological deficit. The authors also previously recommended an early surgery which could prevent further neurological deficit and even advocated prophylactic surgical intervention.<sup>20</sup>



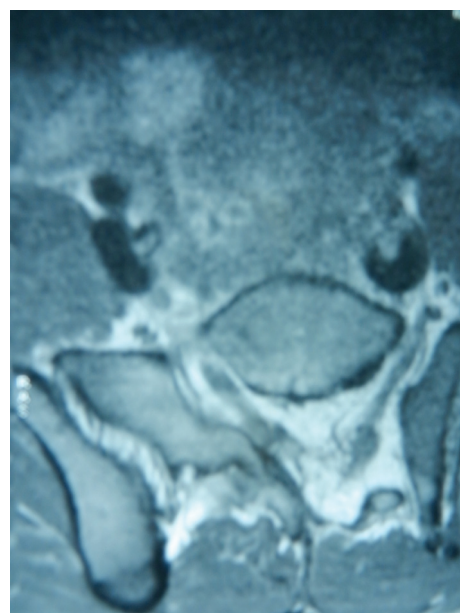
**Fig. 5** Magnetic resonance imaging of lumbosacral spine of a 12-year-old boy, sagittal T1-weighted image showing end of thecal sac at L5 vertebral level along with agnesis lower sacral and coccygeal spinal segment.

### Conclusion

The authors report an interesting case report of caudal regression syndrome with dural canal stenosis in a 12-year-old boy. Following surgery, partial neurological recovery was observed, which was probably related to delayed surgical intervention. So every suspected case of sacral agnesis with neurological deficit should undergo detailed neuro imaging to detect any treatable neurosurgical pathology and surgical intervention should be provided at the earliest possible age so as to completely ameliorate the neurological deficit.



**Fig. 6** Magnetic resonance imaging of lumbosacral spine T2-weighted image, sagittal section showing end of thecal sac at L5 vertebral level along with agnesis lower sacral and coccygeal spinal segment.



**Fig. 7** Magnetic resonance imaging of lumbosacral spine, axial section, T1-weighted image, showing agnesis of thecal sac.

**References**

- 1 Muthukumar N, Gurunathan J, Sampathkumar M, Gajendran R. Sacral agenesis occurring in siblings: case report. *Neurosurgery* 1992;30(6):946–948
- 2 Adra A, Cordero D, Mejides A, Yasin S, Salman F, O'Sullivan MJ. Caudal regression syndrome: etiopathogenesis, prenatal diagnosis, and perinatal management. *Obstet Gynecol Surv* 1994;49(7):508–516
- 3 Barkovich AJ, Raghavan N, Chuang S, Peck WW. The wedge-shaped cord terminus: a radiographic sign of caudal regression. *AJNR Am J Neuroradiol* 1989;10(6):1223–1231
- 4 Nievelstein RA, Valk J, Smit LM, Vermeij-Keers C. MR of the caudal regression syndrome: embryologic implications. *AJNR Am J Neuroradiol* 1994;15(6):1021–1029
- 5 Subtil D, Cosson M, Houfflin V, Vaast P, Valat A, Puech F. Early detection of caudal regression syndrome: specific interest and findings in three cases. *Eur J Obstet Gynecol Reprod Biol* 1998; 80(1):109–112
- 6 Muthukumar N. Surgical treatment of nonprogressive neurological deficits in children with sacral agenesis. *Neurosurgery* 1996;38(6):1133–1137, discussion 1137–1138
- 7 Hirano H, Tomura N, Watarai J, Kato T. Caudal regression syndrome: MR appearance. *Comput Med Imaging Graph* 1998; 22(1):73–76
- 8 Passarge E, Lenz W. Syndrome of caudal regression in infants of diabetic mothers: observations of further cases. *Pediatrics* 1966; 37(4):672–675
- 9 Pang D. Sacral agenesis and caudal spinal cord malformations. *Neurosurgery* 1993;32(5):755–778, discussion 778–779
- 10 Towfighi J, Housman C. Spinal cord abnormalities in caudal regression syndrome. *Acta Neuropathol* 1991;81(4):458–466
- 11 O'Rahilly R, Meyer DB. The timing and sequence of events in the development of the human vertebral column during the embryonic period proper. *Anat Embryol (Berl)* 1979;157(2): 167–176
- 12 Müller F, O'Rahilly R. The development of the human brain, the closure of the caudal neuropore, and the beginning of secondary neurulation at stage 12. *Anat Embryol (Berl)* 1987;176(4): 413–430
- 13 Quan L, Smith DW. The VATER association. Vertebral defects, anal atresia, T-E fistula with esophageal atresia, radial and renal dysplasia: a spectrum of associated defects. *J Pediatr* 1973;82(1): 104–107
- 14 Boemers TM, van Gool JD, de Jong TPVM, Bax KMA. Urodynamic evaluation of children with the caudal regression syndrome (caudal dysplasia sequence). *J Urol* 1994;151(4): 1038–1040
- 15 Karrer FM, Flannery AM, Nelson MD Jr, McLone DG, Raffensperger JG. Anorectal malformations: evaluation of associated spinal dysraphic syndromes. *J Pediatr Surg* 1988;23 (1 Pt 2):45–48
- 16 Pang D, Hoffman HJ. Sacral agenesis with progressive neurological deficit. *Neurosurgery* 1980;7(2):118–126
- 17 Morimoto K, Takemoto O, Wakayama A. Tethered cord associated with anorectal malformation. *Pediatr Neurosurg* 2003;38(2): 79–82
- 18 Muthukumar N. Sacral agenesis: neurological implication. In: Venkataraman S, ed. *Progress in Clinical Neurosciences*. New Delhi: Neurological Society of India: Mediworld Publication; 1996;11:277–286
- 19 Tsugu H, Fukushima T, Oshiro S, et al. A case report of caudal regression syndrome associated with an intraspinal arachnoid cyst. *Pediatr Neurosurg* 1999;31(4):207–212
- 20 Kumar A, Mahapatra AK, Satyarthee GD. Congenital spinal lipomas: role of prophylactic surgery. *J Pediatr Neurosci* 2012; 7(2):85–89