

Posttraumatic Internal Carotid Artery Pseudoaneurysm: Endovascular Management by Stent–Graft Placement

Vivek Agarwal¹ R. V. Phadke¹ Vivek Singh¹

¹ Department of Radiology, Sanjay Gandhi Postgraduate Institute of Medical Sciences, Lucknow, Uttar Pradesh, India

Indian J Neurotrauma 2016;13:116–119.

Address for correspondence Vivek Agarwal, MBBS, MD, DNB, FRCR, Department of Radiology, Sanjay Gandhi Postgraduate Institute of Medical Sciences, Lucknow, Uttar Pradesh, India (e-mail: vivekagarwal0004@gmail.com).

Abstract

Intracavernous internal carotid artery (ICA) pseudoaneurysms are extremely rare among isolated sphenoid fractures. We report a case of a 28-year-old man who suffered from neurotrauma due to a fall of the ceiling fan over the head and subsequently developed headache with recurrent episodes of profuse epistaxis for the next 10 days. Magnetic resonance angiography revealed a large pseudoaneurysm involving intracavernous ICA. The patient underwent emergent digital subtraction angiography and a covered stent graft was used to reconstruct the ICA. Patient was discharged 5 days later completely asymptomatic and was called up for follow-up after 3 months. This case report highlights the importance of high index of suspicion of vascular injury and emergent endovascular treatment to prevent mortality in base of skull fractures.

Keywords

- ▶ intracavernous internal carotid artery
- ▶ stent graft
- ▶ epistaxis
- ▶ pseudoaneurysm

Introduction

Posttraumatic pseudoaneurysm of intracranial internal carotid artery (ICA) is a rare complication of skull base fractures secondary to blunt or penetrating trauma. Patients may present with headache or severe and recurrent epistaxis immediately or months after the head trauma. A possibility of intracranial vascular injury should be considered especially in patients with refractory epistaxis with a history of head trauma. Surgical repair of these lesions is difficult with high rates of cerebral hypoperfusion. An endovascular approach is considered first line of management as it limits the risk of operative damage to surrounding structures and cerebral parenchyma. We present a case of neurovascular trauma that was successfully treated by stent-graft reconstruction of the cavernous ICA.

Case Presentation

A 28-year-old man suffered from neurotrauma due to fall of a ceiling fan over the head 20 days back. After the trauma, the

patient was unconscious for 45 minutes. Initial computed tomography scan (▶**Fig. 1**) done at an outside institution revealed pneumocephalus with fracture of the right lateral wall of sphenoid sinus. Hyperdense collection was also noted in the sphenoid sinus on the right side. Patient was managed conservatively. After 15 days of injury, patient developed moderate intensity headache with profuse epistaxis. Magnetic resonance angiography (▶**Fig. 2**) revealed a large pseudoaneurysm measuring 2.5 × 1.5 cm × 1.2 cm communicating with the intracavernous ICA. Patient was referred to our institution for further management. On admission, the patient had moderate headache and a 3-day history of right-side ptosis. His initial Glasgow Coma Scale score was 15 (eye: 4; motor: 6; verbal: 5). No other comorbidities were present.

Digital subtraction angiography was performed that confirmed a laterally directed lobulated pseudoaneurysm of the right cavernous ICA measuring 27 × 18 mm (▶**Fig. 3**). Balloon test occlusion (BTO) was performed to assess the risk of stroke following permanent total ICA occlusion, but it was well

received

May 8, 2016

accepted

July 13, 2016

published online

August 4, 2016

© 2016 Neurotrauma Society of India

DOI <http://dx.doi.org/>

10.1055/s-0036-1586739.

ISSN 0973-0508.

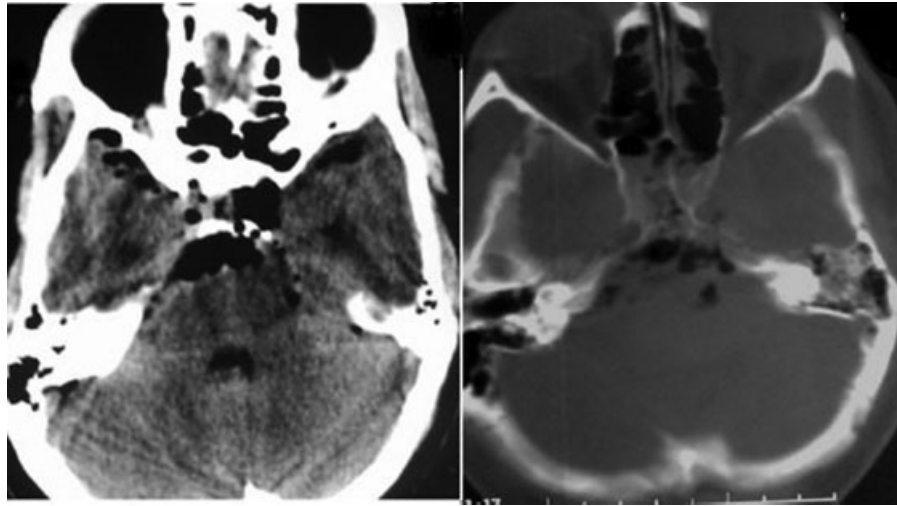


Fig. 1 Computed tomography scan axial images shows skull base pneumocephalus with collection in sphenoid sinuses.

tolerated for 20 minutes without neurological deficits. Balloon-expandable polytetrafluoroethylene (PTFE)-covered stent graft was deployed to reconstruct the rent in the parent artery.

The procedure was done under general anesthesia with appropriate electrocardiogram, arterial oxygen saturation, and blood pressure monitoring. Patient was premedicated with 150 mg of aspirin and 75 mg of clopidogrel for 2 days before the procedure. Baseline activated clotting times (ACTs) were obtained before the procedure. Percutaneous access was obtained via the right femoral artery, and a 7F sheath was inserted. Systemic heparinization with a bolus injection of heparin (5,000 IU) was administered before the therapeutic procedure and an additional 1,000 IU was administered every hour to maintain an ACT of >250 seconds throughout the

procedure. A 6F catheter (Neuron MAX, Penumbra, Alameda, California, United States) was navigated into the distal petrous ICA segment, and preprocedural angiograms were obtained in orthogonal planes. A 300-cm-long, 0.014-inch microwire (Transcend 14, Target/Boston Scientific, Natick, Massachusetts, United States) was navigated into the third segment of the middle cerebral artery. A 4/25-mm-sized PTFE-covered stent graft (Prograft, Vascular Concepts, Essex, United Kingdom) was then advanced over the microwire and positioned across the neck of the pseudoaneurysm by using roadmap imaging and external stent markings. The stent was then deployed and expanded by inflating slowly up to 16 atm. Following stent deployment, the postprocedure angiogram (► **Fig. 4**) confirmed the normal patency of the ICA and perfect sealing of the aneurysm neck with no opacification of the sac. After the procedure, the patient was advised 150 mg of aspirin and 75 mg of clopidogrel daily for 6 months. The headache and ptosis improved gradually and the patient was called up for follow-up after 3 months.

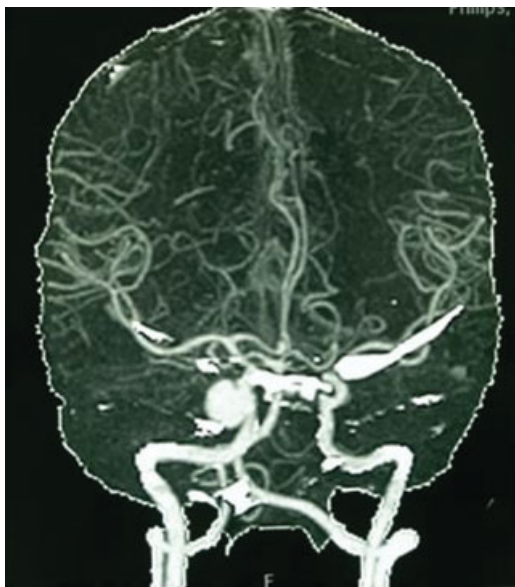


Fig. 2 Magnetic resonance angiography images showing an aneurysm involving cavernous segment of the right internal carotid artery.

Discussion

Pseudoaneurysm results from a breach in the vessel wall such that the blood is contained by the adventitia or surrounding perivascular soft tissue. A pseudoaneurysm of the intracranial ICA is a rare complication with incidence of approximately 3 to 5%.¹ Most cases result either after a blunt or penetrating traumatic injury or after previous surgery. The risk of rupture is higher than that of a true aneurysm of comparable size due to poor support of the aneurysm wall, and thus false aneurysms generally require emergent treatment. The patients may be either completely asymptomatic or may present with headache and recurrent epistaxis due to rupture in sphenoid sinus as in our case. Cavernous ICA is relatively fixed and is in close proximity to sphenoid sinus that predisposes it to injury. Such patients are at higher risk of distal thromboembolism and rebleeding with intracranial hemorrhage.² The mortality rate of posttraumatic aneurysms

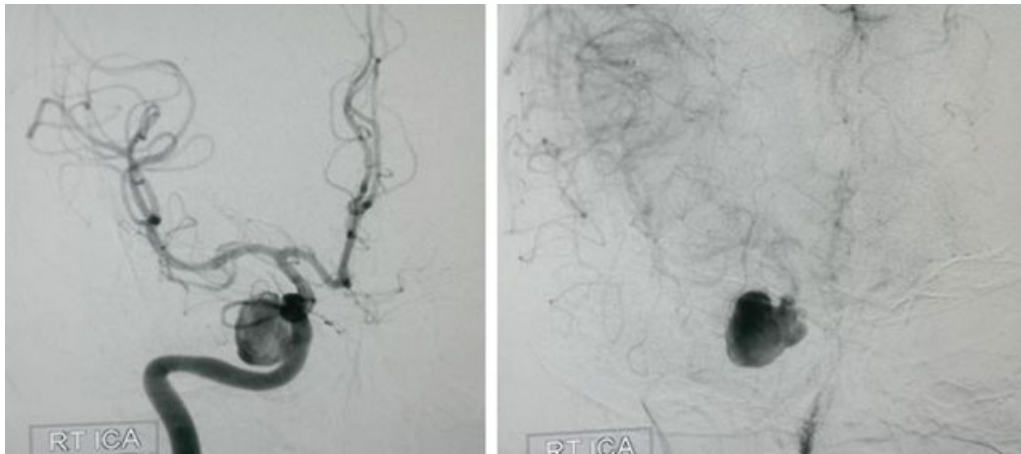


Fig. 3 Digital subtraction angiography images showing lobulated pseudoaneurysm arising from cavernous part of the right internal carotid artery.

with rupture into the sphenoid sinus ranges from 30 to 50%.³ Early diagnosis and prompt treatment is essential in such cases.

Hematoma in the sphenoid sinus or sella turcica should alert a clinician to a possible traumatic intracavernous ICA injury in a supportive clinical context. Carotid angiography is the gold standard investigation to look for the anatomy of the aneurysm and associated bony injuries to decide the further approach. Magnetic resonance angiography is also a good option when the risks of radiation are considered.

Cavernous ICA pseudoaneurysms were previously managed by an emergent surgical repair. But the location of the vessel at the skull base, surrounded by the adjacent sphenoid bone, cavernous sinus, and cranial nerves, complicates direct surgical approach. Even if the BTO is well tolerated, sacrificing the parent artery may result in cerebral hypoperfusion and ischemia in 5 to 22% of patients.⁴ An endovascular reconstructive approach to

these pseudoaneurysms limits the risk of operative damage to surrounding structures without increasing the risk of iatrogenic stroke. Therefore, we decided to use a balloon-expandable graft stent to reconstruct the parent artery.

Coil embolization may not be feasible in all cases due to the lack of a true wall in these pseudoaneurysms, which may result in extrusion of the coil mass and enlargement of the pseudoaneurysm.^{5,6} Use of stent grafts has been described in several case reports for construction of the parent vessel.^{2,7} Graft stents have the advantage of parent artery preservation with lesser rates of aneurysmal recanalization or recurrence. Prograft is a low-profile covered stent system with ultrathin expandable PTFE covered material. It is readily available in India and can be employed for neurovascular disorders. Another self-expandable PTFE covered stent (Peripheral Stent Graft, Jomed GmbH, Rangendingen, Germany) is used mainly for peripheral vessels at our institute. There is a definite risk of additional injury to the vessel wall either by the graft or the

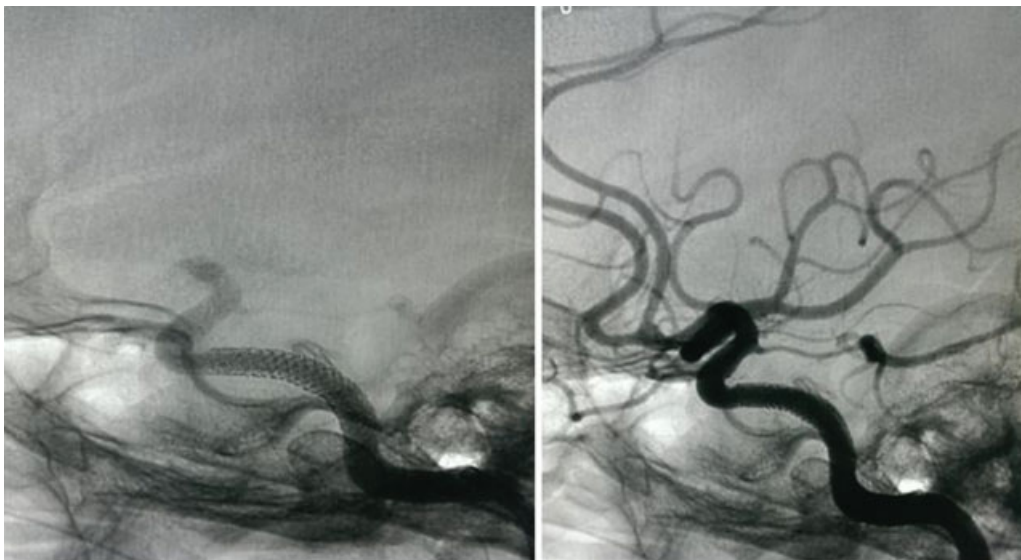


Fig. 4 Poststent digital subtraction angiography shows stent graft in situ with no filling of the aneurysm sac.

guidewire. Also, these stents are relatively inflexible and difficult to negotiate through the tortuous vascular segments at the skull base. Additional risks of intimal hyperplasia and stent thrombosis are also present.

Conclusion

Intracavernous pseudoaneurysms should be considered in patients with a previous history of neurotrauma presenting with refractory epistaxis. Early detection with emergent endovascular therapeutic management is essential to prevent mortality. Reconstructive approach using covered stent grafts is effective with low incidence of iatrogenic morbidity.

References

- 1 Barr HW, Blackwood W, Meadows SP. Intracavernous carotid aneurysms. A clinical-pathological report. *Brain* 1971;94(4): 607-622
- 2 Maras D, Lioupis C, Magoufis G, Tsamopoulos N, Moulakakis K, Andrikopoulos V. Covered stent-graft treatment of traumatic internal carotid artery pseudoaneurysms: a review. *Cardiovasc Intervent Radiol* 2006;29(6):958-968
- 3 Wang AN, Winfield JA, Güçer G. Traumatic internal carotid artery aneurysm with rupture into the sphenoid sinus. *Surg Neurol* 1986;25(1):77-81
- 4 Eckert B, Thie A, Carvajal M, Groden C, Zeumer H. Predicting hemodynamic ischemia by transcranial Doppler monitoring during therapeutic balloon occlusion of the internal carotid artery. *AJNR Am J Neuroradiol* 1998;19(3):577-582
- 5 Fiorella D, Albuquerque FC, Deshmukh VR, et al. Endovascular reconstruction with the Neuroform stent as monotherapy for the treatment of uncoilable intradural pseudoaneurysms. *Neurosurgery* 2006;59(2):291-300, discussion 291-300
- 6 Zhuang Q, Buckman CR, Harrigan MR. Coil extrusion after endovascular treatment. Case illustration. *J Neurosurg* 2007; 106(3):512
- 7 Saatci I, Cekirge HS, Ozturk MH, et al. Treatment of internal carotid artery aneurysms with a covered stent: experience in 24 patients with mid-term follow-up results. *AJNR Am J Neuroradiol* 2004;25(10):1742-1749